Uludağ Üniversitesi Tıp Fakültesi Dergisi
Journal of Uludağ University Medical Faculty
52, 1930595, 2026
DOI: https://doi.org/10.32708/uutfd.1930595

CASE REPORT

A Rare and Reversible Cause of Encephalopathy: Valproic Acid Encephalopathy

Nida Meriç KOYUNCU YILMAZ[1], Aylin BİCAN DEMİR[1], Anıl MUŞTUCU[2], Rümeysa Ayşe GÜLLÜLÜ[2]

[1] Bursa Uludag University, Faculty of Medicine, Department of Neurology, Bursa, Türkiye.
[2] Bursa Uludag University, Faculty of Medicine, Department of Psychiatry, Bursa, Türkiye.

ABSTRACT

Valproic acid encephalopathy is a rare etiology of encephalopathy, characterized by altered consciousness, cognitive slowing, focal neurological deficits, and paradoxical seizure increase in epileptic patients, all developing during valproic acid treatment. It may be hyperammonemia-related (most common), non-hyperammonemia-related, or hepatotoxicity-related. Serum valproate levels may be elevated or within the therapeutic range. EEG showing diffuse slowing of background activity and triphasic waves is helpful. Our case involves a patient with schizophrenia who was using valproate and developed seizure increase and encephalopathy without obvious metabolic or hepatic predisposing factors. Serum valproic acid levels were within the therapeutic range, but EEG revealed severe encephalopathy with diffuse slowing of background activity, and elevated serum ammonia levels led to diagnosis. Symptoms resolved with discontinuation of valproate and L-carnitine treatment. In the psychiatric patient group, differentiating the findings from encephalopathy and the fact that they are reversible with early diagnosis and treatment are critical.

Keywords: Valproic acid. Encephalopathy. Hyperammonemic. Non-hepatic. Side effect.

Ensefalopatinin Nadir ve Geri Dönüşümlü Bir Nedeni: Valproik Asit Ensefalopatisi

ÖZET

Valproik asit ensefalopatisi, ensefalopati etiyolojisinde nadir bir tablo olup VA tedavisi sırasında gelişen bilinç değişikliği, kognitif yavaşlama, fokal nörolojik defisitler ve epileptik hastada paradoksal nöbet artışı ile karakterizedir. Hiperamonyemik(en sık), non-hiperamonyemik ve hepatotoksisite ilişkili olabilir. Serum valproat düzeyleri yüksek veya terapötik aralıkta olabilir. EEG'de zemin aktivitesinde diffüz yavaşlama ve trifazik dalgalar yardımcıdır. Vakamızda, valproat kullanan ve belirgin metabolik veya hepatik predispozan faktörleri olmaksızın nöbet artışı ve ensefalopati geliştiren bir şizofreni hastası yer almaktadır. Serum valproik asit düzeyleri terapötik aralıkta olmasına rağmen, EEG'de zemin aktivitesinde diffüz yavaşlama ile birlikte ağır ensefalopati saptanmış ve yüksek serum amonyak düzeyleri ile tanıya gidilmiştir. Semptomlar valproat kesilmesi ve L-karnitin tedavisi düzelmiştir. Psikiatrik hasta grubunda bulguların ensefalopati ile ayırt edilmesi gerekliliği ve erken tanı tedavi ile geri dönüşümlü olması kritiktir.

Anahtar Kelimeler: Valproik asit. Ensefalopati. Hiperamonyemik. Non-hepatik. Yan etki.

Many diseases are involved in the etiology of encephalopathy. This case report aims to highlight the critical importance of reversible causes, albeit rare, in differential diagnosis.

Date Received: 15.April.2026
Date Accepted: 13.July.2026

Dr. Nida Meriç KOYUNCU YILMAZ
Bursa Uludag University, Faculty of Medicine,
Department of Neurology, Address: Görükle Campus,
Görükle Neighborhood, University 1st Street,
Door No: 405, 16059 Nilufer / BURSA, Türkiye.
E-mail: nidamkoyuncu@gmail.com

AUTHORS' ORCID INFORMATION
Nida Meriç KOYUNCU YILMAZ: 0009-0003-2903-065X
Aylin BICAN DEMIR: 0000-0001-6739-8605
Anıl MUŞTUCU: 0000-0002-2663-3661
Rümeysa Ayşe GÜLLÜLÜ: 0000-0001-7434-0153

Case

A 45-year-old male patient with known diagnoses of epilepsy and schizophrenia presented to us 2-3 months prior with complaints of command auditory hallucinations, fear of harm, seeing demons, damaging the environment, increased sexual desire and increased religious preoccupations. While hospitalized in a psychiatric clinic for sedation treatment, he experienced jerking in his left arm and developed confusion, inappropriate answers to questions and disorientation throughout the day.

His medical history revealed that he had been receiving antiepileptic treatment for generalized tonic-clonic seizures accompanied by loss of consciousness since 2008. Seizure frequency was variable; valproate, carbamazepine, and topiramate were ineffective at

other centers, and he was being followed up with levetiracetam 3000 mg/day. Psychiatric treatment consisted of paliperidone 150 mg/month, sertraline 100 mg/day, amisulpiride 800 mg/day, valproic acid 1000 mg/day, quetiapine 800 mg/day, alprazolam 1 mg/day, biperiden hydrochloride 4 mg/day and haloperidol 10mg/day for sedation treatment.

Laboratory investigations showed: hemoglobin 10.8, no other abnormalities. ALT, AST, ALP, CK, and serum valproic acid levels(69) were within the normal range.

Imaging findings included: A non-contrast cranial MRI was found to be normal, ruling out hemorrhage and ischemia. An EEG was performed (Figure-1); the results showed slowing of the baseline activity and diffuse delta activity, supporting a diagnosis of severe encephalopathy. It was planned to investigate the patient's blood ammonia levels for valproic acid encephalopathy, reduce levetiracetam treatment from 3*1000mg to 2*1000mg, and start lacosamide 2*50mg, increasing to 2*100mg after one week. Informed consent form was obtained from the patient.



Figure 1:
A bipolar montage, a sensitivity of 7 - 10 µV/mm, a paper speed/time scale of 30 mm/sec, a low-frequency filter of 0.5 - 1 Hz, a high-frequency filter of 70 Hz, and a 50 Hz notch filter was used in all EEG recordings.

The initial EEG showed background activity consisting of waves in the 3-4 Hz, 30-35 µv theta band. Delta activity was diffusely distributed at 3-4 Hz, 60-65 µv. Slowing of the baseline activity and diffuse delta activity were consistent with severe encephalopathy.

Results

The patient's blood ammonia level was found to be 118(Normal range:18-72), and 134 the following day. It was recommended that the valproate dose be reduced from 1000mg/day to 750mg/day, then to 500mg/day after 3 days and then discontinued after 3 days. Additionally, after hyperammonemia was detected, the patient was started on intravenous hydration and supportive treatment with L-carnitine 2*1000mg. Four days after valproate dose reduction was started and L-carnitine treatment was started, an EEG (Figure 2) showed slowing of the baseline activity and diffuse slow-wave activity, consistent with mild encephalopathy. The patient, who refused treatment, was discharged from the psychiatry clinic and re-evaluated 15 days later at the neurology outpatient clinic. Valproate treatment was already discontinued, and valproate blood levels were <2. Neurological examination revealed the patient to be fully awake, oriented and cooperative. A control EEG (Figure 3) showed focal (left fronto-centro-temporal) theta activity. Blood ammonia levels were found to be 81.

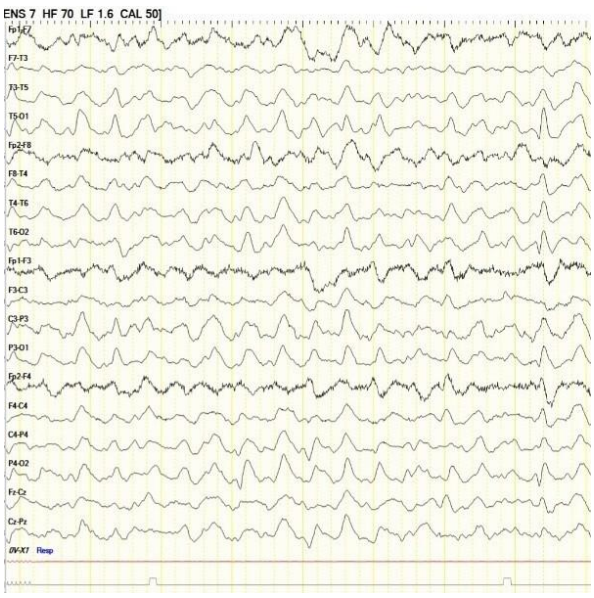

Figure 2:
Four-day later EEG; Background activity consisted of waves in the 5-6 Hz, 40-45 µv theta band. The 5-6 Hz, 40-45 µv theta activity was diffusely distributed. Slowing of the baseline activity and diffuse slow-wave activity are consistent with mild encephalopathy.

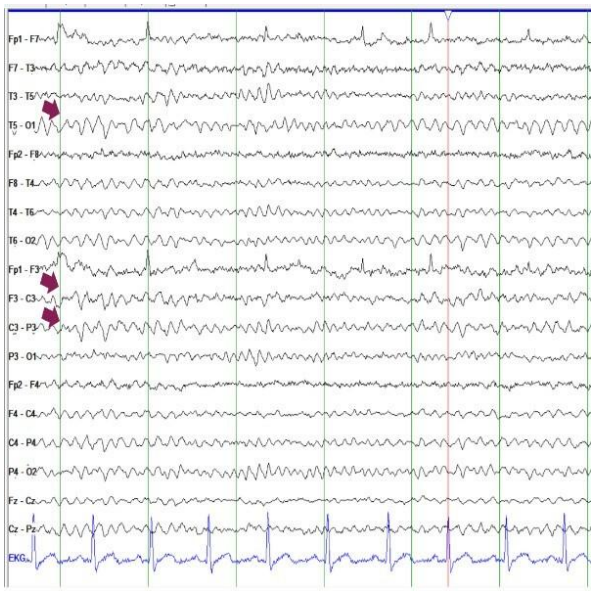

Figure 3:
Outpatient control EEG; Background activity consisted of waves in the 9-10 Hz, 30-35 µv alpha band. Alpha waves were blocked upon opening the eye. 5-6 Hz, 40-45 µv theta activity localized to the left fronto-centro-temporal (focal).

Discussion and Conclusion

Valproic acid encephalopathy is a rare etiology of encephalopathy[1,2]. It accounts for less than 1% of all encephalopathy causes[1], and its frequency in patients using valproic acid is between 0.1% and 2%[3]. It is characterized by altered consciousness, cognitive impairment, focal neurological deficits, and paradoxical seizure increase in epileptic patients, all occurring during valproate treatment[1,3]. It may be hyperammonemia-related (most common), non-hyperammonemia-related, or hepatotoxicity-related[2,4]. Risk factors include polytherapies; combined use of valproate with phenobarbital, phenytoin, carbonic anhydrase inhibitors (acetazolamide), or carbamazepine; urea cycle enzyme defects; high dose-rapid dose escalation; liver disease; infection; and catabolic states[3,5]. However, as in our patient, it can also occur independently of dose and duration of drug use, without. obvious metabolic or hepatic predisposing factors [1] Serum valproate levels may be high or within the therapeutic range[3]. In diagnosis, elevated blood ammonia levels, diffuse slowing on EEG, and triphasic waves are helpful[6,7]. Cranial imaging is usually normal in most cases, although edema may be observed in severe cases[1]. It is a reversible condition, and discontinuation of valproate is often sufficient[2]. In Gerstner et al.'s case series, all patients showed improvement upon discontinuation of valproate[1]. L-carnitine 50-100 mg/kg/day can be used as supportive therapy to correct mitochondrial dysfunction and β-oxidation in hyperammonemia; hemodialysis may be applied in severe cases[2,8].

In prognosis, dramatic improvement is seen in most cases within 24-72 hours[1,2], while delayed diagnosis can lead to coma and, rarely, death[2,3]. There are reported cases with psychiatric illness, and careful differential diagnosis is necessary as psychiatric findings may be confused with the patient's encephalopathy[9,10]. It should be remembered that valproate encephalopathy can develop even at therapeutic valproate levels and with normal liver function tests, as in our patient, and that it can be reversible with prompt diagnosis and treatment.

Researcher Contribution Statement:

- **Conception/Design:** A.B.D
- **Case Management:** A. M., R. A. G., A. B. D., N. M. K. Y.
- **Data Collection/Analysis:** N. M. K. Y.
- **Literature Review:** N. M. K. Y.
- **Drafting & Revising:** N. M. K. Y., A. B. D.
- **Final Approval:** N. M. K. Y., A. B. D.

Support and Acknowledgement Statement:
Our study does not receive financial support.
We would like to thank psychiatry resident Merve Tekmenler for her support in case management.
Conflict of Interest Statement:
The authors of the article have no conflict of interest declarations.
Ethics Committee Approval Information:
There is no ethics committee decision for the case presentation; informed consent was obtained from the patient.

References

1. Gerstner T, Buesing D, Longin E, et al. Valproic acid-induced encephalopathy—a review. *Epilepsia*. 2006;47(12):2069-2073.
2. Lheureux PE, Hantson P. Carnitine in the treatment of valproic acid-induced toxicity. *Clin Toxicol (Phila)*. 2005;43(8):857-863.
3. Wadzinski J, Franks R, Roane D, Bayard M. Valproate-associated hyperammonemic encephalopathy. *J Am Board Fam Med*. 2007;20(5):499-502.
4. Häussinger D. Hepatic encephalopathy. *J Hepatol*. 2006;43(1 Suppl):S10-S20.
5. Brusilow SW, Maestri NE. Urea cycle disorders: diagnosis, pathophysiology, and therapy. *Adv Pediatr*. 1996;43:127-170.
6. Kaplan PW. The EEG in metabolic encephalopathy and coma. *J Clin Neurophysiol*. 2004;21(5):307-318.
7. Butterworth RF. Pathophysiology of hepatic encephalopathy: a new look at ammonia. *Metab Brain Dis*. 2002;17(4):221-227.
8. Perrott J, Murphy NG, Zed PJ. L-carnitine for acute valproic acid overdose: a systematic review. *Ann Pharmacother*. 2010;44(7-8):1287-1293.
9. Carr RB, Shrewsbury K. Hyperammonemia due to valproic acid in the psychiatric setting. *Am J Psychiatry*. 2007;164(7):1020-1027.
10. Verrotti A, Trotta D, Salladini C, et al. Valproate-induced hyperammonemia. *Metab Brain Dis*. 2002;17(4):367-373.