Check for updates

European Journal of Inflammation

Original article

European Journal of Inflammation
2016, Vol. 14(1) 54–60
© The Author(s) 2016
Reprints and permissions:
sagepub.co.uk/journalsPermissions.nav
DOI: 10.1177/1721727X16636889
eji.sagepub.com
SAGE

The effect of infliximab on bone healing in osteoporotic rats

M Cenk Durmuşlar,[1] Akif Türer,[1] Umut Ballı,[2] Zehra Yılmaz,[3] Mehmet Emin Önger,[4] H Hamdi Çelik[5] and Alper Vatansever[5]

Abstract

Purpose: The aim of this study was to evaluate the effect of the infliximab on autogenous-mediated bone regeneration and resorption of autogenous graft in the ovariectomised rat model.

Materials and methods: Forty rats underwent ovariectomy and 6 weeks later the animals were randomly assigned to four groups. Critical size defects were created in each rat calvarium. In the control group (C), the flap was closed without any further action. In the only infliximab group (In), the flap was closed without any further action. After the operation, intravenous infliximab was injected. In the autogenous graft group (Ag), autogenous bone was applied in to the defect. In autogenous graft + infliximab group (Ag+In), autogenous graft was placed on the defect. After the operation, intravenous infliximab was injected. The animals were sacrificed at 4 weeks. Bone formation was assessed by micro-computed tomography (micro-CT) scans and stereological analysis.

Results: The mean new bone volume was the greatest in Ag+In group (1.76 ± 0.20), followed by the Ag group (1.51 ± 0.05) (statistically significant difference at $P < 0.05$). The lowest new bone was found in the control group (1.05 ± 0.09), however no difference was observed from the In group (1.14 ± 0.08) ($P > 0.05$). Besides there was a statistically significant difference between the Ag+In group (1.00 ± 0.05) and Ag group (0.74 ± 0.04) in terms of the graft volume ($P < 0.05$).

Conclusion: This study, despite its limitations, showed that infliximab has a beneficial effect for prevent graft resorption and bone regeneration in osteoporotic rats.

Keywords

autogenous graft, infliximab, osteoporotic rats

Date received: 30 November 2015; accepted: 10 February 2016

Introduction

Maxillofacial bone defects caused from tumours, infection or traumas require surgery. Various bone substitutes are used to restore bone defects; however, bone healing depends on the properties of the substitutes and the host bone.[1–5] Osteoporosis is a skeletal disorder that delays bone healing and reduces the quality of new bone formation.[1,3] Many studies have focused on fracture prevention and therapeutic management to enhance bone density during osteoporosis;[6,7] however, few studies have focused on osteoporotic bone regeneration in the presence of grafted biomaterials.[5]

[1]Department of Oral and Maxillofacial Surgery, Bülent Ecevit University Faculty of Dentistry, Zonguldak, Turkey
[2]Department of Periodontology, Bülent Ecevit University Faculty of Dentistry, Zonguldak, Turkey
[3]Department of Pharmacology, Harran University Faculty of Medicine, urfa, Turkey
[4]Department of Histology and Embriology, Faculty of Medicine, Ondokuz Mayıs University, samsun, Turkey
[5]Department of Anatomy, University Faculty of Medicine, Ankara, Turkey

Corresponding author:
Mustafa Cenk Durmuşlar, Bulent Ecevit Universitesi Dishekimligi Fakultesi, Agız Dis Cene Hastaliklari ve Cerrahisi Anabilim Dali, Kozlu, Zonguldak 67600, Turkey.
Email: cenkdurmuslar@hotmail.com



Figure 1. Critical size defect in rat cranium.

TNF-α is an important mediator in local erosive processes and systemic osteoporosis. It is an osteoclast-stimulating molecule that induces the receptor activator of nuclear factor kappa B ligand (RANK-L) production.[8,9] Agents that block TNF-α have been proposed to protect bone and cartilage by imparting a beneficial systemic effect on bone metabolism.[8,10] Infliximab, a human IgG1 TNF-α monoclonal antibody, is used for rheumatoid arthritis therapy, where it reduces TNF-α levels in the crevicular fluid in rheumatoid arthritis patients.[11] Infliximab also prevents bone resorption during periodontitis.[9,12] Here, we implemented an ovariectomised rat model to evaluate the effect of infliximab on bone regeneration and resorption after application of an autogenous graft.

Materials and methods

Surgical procedures

Eight-month-old female rats (n = 40) with an average weight of 250 g were ovariectomised and randomly assigned to four groups. Six weeks after the ovariectomies, the rats were anaesthetised with an intraperitoneal injection of 10 mg/kg ketamine HCl (Ketalar; Pfizer, Istanbul, Turkey) and a semilunar incision was made in the calvarium, allowing reflection of a full-thickness flap in the anterior direction. A 5-mm-diameter calvarial defect was created using a trephine bur on low speed under continuous saline irrigation (Figure 1). Later, the operation flaps were closed with 3/0 silk suture material. This study was approved by the Bulent Ecevit University Animal Care and Use Committee.

Experimental groups

Animals were assigned to four groups:

- Control group (C): the flap was closed without any further action.
- Infliximab group (In): the flap was closed without any further action. After the operation, 5 mg/kg of intravenous infliximab was administered.
- Autogenous graft group (Ag): the autogenous graft was ground using a bone grinder and applied to the defect. The flap was sutured using silk sutures.
- Autogenous graft + infliximab group (Ag+In): the autogenous graft was applied using the same method as with the Ag group, and after the operation, 5 mg/kg of intravenous infliximab was injected.

All animals survived during surgeries and the postsurgical period. There was no evidence of wound dehiscence, wound infection or abscess formation. All animals were sacrificed 4 weeks after the operation. Calvarias were removed and kept in formaldehyde prior to stereological examination and micro-computed tomography (micro-CT) analysis.

Micro-CT analysis

Samples were scanned using micro-CT (Skyscan 1174; Micro Photonics Inc., Allentown, PA, USA) with a spatial resolution of 15 μm, using 50 kV and 800 μA at a 0.7° rotation step for a total of 180°. Three-dimensional images were taken using NRECON software, and the data were evaluated using CTAn software. Only the volume of mineralised new bone, without graft materials, was calculated (Figure 2).

Stereological analysis

Prior to stereological analyses, samples were decalcified in formic acid (5%) for 21 days. Samples were then fixed in 10% formaldehyde, dehydrated in a graded alcohol series, and clarified in xylol for light microscopic examination. After dehydration, samples were embedded in fresh paraffin and cut using a microtome (Leica RM 2135; Leica Instruments, Nussloch, Germany). Paraffin blocks were cut serially to a thickness of 7 μm, and

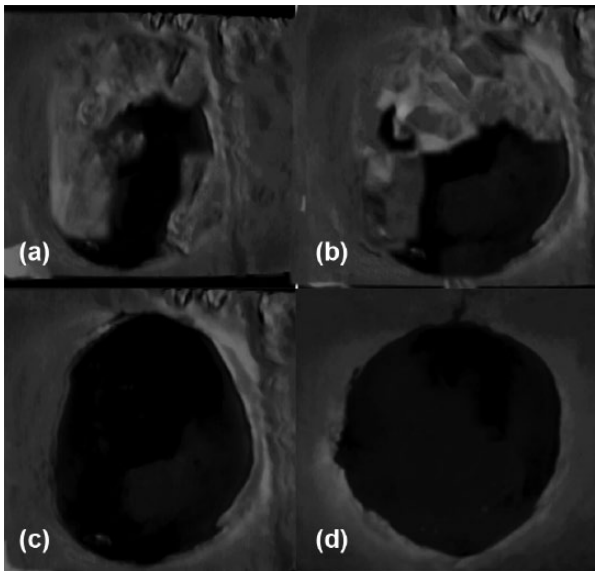

Figure 2. Micro-CT views of the defects. (a) Autogenous graft group (Ag) in the 4th week. (b) Autogenous graft + infliximab group (Ag+In) in the 4th week. (c) Infliximab group (In) in the 4th week. (d) The control group (C) in the 4th week.

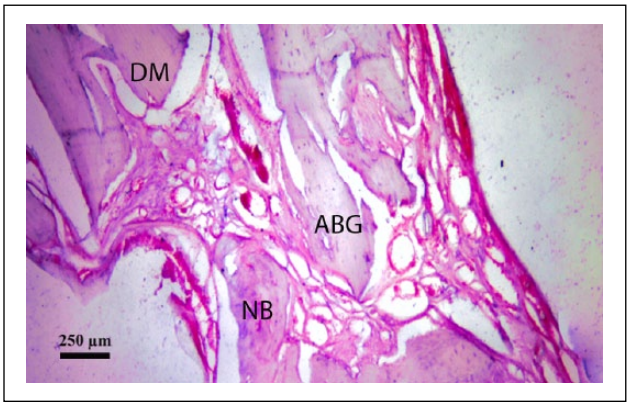

Figure 3. Histological view of defect region. Autogenous Bone Graft (ABG), Defect Margin (DM), New Bone (NB) (H&E, original magnification ×250).

every 20th section was selected for analysis. The first section was chosen at random and all sections were sampled in a random manner. Sections were stained with haematoxylin–eosin (H&E) and photographed using the stereology analysis system (Stereoinvestigator 9.0, Microbrightfield, Williston, VT, USA) with a light microscope (Leica M 4000 B, Germany) containing a digital colour camera (Microbrightfield, Williston, VT, USA).

To estimate the volume of new bone area (Vn; Figure 3), the unbiased Cavalieri method was applied using point-counting test grids. The point density of the point-counting test grids was designed to obtain an appropriate coefficient of error (CE). CEs and coefficients of variation (CVs) were estimated according to the formula of Gundersen and Jensen. The volume of each area was estimated with following formula:

$$\text{Volume} = t \times a/p \times \Sigma p$$

where 't' is section thickness, 'a/p' is the area of each point on the point counting grid, and '$\sum p$' is the total number of points hitting the area of interest.

Statistical analysis

The Shapiro–Wilk test was used to determine whether the data were normally distributed. Comparisons of the new bone, connective tissue and residual graft values were analysed using the Kruskal–Wallis non-parametric test, followed by post-hoc group comparisons with the Bonferroni-adjusted Mann–Whitney *U* test after normality of data had been failed. For the Bonferroni correction, $\alpha = 0.05/6 = 0.008$ was considered to be statistically significant. All tests were performed using statistical software (SPSS Inc., version 19.0, Chicago, IL, USA).

Results

Animals

All animals tolerated surgery well and survived the postsurgical period. Neither wound dehiscence nor wound infection nor abscess formation was observed at any surgical site.

Micro-CT and histomorphometric findings

New bone volume (mm^3) is shown in Figure 4. The mean new bone volume was the greatest in the Ag+In group (1.76 ± 0.20), followed by the Ag group (1.51 ± 0.05) (statistically significant difference at $P < 0.05$). The lowest new bone was found in the control group (1.05 ± 0.09), however no difference was observed from the In group (1.14 ± 0.08) ($P > 0.05$).

Micro-CT (%) is shown in Figure 5. The greatest new bone was found in the Ag+In group (15.12 ± 2.57), and a significant difference was observed

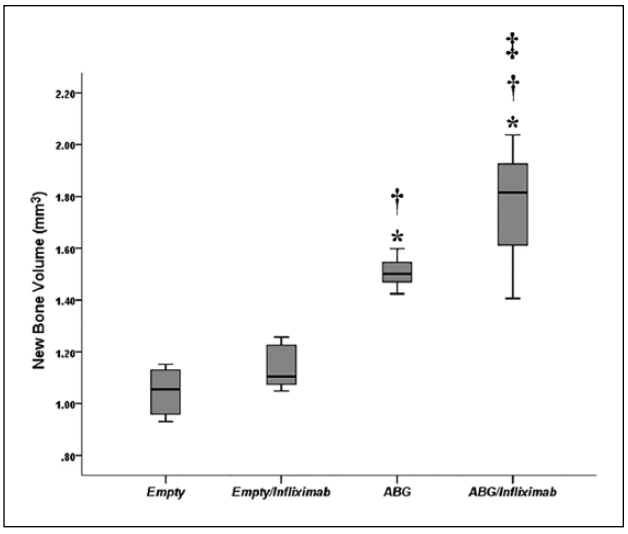

Figure 4. New bone volume (mm^3) in study groups.
*Statistically significant difference from the control group (Bonferroni-adjusted Mann–Whitney *U* test).
†Statistically significant difference from the In group (Bonferroni-adjusted Mann–Whitney *U* test).
‡Statistically significant difference from the Ag group (Bonferroni-adjusted Mann–Whitney *U* test).
Data are presented as box and whisker plots. The median value is indicated by the line within the box plot. The box extends from the 25th to the 75th percentiles. Whiskers extend to show the highest and lowest values.

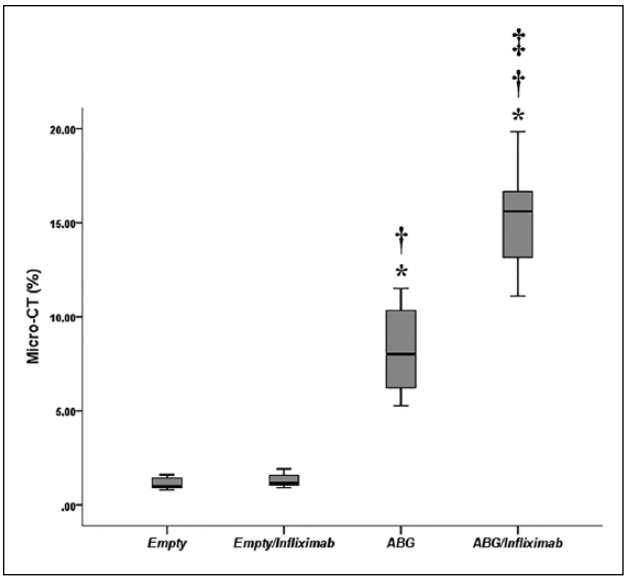

Figure 5. The percentage of new bone in micro-CT (%) in study groups.
*Statistically significant difference from the control group (Bonferroni-adjusted Mann–Whitney *U* test).
†Statistically significant difference from the In group (Bonferroni-adjusted Mann–Whitney *U* test).
‡Statistically significant difference from the Ag group (Bonferroni-adjusted Mann–Whitney *U* test).
Data are presented as box and whisker plots. The median value is indicated by the line within the box plot. The box extends from the 25th to the 75th percentiles. Whiskers extend to show the highest and lowest values.

from the Ag group (8.05 ± 2.25) (P <0.05). The lowest new bone was found in the control group (1.15 ± 0.31), however no difference was observed from the In group (1.30 ± 0.35) (P >0.05). There was a significant difference between the Ag groups and non-Ag groups (P <0.05).

The volume of connective tissue (mm^3) is shown in Figure 6. The mean connective tissue volume was observed to be the lowest in the control group (0.94 ± 0.09) and the highest in the Ag+In group (1.66 ± 0.07) (P <0.05). There was a statistically significant difference between the control group and the In group (1.22 ± 0.09) in terms of the volume of connective tissue (P <0.05), whereas no difference was observed between the Ag+In and Ag groups (1.54 ± 0.14) (P >0.05).

Residual graft volume is shown in Figure 7. There was a statistically significant difference between the Ag+In group (1.00 ± 0.05) and Ag group (0.74 ± 0.04) in terms of the graft volume (P <0.05).

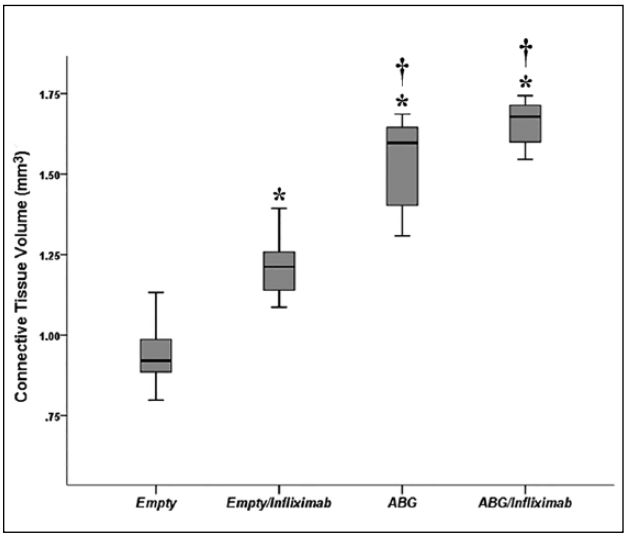

Figure 6. Connective tissue volume (mm^3) in study groups.
*Statistically significant difference from the control group (Bonferroni-adjusted Mann–Whitney *U* test).
†Statistically significant difference from the In group (Bonferroni-adjusted Mann–Whitney *U* test).
Data are presented as box and whisker plots. The median value is indicated by the line within the box plot. The box extends from the 25th to the 75th percentiles. Whiskers extend to show the highest and lowest values.

Histological evaluation

Histological analysis showed new bone formation in all groups. Neither inflammatory reaction nor

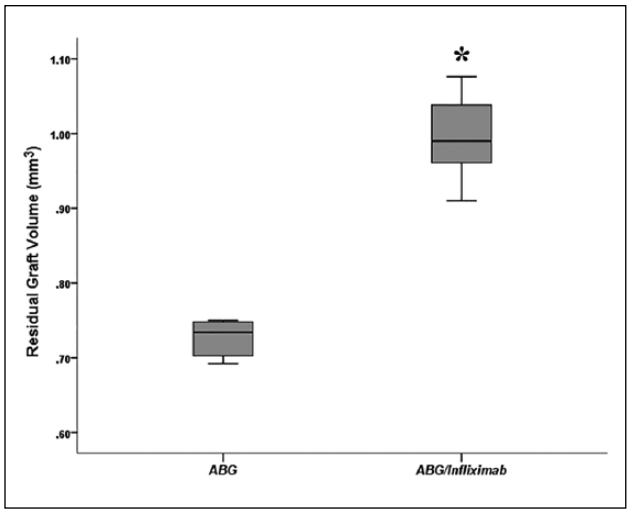

Figure 7. Residual graft volume (mm^3) in study groups.
*Statistically significant difference from the Ag group (Mann–Whitney *U* test).
Data are presented as box and whisker plots. The median value is indicated by the line within the box plot. The box extends from the 25th to the 75th percentiles. Whiskers extend to show the highest and lowest values.

secondary infection findings were observed at any surgical specimen. Fibrous connective tissue was mainly observed in the C and In groups. Centripetal (from the periphery toward the centre of defect new bone formation) was seen in all groups. No new bone formation was detected at the centre of the defect area in the C and In groups. Although there was new bone formation there was no significant difference between the C and In groups; more cellular collagenated connective tissue stroma was seen in the In group. The lowest new bone formation was found in the control group.

In the Ag and Ag+In groups, autogenous grafts were trapped by new bone and in some areas it reached to defect margins. In both groups using Ag, connective tissue was superior and irregular between new bone areas.

Discussion

Osteoporosis is a systemic illness characterised by inadequate bone formation and excessive bone resorption. Osteoporosis reduces bone volume and density in the maxilla and mandibula, and increases bone destruction around the teeth. However, the changes in osteoporotic bone, including the regenerative processes mediated by biomaterial implantation, have been only minimally evaluated.[1,4,5]

In this study, we evaluated the effect of infliximab on bone regeneration and resorption after application of an autogenous graft in an ovariectomised rat model. To our knowledge, this is the first study investigating such an effect. Stereological methods and micro-CT analyses were used to evaluate new bone and resorption of the autogenous graft.

Histological and pathological tissues are often examined in two dimensions using conventional methods;[13] however, Sterio[14] reported several modifications for estimating the quantity of structures in three-dimensional space. The estimation of microscopic parameters in three-dimensions increases the accuracy of morphological measurements.[13]

Biomaterial-mediated bone regeneration processes were impaired under osteoporotic conditions,[5,15–18] which indicated the negative impact of osteoporosis on bone graft healing. Oberg et al.[17] performed 5-mm-diameter defects in ovariectomised and healthy rabbit tibias, and grafted half of the cavities using allogeneic bone. After 8 weeks, histologic evaluations revealed no differences between the empty and grafted cavities. However, significantly less new bone was formed in the ovariectomised rabbits compared with the healthy animals. Kim et al.[18] created surgical defects in the calvarium of ovariectomised and non-ovariectomised rats and grafted defects with a mixture of tooth ash and plaster of Paris. The ovariectomised group had less bone formation compared with non-ovariectomised animals. In a similar ovariectomised rat model, Durao et al.[6] showed a decrease in biomaterial-mediated bone formation using microtomographic and histological analyses. They also observed impaired osteoblastic function in the regenerated bone of ovariectomised rats using gene expression analyses. The authors suggested these findings were consistent with impaired osteogenic processes in biomaterial-mediated bone healing in osteoporotic patients. Ribeiro et al.[16] created surgical defects in ovariectomised rat femurs and grafted defects with hydroxyapatite. In the ovariectomised group, without hormone replacement therapy, less newly formed bone was observed during histological analyses.

Surgical ovariectomies are commonly performed in osteoporotic rat models, and thus, were used in the present study. Rats were our preferred model as they closely resemble major clinical symptoms in humans when oestrogen is deficient.

Another reason for our preference of ovariectomised rats is because osteoporotic bone modifications are rapid.

TNF-α plays a dominant role in local bone resorption and systemic osteoporosis. It is an osteoclast-stimulating molecule that induces the receptor activator of nuclear factor kappa B ligand (RANK-L) production;[8,9] thus, agents that block TNF-α may protect bone and cartilage. Infliximab is an IgG monoclonal antibody that binds TNF-α, inhibiting its activity.[19–21] In this study, we used infliximab to prevent graft resorption and evaluated its effect on bone healing using an osteoporotic rat model. The mean new bone volume was greatest in the Ag+In group, and a statistical difference in graft volume was observed between the Ag+In and Ag groups.

Consistent with our results, TNF-α inhibition was also beneficial in other studies.[8] Kastelan et al.[22] showed that inhibition of TNF-α prevented bone resorption in ovariectomised mice. Moreover, postmenopausal women with osteoporosis have increased TNF-α levels. Goncalves et al.[10] reported that infliximab prevented bone resorption in a periodontitis model, while Timmen et al.[23] showed that infliximab inhibited TNF-α, which was otherwise harmful during chronic inflammation and fracture healing.

Consistent with previous studies, 5 mg/kg infliximab was used in this study. This dose of infliximab is effective at preventing inflammatory changes and bone loss. Gonçalves et al.[10] reported that lower doses of infliximab failed to prevent bone resorption.

In this study, we evaluated the effects of infliximab treatment using an osteoporotic rat model. Our results showed that infliximab prevented graft resorption and increased bone regeneration in osteoporotic rats. Additional studies are required for understanding the benefits and side effects of infliximab on bone regeneration in osteoporotic models.

Acknowledgements

Special thanks to our research assistants, Gamze Yayla and Burcu Delibaş, for performing stereological examinations.

Declaration of conflicting interests

The authors declared no potential conflicts of interest with respect to the research, authorship, and/or publication of this article.

Funding

This research received no specific grant from any funding agency in the public, commercial, or not-for-profit sectors.

References

1. Ji Y, Wang L, Watts DC et al. (2014) Controlled-release naringin nanoscaffold for osteoporotic bone healing. *Dental Materials* 30(11): 1263–1273.
2. Erdoğan O, Shafer DM, Taxel P et al. (2007) A review of the association between osteoporosis and alveolar ridge augmentation. *Oral Surgery, Oral Medicine, Oral Pathology, Oral Radiology and Endodontics* 104(6): 738.
3. Sener I, Bereket C, Kosker H et al. (2013) The effects of zoledronic acid on mandibular fracture healing in an osteoporotic model: A stereological study. *Journal of Craniofacial Surgery* 24(4): 1221–1224.
4. Ramalho-Ferreira G, Faverani LP, Prado FB et al. (2015) Raloxifene enhances peri-implant bone healing in osteoporotic rats. *International Journal of Oral and Maxillofacial Surgery* 44(6): 798–805.
5. Kearns AE and Kallmes DF (2008) Osteoporosis primer for the vertebroplasty practitioner: Expanding the focus beyond needles and cement. *American Journal of Neuroradiology* 29(10): 1816–1822.
6. Durão SF, Gomes PS, Colaço BJ et al. (2014) The biomaterial-mediated healing of critical size bone defects in the ovariectomised rat. *Osteoporosis International* 25(5): 1535–1545.
7. Khosla S, Westendorf JJ and Oursler MJ. (2008) Building bone to reverse osteoporosis and repair fractures. *Journal of Clinical Investigation* 118: 421–428.
8. Dominguez L, Scalisi R and Barbagallo M (2010) Therapeutic options in osteoporosis. *Acta Biomedica* 81 (Suppl. 1): 55–65.
9. Corrado A, Neve A, Marucci A et al. (2015) Combined effects of infliximab and methotrexate on rheumatoid arthritis osteoblastic cell metabolism. *Clinical and Experimental Medicine* 15(3): 277–283.
10. Gonçalves DC, Evangelista RC, da Silva RR et al. (2014) Infliximab attenuates inflammatory osteolysis in a model of periodontitis in Wistar rats. *Experimental Biology and Medicine* 239(4): 442–453.
11. Vis M, Havaardsholm EA, Haugeberg G et al. (2006) Evaluation of bone mineral density, bone metabolism, osteoprotegerin and receptor activator of the NFjB ligand serum levels during treatment with infliximab in patients with rheumatoid arthritis. *Annals of the Rheumatic Diseases* 65: 1495–1499.
12. Mayer Y, Balbir-Gurman A and Machtei EE (2009) Anti-tumor necrosis factor alpha therapy and periodontal parameters in patients with rheumatoid arthritis. *Journal of Periodontology* 80: 1414–1420.

13. Novaes RD, Penitente AR, Talvani A et al. (2012) Use of fluorescence in a modified disector method to estimate the number of myocytes in cardiac tissue. *Arquivos Brasileiros de Cardiologia* 98(3): 252–258.
14. Sterio DC (1984) The unbiased estimation of number and sizes of arbitrary particles using the disector. *Journal of Microscopy* 134 (2): 127–136.
15. Iwashita Y, Yamamuro T, Kasai R et al. (1992) Osteoconduction of bioceramics in normal and osteopenic rats: Comparison between bioactive and bioinert ceramics. *Journal of Applied Biomaterials* 3: 259–268.
16. Ribeiro D, Figueira L, Issa J et al. (2012) Study of the osteoconductive capacity of hydroxyapatite implanted into the femur of ovariectomised rats. *Microscopy Research and Technique* 75: 133–137.
17. Oberg S, Johansson C and Rosenquist JB (2003) Bone formation after implantation of autolysed antigen extracted allogeneic bone in ovariectomised rabbits. *International Journal of Oral and Maxillofacial Surgery* 32(6): 628–632.
18. Kim SY, Kim SG, Lim SC et al. (2004) Effects on bone formation in ovariectomised rats after implantation of tooth ash and plaster of Paris mixture. *Journal of Oral and Maxillofacial Surgery* 62(7): 852–857.
19. Zhang Z, Song C, Fu X et al. (2014) High-dose diosgenin reduces bone loss in ovariectomised rats via attenuation of the RANKL/OPG ratio. *International Journal of Molecular Sciences* 15(9): 17130–17147.
20. McMahon MS and Ueki Y (2008) Does anti-TNF-alpha have a role in the treatment of osteoporosis? *Bulletin of the NYU Hospital for Joint Diseases* 66(4): 280–281.
21. Ostrowska Z, Ziora K, Oświęcimska J et al. (2015) Selected pro-inflammatory cytokines, bone metabolism, osteoprotegerin, and receptor activator of nuclear factor-kB ligand in girls with anorexia nervosa. *Endokrynologia Polska* 66(4): 313–321.
22. Kastelan D, Kastelan M, Massari LP et al. (2006) Possible association of psoriasis and reduced bone mineral density due to increased TNF-alpha and IL-6 concentrations. *Medical Hypotheses* 67(6): 1403–1405.
23. Timmen M, Hidding H, Wieskötter B et al. (2014) Influence of anti-TNF-alpha antibody treatment on fracture healing under chronic inflammation. *BMC Musculoskeletal Disorders* 15: 184.

The English in this document has been checked by at least two professional editors, both native speakers of English. For a certificate, please see: http://www.textcheck.com/certificate/byhKWG