A Case of Parry-Romberg Syndrome: Examining the Efficacy of Lipofilling by Statistical Shape Analysis

Parry-Romberg Sendromu Olgusu: Yağ Enjeksiyonu Etkinliğinin İstatistiksel Şekil Analizi ile İncelenmesi

Emel BÜLBÜL BAŞKAN,[a]
İlker ERCAN,[b]
Senem T. ÖZDEMİR,[c]
Güven ÖZKAYA,[b]
Mediha YILMAZ,[a]
Yeşim ÖZGENEL,[d]
Hayriye SARICAOĞLU[a]

Departments of
[a]Dermatology,
[b]Biostatistics,
[c]Anatomy,
[d]Plastic and Reconstructive Surgery,
Uludağ University Faculty of Medicine, Bursa

Geliş Tarihi/*Received:* 21.10.2011
Kabul Tarihi/*Accepted:* 15.02.2012

Yazışma Adresi/*Correspondence:*
Emel BÜLBÜL BAŞKAN
Uludağ University Faculty of Medicine, Department of Dermatology, Bursa, TÜRKİYE/TURKEY
bbemel@uludag.edu.tr

ABSTRACT Parry-Romberg syndrome is an acquired progressive hemifacial atrophy characterized by the atrophy of subcutaneous fat and bone. The aim of this study was to demonstrate the degree of facial asymmetry before and after treatment with systemic azathioprine and autologous lipofilling. We presented a dramatic case of Parry-Romberg syndrome with central nervous system involvement that was treated with systemic azathioprine and autologous lipofilling. The statistical shape analysis was performed on anatomical landmarks to demonstrate the degree of facial asymmetry before and after therapy. On the face of the subject, 32 anthropometric landmarks on the anterior aspect of the face were defined. Thin-plate spline analysis was performed. Prior to the Thin-plate spline analysis, the right side of the photo was superimposed on the left side of the midsagittal plane and Bookstein coordinates were calculated. After systemic azathioprine and autologous lipofilling, analysis results were evaluated according to the references of the community. While the results were similar to the values of the healthy population in 64% (9/14) of the asymmetry regions, they were different in 29% (4/14). Facial atrophy seen after Parry-Romberg syndrome can include all tissue planes in different grades of severity. Several treatments have been developed to correct this deformity. Lipofilling was demonstrated to decrease the asymmetry to a degree close to the healthy population.

Key Words: Parry-Romberg syndrome; facial asymmetry; facial hemiatrophy

ÖZET Parry-Romberg sendromu, yüz yarımının cilt altı yağ ve kemik dokusunun atrofisi ile karakterize ilerleyici edinsel atrofisidir. Çalışmanın amacı, sistemik azatiyoprin ve otolog yağ enjeksiyonu tedavisinin öncesinde ve sonrasında yüz asimetrisinin derecesini ortaya koymaktır. Bu çalışmada sistemik azatiyoprin ve cilt altı otolog yağ enjeksiyonu yöntemi ile tedavi edilen santral sinir sistemi tutulumlu bir olgu sunulmuştur. Tedaviden önce ve sonra yüz asimetrisinin derecesi, anatomik mirengi noktalarına göre istatistiksel şekil analiziyle değerlendirildi. Olgunun yüzünün önden görünüşünde 32 antropometrik mirengi noktası işaretlendi ve ince levha eğrisi analizi gerçekleştirildi. İnce levha eğrisi analizi gerçekleştirilmeden önce fotoğrafın sağ tarafı, midsagittal düzlemde sol tarafın üzerine yerleştirildi ve Bookstein koordinatları hesaplandı. Analiz sonuçları sistemik azatiyoprin ve otolog yağ enjeksiyonu sonrası toplum referans değerleri dikkate alınarak değerlendirildi. Sonuçlar asimetrik alanın %64 (9/14)'ünde toplum değerlerine yakın bulunurken, %29'unda (4/14) toplum referans değerlerinden farklı bulundu. Parry-Romberg sendromu nedeniyle gelişen yüz atrofisi, bütün dokularda farklı derecelerde görülebilir. Bu deformasyonu düzeltmek amacıyla birçok tedavi geliştirilmiştir. Yağ enjeksiyonunun yüzdeki asimetriyi azaltarak sağlıklı popülasyonun derecesine yaklaştırdığı gösterilmiştir.

Anahtar Kelimeler: Parry-Romberg sendromu;yüz asimetrisi; fasiyal hemiatrofi

Turkiye Klinikleri J Med Sci 2013;33(1):284-9

doi: 10.5336/medsci.2011-27004

Copyright © 2013 by Türkiye Klinikleri

Parry-Romberg syndrome (PRS) is an acquired progressive hemifacial atrophy characterized by atrophy of subcutaneous fat and bone. Facial atrophy seen after PRS can include all tissue planes in different

grades of severity. Several treatments have been developed to correct this deformity. The aim of this study was to demonstrate the degree of facial asymmetry before and after treatment with systemic azathioprine and autologous lipofilling. Lipofilling is a method of tissue augmentation that was used by the end of the 19th century in reconstructive surgery and by the end of the 20th century in cosmetic surgery. Simple method of injection and achievement of satisfying results made the autologous fat injection one of the most preferred methods of cosmetic surgery in the course of time.[1]

Statistical shape analysis, a relatively new method for biological research, compares body forms by using specific landmarks determined by anatomical prominences.[2-7] Several procedures for obtaining such shape information from anatomical landmark data have been proposed.[8,9] In the recent years, studies have used craniofacial shape differences and asymmetry of the soft tissue of face using statistical shape analysis methods.[10]

We presented a severe case of PRS with central nervous system involvement whose volumetric corrections were analyzed with statistical shape analysis. To the best of our knowledge, localizations and degree of facial asymmetry in PRS before and after therapy with statistical shape analysis has never been reported before.

MATERIAL AND METHODS

REPORT

A-70-year-old women presented with right facial hemiatrophy and alopecia over the right

frontoparietal region (Figure 1a). She reported that the right side of her face had begun to shrink after her first delivery, at the second decade with concurrent dysphagia. Dermatologic examination revealed additional clinical features including a band of sclerotic skin on the right frontoparietal region with loss of hair, enopthalmus due to periorbital atrophy on the right side, five hyperpigmented macules over the upper back and tongue and uvula deviation to right. Neurologic examination revealed anisokoria but no motor deficit and cerebellar tests were normal. The patient was classified as severe PRS according to the classification of Inigo et al.[11]



FIGURE 1a: Right facial atrophy before autologous lipofilling.

Laboratory findings revealed that anti-nuclear (1/1000), Ribonucleoprotein (RNP) / Smith (Sm), and thyroid antibodies [anti-thyroid peroxidase (anti-TPO) 48.1 IU/ml, anti-thyroglobulin (anti-TG) 109.2 IU/ml] were positive. Erythrocyte sedimentation rate was moderately elevated (54 mm/h). Histopathological examinations were compatible with localized morfea and dermal and adnexial atrophy. Esophagography revealed achalasia. Magnetic resonance imaging (MRI) of the brain showed hyperintense lesions in the right temporal lobe, cortical and subcortical regions and atrophy of the right cerebellar hemisphere as well as atrophy of the right parotis gland, dermis, subcutis and temporal and frontal bones.

Azathioprine 100 mg/day was initated for neurologic involvement. Balloon dilatation was performed for achalasia. Since the facial atrophy was stabilized and the patient asked for correction, autologous lipofilling was performed by a plastic surgeon for the reconstruction of hemiatrophy.

The procedure was performed under general anesthesia. After harvesting the fat by liposuction from the inner aspect of the thigh bilaterally, 20 cc

was injected into the zygoma, 15 cc into the frontal and 40 cc into the cheek area. No postoperative complication developed except for a small reduction in the volume of the initial graft. The aesthetic result was pleasing.

The patient's photos were taken before and a few days after therapy. The statistical shape analysis was performed on anatomical landmarks to demonstrate the degree of facial asymmetry before and after therapy. The trial was run in accordance with the ethical standards of the Declaration of Helsinki. Informed consent was obtained from the patient.

STATISTICAL SHAPE ANALYSIS

Standard anthropometric landmarks were chosen and were marked on digital image taken before and after therapy using TPSDIG 2.04 software. Extreme care was taken to ensure that the best possible photograph was obtained with constant distance and patient positioning. On the face of the subject, 32 (8 midline landmarks, 12 right-sided landmarks, 12 left-sided landmarks) anthropometric landmarks were defined on the anterior aspect of the face. Midline landmarks were defined by the trichion, supraglabella, nasion, pronasale, labiale superior, stomion, labiale inferior, and gnathion.

The landmarks were located on the forehead (trichion; supraglabella; frontotemporale, frontozygomaticus), eyes (exocanthion; endocanthion; palpebrale inferior), lateral facial region (zygion; gonion), nose (nasion; pronasale; alare), lips and mouth (labiale superior; stomion; labiale inferior; crista philtre; cheilion), and chin (gnathion) (Table 1 and Figure 1b). Analysis of asymmetry then required identification of homologous landmarks on either side of the midsagittal plane of the face and deduction of their differences in a two dimensional plane.

Right to left morphologic deformation was analyzed on before and after photos. Thin-plate spline analysis (TPS) was performed with references of trichion (landmark no 13) and supraglabellar (landmark no14) coordinates, the least disease-affected coordinates of the face. Before TPS analysis, right side of the photo was superimposed on the left si-

TABLE 1: Descriptions of landmarks used in this study.

No	Name of landmark	Description of landmark
Midline landmarks used in this study		
13	trichion	Midpoint of the hairline
14	supraglabella	Most anterior point on midline
15	nasion	The midpoint of the nasofrontal suture
16	pronasale	The most protruded point of the nasal tip
17	labiale superior	The mid point of the vermilion border of the upper lip
18	stomion	The mid point of the labial fissure when the lips are closed naturally
19	labiale inferior	The mid point of the vermilion border of the lower lip.
20	gnathion	The lowest point in the midline on the lower border of the chin
Right and left side landmarks used in this study		
1, 21	frontal eminence	Centered on eye pupil, most anterior point of the forehead
2, 22	frontotemporale	The most medial point on the temporal crest of the frontal bone
3, 23	maxillofrontale	The anterior lacrimal crest of the maxilla at the frontomaxillary suture
4, 24	endocanthion	The inner corner of the eye fissure where the eyelids meet, not the caruncles (the red eminences at the medial angles of the eyes)
5, 25	palpebrale inferius	The lowest point in the middle of the margin of the lower eyelid
6, 26	exocanthion	The outer corner of the eye fissure where the eyelids meet
7, 27	frontozygomaticus	The most lateral point on the frontozygomatic suture
8, 28	zygion	The most lateral point on the zygomatic arch
9, 29	alare	The most lateral point on the nasal ala
10, 30	crista philtre	The point on the crest of the philtrum, the vertical groove in the median portion of the upper lip, just above the vermilion border
11, 31	cheilion	The outer corner of the mouth where the outer edges of the upper and lower vermilions meet
12, 32	gonion	The most lateral point at the angle of the mandible

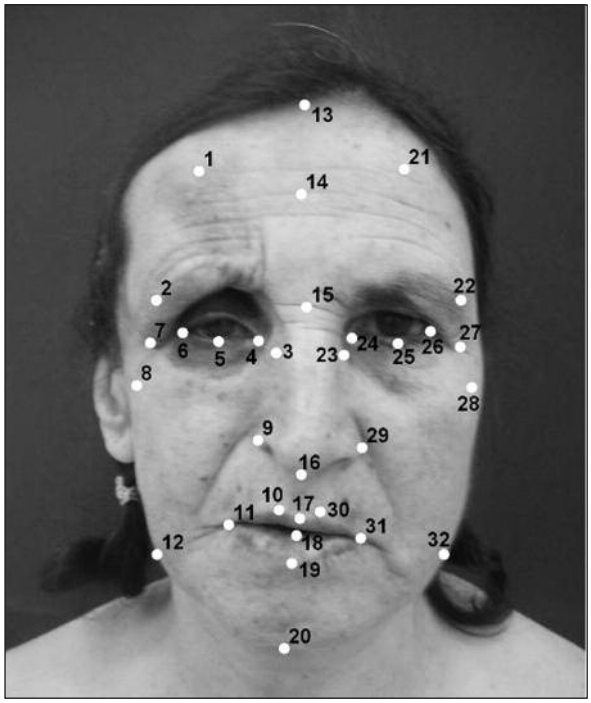

FIGURE 1b: Right facial atrophy after autologous lipofilling. Numbers refer to the landmarks used for statistical analysis.

de on the midsagittal plane and Bookstein coordinates were calculated.

In the second analysis, face was divided into three areas (upper, mid and lower) and asymmetry between the right and left side was calculated. For this analysis, pixel calculations of equivalent landmarks of both sides on the midsagittal plane was performed and left/right ratio was estimated.

RESULTS

Statistical shape analysis revealed that asymmetry of the face had improved after lipofilling almost to the degree of asymmetry in general population. For assessment of asymmetry, the ratios of distances between equivalent landmarks of right and left sides were calculated (Table 2).

Before lipofilling, right to left asymmetry was pronounced at all landmarks except for maxillafrontale (landmark no 3) and zygion (landmark no 8) (Figure 2a). After lipofilling, asymmetry decreased at the zygoma, cheek and frontal areas including the frontal eminence (landmark no 1), frontotemporal (landmark no 2), frontozygomaticus (landmark no 7), zygion (landmark no 8), alare (landmark no 9), crista chiltre (landmark no 10), chelion (landmark no 11) and gonion (landmark no 12). On the other hand, asymmetry increased at maxillofrontal (landmark no 3), endocanthion (landmark no 4), palpebrale inferius (landmark no 5), and exocanthion (landmark no 6) areas (Figure 2b).

DISCUSSION

Facial atrophy that develops after PRS can include all tissue planes in different grades of severity. Se-

TABLE 2: Ratio of equal landmarks on the left and right on midsagittal plane.

Landmark numbers		Before lipofiling	After lipofilling	Reference (Ercan et al.[10])
1	13	0.994	1.023	1.153
1	14	0.926	0.952	1.134
2	15	1.037	0.992	-
3	15	1.075	1.221	-
4	15	0.863	0.921	-
5	15	0.982	1.008	-
6	15	0.981	1.008	1.031
7	15	1.033	1.040	1.019
8	15	1.011	1.038	1.054
9	15	1.071	1.093	-
2	16	1.001	1.006	-
3	16	1.019	1.036	-
4	16	1.005	1.018	-
5	16	0.997	1.014	-
6	16	1.047	1.028	-
7	16	1.013	1.015	1.025
8	16	1.034	1.047	1.076
9	16	1.163	1.075	-
10	17	0.946	0.778	1.234
11	17	1.085	0.926	-
12	17	1.045	1.001	1.027
10	18	0.865	0.923	1.124
11	18	1.114	0.947	1.032
12	18	1.076	1.013	-
10	19	0.928	1.034	-
11	19	1.093	1.094	1.032
12	19	1.090	1.126	1.048
10	20	0.951	0.992	-
11	20	0.980	0.959	-
12	20	1.046	1.086	1.042

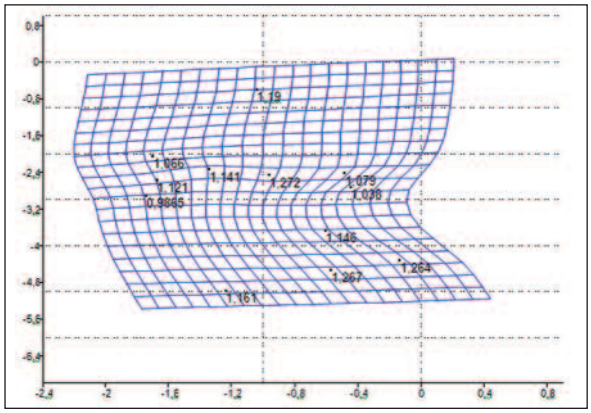

FIGURE 2a: Thin-plate spline demonstrating the average shape deformation from right side to the left side before lipofilling. Expansion factors at the landmarks are shown numerically (expansion factors larger than one).
(See for colored form http://tipbilimleri.turkiyeklinikleri.com/)

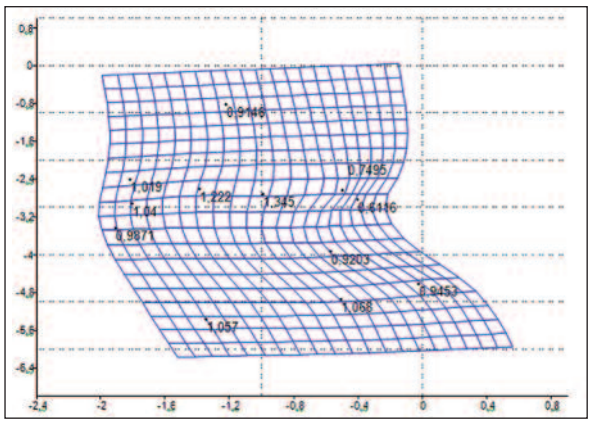

FIGURE 2b: Thin-plate spline demonstrating the average shape deformation from right side to the left side after lipofilling. Expansion factors at the landmarks are shown numerically (expansion factors larger than one).
(See for colored form http://tipbilimleri.turkiyeklinikleri.com/)

veral treatments have been developed to correct this deformity. Especially in severe cases, the best cosmetic results were obtained by pedicle or free flaps.[12] In mild to moderate cases, free autologous fat transplant has yielded successful results.[13] Lipofilling has multiple advantages including simplicity, lower cost and reduced morbidity. However, the major disadvantage of this technique is that multistage operations are required in order to achieve the ideal correction since approximately 20% of the initial fat transplanted is reabsorbed.[14] This may result with overcorrection to overcome this problem. Another disadvantage of lipofiling is the necessity of repeated episodes to maintain the correction due to the absorption of fat. However, the advantages and disadvantages of lipofilling as well as the long-term results are beyond the scope of this study, thus they have not been discussed in detail.

Standard photographic techniques are subject to variations and insufficient to assess the efficacy of facial volume augmentation. Thus, three dimensional imaging techniques have been presented in the recent years.[15] However, currently available systems do not meet the "fast, easy and cheap" criteria for an ideal imaging system to be used in routine clinical facial volume augmentation practice.[16] On the other hand, statistical shape analysis performed on the standardized digital photographic images taken from the constant distance with the same patient positioning and camera is a fast and cheaper method to demonstrate the asymmetry.

The statistical shape analysis has recently become more important in the medical and biological sciences. Most of the studies in medicine are related with the examination of geometrical properties of an organ or organism.[17] In our case, statistical shape analysis revealed remarkable asymmetry before therapy and the asymmetry was dramatically different from the results of a study by Ercan et al. investigating the healthy Turkish population.[10] The efficiency of treatment was also demonstrated in detail by statistical shape analysis. Lipofilling was shown to decrease the asymmetry to a degree close to that seen in the healthy population. After systemic azathioprine and autologous lipofilling, analysis results were evaluated according to the study by Ercan et al. while the results were similar to the values of the healthy population in 64% (9/14) of the asymmetry areas, 29% (4/14) were different.[10] The increase in the asymmetry in some landmarks is possibly due to the overcorrection of the zygoma and the cheek area.

To the best of our knowledge, this is the first case of PRS that was evaluated with statistical shape analysis to demonstrate facial asymmetry and the efficacy of treatment.

CONCLUSION

Facial atrophy seen after PRS can include all tissue planes in different grades of severity. Several treatments have been developed to correct this deformity. Lipofilling decreased the asymmetry to a degree close to that in the healthy population.

REFERENCES

1. Gökalp HC, Aksakal AB. [Autologous fat injection]. Turkiye Klinikleri J Cosm Dermatol-Special Topics 2009;2(2):36-9.
2. Lele S, Richtsmeier JT. Euclidean distance matrix analysis: a coordinate-free approach for comparing biological shapes using landmark data. Am J Phys Anthropol 1991;86(3):415-27.
3. Ozdemir ST, Ercan I, Ozkaya G, Cankur NS, Erdal YS. Geometric morphometric study and cluster analysis of late Byzantine and modern human crania. Coll Antropol 2010; 34(2):493-9.
4. Ferrario VF, Sforza C, Miani A Jr, Serrao G. A three-dimensional evaluation of human facial asymmetry. J Anat 1995;186(Pt 1):103-10.
5. Ozdemir ST, Ercan I, Sevinc O, Guney I, Ocakoglu G, Aslan E, et al. Statistical shape analysis of differences in the shape of the corpus callosum between genders. Anat Rec (Hoboken) 2007;290(7):825-30.
6. Hennessy RJ, Lane A, Kinsella A, Larkin C, O'Callaghan E, Waddington JL. 3D morphometrics of craniofacial dysmorphology reveals sex-specific asymmetries in schizophrenia. Schizophr Res 2004;67(2-3):261-8.
7. Hennessy RJ, McLearie S, Kinsella A, Waddington JL. Facial shape and asymmetry by three-dimensional laser surface scanning covary with cognition in a sexually dimorphic manner. J Neuropsychiatry Clin Neurosci 2006;18(1):73-80.
8. Richtsmeier JT, Cheverud JM, Lele S. Advances in anthropological morphometrics. Annu Rev Anthropol 1992;21:283-305.
9. Richtsmeier JT, DeLeon VB, Lele SR. The promise of geometric morphometrics. Am J Phys Anthropol 2002;(Suppl 35):63-91.
10. Ercan I, Ozdemir ST, Etoz A, Sigirli D, Tubbs RS, Loukas M, et al. Facial asymmetry in young healthy subjects evaluated by statistical shape analysis. J Anat 2008;213(6):663-9.
11. Iñigo F, Rojo P, Ysunza A. Aesthetic treatment of Romberg's disease: experience with 35 cases. Br J Plast Surg 1993;46(3):194-200.
12. Longaker MT, Siebert JW. Microvascular free-flap correction of severe hemifacial atrophy. Plast Reconstr Surg 1995;96(4):800-9.
13. Moscona R, Ullman Y, Har-Shai Y, Hirshowitz B. Free-fat injections for the correction of hemifacial atrophy. Plast Reconstr Surg 1989; 84(3):501-7; discussion 508-9.
14. Niechajev I, Sevćuk O. Long-term results of fat transplantation: clinical and histologic studies. Plast Reconstr Surg 1994;94(3):496-506.
15. Hoehnke C, Eder M, Papadopulos NA, Zimmermann A, Brockmann G, Biemer E, et al. Minimal invasive reconstruction of posttraumatic hemi facial atrophy by 3-D computer-assisted lipofilling. J Plast Reconstr Aesthet Surg 2007;60(10):1138-44.
16. Goldman MP, Skover GR, Payonk GS. Three-dimensional imaging techniques in the assessment of facial volume augmentation. J Drugs Dermatol 2009;8(12):1113-9.
17. Ercan İ, Ocakoğlu G, Sığırlı D, Özkaya G. [Statistical shape analysis and usage in medical sciences]. Turkiye Klinikleri J Biostat 2012;4(1):27-35.