Kafkas Universitesi Veteriner Fakultesi Dergisi
Journal Home-Page: http://vetdergikafkas.org
E-ISSN: 1309-2251

Kafkas Univ Vet Fak Derg
XX (X): X-X, XXXX
DOI: 10.9775/kvfd.2022.28744

ARTICLE IN PRESS

RESEARCH ARTICLE

Comparison of the Effects of Ketamine-Diazepam, Tiletamine-Zolazepam and Propofol Infusion Anesthesia in Rabbits

Ayse TOPAL [1] Nihal Yasar GUL SATAR [1] Ozge ATES [1 (*)] Elyesa Melih UCKAN [1]
Ozkan YAVAS [2] Ibrahim Taci CANGUL [2]

[1] Bursa Uludag University, Faculty of Veterinary Medicine, Department of Surgery, TR-16059 Bursa - TÜRKİYE

[2] Bursa Uludag University, Faculty of Veterinary Medicine, Department of Pathology, TR-16059 Bursa - TÜRKİYE

ORCIDs: A.T. 0000-0003-1882-4545; N.Y.G.S. 0000-0002-3505-3394; O.A. 0000-0003-0953-7923; E.M.U. 0000-0002-9587-9032; O.Y. 0000-0001-9811-9920; I.T.C. 0000-0003-0537-2113

Article ID: KVFD-2022-28744 Received: 08.11.2022 Accepted: 13.02.2023 Published Online: 14.02.2023

Abstract: In this study we evaluated the anesthetic effects of ketamine-diazepam (K-D), tiletamine zolazepam (T-Z), and propofol (P) infusion for one h in rabbits, and also the impact of these anesthetics on physiological and biochemical parameters, and the tissue structure of the liver, kidney, and lungs. 18 New Zealand white rabbits were allocated to three administration groups. All groups were premedicated with xylazine. For induction, ketamine and diazepam were administered intravenously in group K-D, tiletamine-zolazepam combination was administered in group T-Z, and propofol was administered in group P. After induction, infusion anesthesia was continued for one h by intravenously ketamine and diazepam in group K-D, tiletamine-zolazepam combination in group T-Z, and propofol in group P. The respiratory rate significantly decreased in the P group at 30, 45, and 60 min compared to the initial values ($P<0.05$). End-tidal CO_2 significantly increased in the P group at 30, 45, and 60 min compared to the initial values ($P<0.05$). All physiological and serum biochemical parameters were within the reference ranges. Infusions resulted in varying degrees of degenerative changes in the kidney, lung, and liver, but these changes did not affect the anesthesia status or biochemical parameters. We suggest that K-D, T-Z, and P can be applied safely as an infusion for one h anesthesia of rabbits as an alternative to traditional anesthesia regimens.

Keywords: *Infusion anesthesia, Ketamine-diazepam, Tiletamine-zolazepam, Propofol, Rabbit*

Tavşanlarda İnfüzyon Tekniği ile Ketamine-Diazepam, Tiletamine-Zolazepam ve Propofol Anestezi Uygulamalarının Etkilerinin Karşılaştırılması

Öz: Bu çalışmada tavşanlarda bir saat süreyle uygulanan ketamin-diazepam (K-D), tiletamin zolazepam (T-Z) ve propofol (P) infüzyonunun anestezik etkilerinin yanı sıra bu anesteziklerin karaciğer, böbrek ve akciğer dokularının üzerindeki etkilerini fizyolojik ve biyokimyasal parametreler yönünden değerlendirdik. 18 adet Yeni Zelenda tavşanı rastgele üç gruba ayrıldı. Tüm gruplarda, sedasyon için xylazine HCl, kas içi uygulandı. İndüksiyon için intravenöz olarak K-D grubuna ketamin-diazepam kombinasyonu, T-Z grubuna tiletamin-zolazepam kombinasyonu, P grubuna ise propofol uygulandı. İndüksiyondan sonra, intravenöz olarak K-D grubunda ketamin ve diazepam, T-Z grubunda tiletamin-zolazepam kombinasyonu ve P grubunda propofol uygulanarak infüzyon anestezisine bir saat boyunca devam edildi. Solunum hızı P grubunda başlangıç değerlerine göre 30., 45. ve 60. dakikada anlamlı olarak azaldığı görüldü ($P<0.05$). End-tidal CO_2, P grubunda başlangıç değerlerine göre 30., 45. ve 60. dakikada artış gösterdi ($P<0.05$). Her üç grupta da bir saatlik infüzyon süresinden sonra tüm fizyolojik ve serum biyokimyasal parametreleri referans aralıklarındaydı. İnfüzyonlar böbrek, akciğer ve karaciğerde değişen derecelerde dejeneratif değişikliklere neden oldu, ancak bu değişiklikler anestezi durumunu veya biyokimyasal parametreleri etkilemedi. Geleneksel anestezi protokollerine alternatif olarak tavşanların bir saatlik anestezisi için infüzyon olarak K-D, T-Z ve P' nin güvenle uygulanabileceğini öneriyoruz.

Anahtar sözcükler*: İnfüzyon anestezisi, Ketamin-diazepam, Tiletamin-zolazepam, Propofol, Tavşan*

How to cite this article?

Topal A, Gul Satar NY, Ates O, Uckan EM, Yavas O, Cangul IT: Comparison of the effects of ketamine-diazepam, tiletamine-zolazepam and propofol infusion anesthesia in rabbits. *Kafkas Univ Vet Fak Derg,* 2023 (*Article in Press*).
DOI: 10.9775/kvfd.2022.28744

(*) Corresponding Author

Phone: +90 539 256 7931 Fax: +90 224 294 1202
E-mail. ozgepamukcular@gmail.com (O. Ates)

This article is licensed under a Creative Commons Attribution-NonCommercial 4.0 International License (CC BY-NC 4.0)

Introduction

Anesthesia is required for many animal experiments and is often provided by the injectable anesthetics such as ketamine, tiletamine, or propofol. These agents are also used for the anesthesia of rabbits [1]. Nevertheless, the effects of administering these drugs as infusions in rabbits remain unclear.

Potential intra- and postoperative mortality have been observed with various anesthetic drugs and therefore developing safe and effective anesthesia methods has often been difficult in rabbits. Rabbit anesthesia has always been considered a high-risk procedure, however, when done properly, the risks are low and do not outweigh the benefits. Rabbits are common companion animals widely used in experimental surgeries and biomedical research [2].

Ketamine and xylazine are two widely used anesthetics. Ketamine, a dissociative anesthetic, produces a state of cataleptic sedation and is usually administered in combination with xylazine or diazepam for inducing surgical anesthesia in rabbits [3-5]. Animals have been successfully immobilized with ketamine hydrochloride and sedative drugs. Inadequate muscle relaxation, convulsions, and prolonged recovery periods are the most common side effects of these drugs in animals. Diazepam is frequently used in anesthesia due to its muscle relaxant effect. When this positive effect is used together, it is beneficial to eliminate the cataleptic effects of ketamine [6-8].

Tiletamine and zolazepam have dissociative anesthetic and tranquilizing properties, respectively. Tiletamine-zolazepam has been used alone or in combination with other anesthetic agents in rabbits. Tiletamine does not relax the muscles or affect the cranial nerve and spinal reflexes, however the combination with zolazepam results in muscle relaxation [6]. This combination is commonly used as part of the anesthetic management of domestic animals. But, tiletamine is not an anesthetic substance with an antidote such as ketamine [9,10].

Propofol is a lipophilic anesthetic used widely for the induction and maintenance of anesthesia in humans and animals. It has acquired worldwide acceptance because of its rapid onset, short duration of action and clinical effect, and quality and rate of recovery. Its pharmacokinetics in most species makes it the preferred agent for induction and continuous infusion. It can maintain stable anesthesia for prolonged periods and the recovery is rapid [11,12].

In veterinary medicine, there is no alternative method to the intramuscular dissociative anesthesia for medium-term anesthesia (45 min-1 h) in rabbits under field conditions. The most significant disadvantage of dissociative anesthetics is that they do not have an antidote for use when complications occur. During monitorization of the infusion anesthesia, when deep anesthesia appears reducing the dose of anesthetic will prevent complications [13].

This study compares the anesthetic effects of intravenous infusion of ketamine-diazepam, tiletamine-zolazepam, and propofol for one h to create medium-term anesthesia in rabbits. We also investigated the effects of these anesthetics on the physiological, hepatic and renal biochemical parameters, and the histology of the liver, kidney, and lungs.

Materials and Methods

Ethical Statement

The study was started after the approval of the Ethics Committee on Animal Research of Bursa Uludag University (Approval No: 2021-03-01)

Animals

In this study we applied three anesthesia protocols on 18 clinically healthy male adolescent New Zealand white rabbits weighing 2.30-2.90 kg. The rabbits were single-housed in cages for at least 14 days for acclimatization before the experiments and were given commercial pellet food (Purina®) and water *ad libitum*. Before initiating the experiments, the animals were fasted for 12 h and water was removed 2 h in advance. The rabbits were randomly assigned to one of the three groups: Ketamine-diazepam (K-D), tiletamine-zolazepam (T-Z), and propofol (P) with six rabbits in each group.

Anesthesia and Monitorization Period

On the day of the experiment, rabbits were weighed and transferred from the housing room to the operating room using a covered pet carrier. The catheters (Vasofix®, 24-gauge, B. Braun, Istanbul, Turkey) were applied to the lateral ear veins for taking blood samples and for intravenous infusion administration. Rabbits were immobilized in sternal recumbent position, supplied with blow-by-nose oxygen, and sedated with xylazine (5 mg/kg IM, Rompun®, Bayer, Leverkusen, Germany) injected into the longissimus muscle. The following indicators determined sedation: absence of pedal withdrawal reflex in response to a toe pinch, stable reduced frequency of respiration (from more than 150 breaths per min to 30-60 evenly paced breaths per min), reduction of smooth muscle tone, and loss of righting reflex when placed in a lateral recumbent position. Once sedation was confirmed, rabbits were transferred to lateral position on the pad with a heating feature to maintain body temperature. One of the catheters was used for the anesthetic infusion when animals were completely sedated. The other catheter was used to provide warmed 0.9% sodium chloride at a dose of 10 mL/kg/h during anesthesia. First blood samples for the measurement of enzyme levels were obtained before infusion. Blood was placed into

heparinized tubes and centrifuged (Minifuge RF, Heraeus, Hannover, Germany) at 1200 g at 4°C for 20 min. Plasma was separated and stored frozen at -20°C until assayed. The second blood sample was taken with a similar procedure after the termination of infusion anesthesia.

For induction, 10 mg/kg ketamine (Alfamine®, Alfasan, Woerden, The Netherlands) and 0.25 mg/kg diazepam (Diazem®, Deva, Istanbul, Turkey) were administered intravenously in group K-D, 10 mg/kg tiletamine-zolazepam (Zoletil®, I.E. Ulagay, Istanbul, Turkey) combination was administered in group T-Z, and 10 mg/kg propofol (Propofol®, Fresenius Kabi, Austria) was administered in group P to achieve induction. All rabbits were then intubated via the orotracheal route with a size 2.5 cuffed endotracheal tube (Bicakcilar, Istanbul, Turkey) after the disappearance of the swallowing reflex by using the premature blade. After intubation, the animals were connected to the anesthesia device (Espire®, General Electric, Boston, MA, USA), and only oxygen ventilation was provided. After that, the infusion of the anesthetic substance was started by an infusion pump (Infusomat® Space - B. Braun Medical Inc, Melsunger, Germany). The infusion pump was operated for one h to administer the anesthetics determined for each group. For infusion administration, 25-30 mg/kg/h ketamine and 2.5-3.0 mg/kg/h diazepam were administered intravenously in group K-D, 25-30 mg/kg/h tiletamine-zolazepam combination was administered in group T-Z, and 30-50 mg/kg/h propofol was administered in group P for one h. Separate syringe infusion pumps were used for each drug for the suitable dose adjustment.

Monitoring devices were attached after induction, but before the infusion of anesthesia. The end-tidal CO_2 collector of the monitor (Cardiocap 5®, Datex-Ohmeda, Helsinki, Finland) was placed between the endotracheal tube and the anesthesia device's Y pipe. Then, the end-tidal CO_2 value was measured. At the same time, oxygen saturation (SpO_2) probe of the monitor was placed on the rabbit's tongue, and the saturation value was measured. Heart rate was determined from a lead II ECG recording by ECG electrodes (3M®, Istanbul, Turkey). Electrodes were placed on the skin on the medial aspect of the rabbits' upper forelegs and left hind leg. The respiratory rate was recorded along with the end-tidal CO_2 value. A rectal thermometer measured body temperature. Heart rate, respiration rate, SpO_2, and end-tidal CO_2 were recorded every 15 min using the monitor during anesthesia.

The depth of anesthesia was monitored utilizing pedal withdrawal, ear pinch, palpebral, and corneal reflexes. When assessing these reflexes, any movement was considered a positive response. A desired surgical plane of anesthesia was determined by the absence of a corneal or laryngeal response under maintenance of independent diaphragmatic breathing.

The anesthetic drug infusion was terminated after one h. After the infusion was completed, 1 mL of blood sample was taken for blood serum analysis. The levels of BUN, creatinine, AST, and ALT were determined from serum samples. Euthanasia was established by rapid intravenous administration of six times the induction dose of the drugs administered in each group.

Histopathological Examination

After euthanasia, tissue samples from the liver, kidneys, and lungs were taken into neutral, buffered formalin from all rabbits for histopathological examination. After routine tissue processing, 4 µm sections were cut and stained with hematoxylin&eosin. Four randomly selected areas were examined in each section under x400 magnification. Livers were examined for hepatocellular degeneration, and the presence of sinusoidal or portal inflammatory cell infiltrations. Kidneys were evaluated for tubular degeneration and inflammatory cell infiltrates. The lung tissues were examined for hyperemia, intraalveolar edema and hemorrhages, presence of inflammatory cells, and atelectasis. All parameters were scored as 1: mild, 2: moderate, and 3: severe. Other significant findings in the organs were also noted.

Statistical Analysis

Data for plasma BUN, creatinine, ALT, AST concentrations, and heart and respiratory rates, end-tidal CO_2, SpO_2 levels were analyzed using a one-way analysis of variance (ANOVA) and then Tukey's HSD post hoc test for equal variences with repeated measures in each group to assess changes with time, followed by Dunnett's *t*-test when a significant difference was indicated. Scores of the histopathological changes were analyzed using ANOVA. Differences were considered significant when $P<0.05$. A statistical software was used for the calculations (SPSS v22.0 Statistical Software, IBM Corp, CA, USA).

Results

All anesthetized animals survived the one-h infusion anesthesia. In each group, unconsciousness occurred in a brief time (42±8 sec [mean±SD]) with intravenous induction doses. No additional doses were needed in any group for induction.

Physiological Parameters During Infusion

The mean heart rate (beats per min) was lower in the T-Z group at the beginning of the infusion period than in the K-D group and in the P group. The heart rate increased slightly until the 30th min and returned to the initial value at the 60th min in the K-D group, whereas a slight decrease was observed over time in other groups ($P>0.05$). In any of the groups, the changes in heart rate over time could not be statistically substantiated ($P>0.05$) *(Table 1)*.

The respiratory rate significantly decreased in the P group at 30, 45, and 60 min compared to the initial values ($P<0.05$); the most significant decrease being observed at 60 min. There was no significant difference in the respiratory rates during the infusion period in the K-D and T-Z groups *(Table 1)*.

End-tidal CO_2 significantly increased in the P group at 30, 45, and 60 min compared to the initial values ($P<0.05$). There was no significant difference in oxygen saturation (SpO_2) during the infusion periods in any of the anesthesia groups ($P>0.05$) *(Table 2)*.

Reflexes Monitored

Anesthesia evaluation was based on reflex examinations without surgical intervention. Pedal withdrawal, ear pinch, and palpebral reflexes were abolished entirely in all groups. When a slight presence of the corneal reflex was observed, the infusion doses of the anesthetics was increased to their upper limit, maintaining the depth of anesthesia to the desired level.

Body Temperature

No significant changes were observed and the body temperature remained between 37.8-39.4°C in all rabbits.

Biochemical Parameters

The results of the plasma biochemical parameters are shown in *Table 3*. The hematological findings were within the reference values in all groups ($P>0.05$).

Table 1. *Heart rate and respiratory rate at various times in the ketamine-diazepam, tiletamine-zolazepam, and propofol groups during infusion periods **

Time (min)	Heart Rate (beats per min)			Respiratory Rate (breaths per min)		
	K-D (n=6)	T-Z (n=6)	P (n=6)	K-D (n=6)	T-Z (n=6)	P (n=6)
0	171.17±15.33	149.17±20.63	189.33±6.90	41.17±4.28	42.33±3.63	48.67±1.45[a]
15	173.17±13.73	145.00±19.01	183.33±7.98	40.33±4.84	43.33±5.58	48.67±2.33[a]
30	183.17±11.60	135.17±16.26	173.83±8.80	43.17±4.19	40.17±1.74	41.17±1.89[a,b]
45	179.17±6.83	126.67±10.43	172.17±5.91	40.33±2.74	39.17±2.22	42.17±2.22[a,b]
60	168.50±9.58	120.17±9.80	169.50±5.43	41.00±4.90	39.00±2.82	37.83±2.25[b]

** Data presented as mean ± SEM. Different superscripts within a column indicate a significant difference among the anesthesia groups ($P<0.05$).* ***K-D:*** *ketamine-diazepam,* ***T-Z:*** *tiletamine-zolazepam,* ***P:*** *propofol*

Table 2. *End-tidal CO_2 and SpO_2 (saturation) at various times in the ketamine-diazepam, tiletamine-zolazepam, and propofol groups during infusion periods**

Time (min)	End-Tidal CO_2 (mmHg)			SpO_2		
	K-D (n=6)	T-Z (n=6)	P (n=6)	K-D (n=6)	T-Z (n=6)	P (n=6)
0	25.67±4.00	26.67±2.30	27.50±1.48[a,b]	96.17±1.01	97.50±1.72	91.16±1.25
15	24.33±4.35	25.50±2.88	25.50±1.43[a]	96.00±1.34	93.33±3.32	91.33±1.56
30	25.83±3.56	24.17±4.12	31.83±1.56[b,c]	93.00±2.51	94.50±2.08	90.83±1.51
45	28.17±3.56	26.00±4.59	35.00±1.61[c]	95.17±1.40	95.67±2.39	93.67±1.05
60	30.50±4.25	25.50±5.30	36.33±1.80[c]	94.00±2.06	96.50±2.01	94.50±1.72

** Data presented as mean ± SEM. Different superscripts within a column indicate a significant difference among the anesthesia groups ($P<0.05$).* ***K-D:*** *ketamine-diazepam,* ***T-Z:*** *tiletamine-zolazepam,* ***P:*** *propofol*

Table 3. *Plasma ALT, AST, BUN, CRE concentrations, and BUN/CRE ratio in the ketamine-diazepam, tiletamine-zolazepam, and propofol groups before and after the infusion period**

Group/Time (n=6)		ALT (IU/L)	AST (IU/L)	BUN (mg/dL)	CRE (mg/dL)	BUN/CRE	Refereence Range ALT/AST/BUN/CRE
K-D	0 min	29.67±1.65	27.0±1.12	16.61± 1.29	0.84±0.04	19.80±1.32	(10-27)/(9-34)/(12-22)/(0.8-2.6) [14,15]
	60 min	25.03±1.59	28.17±1.72	16.40± 1.35	0.76±0.02	21.13±1.35	(10-27)/(9-34)/(12-22)/(0.8-2.6) [14,15]
T-Z	0 min	17.67±1.67	31.33±3.92	18.31± 1.86	0.71±0.12	33.35±10.39	(10-27)/(9-34)/(12-22)/(0.8-2.6) [14,15]
	60 min	17.50±4.10	32.17±3.30	18.78± 2.15	0.86±0.11	22.75±2.54	(10-27)/(9-34)/(12-22)/(0.8-2.6) [14,15]
P	0 min	36.33±3.29	20.13±2.32	20.13± 2.32	0.89±0.03	22.48±1.99	(10-27)/(9-34)/(12-22)/(0.8-2.6) [14,15]
	60 min	33.0±3.26	21.35±2.50	21.35± 2.50	0.82±0.04	25.38±2.28	(10-27)/(9-34)/(12-22)/(0.8-2.6) [14,15]

** Data presented as mean ± SEM. A column without superscripts indicates no significant difference among the anesthesia groups.* ***K-D:*** *ketamine-diazepam,* ***T-Z:*** *tiletamine-zolazepam,* ***P:*** *propofol,* ***ALT:*** *alanine aminotransferase,* ***AST:*** *aspartate aminotransferase,* ***BUN:*** *blood urea nitrogen,* ***CRE:*** *creatinine*

Histopathological Findings

Histopathology scores and the results of statistical analysis are shown in *Table 4*. Briefly;

Kidney: In all groups, varying degrees of vacuolar degeneration in the tubules and inflammatory cell infiltrates in the intertubular regions were observed.

Table 4. *Scores (mean ± SEM) and the comparison of the histopathological changes in the kidney, lung, and liver after the administration of ketamine-diazepam, tiletamine-zolazepam, and propofol*

Group (n=6)	Liver			Kidney		Lung			
	Vacuolar Degeneration	Sinusoidal Infiltration	Infiltration in Portal Areas	Tubular Degeneration	Infiltration	Hyperemia	Intraalveolar Edema and Hemorrhage	Infiltration	Atelectasis
K-D	1.50±0.22[a]	1.17±0.17[a]	2.00±0.00[a]	1.17±0.17[a]	1.17±0.17[ab]	1.83±0.40[a]	1.33±0.21[a]	1.83±0.17[a]	1.67±0.42[a]
T-Z	2.67±0.21[b]	2.33±0.21[b]	2.67±0.21[b]	2.00±0.26[b]	1.17±0.21[b]	1.00±0.00[b]	1.17±0.17[a]	1.50±0.22[a]	1.00±0.00[a]
P	1.67±0.33[a]	1.00±0.00[a]	1.83±0.17[a]	1.50±0.22[ab]	1.00±0.00[a]	1.67±0.21[ab]	1.83±0.30[a]	2.00±0.00[a]	1.33±0.21[a]
P Value	0.014	0.000	0.004	0.051	0.022	0.090	0.149	0.116	0.255

[a,b,c] *Values within a column with different superscripts differ significantly at P<0.05.* ***K-D:*** *ketamine-diazepam,* ***T-Z:*** *tiletamine-zolazepam,* ***P:*** *propofol*

Liver: Significantly more severe vacuolar degeneration was observed in the livers of the T-Z administered animals than in the K-D and P administered animals. It was determined that hepatocytes were swollen and sinusoids were narrowed in these animals. In all groups, vacuolar degenerations affected hepatocytes especially around the vena centralis, while hepatocytes close to the portal area had a healthier appearance *(Fig. 1)*. In terms of inflammatory cell infiltrates in the sinusoids, the animals in the T-Z group were more severely affected. The infiltrates were predominantly composed of lymphocytes. Inflammatory cell infiltrations in the portal areas were observed in almost all groups, but the infiltration severity was higher in the T-Z group than in the other groups. Multifocal necroses were observed in the liver parenchyma in two animals administered T-Z.

When evaluated in terms of both tubular degeneration and inflammatory cell infiltrations in interstitial areas, the effect was greater in animals treated with T-Z. It was also noted that in some areas the tubular epithelium was swollen, tubule epithelium nuclei were karyorhectic and karyolytic, and the tubule lumens were narrowed *(Fig. 2)*.

Lung: The vessels were hyperemic in all groups and the hyperemia was more prominent in the K-D and P groups than in T-Z group. No significant differences were observed regarding the edema and intraalveolar hemorrhage, interalveolar septal infiltration, and atelectasis scores among the groups. Besides these parameters intraalveolar macrophages *(Fig. 3)*, hemosiderinophages and emphysematic areas were observed in all groups.

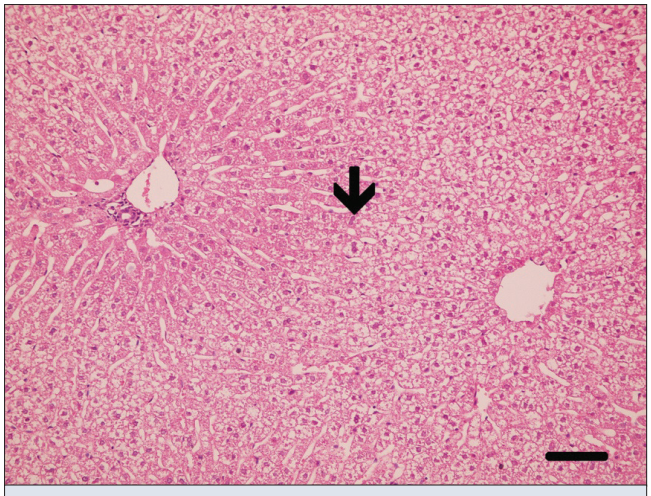

Fig 1. Vacuolar degeneration was the most significant change in the livers of all groups. Hepatocytes especially around vena centralis were more severely affected *(right and bottom of the arrow)*, while hepatocytes close to the portal area *(left of the arrow)* were less affected. Animal from the T-Z group, hematoxylin&eosin staining, bar=200 µm

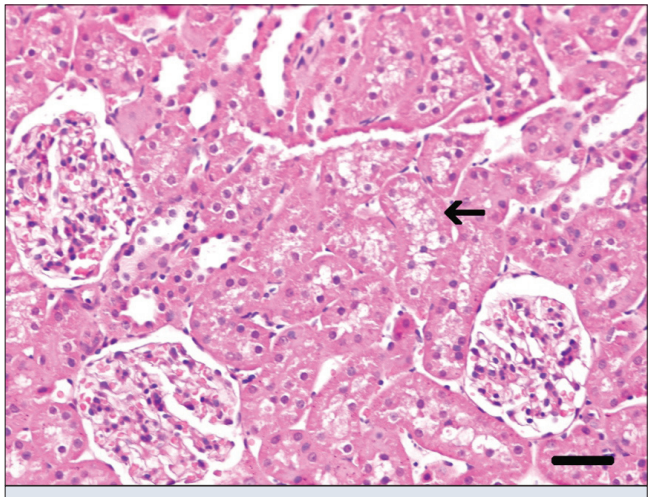

Fig 2. Tubular degeneration of varying degrees was observed in all groups. Cytoplasms of the tubular epithelium are vacuolar and some nuclei are karyolytic *(arrow)*. Lumens are narrowed due to the swollen tubular epithelium. Animal from the T-Z group, hematoxylin&eosin staining, bar=100 µm

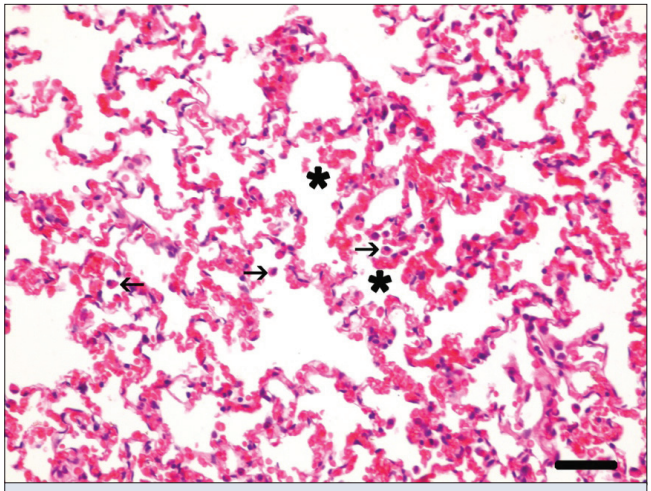

Fig 3. Hyperemia of the interalveolar capillaries was the most significant change in all groups. Intraalveolar hemorrhages *(*)* and intraalveolar macrophages *(arrows)* were also observed in some animals. Animal from the K-D group, hematoxylin&eosin staining, bar=100 µm

Discussion

Anesthetics may affect the physiological parameters, structure, and function of organ and biological systems, and these effects have been extensively studied. However, there is limited information about the effects of the infusion anesthetics in rabbits. We applied three different infusion anesthesia protocols and the results showed no negative effects on hematological and biochemical values and only minor changes on tissue structure of the liver, kidney, and lungs.

In experimental studies in rabbits, the effects of intramuscular ketamine and tiletamine anesthesia on different parameters were investigated [4,6,9,13]. Numerous studies present data from infusion anesthesia with propofol. Results of previous studies suggest that the necessary infusion rate for propofol in rabbits varies from 24-100 mg/kg/h [16,17]. We found that the propofol infusion rate of 30-50 mg/kg/h was sufficient to provide an optimal anesthesia level. Only in two rabbits corneal reflex was present, revealing superficial anesthesia, and the anesthetic dose was increased to 50 mg/kg/h.

Since the doses administered for induction were sufficient in all anesthetic groups, orotracheal intubation was achieved without the aid of topical lidocaine by using a disposable plastic endotracheal tube in our study. Then, the rabbits assumed lateral recumbency.

Heart rates were well-maintained in rabbits in the K-D and T-Z groups and there was no need for any anticholinergic drugs in any group. The heart rate decreased slightly over time in all groups, but the difference could not be substantiated statistically.

Ketamine or tiletamine administration increases heart rate in animals [10]. It has been reported that the slightly higher heart rate in the K-D and T-Z groups is due to the heart frequency-enhancing effects of the enhanced vagal activity of dissociative anesthetics-induced sympathomimetic effect [18]. In our study the heart rate increased slightly until the 30th min and returned to a slightly below initial value at the 60th min in the K-D group, while a slight gradual decrease was observed in the T-Z group. The difference between the aforementioned studies and our study can be due to the administration route of the anesthetics. While the anesthetics were used as a single dose intramuscularly in the studies mentioned, we applied the anesthetics in the form of an infusion for one h in our study.

An Another study revealed that propofol reduces sympathetic tone more than the parasympathetic tone, thus resulting in bradycardia from an unopposed parasympathetic response [19]. Heart rates were slightly lower in rabbits in the P group than in the K-D and T-Z groups throughout our study, but the statistical difference was insignificant.

Respiratory rates did not change in the K-D and T-Z groups from the beginning to the end of the infusion. However, a significant decrease in respiratory rate was observed from the 30th min of infusion in the P group, which affected the end-tidal CO_2 level in this group. The oxygen saturation did not change significantly over time in any of the groups.

Varying degrees of histopathological changes were observed in liver, kidney, and lung after all infusions. In the liver, T-Z infusion resulted in significantly more damage than in the other groups, as demonstrated by more severe vacuolar degeneration and inflammatory cell infiltrates both in the sinusoids and portal areas. In the kidney T-Z infusion resulted in slightly more severe changes than in the other groups. In the lungs all infusions resulted in similar edema and intraalveolar hemorrhage, interalveolar septal infiltration, and atelectasis scores. However, none of these organ changes unfavorably affected the anesthesia or biochemical parameters.

As a result of our study, we believe that ketamine-diazepam, tiletamine-zolazepam, and propofol can be safely administered as an intravenous infusion in healthy rabbits as an alternative to the single-dose intramuscular administration according to the hematological, serum biochemical and histopathological data.

Availability of Data and Materials

The datasets used and/or analyzed during the current study are available from the corresponding author (O. Ates) on reasonable request.

Acknowledgement

Funding for this work was totaly provided by Uludag University BAP Unit which is greatly appreciated.

Financial Support

This project supported and sponsored by Uludag Unıversity BAP Unit (Project code: THIZ-2021-397)t.

Conflict of Interest

The authors declared that there is no conflict of interest.

Author Contributions

AT, NYGS, OA and EMU planned the study, designed the experiments and helped manuscript writing; AT, NYGS, OA and EMU performed the this study; OA, EMU and OY collected blood and pathological samples and conducted laboratory process. ITC and OY worked on histopathological examination and writing phase. EMU analysed the statistics data. All authors read and approved the final manuscript.

References

1. Wenger S, Müllhaupt D, Ohlerth S, Prasse S, Klein K, Silva Valente B, Mosing M: Exprerimental evaluation of four airway devices in anaesthetized New Zealand White rabbits. *Vet Anaesth Analg*, 44 (3): 529-537, 2017. DOI: 10.1016/j.vaa.2016.05.009

2. Wenger S: Anesthesia and analgesia in rabbits and rodents. *J Exotic Pet Med,* 21, 7-16, 2012. DOI: 10.1053/j.jepm.2011.11.010

3. Gardhouse S, Sanchez A: Rabbit sedation and anesthesia. *Vet Clin North Am Exot Anim Pract*, 25 (1): 181-210, 2022. DOI: 10.1016/j.cvex.2021.08.012

4. Gonzalez Gil A, Illera JC, Silvan G, Illera M: Plasma glucocorticoid concentrations after fentanyl-droperidol, ketamine-xylazine and ketamine-diazepam anaesthesia in New Zealand white rabbits. *Vet Rec,* 148, 784-786, 2001. DOI: 10.1136/vr.148.25.784

5. Karasu A, Altuğ N, Aslan L, Bakır B, Yüksek N: Evaluation of the anesthetic effects of xylazine-ketamine, xylazine-tiletamine-zolazepam and tiletamine zolazepam using clinical and laboratory parameters in rabbits. *Med Weter,* 74 (10): 646-652, 2018. DOI: 10.21521/mw.6119

6. Dupras J, Vachon P, Cuvelliez S, Blais D: Anesthesia of the New Zealand rabbit using the combination of tiletamine-zolazepam and ketamine-midazolam with or without xylazine. *Can Vet J*, 42 (6): 455-460, 2001.

7. Luca GC, Barter LS, Pypendop BH: Pharmacokinetics of ketamine following a short intravenous infusion to isoflurane-anesthetized New Zealand white rabbits *(Oryctolagus cuniculus). Vet Anaesth Analg*, 47 (3): 334-340, 2020. DOI: 10.1016/j.vaa.2020.02.002

8. Kılıc N: A comparison between medetomidine-ketamine and xylazine-ketamine anaesthesia in rabbits. *Turk J Vet Anim Sci,* 28, 921-926, 2004.

9. Popilskis SJ, Oz MC, Gorman P, Florestal A, Kohn DF: Comparison of xylazine with tiletamine-zolazepam (Telazol) and xylazine-ketamine anesthesia in rabbits. *Lab Anim Sci,* 41, 51-53, 1991.

10. Ko JCH, Payton M, Weil AB, Kitao T, Haydon T: Comparison of anesthetic and cardiorespiratory effects of tiletamine-zolazepam-butorphanol and tiletamine-zolazepam-butorphanol-medetomidine in dogs. *Vet Ther,* 8 (2): 113-126, 2007.

11. Cicero L, Fazzotta S, Palumbo VD, Cassata G, Monte AI: Anesthesia protocols in laboratory animals used for scientific purposes. *Acta Biomed*, 89 (3): 337-342, 2018. DOI: 10.23750/abm.v89i3.5824

12. Saldanha A, Muehlbauer E, Gil EM, Froes TR, Duque JC, Lange RR: Comparison of blind intubation and a smartphone based endoscope-assisted intubation in rabbits. *Vet Anaesth Analg*, 47 (6): 826-834, 2020. DOI: 10.1016/j.vaa.2020.07.037

13. Orr HE, Roughan JV, Flecknell PA: Assessment of ketamine and medetomidine anaesthesia in the domestic rabbit. *Vet Anaesth Analg,* 32 (5): 271-279, 2005. DOI: 10.1111/j.1467-2995.2005.00211.x

14. Ypsilantis P, Politou M, Mikroulis D, Pitiakoudis M, Lambropouolu M, Tsigalou C, Didilis V, Bougioukas G, Papadopoulos N, Manolas C, Simopoulos C: Organ toxicity and mortality in propofol-sedated rabbits under prolonged mechanical ventilation. *Anesth Analg,* 105, 155-166, 2007. DOI: 10.1213/01.ane.0000265544.44948.0b

15. Campos SP, De Lurdes Pinto M, Gomes G, De Pinho, PG, Monteiro JA, Félix LM, Branco PS, Ferreira LM, Antunes LM: Expression of CYP1A1 and CYP1A2 in the liver and kidney of rabbits after prolonged infusion of propofol. *Exp Toxicol Pathol,* 68 (9): 521-531, 2016. DOI: 10.1016/j.etp.2016.07.006

16. Krimins RA, Ko JCH, Weil AB, Payton ME: Evaluation of anesthetic, analgesic, and cardiorespiratory effects in dogs after intramuscular administration of dexmedetomidine–butorphanol-tiletamine-zolazepam or dexmedetomidine-tramadol-ketamine drug combinations. *Am J Vet Res*, 73 (11): 1707-1714, 2012. DOI: 10.2460/ajvr.73.11.1707

17. Culp KE, Augoustıdes JG, Ochroch AE, Milas BL: Clinical management of cardiogenic shock associated with prolonged propofol infusion. *Anaesth Analg*, 99 (1): 221-226, 2004. DOI: 10.1213/01.ANE.0000117285.12600.C1

18. Kozma C, Macklin W, Cummıns LM, Mauer R: Anatomy, Physiology, and Biochemistry of the Rabbit. 49-72, Academic Press, New York, 1974.

19. Loeb WF, Quimby FW: Appendix-Reference values for clinical chemical analytes. 2nd ed., 415-495, Pergamon Press, New York, 1989.