The European Research Journal 2026;12(10):1185-1193

DOI: https://doi.org/10.18621/eurj.1409 Research Article | Ophthalmology

Three Clinical Indicators Supporting the Diagnosis of Suspected Ocular Demodicosis: A Retrospective Clinical Series

Derya Doganay[1], Oktay Alver[2], Zeynep Akkul[1]

[1]Department of Ophthalmology, Bursa Yuksek Ihtisas Training and Research Hospital, University of Health Sciences, Bursa, Türkiye
[2]Department of Medical Microbiology, Faculty of Medicine, Bursa Uludag University, Bursa, Türkiye

Objective: To identify practical clinical indicators to support the diagnosis of *Demodex*-associated blepharitis and guide anti-*Demodex* treatment decisions in patients with treatment-resistant chronic blepharitis, madarosis, and cylindrical dandruff (CD), particularly in clinical settings where microscopic confirmation is unavailable.

Methods: This retrospective clinical series evaluated 178 eyes of 89 patients with treatment-resistant chronic blepharitis accompanied by madarosis and CD. Three eyelashes were epilated from the upper and lower eyelids of each eye and examined using light microscopy at ×10 and ×40 magnification. Patients received a standardized regimen consisting of oral doxycycline, topical moxifloxacin, oxytetracycline/polymyxin B sulfate ointment, eyelid hygiene with pilocarpine hydrochloride drops, and tea tree oil (terpinen-4-ol). Oral ivermectin was initiated at 6 months in patients who remained symptomatic and exhibited Grade 2 or higher *Demodex* infestation.

Results: The mean (SD) age of the study population was 56.0 (18.3) years, and 51 patients (57.3%) were female. *Demodex folliculorum* was detected in all 89 patients (100%), whereas *Demodex brevis* was identified in 13 patients (14.6%). Mean (SD) *Demodex* counts ranged from 4.18 (4.05) to 4.51 (3.71) across the eyelids, with Grade 1 infestation being the most prevalent. The coexistence of all 3 primary clinical indicators (chronic refractory blepharitis, madarosis, and CD) demonstrated 100% concordance with the microscopic detection of *Demodex* infestation.

Conclusions: Chronic refractory blepharitis accompanied by madarosis and CD may serve as reliable, practical clinical indicators for initiating anti-*Demodex* therapy in settings where microscopic confirmation is unavailable.

Keywords: Blepharitis, *Demodex folliculorum*, Eye infections, Parasitic, Mite infestations, Cylindrical dandruff

Demodex is an ectoparasitic mite belonging to the phylum Arthropoda.[1] Two *Demodex* sp. capable of colonizing humans have been identified: *Demodex folliculorum* and *Demodex brevis*. *D. folliculorum* primarily inhabits hair follicles, whereas D. brevis preferentially resides within sebaceous glands, particularly the meibomian glands.[2-5] Transmission is believed to occur through close interpersonal contact, with the sharing of personal hygiene items, such as towels, among household members con-

Article History: Submitted: July 10, 2026 | Accepted: September 6, 2026 | Published Online: September 21, 2026

Corresponding Author: Derya Doganay, MD, Department of Ophthalmology, Bursa Yuksek Ihtisas Training and Research Hospital, University of Health Sciences, Mimar Sinan Mh. Emniyet Cd No. 35, 16310 Yıldırım, Bursa, Turkiye (d3rya1983@gmail.com).

Copyright and Open Access: Copyright © 2026 The Author(s). Published by Nicaea Medical Publishing. This is an open access article distributed under the terms of the Creative Commons Attribution-NonCommercial-NoDerivatives 4.0 International License (CC BY-NC-ND 4.0).

Digital Infrastructure Registries: Available Online at https://eurj.org.tr

sidered a potential route of spread. Although *Demodex* infestation has been implicated in several ocular and dermatological disorders, the precise mechanisms by which these mites contribute to disease pathogenesis remain incompletely understood.[6]

The diagnosis of *Demodex* sp. infestation is most commonly established by direct microscopic examination of epilated eyelashes, allowing assessment of both mite morphology and parasite density.[7] In recent years, increasing evidence has suggested an association between *Demodex* sp. infestation and a variety of dermatological disorders as well as chronic blepharitis. Conversely, some investigators consider *Demodex* sp. to be a component of the normal eyelid flora and argue that it does not play a pathogenic role.[8]

Blepharitis is a chronic inflammatory disorder of the eyelid margins. It is one of the most common conditions encountered in ophthalmic practice and accounts for approximately 47 percent of outpatient ophthalmology visits.[9,10] Patients most commonly present with symptoms of burning, foreign body sensation, ocular discomfort, epiphora, and redness. In untreated or advanced cases, ocular surface involvement may develop, leading to more severe clinical manifestations, including conjunctival hyperemia. Although uncommon, serious corneal complications such as superficial punctate keratopathy, corneal erosions, and even keratitis may also occur in these patients.[9,11]

D. folliculorum may proliferate within the eyelash follicles, resulting in follicular obstruction. This process is considered clinically important because the mites may induce allergic inflammation through their antigenic components while the resulting mechanical obstruction may facilitate secondary bacterial infection.[12] When *Demodex* sp. infestation is associated with blepharitis, patients may exhibit a broad spectrum of clinical manifestations ranging from mild ocular irritation to severe ocular surface disease capable of impairing visual quality. Furthermore, conventional blepharitis treatment often fails to provide satisfactory symptom control in affected individuals.[13] Eyelash microscopy therefore represents an important diagnostic tool, particularly in patients with chronic blepharitis refractory to conventional therapy.[14] Nevertheless, management of *Demodex* sp–associated blepharitis remains challenging because no universally accepted treatment strategy has yet been established despite decades of investigation into the relationship between *Demodex* sp. infestation and blepharitis.[8] Consequently, persistent symptoms substantially impair patient quality of life.

Key Points

Question: Can the coexistence of chronic refractory blepharitis, madarosis, and cylindrical dandruff serve as reliable clinical indicators for diagnosing ocular demodicosis without microscopic confirmation?

Findings: In this retrospective clinical series evaluating 89 patients (178 eyes), the simultaneous presence of chronic refractory blepharitis, madarosis, and cylindrical dandruff demonstrated 100% concordance with the microscopic detection of *Demodex* mites.

Meaning: The combination of these 3 specific clinical indicators offers a practical and reliable clinical proxy for initiating anti-*Demodex* therapy, particularly in healthcare settings where light microscopy is unavailable.

The present study was designed to identify practical clinical indicators that may facilitate the diagnosis of *Demodex*-associated blepharitis and assist clinicians in deciding when patients should undergo microscopic evaluation for *Demodex* infestation. In addition, we aimed to propose clinically applicable indicators that may support the initiation of anti-*Demodex* sp. treatment in settings where microscopic diagnostic facilities are unavailable. Specifically, we evaluated whether the coexistence of chronic blepharitis, madarosis, and cylindrical dandruff (CD) could serve as 3 principal clinical indicators for identifying this condition.

Methods

Study Design and Participants

This multicenter retrospective study was conducted between January 2019 and May 2026 through a collaboration between the Department of Ophthalmology, University of Health Sciences Bursa Yuksek Ihtisas Training and Research Hospital, and the Department of Microbiology, Uludağ University Hospital. The study received ethical approval from the Medical Sciences Ethics Committee of the University of Health Sciences Bursa Yuksek Ihtisas Training and Research Hospital (Decision No. 2024-TBEK 2026/05-19; May 20, 2026) and adhered to the tenets of the Declaration

of Helsinki. Due to the retrospective and anonymized nature of the data, the requirement for institutional informed consent was waived by the ethics committee. However, written informed consent was obtained from the patients for the publication of the clinical and anterior segment photographs included in this article.

A total of 178 eyes from 89 patients were included. Demographic characteristics, including age, sex, and ocular surface symptoms, were recorded. Patients with chronic blepharitis who had persistent symptoms (burning, stinging, and redness) despite prolonged conventional treatment at other institutions were enrolled. All participants underwent a comprehensive ophthalmic examination, including slit-lamp biomicroscopy of the eyelid margins, ocular surface, and conjunctiva. Eyelid margin inflammation was defined as blepharitis. The presence of blepharitis, madarosis, and CD was recorded in all patients. All ophthalmic examinations were performed by the same ophthalmologist.

Patients exhibiting the simultaneous presence of chronic blepharitis, madarosis, and CD underwent microscopic evaluation for *Demodex* sp. infestation. Three eyelashes were epilated from both the upper and lower eyelids of each eye using sterile forceps.

Patients with asymptomatic blepharitis, chronic ocular surface disease, a history of eyelid or eyelash malposition, or the use of topical or systemic medications that could affect the ocular surface were excluded from the study.

Eyelash Sampling and Microscopic Examination

Eyelash sampling was performed according to a standardized protocol. Three eyelashes were epilated from the medial, central, and lateral portions of each eyelid. Eyelashes demonstrating CD and surrounding hyperemia, suggestive of *Demodex* sp. infestation, were preferentially selected. Both eyelash epilation and microscopic examination were performed by 1 experienced microbiologist.

A total of 12 eyelashes were obtained from each patient (3 from each eyelid), resulting in the examination of 1068 eyelashes during the study. The specimens were mounted on glass slides using Hoyer medium and examined via light microscopy at ×40 and ×100 magnifications (**Figure 1**). The number of *Demodex* sp. mites detected in the epilated eyelashes from each eyelid was recorded separately. Mite quantification was performed using an oculometric method (CHWK, Olympus).

The presence of at least 1 *D. folliculorum* and/or *D. brevis* mite among the 12 examined eyelashes was considered positive for *Demodex sp.* infestation. For quantitative analysis, the total number of *Demodex* sp. mites detected in both eyelids was recorded. Infestation severity was graded from 0 to 3 according to the classification described by Murphy et al.[15] Infestation severity was categorized based on the mite count per eyelid: Grade 0, 0 mites (no infestation); Grade 1, 1 to 3 mites (mild infestation); Grade 2, 4 to 6 mites (moderate infestation); and Grade 3, 7 or

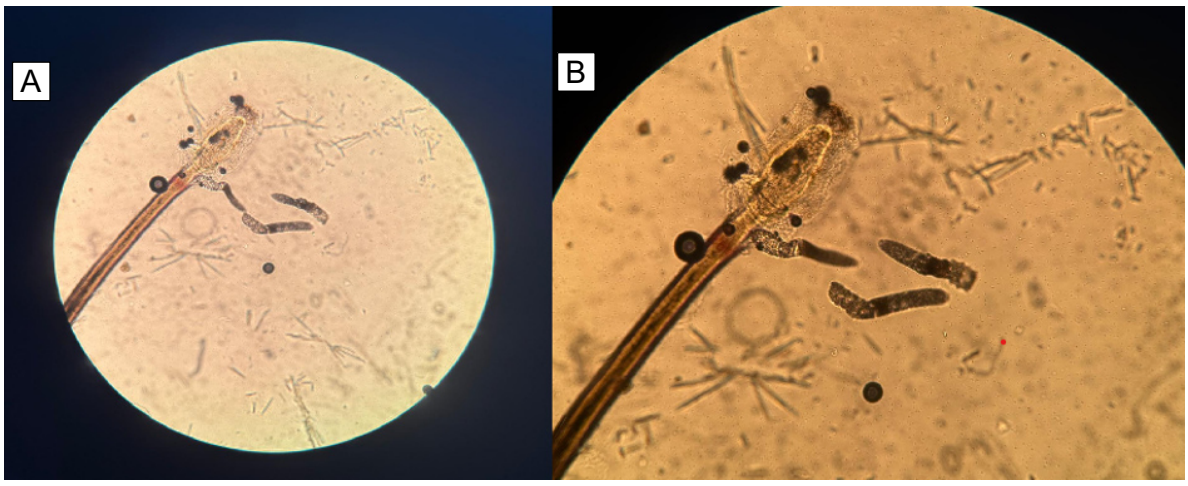

Figure 1. Microscopic Appearance of Demodex folliculorum on an Epilated Eyelash
A, The sample was observed under light microscopy (×10). **B**, Close-up magnification (×40).

more mites (severe infestation).

In this study, a total of 178 eyes from 89 patients were evaluated. The upper and lower eyelids of each eye were examined separately. For each eye, the Murphy classification severity grade was determined based on the single eyelid with the highest mite count between the upper and lower eyelids.

Clinical Evaluation and Treatment Protocol

Although nonspecific clinical manifestations such as burning, stinging, epiphora, and ocular pain suggest active disease, they were excluded from the definitive diagnostic criteria because they represent universal findings in patients with blepharitis independent of etiology. The primary objective of this study was to identify highly sensitive clinical indicators for *Demodex* sp. infestation that could facilitate treatment decisions in centers where microscopic confirmation is unavailable. Based on routine clinical observations, *Demodex* sp. infestation was most frequently identified in patients presenting with simultaneous CD, madarosis, and anterior or posterior blepharitis. Therefore, these 3 findings were defined as the principal clinical indicators evaluated in this study.

Patients presenting with all 3 indicators (N = 89) were referred for microscopic examination for *Demodex* sp. infestation. As the first-line treatment protocol, all patients received a standardized treatment regimen consisting of oral doxycycline (100 mg twice daily for 20 days), topical moxifloxacin eye drops (4 times daily for 2 months), topical oxytetracycline/polymyxin B sulfate ophthalmic ointment (twice daily for 60 days), pilocarpine hydrochloride for eyelid hygiene (5 times daily for 2 months), and 5% tea tree oil (terpinen-4-ol) applied once daily for 6 months.

Following completion of the initial 6-month treatment protocol, patients with persistent symptoms underwent repeat microscopic evaluation for bilateral upper and lower eyelid *Demodex* infestation. Those presenting with a persistent infestation of grade 2 or higher in any eyelid were enrolled in the second-line protocol, receiving oral ivermectin (200 µg/kg) administered in 2 doses 4 weeks apart.

Statistical Analysis

Statistical analyses were performed using appropriate nonparametric tests according to the distribution and measurement level of the variables. The relationship between age and *Demodex* load or severity scores was assessed using the Spearman rank correlation coefficient. Comparisons between sexes were performed using the Mann-Whitney *U* test. *Demodex* severity scores, which were considered ordinal variables, were analyzed using nonparametric methods. For paired pre-treatment and post-treatment comparisons, the Wilcoxon signed-rank test was used. All statistical tests were 2-sided, and a *P* value of less than .05 was considered statistically significant.

Results

A total of 178 eyes from 89 patients were included in the study. The study population comprised 51 female (57.3%) and 38 male (42.7%), with a mean (SD) age of 56.0 (18.3) years. *Demodex* sp. infestation was detected in at least 1 eyelid in all patients. The demographic characteristics of the study population are summarized in **Table 1**. The mean (SD) number of *Demodex* sp. mites detected microscopically was 4.43 (3.69) in the right upper eyelid, 4.22 (3.56) in the right lower eyelid, 4.51 (3.71) in the left upper eyelid, and 4.18 (4.05) in the left lower eyelid (**Table 2**).

According to the infestation severity grading, Grade 1 infestation was identified in 44 (49.4%), 36 (40.4%), 38 (42.7%), and 45 (50.6%) patients in the right upper, right lower, left upper, and left lower eyelids, respectively. Grade 2 infestation was observed in 23 (25.8%), 36 (40.4%), 30 (33.7%), and 22 (24.7%) patients, whereas Grade 3 infestation was detected in 22 (24.7%), 17 (19.1%), 21 (23.6%), and 22 (24.7%)

Table 1. Demographic Characteristics of the Study Population (N = 89)

Variable	No. (%)	Mean (SD)	Min–Max
Age, y	—	56.0 (18.3)	7–86
Sex			
Female	51 (57.3)	—	—
Male	38 (42.7)	—	—

Abbreviations: Max, maximum; Min, minimum; SD, standard deviation.

Table 2. Distribution of *Demodex* sp. Counts

Eyelid	Min–Max	Mean (SD)
Right upper eyelid	1–17	4.43 (3.69)
Right lower eyelid	1–20	4.22 (3.56)
Left upper eyelid	1–17	4.51 (3.71)
Left lower eyelid	1–23	4.18 (4.05)

Abbreviations: Max, maximum; Min, minimum; SD, standard deviation.

patients, respectively. Staging was performed considering the eyelid with the maximum *Demodex* load. The distribution of *Demodex* sp. mite counts and the severity grades for each eyelid are presented in **Tables 2 and 3.**

A history of recurrent hordeolum and chalazion was present in 18 patients (**Figure 2**), while ocular surface disease was identified in 4 patients. All patients presenting with the simultaneous presence of chronic blepharitis, madarosis (**Figure 3**), and CD (**Figure 4**) were confirmed to have *Demodex* sp. infestation.

Following treatment with oral doxycycline and topical therapy, based on the maximum eyelid severity grade per patient, 27 patients (30.3%) were classified as Grade 0, 36 (40.4%) as Grade 1, and 26 (29.2%) as Grade 2 infestation. Patients with Grade 2 infestation subsequently received oral ivermectin therapy (200 µg/kg single dose, 2 doses administered 4 weeks apart). After ivermectin treatment, only 6 patients (6.7%) remained positive for *Demodex* sp. infestation. A significant positive correlation was observed between age and total *Demodex* load (Spearman $r = .28$, $P = .008$), indicating that *Demodex* load increased with increasing age. Similarly, age was significantly correlated with the total Grade score (Spearman $r = .25$, $P = .02$) and the maximum Grade score (Spearman $r = .22$, $P = .04$). In contrast, no statistically significant associations were found between sex and total *Demodex* load ($P = .41$), total Grade score ($P = .40$), or maximum Grade score ($P = .74$).

Discussion

This study underscores that while blepharitis remains a chronic, highly prevalent inflammatory disorder across all age groups, its clinical severity is intricately linked to *Demodex* proliferation. Although the condition rarely causes permanent visual acuity loss, it substantially impairs patient quality of life and, in advanced stages, induces irreversible structural alterations to the eyelids and ocular surface. Within this clinical framework, whether *D. folliculorum* and D. brevis—the only species known to obligately inhabit humans as exclusive mammalian hosts—represent benign components of the normal ocular microbiota or operate as true pathogens continues to be a subject of intense controversy.[1,4]

The pathogenic role of *Demodex* in chronic blepharitis has historically yielded conflicting epidemiological data. For instance, Kemal et al[8] reported no significant difference in infestation rates between patients with blepharitis and healthy controls (28.8% vs 26.7%, respectively). Conversely, Uyttebroeck et al[16] demonstrated a distinct disparity, identifying *Demodex* infestation in 51.0% of patients with seborrheic blepharitis compared with only 25.0% of healthy controls. Supporting this pathogenic association, Demmler et al[17] argued that these mites play a direct causative role in chronic eyelid inflammation, emphasizing the necessity of targeted clinical investigations.

Our methodology departs fundamentally from these previous historical cohorts by focusing exclusively on patients with symptomatic chronic blepharitis who remained strictly refractory to conventional therapies

Table 3. Classification of *Demodex* sp. Infestation Severity

Eyelid	Grade 1, No. (%)	Grade 2, No. (%)	Grade 3, No. (%)
Right upper eyelid	44 (49.4)	23 (25.8)	22 (24.7)
Right lower eyelid	36 (40.4)	36 (40.4)	17 (19.1)
Left upper eyelid	38 (42.7)	30 (33.7)	21 (23.6)
Left lower eyelid	45 (50.6)	22 (24.7)	22 (24.7)

Severity grades are defined based on the number of mites per eyelid: Grade 1, 1–3 mites; Grade 2, 4–6 mites; Grade 3, ≥7 mites.

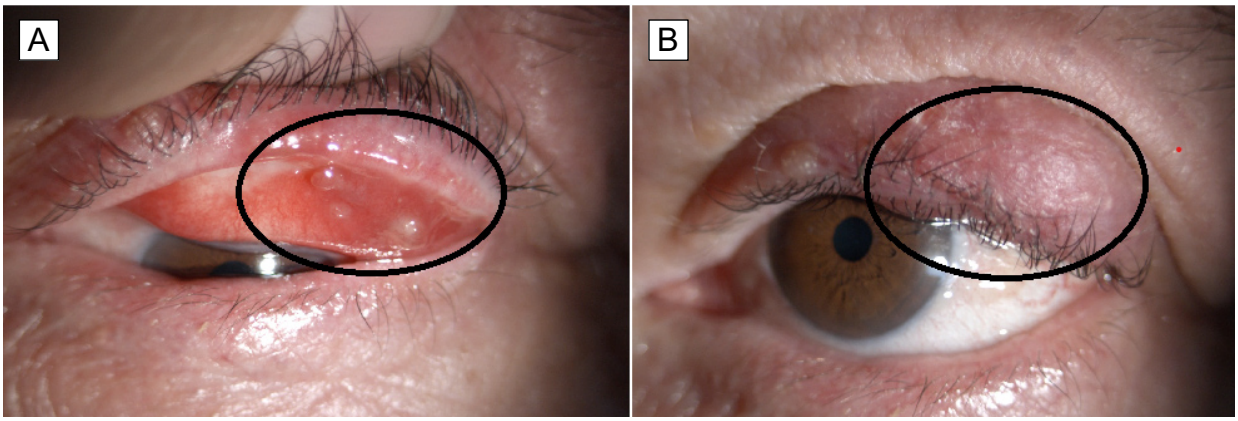

Figure 2. Anterior Segment Photograph of a Patient With Chronic Recurrent Chalazion
The image demonstrates microscopically confirmed Demodex infestation.
The ellipse symbol indicates tarsal surface (**A**) and dermal surface (**B**) infestation.
Written informed consent for the publication of this photograph was obtained from the patient.

for at least 6 months. Remarkably, every enrolled patient simultaneously exhibited madarosis, CD, and microscopically confirmed *Demodex* infestation. This absolute coexistence strongly implies that the triad of chronic blepharitis, madarosis, and CD represents an pathognomonic clinical signature of high-density *Demodex* blepharitis rather than incidental colonization.

Numerous studies have demonstrated an association between *Demodex* sp. infestation and blepharitis as well as other anterior segment disorders.[14,18] Rather than the mere presence of the mites, increasing evidence suggests that excessive mite proliferation and an increased parasite burden may disrupt ocular surface homeostasis and contribute to the development of clinical disease. A similar mechanism has also been proposed in several

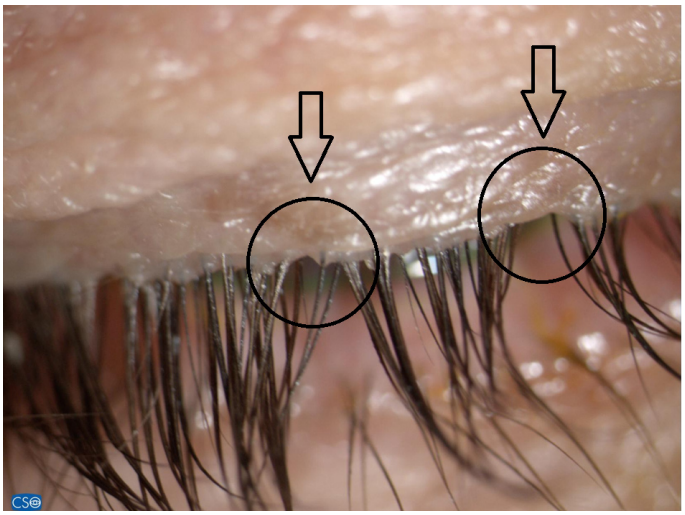

Figure 3. Clinical Photograph Demonstrating Madarosis
The patient presents with microscopically confirmed Demodex infestation. The lesions enclosed in circles are shown by arrows.
Written informed consent for the publication of this photograph was obtained from the patient.

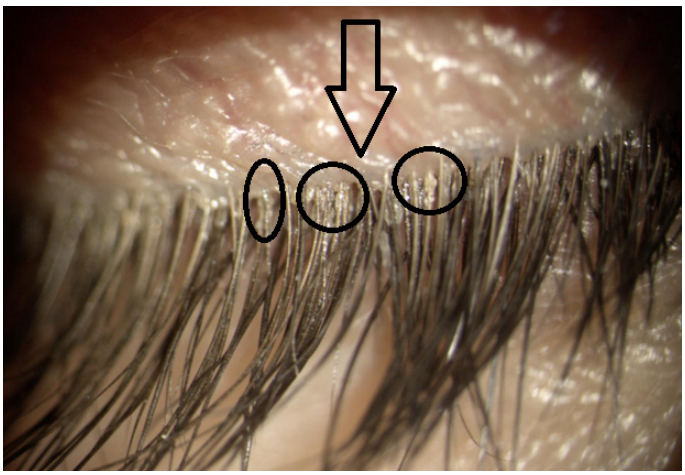

Figure 4. Characteristic Cylindrical Dandruff Surrounding the Base of the Eyelashes
The presentation is pathognomonic for Demodex-associated blepharitis. The arrow indicates the lesion enclosed within the circles.
Written informed consent for the publication of this photograph was obtained from the patient.

dermatological disorders, in which alterations in the host-parasite balance are thought to promote *Demodex* sp. proliferation.[19] In line with the findings of Kemal et al,[8] who reported a 40.8% prevalence among individuals older than 60 years, our data confirm a significant age-related escalation in parasite load. This age-related increase has been attributed to alterations in sebaceous gland function accompanying aging.[20]

The classical phenotypic presentation of ocular demodicosis encompasses recurrent eyelid margin inflammation, trichiasis, distichiasis, madarosis, and periciliary CD.[14,21,22] Previous studies have reported widely varying rates of *Demodex* sp. positivity in patients with CD, ranging from 31% to 100%.3,22 To standardize this diagnostic ambiguity, Alver et al[23] recently introduced the Uludağ Ocular Demodicosis Clinical Scoring System. While their model successfully yielded a 94.0% positivity rate using a threshold score of of ≥4, it relied heavily on subjective patient-reported symptoms such as burning, stinging, pruritus, and ocular pain.[23]

In contrast, our diagnostic paradigm deliberately excluded these subjective metrics. Symptoms like burning and stinging are inherently nonspecific, showing extensive overlap across diverse etiologies of dry eye syndrome, meibomian gland dysfunction, and general ocular surface diseases. By refining our diagnostic lens strictly to the concurrent triad of objective biomarkers—chronic blepharitis, madarosis, and CD—we achieved a 100.0% microscopic confirmation rate. Consequently, we propose this objective triad as a highly reliable, cost-effective clinical surrogate for identifying ocular demodicosis, particularly in resource-limited settings lacking immediate microscopic or confocal verification capabilities.

Given that a universally accepted therapeutic standard for ocular demodicosis remains elusive, contemporary strategies range from mechanical lid hygiene with 5% tea tree oil to systemic interventions including oral ivermectin and metronidazole for refractory presentations.[23,24] Because complete biological eradication is clinically unrealistic, the primary therapeutic goal must focus on suppressing the parasite density below pathogenic thresholds. Our protocol successfully operationalized this concept, demonstrating that a targeted, 2-dose oral ivermectin regimen effectively controls infestation and restores the clinical architecture of the eyelid margin.

Strengths and Limitations

The primary strength of this study lies in its focused evaluation of a highly specific, treatment-resistant patient cohort, addressing a critical gap in daily ophthalmic practice. Unlike prior investigations that relied on highly subjective symptoms—such as burning, stinging, or ocular discomfort, which frequently overlap with various ocular surface disorders—our protocol restricted the diagnostic criteria to 3 objective, easily identifiable clinical landmarks: chronic refractory blepharitis, madarosis, and CD. The 100 percent concordance observed between the coexistence of these 3 criteria and microscopic *Demodex* confirmation underscores the clinical utility of this combination. Furthermore, this study proposes a practical, reliable, and cost-effective clinical proxy that enables clinicians to confidently initiate targeted anti-*Demodex* therapy, particularly in low-resource or primary care healthcare settings where light microscopy facilities are completely unavailable.

However, this study has several limitations. First, its retrospective design may have introduced selection bias. Second, the study included only patients with treatment-resistant chronic blepharitis who simultaneously presented with madarosis and CD; therefore, the proposed clinical indicators cannot be generalized to all patients with blepharitis. Third, because all enrolled patients underwent microscopic examination after meeting the predefined clinical criteria, a control group lacking these findings was not included.

Although *Demodex* sp. positivity was detected in all 89 patients included in the study, determining the precise diagnostic sensitivity or specificity of these findings is not possible, as this high positivity rate was obtained within a highly selected cohort.

Therefore, evaluating these clinical indicators in larger, prospective, multicenter series with an appropriate control group and a more heterogeneous patient population is warranted to further establish their diagnostic performance and clinical applicability.

Conclusions

Because *Demodex* species may be present as part of the normal ocular microbiota, their pathogenic role remains controversial. Our findings support the hypothesis that symptomatic disease may be associated not

simply with the presence of *Demodex* sp. mites but with an increased mite burden resulting from disruption of the host-parasite equilibrium. In this study, all patients presenting with the simultaneous presence of chronic blepharitis, madarosis, and CD were positive for Demodex sp. infestation. Therefore, these 3 objective clinical findings may serve as practical clinical indicators for identifying patients with suspected ocular demodicosis and may assist clinicians in initiating appropriate anti-*Demodex* sp. therapy in centers where microscopic examination is unavailable. Prospective, multicenter studies are needed to validate the diagnostic performance and generalizability of these proposed clinical indicators.

Declarations

Ethics Approval and Informed Consent: This study was approved by the Medical Sciences Ethics Committee of the University of Health Sciences Bursa Yuksek Ihtisas Training and Research Hospital (Decision No. 2024-TBEK 2026/05-19; Date: May 20, 2026). The study was conducted in accordance with the ethical principles of the Declaration of Helsinki. Given the use of anonymized retrospective data, the requirement for informed consent was waived by the ethics committee. However, written informed consent was obtained from the patients for the publication of the clinical and anterior segment photographs included in this article.

Conflict of Interest Disclosures: The authors have no conflicts of interest to disclose and report no proprietary or commercial interest in any product mentioned or concept discussed in this article.

Funding/Support: The authors received no specific grant or financial support from any funding agency in the public, commercial, or not-for-profit sectors for this study.

Data Sharing Statement: The data that support the findings of this study are available from the corresponding author upon reasonable request.

Author Contributions: Dr D. Doğanay had full access to all of the data in the study and takes responsibility for the integrity of the data and the accuracy of the data analysis.
Concept and design: D. Doğanay.
Acquisition, analysis, or interpretation of data: D. Doğanay, Z. Akkul.
Drafting of the manuscript: D. Doğanay, O. Alver.
Critical review of the manuscript for important intellectual content: D. Doğanay, Z. Akkul.
Statistical analysis: D. Doğanay, Z. Akkul.
Obtained funding: All authors.
Administrative, technical, or material support: D. Doğanay, O. Alver.
Supervision: D. Doğanay.

Acknowledgments: None

Declaration of Generative AI and AI-Assisted Technologies: During the preparation of the manuscript, the authors used generative artificial intelligence (AI) and AI-assisted Technologies (OpenAI, June 2026) solely for language editing, grammar and punctuation refinement, and to verify the accuracy and clarity of English sentence construction. Following the use of these tools, the authors reviewed, edited, and approved all revisions, and they take full responsibility for the integrity and final content of the manuscript.

Publisher Note and Legal Disclaimer

The opinions, findings, and conclusions expressed in this article are solely those of the authors and do not necessarily reflect the official policy or position of the journal, the editorial board, or the publisher. The publisher maintains a neutral position with regard to jurisdictional claims in published maps and institutional affiliations. The publisher provides no warranties, express or implied, regarding the accuracy, completeness, or reliability of any products, services, dosages, or manufacturer claims mentioned within this manuscript. Professional medical judgment should always be exercised in clinical practice, and readers are advised to verify all medical information independently.

How to cite this article: Doganay D, Alver O, Akkul Z. Three Clinical Indicators Supporting the Diagnosis of Suspected Ocular Demodicosis: A Retrospective Clinical Series. *Eur Res J.* 2026;12(10):1185-1193. doi:10.18621/eurj.1409

References

1. Zhao YE, Guo N, Xun M, Xu JR, Wang M, Wang DL. Sociodemographic characteristics and risk factor analysis of *Demodex* infestation (Acari: Demodicidae). *J Zhejiang Univ Sci B*. 2011;12(12):998-1007. doi:10.1631/jzus.B1100079
2. Biernat MM, Rusiecka-Ziółkowska J, Piątkowska E, Helemejko I, Biernat P, Gościniak G. Occurrence of *Demodex* species in patients with blepharitis and in healthy individuals: a 10-year observational study. *Jpn J Ophthalmol.* 2018;62(6):628-633. doi:10.1007/s10384-018-0624-3
3. Liu J, Sheha H, Tseng SC. Pathogenic role of *Demodex* mites in blepharitis. *Curr Opin Allergy Clin Immunol.* 2010;10(5):505-510. doi:10.1097/ACI.0b013e32833df9f4

4. Desch C, Nutting WB. *Demodex folliculorum* (Simon) and *D. brevis* Akbulatova of man: redescription and reevaluation. *J Parasitol*.1972;58(1):169-177.
5. Coston TO. *Demodex folliculorum* blepharitis. *Trans Am Ophthalmol Soc*. 1967;65:361-392.
6. Baima B, Sticherling M. Demodicidosis revisited. *Acta Derm Venereol*. 2002;82(1):3-6. doi:10.1080/000155502753600795
7. Muntz A, Purslow C, Wolffsohn JS, Craig JP. Improved *Demodex* diagnosis in the clinical setting using a novel in situ technique. *Cont Lens Anterior Eye*. 2020;43(4):345-349. doi:10.1016/j.clae.2019.11.009
8. Kemal M, Sümer Z, Toker MI, Erdoğan H, Topalkara A, Akbulut M. The Prevalence of *Demodex folliculorum* in blepharitis patients and the normal population. *Ophthalmic Epidemiol*. 2005;12(4):287-290. doi:10.1080/092865805910057
9. Amescua G, Akpek EK, Farid M, et al. Blepharitis preferred practice pattern®. *Ophthalmology*. 2019;126(1):P56-P93. doi:10.1016/j.ophtha.2018.10.019
10. Lemp MA, Nichols KK. Blepharitis in the United States 2009: a survey-based perspective on prevalence and treatment. *Ocul Surf*. 2009;7(2 Suppl):S1-S14. doi:10.1016/s1542-0124(12)70620-1
11. Putnam CM. Diagnosis and management of blepharitis: an optometrist's perspective. *Clin Optom (Auckl)*. 2016;8:71-78. doi:10.2147/opto.S84795
12. Budak S, Yolasığmaz A. Demodicosis. In: Özcel MA, ed. *İmmün Yetmezlikte Önemi Artan Parazit Hastalıkları*. 1st ed. Türk Parazitoloji Derneği Yayınları; 2000:165-168.
13. Cheng AM, Hwang J, Dermer H, Galor A. Prevalence of ocular demodicosis in an older population and its association with symptoms and signs of dry eye. *Cornea*. 2021;40(8):995-1001. doi:10.1097/ICO.0000000000002542
14. Luo X, Li J, Chen C, Tseng S, Liang L. Ocular demodicosis as a potential cause of ocular surface inflammation. *Cornea*. 2017;36(suppl 1):S9-S14. doi:10.1097/ICO.0000000000001361
15. Murphy O, O'Dwyer V, Lloyd-McKernan A. Ocular *Demodex folliculorum*: prevalence and associated symptoms in an Irish population. *Int Ophthalmol*. 2019;39(2):405-417. doi:10.1007/s10792-018-0826-1
16. Uyttebroeck W, Nijs I, Maudgal PC, et al. Incidence of *Demodex folliculorum* in normal people and in blepharitis patients. *Bull Soc Belge Ophtalmol*. 1982;201:83-87.
17. Demmler M, de Kaspar HM, Möhring C, Klauss V. Blepharitis. Demodex folliculorum, assoziiertes Erregerspektrum und spezifische Therapie [Blepharitis. *Demodex folliculorum*, associated pathogen spectrum and specific therapy]. *Ophthalmologe*. 1997;94(3):191-196. doi:10.1007/s003470050100 Article in German
18. Cheng AM, Sheha H, Tseng SC. Recent advances on ocular *Demodex* infestation. *Curr Opin Ophthalmol*. 2015;26(4):295-300. doi:10.1097/ICU.0000000000000168
19. Fromstein SR, Harthan JS, Patel J, Opitz DL. *Demodex* blepharitis: clinical perspectives. *Clin Optom* (Auckl). 2018;10:57-63. doi:10.2147/OPTO.S142708
20. Rusiecka-Ziółkowska J, Nokiel M, Fleischer M. *Demodex* - an old pathogen or a new one?.*Adv Clin Exp Med*. 2014;23(2):295-298. doi:10.17219/acem/37081
21. Gao YY, Di Pascuale MA, Elizondo A, Tseng SC. Clinical treatment of ocular demodecosis by lid scrub with tea tree oil. *Cornea*. 2007;26(2):136-143. doi:10.1097/01.ico.0000244870.62384.79
22. Kheirkhah A, Casas V, Li W, Raju VK, Tseng SC. Corneal manifestations of ocular demodex infestation. *Am J Ophthalmol*. 2007;143(5):743-749. doi:10.1016/j.ajo.2007.01.054
23. Alver O, Kıvanç SA, Akova Budak B, Tüzemen NÜ, Ener B, Özmen AT. A Clinical scoring system for diagnosis of ocular demodicosis. *Med Sci Monit*. 2017;23:5862-5869. Published 2017 Dec 10. doi:10.12659/msm.907824
24. Alver O, Doğanay D, Doğanay S. Effectiveness of oral ivermectin treatment in cases unresponsive to classical *Demodex* blepharitis treatment. *Turkiye Parazitol Derg*. 2025;49(4):168-172. doi:10.4274/tpd.galenos.2025.39260