Check for updates

Microsurgery

WILEY

MICROSURGERY

CLINICAL ARTICLE

Superior Lateral Genicular Artery Perforator Flap for Reconstruction of Anterolateral Knee Soft Tissue Defects

Süleyman Çeçen[1] | Burak Özkan[2] | Mehmet Ali Şahin[3] | Menekşe Kastamoni Başkan[1] | Çağrı Ahmet Uysal[4]

[1]Department of Plastic, Aesthetic and Reconstructive Surgery, Bursa Uludağ University Faculty of Medicine, Bursa, Turkey | [2]Department of Plastic, Aesthetic and Reconstructive Surgery, İstanbul Medipol University Faculty of Medicine, Medipol Mega University Hospital, İstanbul, Turkey | [3]Department of Plastic, Aesthetic and Reconstructive Surgery, Artvin State Hospital, Artvin, Turkey | [4]Department of Plastic, Aesthetic and Reconstructive Surgery, Başkent University Faculty of Medicine, Ankara, Turkey

Correspondence: Süleyman Çeçen (scecen@uludag.edu.tr)

Received: 20 July 2026 | **Revised:** 24 October 2026 | **Accepted:** 31 October 2026

Keywords: knee reconstruction | lower extremity reconstruction | perforator flap | propeller flap | soft tissue defect | superior lateral genicular artery

ABSTRACT

Background: Soft tissue defects around the knee remain a reconstructive challenge because of limited local tissue availability, exposure of vital structures, and the need to preserve joint function. Previous anatomical studies and small clinical reports have described the superior lateral genicular artery perforator (SLGAP) flap, but evidence guiding selection among propeller, bilobed, and keystone configurations remains limited. This report describes clinical outcomes in a retrospective series of predominantly anterior and lateral knee soft tissue defects and explores configuration selection in relation to defect size, geometry, and location.

Methods: A retrospective review was performed of consecutive patients who underwent reconstruction using an SLGAP flap between January 2017 and December 2025. Perforators were mapped preoperatively using handheld or color Doppler ultrasonography. According to defect size, geometry, location, and required flap mobility, the flaps were designed in propeller, bilobed, or keystone configurations. Flaps were elevated in the subfascial plane with preservation of the identified perforator, mobilized and transferred without excessive tension or pedicle compression, and inset after clinical confirmation of adequate perfusion. Patient demographics, defect characteristics, flap design, postoperative complications, flap survival, and clinical outcomes were analyzed. Ambulatory status was recorded from routine subjective clinical assessment; no standardized functional outcome instrument was used.

Results: Fifteen patients underwent reconstruction with an SLGAP flap. Mean defect dimensions were 6.9 × 5.7 cm (length range, 4–15 cm; width range, 3–10 cm), and defects were located in the anterior patellar ($n = 9$), lateral patellar ($n = 5$), and medial patellar ($n = 1$) regions. Mean flap dimensions were 14.7 × 7.0 cm (length range, 6–25 cm; width range, 5–10 cm); 10 propeller, four bilobed, and one keystone flap were used. Trauma was the most common etiology ($n = 9$), followed by electrical burns ($n = 2$), tumor resection ($n = 2$), radiation necrosis ($n = 1$), and prosthesis exposure ($n = 1$). Initial defect coverage was achieved in all patients, with no early total flap loss. Marginal necrosis occurred in two patients and transient venous congestion in one; these complications resolved without further reconstruction. One patient developed delayed total flap necrosis approximately 5–6 days after surgery and underwent secondary reconstruction with a lateral gastrocnemius muscle flap. Among the 13 patients with available follow-up data, mean follow-up was 17.4 months (range, 2–72 months). Stable wound coverage was maintained in 14 of 15 patients, with no major donor-site complications. All 15 patients were documented as ambulatory during postoperative care based on routine subjective clinical assessment; however, knee range of motion, gait, and functional status were not assessed using standardized instruments.

© 2026 Wiley Periodicals LLC.

All rights reserved, including rights for text and data mining and training of artificial intelligence technologies or similar technologies.

Conclusions: In this retrospective series, SLGA perforator flaps were used to reconstruct predominantly anterior and lateral knee soft tissue defects in propeller, bilobed, and keystone configurations. Stable wound coverage at the latest available follow-up was observed in 14 of 15 patients, with no major donor-site complications. These findings suggest that adapting flap configuration to defect characteristics may be feasible in selected patients; however, the small sample, absence of a comparison group, variable follow-up, and lack of standardized functional outcomes preclude conclusions regarding superiority, broad reliability, or general applicability.

1 | Introduction

The knee is a critical joint for maintaining the functional integrity of the lower extremity. Soft tissue defects developing in this region due to trauma, burns, tumor resection, or infection may adversely affect not only the esthetic appearance but also joint function. In particular, wound complications following total knee arthroplasty can lead to serious consequences, including prosthesis loss, deep infection, and even limb loss (Koressel et al. 2023) Therefore, achieving reliable and functional coverage of soft tissue defects around the knee remains a significant challenge in reconstructive surgery.

The gastrocnemius muscle flap has traditionally been used for reconstruction in this region; reported limitations include donor-site morbidity and contour deformity, particularly for larger defects (Taniguchi et al. 2009). Free tissue transfer, including the anterolateral thigh flap, can provide coverage for extensive or complex defects but requires microsurgical expertise and may involve longer operative times and additional donor-site morbidity (Philandrianos 2018).

The superior lateral genicular artery perforator (SLGAP) flap has been described as a local option for perigenicular soft tissue defects. The anatomical and clinical basis of the lateral genicular artery flap was described by Hayashi and Maruyama (1990) and further characterized by Spokevicius and Jankauskas (1995). Wiedner et al. (2011) reported applications for chronic ulcers, post-oncologic defects, and pressure sores. Taniguchi et al. (2009) reported a single case after total knee arthroplasty and proposed the flap as a possible alternative to muscle-based coverage.

In a review encompassing 39 reported cases, Low et al. summarized the vascular anatomy of the SLGA flap, a mean pedicle length of 7.4 cm, donor-site findings, and complications that included distal flap necrosis (Low et al. 2022). These observational data support clinical feasibility but do not provide comparative evidence regarding function, esthetics, or superiority over other reconstructive methods.

The development of perforator and local flap concepts has expanded the range of reconstructive options while aiming to limit donor-site morbidity (Mohan et al. 2016). Within this context, the SLGA flap is one of several muscle-sparing local options for soft tissue defects around the knee; its relative advantages and indications remain incompletely defined.

Although previous studies have established the anatomical basis and clinical feasibility of the SLGAP flap, most reports have focused on isolated applications or individual flap configurations. Practical guidance on selecting among propeller, bilobed, and keystone designs according to defect size, geometry, location, surrounding tissue laxity, and the required arc of movement remains limited. Therefore, the present report retrospectively describes the clinical outcomes and complications of SLGAP flap reconstruction for predominantly anterior and lateral knee soft tissue defects and seeks to describe a practical framework for configuration selection based on defect characteristics.

2 | Patients and Methods

Hospital operative logs and electronic medical records were retrospectively reviewed to identify all consecutive patients who underwent reconstruction with a superior lateral genicular artery perforator (SLGAP) flap between January 2017 and December 2025. Patients were eligible if they had a soft tissue defect around the knee following trauma, burn injury, tumor surgery or related oncologic treatment, infection, or revision arthroplasty/prosthesis-related complications; underwent reconstruction with a propeller, bilobed, or keystone SLGAP flap; and had complete hospital records and sufficient postoperative follow-up information to assess flap survival and perioperative complications. No age-based eligibility restriction was applied.

Patients were excluded if clinical records were incomplete, if follow-up information was insufficient to assess flap survival and perioperative complications, or if simultaneous reconstruction with a non-SLGA flap in the same anatomical region prevented the outcome of the SLGAP flap from being evaluated separately. Absence of extended follow-up beyond the perioperative assessment period alone was not considered an exclusion criterion. All 15 consecutive patients identified during the review period met the eligibility criteria and were included in the perioperative analysis; no patient was excluded. Extended follow-up data were available for 13 patients and unavailable for two patients, and longer-term outcomes were analyzed using the available follow-up data.

2.1 | Surgical Technique

Following debridement, the definitive dimensions and configuration of the recipient defect were assessed before flap design. On the lateral aspect of the distal thigh, the fibular head, lateral knee joint line, lateral femoral condyle, superolateral border of the patella, posterior border of the iliotibial band, and biceps femoris tendon were marked. The posterior border of the iliotibial band, the biceps femoris tendon, and

10982752, 2026, 8, Downloaded from https://onlinelibrary.wiley.com/doi/10.1002/micr.70337 by Süleyman ÇEÇEN - Bursa Uludağ University Kutuphane ve Dokumantasyon , Wiley Online Library on [08/11/2026]. See the Terms and Conditions (https://onlinelibrary.wiley.com/terms-and-conditions) on Wiley Online Library for rules of use; OA articles are governed by the applicable Creative Commons License

a line extending between the fibular head and the superolateral patellar border delineated the operative region in which the cutaneous perforator was sought. Preoperative perforator mapping was performed with handheld Doppler ultrasonography or color Doppler ultrasonography when available. The most suitable signal was selected as the provisional pivot point and was positioned toward the distal portion of the flap (Figure 1A,B).

The superior lateral genicular artery arises from the popliteal artery and courses laterally around the distal femur toward the lateral intermuscular septum. It divides into superficial (patellar) and deep (condylar) branches. One or more septocutaneous perforators from the superficial system emerge posterior to the lateral intermuscular septum and contribute to the cutaneous vascular territory of the lateral distal thigh. This anatomy constitutes the vascular basis of the SLGAP flap (Hayashi and Maruyama 1990; Spokevicius and Jankauskas 1995; Morsy et al. 2018). Because the number and exact course of the cutaneous perforators may vary, final perforator selection was based on both preoperative mapping and direct intraoperative visualization.

Flap dimensions, longitudinal orientation, and configuration were individualized according to defect size, geometry, location, available tissue laxity, perforator position, required arc of movement, and the anticipated method of donor-site closure. A propeller design was favored when greater mobility or a wider rotation arc was required for a larger anterior or lateral defect. A bilobed design was used mainly for small-to-medium anterior defects when redistribution between two lobes facilitated coverage and primary donor-site closure. A keystone configuration was considered for relatively small lateral defects with sufficient adjacent skin laxity and a limited advancement requirement. This preliminary, experience-based selection framework is summarized in Figure 2.

Flap elevation began along the anterior margin and proceeded posteriorly in the loose areolar plane immediately superficial to the iliotibial band. As the posterior border of the iliotibial band was approached, the dissection was slowed and the perforators entering the flap were identified under direct vision. Near the selected perforator, the dissection was transitioned locally to a subfascial plane; the perforator was preserved with a small cuff of surrounding tissue, and the fascia was opened carefully around it. The vessel was then followed toward the lateral intermuscular septum in the interval between the vastus lateralis anteriorly and the short head of the biceps femoris posteriorly. Pedicle dissection was continued only as far as required to obtain an adequate arc of movement and tension-free reach while avoiding traction, compression, or injury to adjacent muscular and articular branches (Figure 3).

After sufficient mobility had been achieved, the remaining flap margins were incised and the flap was islanded. The planned transfer was simulated before final inset so that pedicle length, flap reach, and the possibility of kinking or compression at the pivot point could be reassessed. Propeller flaps were rotated around the perforator according to the required direction and arc; bilobed flaps were transposed sequentially; and keystone flaps were advanced into the defect. Particular attention was paid to preventing excessive longitudinal traction when the flap was advanced or transposed rather than rotated as a propeller.

Before definitive suturing, flap perfusion was assessed clinically after temporary positioning, including skin color, capillary refill, dermal-edge bleeding, and evidence of venous congestion. The flap was inset without tension, and tight sutures or compression around the perforator were avoided. The donor site was closed primarily whenever this could be achieved without excessive tension. When complete primary closure was not feasible, the proximal portion was closed primarily and the remaining distal donor-site defect was covered with a split-thickness skin graft.

Data were collected retrospectively from hospital electronic medical records, operative reports, discharge summaries, laboratory findings, outpatient follow-up records, and the institutional clinical photography archive. Clinical photographs were reviewed to describe postoperative wound coverage and contour. Ambulatory status was determined from routine clinical documentation and subjective clinical assessment; no standardized functional assessment protocol was used.

Patient-related variables included age, sex, comorbidities (such as diabetes mellitus, hypertension, and peripheral vascular disease), smoking status, and regular medication use, including anticoagulants and immunosuppressive agents. Defect-related variables included etiology, anatomical location, and defect dimensions. Operative data included flap dimensions, flap design, surgical technique, and intraoperative findings.

Outcome measures included flap survival (complete survival, partial necrosis, or total necrosis), postoperative complications (hematoma, infection, seroma, wound dehiscence, and venous congestion), and the need for secondary surgical intervention. Ambulatory status and postoperative contour were assessed descriptively from routine clinical notes and photographs. Knee range of motion, gait parameters, validated functional or esthetic scores, and patient-reported outcome measures were not collected systematically.

Data were analyzed descriptively. Continuous variables were summarized as mean and range, whereas categorical variables were presented as counts. Because this was a single-cohort descriptive case series without a comparison group, no inferential statistical tests were performed and no *p*-values were calculated.

3 | Results

Operative record review identified 15 consecutive patients who underwent reconstruction using a superior lateral genicular artery perforator flap between January 2017 and December 2025. No patient met the exclusion criteria, and all 15 patients were included in the perioperative analysis. The mean patient age was 44.9 years (range, 13–68 years). Trauma-related defects represented the most common indication for reconstruction and accounted for nine cases, including traffic accidents, crush injuries, falls, and other traumatic mechanisms. Additional etiologies included electrical burns ($n = 2$), tumor-related defects ($n = 2$), radiation necrosis ($n = 1$), and prosthesis-related soft tissue exposure ($n = 1$).

10982752, 2026, 8, Downloaded from https://onlinelibrary.wiley.com/doi/10.1002/micr.70337 by Süleyman ÇEÇEN - Bursa Uludag University Kutuphane ve Dokumantasyon , Wiley Online Library on [08/11/2026]. See the Terms and Conditions (https://onlinelibrary.wiley.com/terms-and-conditions) on Wiley Online Library for rules of use; OA articles are governed by the applicable Creative Commons License

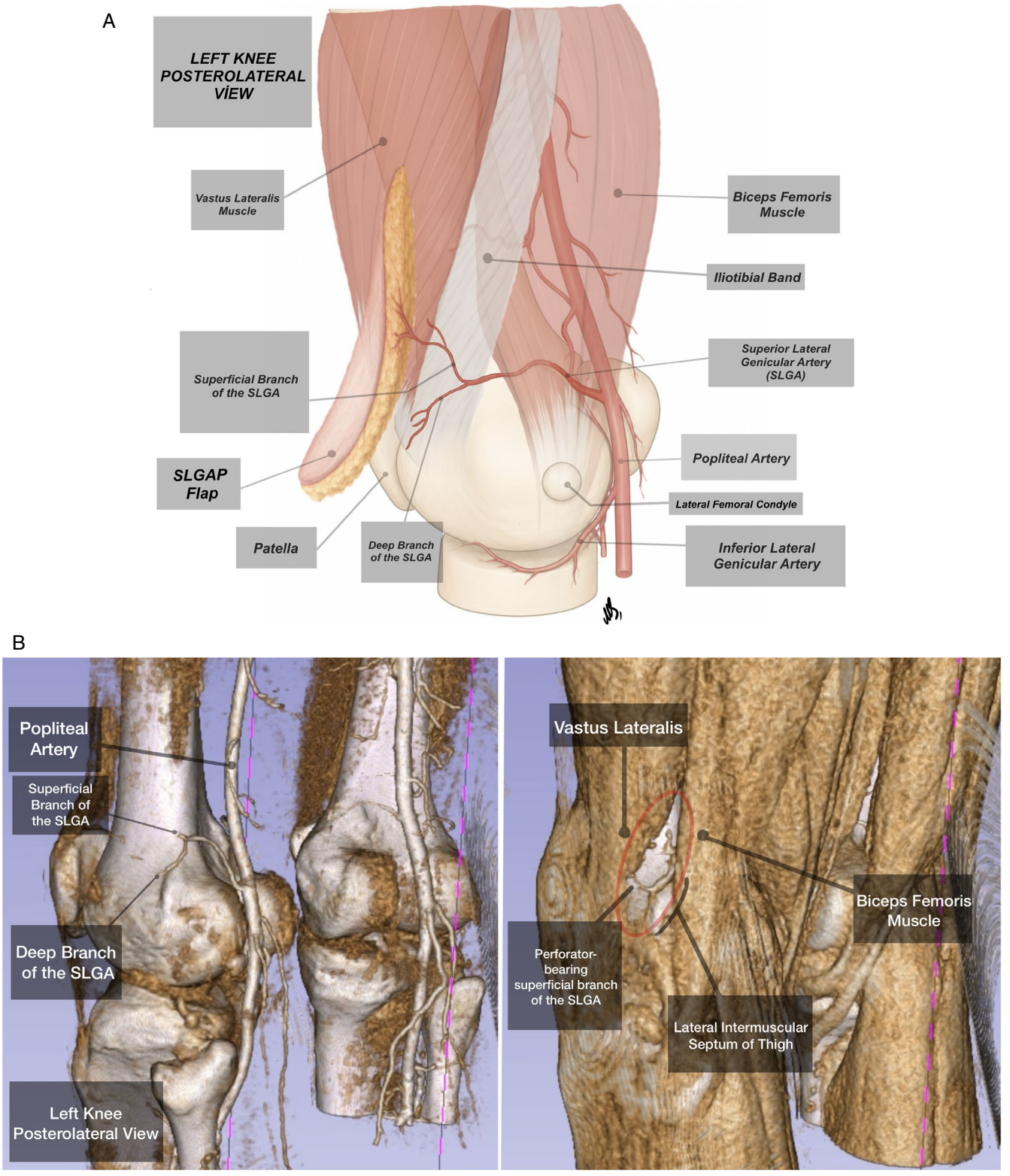

FIGURE 1 | Vascular anatomy of the superior lateral genicular artery in the left knee. (A) Schematic posterolateral view demonstrating the course of the superior lateral genicular artery (SLGA), its superficial and deep branches, and the surrounding anatomical structures. The illustrated SLGAP skin paddle is representative and does not depict a specific flap transfer, arc of rotation, or direction of rotation. (B) Patient-specific three-dimensional computed tomographic angiography reconstructions of the left knee in posterolateral view, which served as the anatomical reference for the schematic illustration. The image on the left demonstrates the popliteal artery and the superficial and deep branches of the SLGA. The image on the right demonstrates the perforator-bearing superficial branch of the SLGA coursing between the vastus lateralis and biceps femoris muscles. The red oval highlights the lateral intermuscular septum through which the perforator-bearing superficial branch courses.

10982752, 2026, 8, Downloaded from https://onlinelibrary.wiley.com/doi/10.1002/micr.70337 by Süleyman ÇEÇEN - Bursa Uludag University Kutuphane ve Dokumantasyon , Wiley Online Library on [08/11/2026]. See the Terms and Conditions (https://onlinelibrary.wiley.com/terms-and-conditions) on Wiley Online Library for rules of use; OA articles are governed by the applicable Creative Commons License

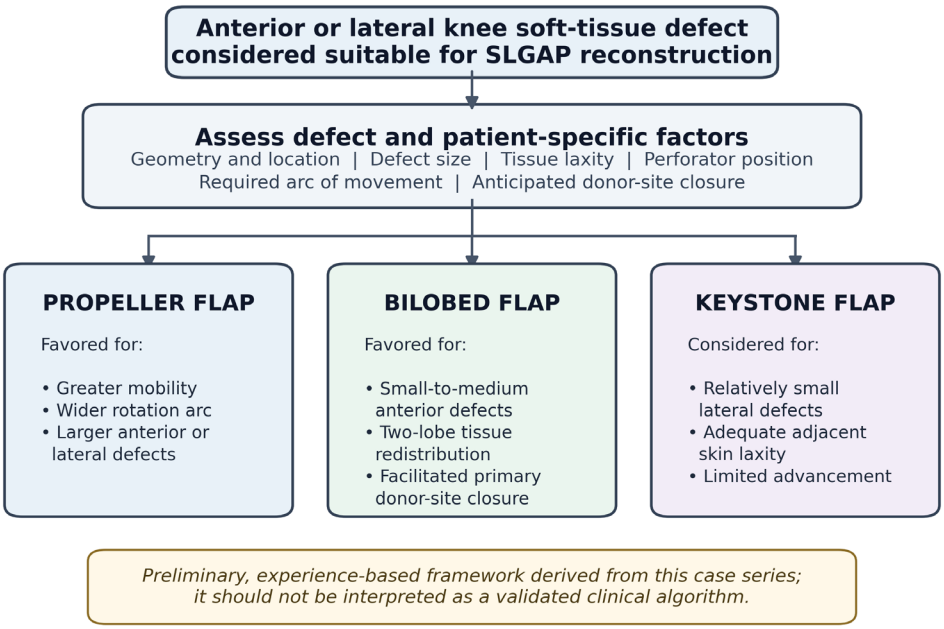

FIGURE 2 | Proposed defect-oriented framework for selection of the superior lateral genicular artery perforator (SLGAP) flap configuration. The framework considers defect geometry, location and size, tissue laxity, perforator position, required movement, and donor-site closure. Greater mobility or a wide rotation arc favors a propeller flap; a small-to-medium anterior defect benefiting from two-lobe tissue redistribution favors a bilobed flap; and a relatively small lateral defect with adequate skin laxity and limited advancement favors a keystone flap. This experience-based framework is preliminary and has not been validated.

Defects were most frequently located in the anterior patellar region ($n = 9$), followed by the lateral patellar region ($n = 5$) and the medial patellar region ($n = 1$). Detailed demographic and clinical characteristics of the patients are presented in Table 1.

The mean defect dimensions were 6.9×5.7 cm (length range, 4–15 cm; width range, 3–10 cm), and the mean flap dimensions were 14.7×7.0 cm (length range, 6–25 cm; width range, 5–10 cm). Propeller flap reconstruction was the most commonly utilized design and was performed in 10 patients. Bilobed flaps were used in four patients, whereas a keystone flap configuration was employed in one patient. Nine flaps were rotated 90°, five were rotated 180°, and the keystone flap was advanced without rotation. Representative clinical applications of the propeller, bilobed, and keystone flap configurations are shown in Figures 3–5.

Complete defect coverage was achieved in all patients during the initial reconstruction procedure, and overall flap survival was documented in 14 of 15 patients. No cases of early total flap loss were observed. Marginal flap necrosis occurred in two patients and was managed conservatively. One patient developed temporary venous congestion that resolved without surgical intervention. One propeller flap that had appeared completely viable during the early postoperative period developed delayed total necrosis approximately 5–6 days after surgery. Pedicle traction or tension related to postoperative limb movement was considered a possible contributing mechanism, although a definitive cause could not be established. The patient had an underlying rheumatic joint disease. After debridement of the necrotic flap, the defect was reconstructed with a lateral gastrocnemius muscle flap.

At the latest follow-up, stable wound coverage was achieved in 14 of 15 patients, and no major donor-site complications were encountered. Follow-up data were available for 13 patients; the mean follow-up duration was 17.4 months (range, 2–72 months). All 15 patients were documented as ambulatory during postoperative care based on routine subjective clinical assessment. This observation was not supported by objective range-of-motion measurements, gait analysis, or validated functional outcome scores.

4 | Case Reports

Case 1. A 36-year-old patient presented with a 6×5 cm anterior patellar soft-tissue defect following a traffic accident. Preoperative color Doppler ultrasonography demonstrated a suitable perforator (Figure 3A), and a 15×8 cm propeller SLGAP flap was designed accordingly (Figure 3B). Following debridement, the flap was elevated with preservation of the identified perforator (Figure 3C) and rotated through 90° to cover the defect (Figure 3D). The appearance following flap inset and donor-site closure is shown in Figure 3E. The postoperative course was uneventful, and stable coverage was maintained at late follow-up (Figure 3F). Clinical photographs obtained 5 years after reconstruction demonstrated maintained soft-tissue coverage during active knee extension (Figure 5A) and active knee flexion (Figure 5B).

Case 2. A 33-year-old patient presented with a 7×7 cm lateral patellar soft-tissue defect following an electrical burn injury. The defect and bilobed flap design are shown in Figure 4D. Reconstruction was performed using a 14×7 cm bilobed SLGAP flap with 90° rotation; the appearance following flap inset is shown in Figure 4E. The postoperative course was uneventful,

10982752, 2026, 8, Downloaded from https://onlinelibrary.wiley.com/doi/10.1002/micr.70337 by Süleyman ÇEÇEN - Bursa Uludag University Kutuphane ve Dokumantasyon , Wiley Online Library on [08/11/2026]. See the Terms and Conditions (https://onlinelibrary.wiley.com/terms-and-conditions) on Wiley Online Library for rules of use; OA articles are governed by the applicable Creative Commons License

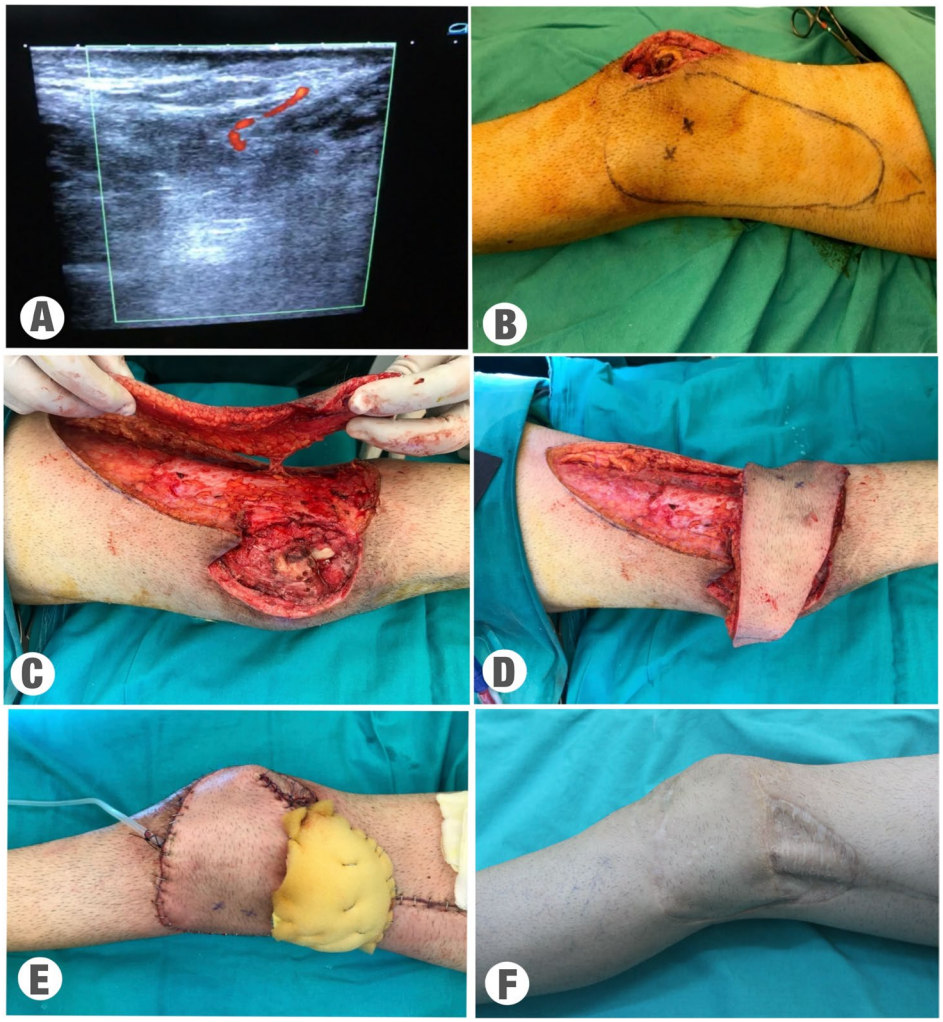

FIGURE 3 | Surgical reconstruction of an anterior patellar soft-tissue defect in Case 1 using a superior lateral genicular artery perforator (SLGAP) flap. (A) Preoperative color Doppler ultrasonography demonstrating a perforator arising from the superior lateral genicular artery. (B) Preoperative flap design based on perforator mapping and defect dimensions. (C) Subfascial flap elevation with preservation of the identified perforator following thorough debridement of the knee defect. (D) Flap transposition into the defect, demonstrating adequate arc of rotation and tension-free coverage. (E) Immediate postoperative appearance following flap inset and donor-site closure. (F) Late postoperative follow-up demonstrating complete flap survival, stable soft tissue coverage, and postoperative contour of the knee.

with complete flap survival and no flap-related complications. Stable soft-tissue coverage was maintained at the 6-month follow-up (Figure 4F).

Case 3. A 56-year-old patient presented with a 4×4 cm lateral patellar soft-tissue defect following a crush injury. The preoperative defect and keystone flap design are shown in Figure 4A. Reconstruction was performed using a 6×6 cm keystone SLGAP flap advanced into the defect, with the appearance after flap inset shown in Figure 4B. The postoperative course was uneventful, with complete flap survival and no flap-related complications. Stable soft-tissue coverage was maintained at the 4-month follow-up (Figure 4C).

5 | Discussion

Reconstruction of knee soft tissue defects must balance durable coverage, contour, donor-site morbidity, and preservation of joint function. Gastrocnemius muscle flaps remain established options, but reported limitations include bulk, donor-site morbidity, and possible effects on knee or plantar-flexion strength (Menderes et al. 2002; Suda et al. 2014; Kwiecien et al. 2016; Maniglio et al. 2024). Free tissue transfer can address larger or complex wounds but may require longer operations and more demanding recipient-vessel planning. Regional perforator options, including reverse anterolateral thigh, descending genicular artery perforator, medial sural artery perforator, and SLGAP flaps, expand the choices around the knee (Demirseren et al. 2011; Wong et al. 2013; Liu et al. 2017; Du et al. 2024; Lin et al. 2016; Yu 2004; Venkatramani et al. 2014; Zheng et al. 2015; Sananpanich et al. 2013; Hsieh et al. 2023; Chen 2025; Koh et al. 2021; Innocenti et al. 2014; Shim and Kim 2006; Luca-Pozner et al. 2020; Scaglioni et al. 2021; Narayan et al. 2022; Suba et al. 2022). Because these techniques have different vascular and technical constraints, reconstruction should be individualized according to defect and patient factors.

Anatomical and early clinical reports describe the SLGAP flap as a source of relatively thin, pliable tissue that can be used in

10982752, 2026, 8, Downloaded from https://onlinelibrary.wiley.com/doi/10.1002/micr.70337 by Süleyman ÇEÇEN - Bursa Uludag University Kutuphane ve Dokumantasyon , Wiley Online Library on [08/11/2026]. See the Terms and Conditions (https://onlinelibrary.wiley.com/terms-and-conditions) on Wiley Online Library for rules of use; OA articles are governed by the applicable Creative Commons License

TABLE 1 | Demographic and clinical characteristics of patients undergoing superior lateral genicular artery flap reconstruction.

Pt.	Age	Etiology	Defect location	Defect size (cm)	Flap size (cm)	Rotation arc	Flap design	Complication	Follow-up (months)
1	53	Traffic accident	Anterior patellar	8×6	12×8	90°	Propeller	Marginal necrosis	3
2	36	Traffic accident	Anterior patellar	6×5	15×8	90°	Propeller	None	4
3	40	Electrical burn	Anterior patellar	12×10	25×10	180°	Propeller	None	72
4	53	Traffic accident	Lateral patellar	5×3	20×6	180°	Propeller	Marginal necrosis	24
5	60	Fall injury	Anterior patellar	15×7	18×8	90°	Propeller	None	4
6	22	Traffic accident	Anterior patellar	5×5	15×5	180°	Propeller	Temporary venous congestion	60
7	33	Electrical burn	Lateral patellar	7×7	14×7	90°	Bilobed	None	6
8	56	Crush injury	Lateral patellar	4×4	6×6	Advancement	Keystone	None	4
9	13	Radiation necrosis	Lateral patellar	5×5	15×5	180°	Propeller	None	36
10	65	Tumor excision	Medial patellar	4×3	7×6	90°	Bilobed	None	NA
11	43	Prosthesis-related exposure	Lateral patellar	5×6	18×9	180°	Propeller	Late flap necrosis requiring lateral gastrocnemius flap	NA
12	68	Tumor resection	Anterior patellar	6×6	16×6	90°	Bilobed	None	2
13	33	Trauma	Anterior patellar	7×5	15×6	90°	Bilobed	None	2.5
14	47	Trauma	Anterior patellar	8x7	13x8	90	Propeller	None	5
15	52	Traffic Accident	Lateral Patellar	6x7	12x7	90	Propeller	None	4

Note: Defect and flap sizes are presented as length×width (cm). NA indicates that extended follow-up data were unavailable (Patients 10 and 11). Functional status: All 15 patients were documented as ambulatory during routine postoperative care based on clinical assessment. This observation does not represent a standardized final functional outcome assessment. Knee range of motion, gait parameters, and validated functional outcome scores were not systematically assessed.

10982752, 2026, 8, Downloaded from https://onlinelibrary.wiley.com/doi/10.1002/micr.70337 by Süleyman ÇEÇEN - Bursa Uludag University Kuruphane ve Dokumantasyon , Wiley Online Library on [08/11/2026]. See the Terms and Conditions (https://onlinelibrary.wiley.com/terms-and-conditions) on Wiley Online Library for rules of use; OA articles are governed by the applicable Creative Commons License

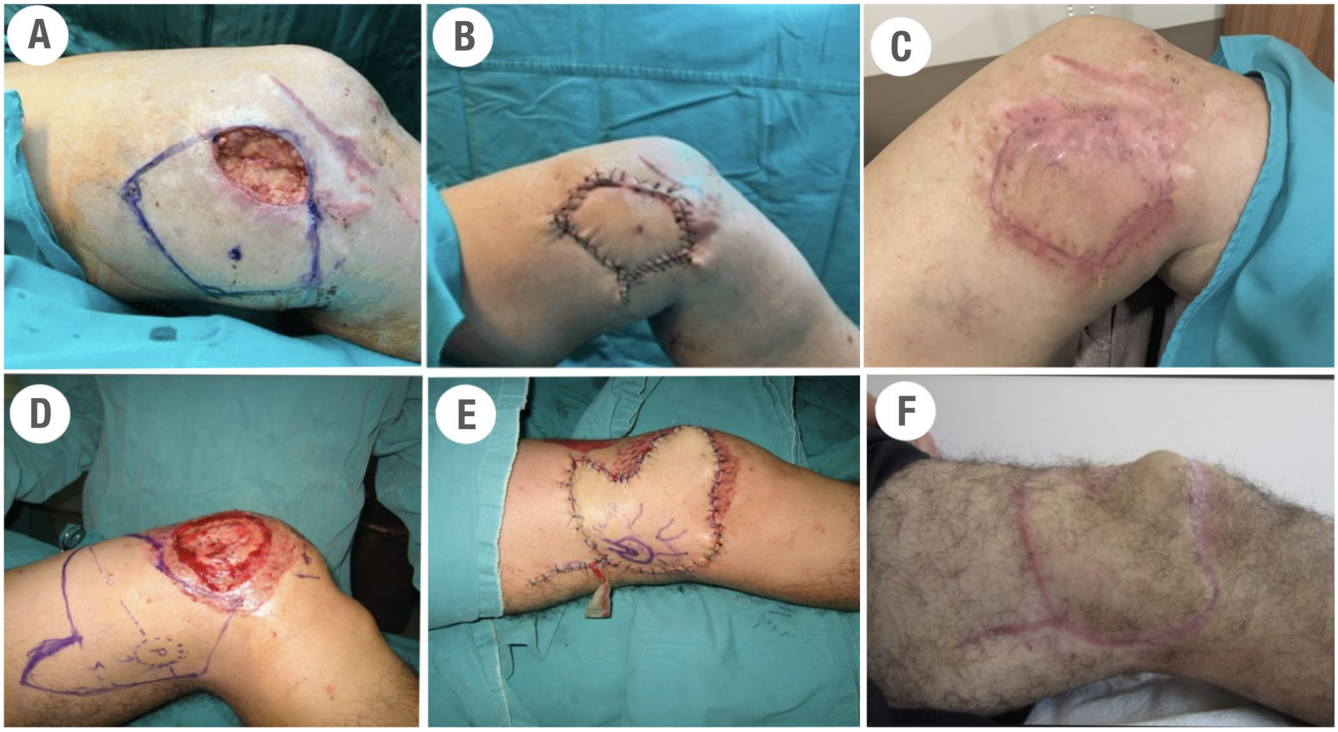

FIGURE 4 | Clinical applications of the superior lateral genicular artery perforator (SLGAP) flap in keystone and bilobed configurations. (A) Preoperative lateral patellar defect following a crush injury and keystone flap markings (Case 3). (B) Appearance immediately after keystone flap advancement and inset. (C) Four-month postoperative appearance demonstrating stable soft-tissue coverage. (D) Preoperative lateral patellar defect following an electrical burn and bilobed flap markings (Case 2). (E) Appearance immediately after bilobed flap transfer and inset. (F) Six-month postoperative appearance demonstrating stable soft-tissue coverage.

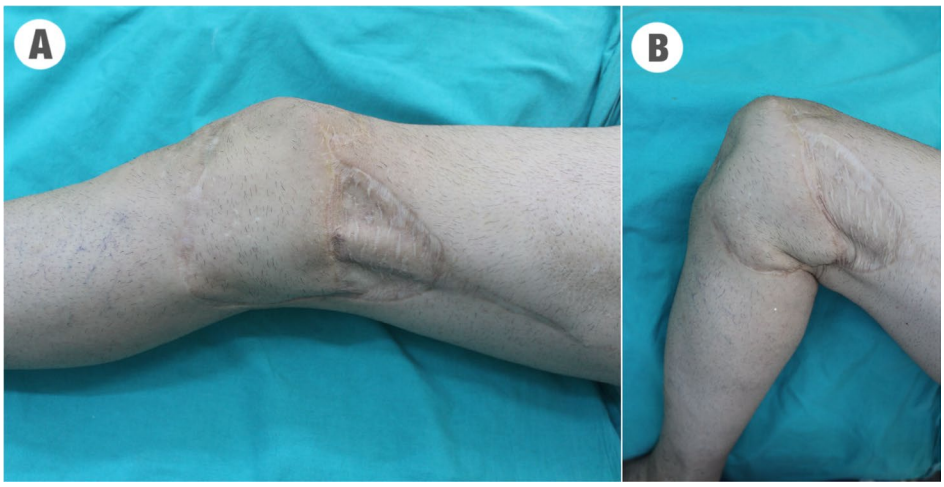

FIGURE 5 | Late postoperative appearance of Case 1 at 5 years after propeller SLGAP flap reconstruction. Stable soft-tissue coverage during active knee extension (A) and active knee flexion (B).

pedicled, propeller, bilobed, advancement, or free-flap configurations (Taniguchi et al. 2009; Hayashi and Maruyama 1990; Spokevicius and Jankauskas 1995; Wiedner et al. 2011; Low et al. 2022; Morsy et al. 2018; Nguyen et al. 2011; Moktader et al. 2010; Gstoettner et al. 2019; Parvizi et al. 2016; Enzinger et al. 2018; Çeçen et al. 2025). Published applications include trauma-, prosthesis-, tumor-, and burn-related defects. These reports support anatomical feasibility but remain largely observational and involve small samples; distal tissue loss and venous congestion have also been reported. Accordingly, the existing literature does not establish comparative superiority or uniform predictability across patients and institutions.

The specific contribution of this report is the description, rather than validation, of a defect-oriented approach for choosing among propeller, bilobed, and keystone configurations within the same perforator territory. Configuration selection considered defect geometry and location, surrounding tissue laxity, perforator position, required arc of movement, and anticipated donor-site closure rather than defect area alone. Because the

10982752, 2026, 8, Downloaded from https://onlinelibrary.wiley.com/doi/10.1002/micr.70337 by Süleyman ÇEÇEN - Bursa Uludag University Kutuphane ve Dokumantasyon , Wiley Online Library on [08/11/2026]. See the Terms and Conditions (https://onlinelibrary.wiley.com/terms-and-conditions) on Wiley Online Library for rules of use; OA articles are governed by the applicable Creative Commons License

series was small and included only one keystone flap, this approach should be regarded as preliminary practical guidance rather than a validated algorithm.

In practical terms, propeller flaps were selected when greater mobility and a wider rotation arc were needed, particularly for larger anterior or lateral defects. Bilobed flaps were used for small- to medium-sized anterior defects when distributing tissue movement across two lobes facilitated coverage and primary donor-site closure. The keystone design was used in one relatively small lateral defect with sufficient adjacent skin laxity and a limited advancement requirement. These choices reflect our experience in this series and should not be extrapolated beyond similar defects without further evaluation.

Several technical considerations were common across configurations. Flap planning followed definitive debridement so that flap dimensions reflected the final defect. In this series, the perforator was identified at a mean position of 5.3 cm proximal and 5.0 cm lateral to the superolateral border of the patella, which served as the reference point for both measurements. Doppler mapping related perforator position to both the defect and the proposed skin paddle. Subfascial elevation, careful perforator preservation, and sufficient mobilization were used to avoid excessive longitudinal tension or pedicle compression. Perfusion was reassessed clinically with the flap in its intended position before final inset. These steps represent practical observations rather than formally tested determinants of outcome.

The observed complications informed our technical caution. The two cases of marginal necrosis, both managed conservatively, reinforced the importance of avoiding excessive tension at the distal margin and of accounting for the tissue required for inset rather than basing flap dimensions on the defect alone. The transient venous congestion emphasized inspection of the pedicle after transfer and avoidance of compression during inset. The initially viable propeller flap that developed delayed total necrosis approximately 5–6 days after surgery raised concern for pedicle traction or tension related to postoperative movement. However, because the patient also had an underlying rheumatic joint disease and only one delayed loss occurred, a causal association cannot be established. Salvage with a lateral gastrocnemius muscle flap indicates that early viability should not be equated with durable survival and that a secondary reconstructive option may still be required. Because the number of events was small, no association between flap configuration, rotation arc, comorbidity, and complications can be inferred.

Within this series, use of propeller, bilobed, and keystone SLGAP flaps for selected anterior and lateral knee defects suggests technical feasibility rather than comparative advantage. Although all patients were documented as ambulatory during postoperative care, this was based on routine subjective clinical assessment; knee range of motion, gait, validated functional scores, and patient-reported outcomes were not measured systematically. This case series had no control group or standardized esthetic assessment, follow-up varied from 2 to 72 months, and extended follow-up data were unavailable for two patients. The small retrospective cohort and limited anatomical distribution further restrict generalizability and may have led to underestimation of late adverse events.

6 | Conclusion

In this retrospective case series of 15 patients, superior lateral genicular artery perforator flaps provided stable coverage in 14 patients with predominantly anterior and lateral knee soft-tissue defects. Selection among propeller, bilobed, and keystone configurations based on defect characteristics may be feasible in selected patients; however, the small sample, absence of a comparison group, and lack of standardized functional outcome measures limit broader conclusions.

Author Contributions

Süleyman Çeçen: conceptualization, methodology, supervision, project administration, writing – review and editing. **Burak Özkan:** conceptualization, methodology, investigation, supervision, writing – review and editing. **Mehmet Ali Şahin:** conceptualization, data curation, formal analysis, visualization, writing – original draft, writing – review and editing. **Menekşe Kastamoni Başkan:** investigation, data curation, validation, writing – review and editing. **Çağrı Ahmet Uysal:** methodology, validation, supervision, writing – review and editing. All authors reviewed and approved the final version of the manuscript and agree to be accountable for their respective contributions to the work.

Funding

The authors have nothing to report.

Ethics Statement

The protocol for this retrospective case series was reviewed and approved by the Bursa Uludağ University Health Research Ethics Committee (Approval No: 2025/849115-40).

Consent

Written informed consent was obtained from all patients included in this case series.

Conflicts of Interest

The authors declare no conflicts of interest.

Data Availability Statement

The data that support the findings of this study are available on request from the corresponding author. The data are not publicly available due to privacy or ethical restrictions.

References

Çeçen, S., K. Kavruk, and S. Akın. 2025. "Heel Reconstruction With Free Superior Lateral Genicular Artery Perforator Flap." *Turkish Journal of Plastic Surgery* 33, no. 4: 188–190. https://doi.org/10.4103/tjps.tjps_19_25.

Chen, C. E. 2025. "Potential of a Genicular Artery Perforator Keystone Flap for the Reconstruction of Defects in the Knee to the Upper Third of the Leg." *Annals of Plastic Surgery* 94, no. 3S: S38–S43. https://doi.org/10.1097/SAP.0000000000004188.

Demirseren, M. E., K. Efendioglu, C. O. Demiralp, K. Kilicarslan, and H. Akkaya. 2011. "Clinical Experience With a Reverse-Flow Anterolateral Thigh Perforator Flap for the Reconstruction of Soft-Tissue Defects of the Knee and Proximal Lower Leg." *Journal of Plastic, Reconstructive*

10982752, 2026, 8, Downloaded from https://onlinelibrary.wiley.com/doi/10.1002/micr.70337 by Süleyman ÇEÇEN - Bursa Uludag University Kutuphane ve Dokumantasyon , Wiley Online Library on [08/11/2026]. See the Terms and Conditions (https://onlinelibrary.wiley.com/terms-and-conditions) on Wiley Online Library for rules of use; OA articles are governed by the applicable Creative Commons License

& Aesthetic Surgery 64, no. 12: 1613–1620. https://doi.org/10.1016/j.bjps.2011.06.047.

Du, Q., Y. Liu, M. Zang, et al. 2024. "Distally Based Anterolateral Thigh Flap Algorithm for Unexpected Situations During Soft-Tissue Defect Reconstruction Around the Knee." *Plastic and Reconstructive Surgery* 153, no. 3: 728–738. https://doi.org/10.1097/PRS.0000000000010814.

Enzinger, S., H. Bürger, and A. Gaggl. 2018. "Reconstruction of the Mandibular Condyle Using the Microvascular Lateral Femoral Condyle Flap." *International Journal of Oral and Maxillofacial Surgery* 47, no. 5: 603–607. https://doi.org/10.1016/j.ijom.2017.12.002.

Gstoettner, C., J. A. Mayer, M. Aman, et al. 2019. "Cutaneous Angiosome of the Chimeric SLGA Perforator Flap: Anatomical Study and Clinical Considerations." *Journal of Plastic, Reconstructive & Aesthetic Surgery* 72, no. 7: 1142–1149. https://doi.org/10.1016/j.bjps.2019.02.016.

Hayashi, A., and Y. Maruyama. 1990. "The Lateral Genicular Artery Flap." *Annals of Plastic Surgery* 24, no. 4: 310–317. https://doi.org/10.1097/00000637-199004000-00003.

Hsieh, Y., D. Kalmin, M. I. Motoroko, M. Morsi, and A. Morsi. 2023. "Reconstructing Complex Peripatellar Defects Using the Descending Genicular Artery Perforator Flap." *ANZ Journal of Surgery* 93, no. 7–8: 1950–1956. https://doi.org/10.1111/ans.18560.

Innocenti, M., E. Cardin-Langlois, G. Menichini, and C. Baldrighi. 2014. "Gastrocnaemius-Propeller Extended Miocutanous Flap: A New Chimaeric Flap for Soft Tissue Reconstruction of the Knee." *Journal of Plastic, Reconstructive & Aesthetic Surgery* 67, no. 2: 244–251. https://doi.org/10.1016/j.bjps.2013.10.011.

Koh, K., Y. Kong, M. L. Loh, Y. Wu, and C. H. Pek. 2021. "Free-Style Approach to the Pedicled Lower Medial Thigh Perforator Flap." *Plastic and Reconstructive Surgery* 9, no. 10: e3848. https://doi.org/10.1097/GOX.0000000000003848.

Koressel, J., B. A. Perez, G. T. Minutillo, C. B. Granruth, S. Mastrangelo, and G. C. Lee. 2023. "Wound Complications Following Revision Total Knee Arthroplasty: Prevalence and Outcomes." *Knee* 42: 44–50. https://doi.org/10.1016/j.knee.2023.02.011.

Kwiecien, G. J., G. Lamaris, B. B. Gharb, et al. 2016. "Long-Term Outcomes of Total Knee Arthroplasty Following Soft-Tissue Defect Reconstruction With Muscle and Fasciocutaneous Flaps." *Plastic and Reconstructive Surgery* 137, no. 1: 177e–186e. https://doi.org/10.1097/PRS.0000000000001929.

Lin, C., J. Zelken, C. Hsu, C. Lin, and F. Wei. 2016. "The Distally Based, Venous Supercharged Anterolateral Thigh Flap." *Microsurgery* 36, no. 1: 20–28. https://doi.org/10.1002/micr.22380.

Liu, Y., Q. Ding, M. Zang, et al. 2017. "Classification and Application of the Distally-Based Thigh Flap Based on the Lateral Circumflex Femoral Artery System." *Annals of Plastic Surgery* 78, no. 5: 497–504. https://doi.org/10.1097/SAP.0000000000000946.

Low, O. W., T. F. Loh, H. Lee, et al. 2022. "The Superior Lateral Genicular Artery Flap for Reconstruction of Knee and Proximal Leg Defects." *Archives of Plastic Surgery* 49, no. 01: 108–114. https://doi.org/10.5999/aps.2021.01123.

Luca-Pozner, V., A. Delgove, N. Kerfant, A. Karra, C. Herlin, and B. Chaput. 2020. "Medial Sural Artery Perforator Flap for Leg and Knee Coverage: Extended Skin Paddle With 2 Perforators." *Annals of Plastic Surgery* 85, no. 6: 650–655. https://doi.org/10.1097/SAP.0000000000002356.

Maniglio, M., M. Maruccia, M. Morandi, et al. 2024. "Comparisons of the Morbidities of a Double Gastrocnemius Flap and a Medial Gastrocnemius Flap in the Orthoplastic Reconstruction Around the Knee." *Microsurgery* 44, no. 1: e31114. https://doi.org/10.1002/micr.31114.

Menderes, A., C. Demirdover, M. Yilmaz, H. Vayvada, and A. Barutcu. 2002. "Reconstruction of Soft Tissue Defects Following Total Knee Arthroplasty." *Knee* 9, no. 3: 215–219. https://doi.org/10.1016/S0968-0160(02)00010-8.

Mohan, A. T., Y. J. Sur, L. Zhu, et al. 2016. "The Concepts of Propeller, Perforator, Keystone, and Other Local Flaps and Their Role in the Evolution of Reconstruction." *Plastic and Reconstructive Surgery* 138, no. 4: 710e–729e. https://doi.org/10.1097/PRS.0000000000002610.

Moktader, M. A. A., M. Hassan, E. Taman, A. Taha, and S. Elawa. 2010. "Lateral Superior Genicular Flap for Reconstruction Around the Knee." *Egyptian Journal of Plastic and Reconstructive Surgery* 34, no. 2: 223–226.

Morsy, M., Y. J. Sur, O. Akdag, et al. 2018. "Anatomic and High-Resolution Computed Tomographic Angiography Study of the Lateral Femoral Condyle Flap: Implications for Surgical Dissection." *Journal of Plastic, Reconstructive & Aesthetic Surgery* 71, no. 1: 33–43. https://doi.org/10.1016/j.bjps.2017.08.012.

Narayan, N., J. E. Berner, A. Saeed, F. Zanchetta, and L. Troisi. 2022. "Outcomes of the Pedicled Medial Sural Artery Perforator Flap for Soft Tissue Reconstruction Around the Knee: When to Use It and How to Look After It." *Journal of Hand and Microsurgery* 14, no. 3: 216–221. https://doi.org/10.1055/s-0040-1715919.

Nguyen, A. T., C. Wong, A. Mojallal, and M. Saint-Cyr. 2011. "Lateral Supragenicular Pedicle Perforator Flap: Clinical Results and Vascular Anatomy." *Journal of Plastic, Reconstructive & Aesthetic Surgery* 64, no. 3: 381–385. https://doi.org/10.1016/j.bjps.2010.05.029.

Parvizi, D., A. Vasilyeva, P. Wurzer, et al. 2016. "Anatomy of the Vascularized Lateral Femoral Condyle Flap." *Plastic and Reconstructive Surgery* 137, no. 6: 1024e–1032e. https://doi.org/10.1097/PRS.0000000000002182.

Philandrianos, C. 2018. "Free Antero-Lateral Thigh Flap for Total Knee Prosthesis Coverage After Infection Complicating Malignant Tumour Resection." *Orthopaedics & Traumatology, Surgery & Research: OTSR* 104, no. 5: 713–717. https://doi.org/10.1016/j.otsr.2018.05.006.

Sananpanich, K., P. Atthakomol, S. Luevitoonvechkij, and J. Kraisarin. 2013. "Anatomical Variations of the Saphenous and Descending Genicular Artery Perforators: Cadaveric Study and Clinical Implications for Vascular Flaps." *Plastic and Reconstructive Surgery* 131, no. 3: 363e–372e. https://doi.org/10.1097/PRS.0b013e31827c7067.

Scaglioni, M. F., T. Rodi, and E. Fritsche. 2021. "The Versatility of the Pedicled Medial Sural Artery Perforator Flap: From Simple to Its Chimeric Pattern and Clinical Experience With 37 Cases." *Plastic and Reconstructive Surgery* 147, no. 4: 960–969. https://doi.org/10.1097/PRS.0000000000007795.

Shim, J. S., and H. H. Kim. 2006. "A Novel Reconstruction Technique for the Knee and Upper One Third of Lower Leg." *Journal of Plastic, Reconstructive & Aesthetic Surgery* 59, no. 9: 919–926. https://doi.org/10.1016/j.bjps.2006.01.025.

Spokevicius, S., and A. Jankauskas. 1995. "Anatomy and Clinical Applications of a Composite Cutaneo-Subcutaneous Flap Based on the Lateral Superior Genicular Vessels." *Journal of Reconstructive Microsurgery* 11, no. 1: 15–20. https://doi.org/10.1055/s-2007-1006505.

Suba, S., S. K. Giri, P. Pant, and A. Kanungo. 2022. "Versatility of Medial Sural Artery Islanded Pedicled Perforator Flap for Resurfacing Areas Around the Knee." *Annals of Plastic Surgery* 88, no. 6: 647–657. https://doi.org/10.1097/SAP.0000000000003057.

Suda, A. J., A. Cieslik, P. A. Grützner, M. Münzberg, and V. Heppert. 2014. "Flaps for Closure of Soft Tissue Defects in Infected Revision Knee Arthroplasty." *International Orthopaedics* 38, no. 7: 1387–1392. https://doi.org/10.1007/s00264-014-2316-z.

Taniguchi, Y., T. Kitano, T. Shimoe, Y. Asai, and M. Yoshida. 2009. "Superior Lateral Genicular Artery Flap for Coverage of a Soft Tissue Defect After Total Knee Arthroplasty." *Journal of Reconstructive Microsurgery* 25, no. 08: 479–482. https://doi.org/10.1055/s-0029-1234026.

10982752, 2026, 8, Downloaded from https://onlinelibrary.wiley.com/doi/10.1002/micr.70337 by Süleyman ÇEÇEN - Bursa Uludağ University Kutuphane ve Dokumantasyon , Wiley Online Library on [08/11/2026]. See the Terms and Conditions (https://onlinelibrary.wiley.com/terms-and-conditions) on Wiley Online Library for rules of use; OA articles are governed by the applicable Creative Commons License

Venkatramani, H., S. R. Sabapathy, and S. Nayak. 2014. "Free-Flap Cover of Complex Defects Around the Knee Using the Descending Genicular Artery as the Recipient Pedicle." *Journal of Plastic, Reconstructive & Aesthetic Surgery* 67, no. 1: 93–98. https://doi.org/10.1016/j.bjps.2013.09.011.

Wiedner, M., H. Koch, and E. Scharnagl. 2011. "The Superior Lateral Genicular Artery Flap for Soft-Tissue Reconstruction Around the Knee: Clinical Experience and Review of the Literature." *Annals of Plastic Surgery* 66, no. 4: 388–392. https://doi.org/10.1097/SAP.0b013e3181e37627.

Wong, C. H., T. Goh, B. K. Tan, and Y. S. Ong. 2013. "The Anterolateral Thigh Perforator Flap for Reconstruction of Knee Defects." *Annals of Plastic Surgery* 70, no. 3: 337–342. https://doi.org/10.1097/SAP.0b013e318234e8e2.

Yu, P. 2004. "Characteristics of the Anterolateral Thigh Flap in a Western Population and Its Application in Head and Neck Reconstruction." *Head & Neck* 26, no. 9: 759–769. https://doi.org/10.1002/hed.20050.

Zheng, H., Y. Zhuang, J. Lin, et al. 2015. "Revisit of the Anatomy of the Distal Perforator of the Descending Genicular Artery and Clinical Application of Its Perforator "Propeller" Flap in the Reconstruction of Soft Tissue Defects Around the Knee." *Microsurgery* 35, no. 5: 370–379. https://doi.org/10.1002/micr.22340.

10982752, 2026, 8, Downloaded from https://onlinelibrary.wiley.com/doi/10.1002/micr.70337 by Süleyman ÇEÇEN - Bursa Uludag University Kutuphane ve Dokumantasyon , Wiley Online Library on [08/11/2026]. See the Terms and Conditions (https://onlinelibrary.wiley.com/terms-and-conditions) on Wiley Online Library for rules of use; OA articles are governed by the applicable Creative Commons License