Kafkas Universitesi Veteriner Fakultesi Dergisi
Journal Home-Page: http://vetdergikafkas.org
E-ISSN: 1309-2251

Kafkas Univ Vet Fak Derg
30 (6): 821-826, 2024
DOI: 10.9775/kvfd.2024.32935

Case Report

Topical Xenogeneic Exosome Therapy in a Dog with Toxic Epidermal Necrolysis

Zeki YILMAZ [1 (*)] Tuğba VARLIK [1] Pınar LEVENT KARABARUT [2] Şebnem ÜNLÜİŞLER [3] Serli CANİKYAN [3]

[1] Department of Internal Medicine, Bursa Uludag University, Veterinary Faculty, TR-16059 Bursa - TÜRKİYE
[2] VetPlanet, Private Small Animal Clinic, TR-16145 Nilüfer, Bursa - TÜRKİYE
[3] Mage Group, Biotechnology Company, London, UNITED KINGDOM

[(*)] **Corresponding authors:**
Zeki YILMAZ

Phone: +90 224 294 0809
Fax: +90 224 294 0873

E-mail: zyilmaz@uludag.edu.tr

How to cite this article?

Yılmaz Z, Varlık T, Levent Karabarut P, Ünlüişler Ş, Canikyan S: Topical xenogeneic exosome therapy in a dog with toxic epidermal necrolysis. *Kafkas Univ Vet Fak Derg,* 30 (6): 821-826, 2024.
DOI: 10.9775/kvfd.2024.32935

Article ID: KVFD-2024-32935
Received: 05.09.2024
Accepted: 28.10.2024
Published Online: 12.11.2024

Abstract

This report describes a positive outcome of topical exosome therapy for toxic epidermal necrolysis (TEN) in a dog. Enrofloxacin was administered subcutaneously one day before and for 7 days after the surgery for urolithiasis. Fourteen days after discontinuing the treatment, the dog was presented to the clinic for disseminated superficial tissue loss in the dorsal region which is associated with adverse drug reaction based on the scores for assessment of drug causality for epidermal necrolysis. Bovine-derived cord blood exosome was applied in the dose of 1 million/kg, twice a day, with intradermal and spraying routes to multiple points around the wound. The dog was monitored weekly, and complete recovery was observed 58 days after treatment. This report shows that topical xenogeneic exosome may be an alternative treatment approach for wound healing in dogs.

Keywords: Dogs, Enrofloxacin, Exosome, Toxic epidermal necrolysis

Introduction

Toxic epidermal necrolysis (TEN) is a life-threatening immune-mediated skin reaction most often triggered by particular medications. Stevens-Johnson syndrome (SJS) and TEN are on the same spectrum and are clinically distinguished by the percentage of body surface area detached. In humans and dogs, SJS, SJS/TEN, or TEN is characterized by more than 10%, 10-30%, and 30% skin detachment of the total body surface area, respectively. Although there is no definitive information on TEN pathophysiology, the activation of T cells in response to a drug or infection and the subsequent development of epidermal necrosis is emphasized [1]. ALDEN score, the algorithm of drug causality for epidermal necrolysis, describes SJS/TEN in humans [2] and dogs [3].

Enrofloxacin is a fluoroquinolone antibiotic used widely in veterinary medicine due to its potent Gram-positive and Gram-negative activity; however, it is more toxic to eukaryotic cells than many other groups of antibiotics [4]. Enrofloxacin administration may inhibit cell proliferation, decrease metabolic activity, negatively affect the bone marrow, and result in tissue necrosis [5]. Enrofloxacin can also induce an inflammatory response at the injection site and affect the cell count and protein levels of the immune system [6].

Exosomes are nano-sized bio-vesicles released into surrounding body fluids upon the fusion of multivesicular bodies and the plasma membrane. They were shown to carry cell-specific cargos of proteins, lipids, and genetic materials, and can be selectively taken up by neighboring or distant cells far from their release, reprogramming the recipient cells upon their bioactive compounds. The native role of extracellular vesicles in mediating the transfer of biomolecules between cells has raised the possibility of

This article is licensed under a Creative Commons Attribution-NonCommercial 4.0 International License (CC BY-NC 4.0)

using them as therapeutic vehicles. Exosomes reflect the biophysical features of mesenchymal stem cells (MSCs) and are considered more effective than MSCs themselves. Exosomes have many beneficial effects on skin care as they contain various biological molecules that can help promote skin repair and regeneration [7,8].

Case reports and controlled studies are needed to assess whether exosome application could be an alternative treatment approach in dogs and cats. Thus, herein, a successful result of topical exosome treatment in a dog with TEN following subcutaneous enrofloxacin administration was presented.

Case History

Written informed consent was obtained from the owner for the participation of the animal in this study. An 8-year-old, male, 12 kg body weight, sterile Cavalier King Charles Spaniel was brought to a private clinic on 23.09.2023 with the complaint of inability to urinate. Physical examination did not reveal specific signs except pain in response to abdominal palpation *(Table 1)*. Complete blood count (CBC) (Mindray 2800Vet) and serum biochemistry profile (FujiFilm Dri-Chem 4000i) were within their references (data not shown). Subsequently, 14 stones obstructing the urethra were detected by the abdominal radiography. The patient was considered to be suitable for inhalation anesthesia and abdominal surgery based on the pre-operative evaluation for anesthesia. Stones in the urethra were successfully removed with the surgery (24.09.2023).

The patient was administered 1 mL enrofloxacin (Baytril-K 5%, 50 ml, Flacon, Bayern, Istanbul/ Türkiye) subcutaneously for 7 days and 1.5 mL meloxicam (Bavet Meloxicam, 20 mL, Flacon, Bavet, Istanbul/ Türkiye) for 3 days. The dog was discharged after 6 days (30.09.2023)

Table 1. *Some physical and hematological test results before and 58 days after the topical exosome treatment in the dog*

Parameter	Pre-exosome Treatment	Post-exosome Treatment	Reference Range [12]
Temperature °C	39.2	39.0	37.2-39.3
Heart rate bpm	136	132	100-140
Respiration rpm	22	20	<20
Capillary re-filling time sec	1	1	<1
WBC x10^9/L	18.1	9.0	6.0-15.0
Lymphocyte x10^9/L	2.2	1.9	1.0-4.8
Monocyte x10^9/L	0.5	0.3	0.2-1.4
Eosinophils x10^9/L	0.70	0.33	0.1-1.2
Granulocyte x10^9/L	15.4	6.8	3.0-11.5
Erythrocyte x10^{12}/L	6.7	5.93	5.5-8.5
Hemoglobin g/dL	13.1	10.9	12.0-18.0
Hematocrit %	43.3	37.7	37.0-55.0
MCHC g/dL	31.2	28.9	30.0-38.0
MCV fL	65.6	63.6	60.0-77.0
MCH pg	19.9	18.3	19.5-24.5
RDW %	13.3	15.0	12.0-14.9
Platelets x10^9/L	191	151	200-500
MPV fL	9.4	9.6	8.0-14.1
PDW %	18.1	17.4	12.0-17.5
PCT %	0.11	0.144	0.14-0.46

Table 2. *Some biochemical parameters before and 58 days after the topical exosome treatment in the dog*

Parameters	Pre-exosome Treatment	Post-exosome Treatment	Reference Range [12]
ALP IU/L	496	120	20-60
ALT IU/L	180	41	15-60
BUN mg/dL	10.9	13.7	9-29
Creatinine mg/dL	0.63	0.71	0.4-1.4
Glucose mg/dL	133	110	75-128
TP g/dL	6.8	6.8	5.8-7.3

ALP: Alkalen phosphatase, ALT: Alaline aminotransferase, BUN: Blood ure nitrogen, TP: Total protein

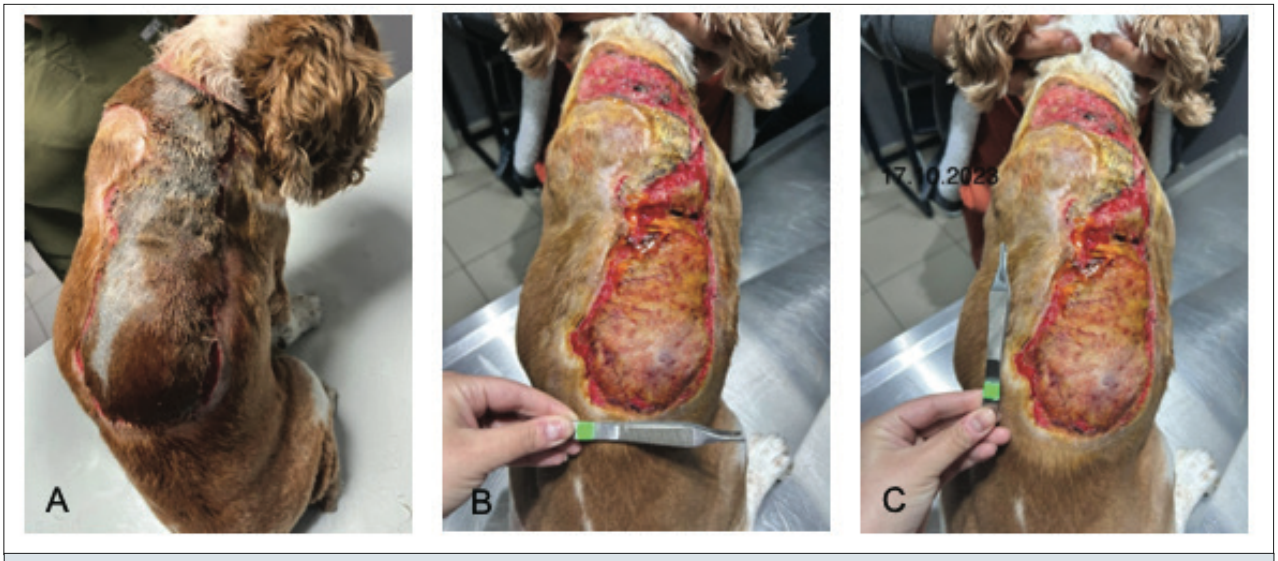

Fig 1. Following the enrofloxacin injection on day 5, the dog was presented to the clinic with the complaint of rigid and crusted swelling on his back (A). The dog was sedated for cleaning necrotized areas, showing a wound with extensive tissue loss (B and C). TEN was diagnosed based on the epidermal necrolysis of the skin surface covering more than 30% of the body



Fig 2. Monitoring of treatment effectiveness before (A) and 1 week (B), 2 weeks (C), 3 weeks (D), 5 weeks (E), 7 weeks (F), 8 weeks (G), and 9 weeks after topical exosome application in a CKCS dog with epidermal necrolysis due to enrofloxacin injection. In the last examination (H), full epithelization was achieved, and treatment was ceased

with the urethral catheter removed. On 14.10.2023, the patient was brought back to the clinic with the complaint of swelling and pruritis on his back where the area was rigid and crusted on palpation *(Fig. 1-A)*. The CBC and serum biochemistry panel showed slightly elevated leukocytes, eosinophils, alkaline phosphatase (ALP), alanine aminotransferase (ALT), and glucose *(Table 1, Table 2)*, compared to their references [9].

The patient was hospitalized and topical standard treatments were applied for 5 days, using an antiseptic solution (Chlorhexidine, Crystaline^{R} solution, Animal Health, Türkiye) to prevent the dog from secondary bacterial infections, NSAID (Meloxicam, Bavet Meloxicam 20 Flacon, Türkiye) for pain management, and antihistaminic to relieve allergy symptoms (Cetirizine, Zyrtec 10 mg tablet, UCB Pharma, Türkiye) as suggested [1], but it was not beneficial because of too much necrotized tissue. The necrotized areas were cleaned under sedation with butorphanol (Butomidor Flacon, 0.2 mg/kg, im; InterHas, Türkiye) (17.10.2023), and a wound with extensive tissue loss was observed *(Fig. 1-B,C)*. Microbiologic examination of the skin swap did not reveal the presence of any bacteria or fungus. Considering the withdrawal time and duration of the drugs, epidermal necrolysis was considered to be associated with the enrofloxacin administration rather than meloxicam [4]. ALDEN score (+3) was found to be most likely drug-induced TEN [2,3-7,10].

To increase epithelization and wound healing faster, xenogeneic exosome obtained from the umbilical cord of calves was purchased (5 billion exosomes/mL, 5 ml Flacon; Morphiya, Mage Group Biotechnology Company, London, UK). The exosome was isolated according to the recommended procedure [11]. The dose (1 million/kg) used in the study was adapted from the previous study [12]. It was applied intradermally at 0.05 mL with an intradermal needle to multiple points (peripherally with 1 cm intervals) around the wound. In the following days, the wound area was first cleaned with crystalline, and then 1 mL exosome was diluted with 5 mL normal saline and applied twice daily to the area by spray for the first 10 days. In the following days, 0.5 mL exosome was diluted with 2 mL normal saline, and the same procedure was followed thereafter. During this period, the wound area was protected from external factors only by covering it with sterile gauze, and no other treatment was applied. The area of the skin wound was minimalized from day to day, and the healing process was monitored by the weekly photos *(Fig. 2)*. After 51 days, the patient was discharged to home since the skin wound was minimalized. In the last examination (58th day of the treatment), full recovery *(Table 1, Table 2)* or full epithelization was achieved, and thus treatment was ceased *(Fig. 2-H)*.

Discussion

Exosomes are being investigated for their biomarkers and therapeutic potential in humans and experimental animals, especially in hepato-renal diseases. Topical exosome therapy is also used for cosmetics, skin care, tissue regeneration, and dermatological disease in humans. However, no study has evaluated its effectiveness in improving acute skin wound healing in dogs. Therefore, we presented here a successful outcome of xenogeneic topical exosome therapy in a dog with a large-sized skin wound.

In this dog, TEN was suspected since huge epidermal necrolysis of the skin surface (more than 30% of the whole-body surface area) occurred after enrofloxacin injection *(Fig. 1)*. Other possible etiologies such as traumatic burns, thermal injury, erythema multiforme, vasculitis with ischemic necrosis, pemphigoid, and bullous immune diseases, systemic lupus erythematosus [1], and endocrinopathies such as hypothyroidism and hyperadrenocorticism were excluded based on the history, clinical and hemato-biochemistry findings *(Table 1, Table 2)*, as well as appearance of the skin lesion *(Fig. 1)*. Observed increases in serum ALP and ALT, two weeks after enrofloxacin treatment in this dog were found to be associated with TEN [13]. Similar to this concept, hepatitis and cholestatic liver disease were reported as the most common complications seen in patients with TEN [13]. The exact mechanism between TEN and liver diseases has not been explained yet [13]. In this case, enrofloxacin administration may be a possible reason for observed increases in serum hepatic injury marker and eosinophil count in peripheral blood [13]. Since the enrofloxacin use causes an increase in pro-inflammatory factors (IL-1β, TNF, etc.) and induces an inflammatory response at the injection site [4], it may have a role in developing large-sized epidermal necrolysis in the presented case.

Following the diagnostic work-up, treatment options were considered, and it was included using conventional techniques; antiseptic solution to prevent the dog from secondary bacterial infections, NSAID such as meloxicam for pain management, and antihistaminic such as cetirizine, as suggested [1]. Since the dog did not give a positive response to these medications and had a huge skin lesion with tissue loss, we decided to use topical xenogeneic (bovine-derived cord blood) exosome as an alternative treatment approach. Exosomes are beneficial for skin care since they are filled with proteins, lipids, and other molecules that can help to promote healing, hydration, and the protection of the skin. These molecules can help to boost collagen production, reduce inflammation, and protect the skin from environmental stressors. Additionally, exosomes can help increase the efficacy of other active ingredients, such as hyaluronic acid, peptides, and antioxidants [8]. Although many studies have been conducted on exosome therapy in human and animal models in recent years, no clear results have been obtained and also its routine clinical use has not been realized yet. Therefore, the subject needs further studies with more cases in human and veterinary medicine.

Studies show the differences in the sources and applications of exosomes. Since MSC-derived exosomes are most commonly used in these studies, their usage was preferred

in the presented case. Exosomes have been used topically for wound healing or parenterally for various diseases, such as renal failure, liver damage, and tumors, in humans and experimental animals. In a recently published study, prepared exosomes were injected into the peripheral and central areas of the wound immediately after injury and then for two weeks (daily for the first week and every other day for the second week) [14]. In that study [14], the wound closure rate was higher in the exosome group compared to the placebo control group on day 14. In the presented case, successful re-epithelialization and wound healing were observed from the first week of exosome treatment, and the wound size decreased significantly from week to week. Another study showed that ulcer surface area decreased 12 weeks after direct and intramuscular exosome administration in diabetic patients [15]. Perianal fistule was reported to have 56% closure at 24 weeks following intralesional exosome administration in humans [16]. The time to heal TEN-related wounds was reported to be maximally 65 days after the comprehensive treatment including immunosuppressive drugs and immunoglobulins in humans [17]. In the presented case, full recovery was observed at 58 days without additional local and parenteral drug applications *(Fig. 2)*.

This case report has some limitations. Firstly, since enrofloxacin and meloxicam are injected simultaneously, it was not easy to decide which medication led to epidermal necrolysis in the dog. It should be kept in mind that quinolones and oxicam NSAIDs are definitely on the list of drugs found to be associated with TEN [10]. Considering the withdrawal time and duration of meloxicam usage, epidermal necrolysis could have resulted from enrofloxacin administration rather than meloxicam. In addition, when the ALDEN scores were calculated for both drugs, enrofloxacin was found to be a more potent factor in causing skin lesions in this case. Secondly, it would be better if the skin biopsy and histopathologic examination could have been performed. The owner did not permit skin biopsy due to the necessity for anesthesia in this procedure. Despite this limitation, ALDEN scores and others such as the Naranjo Algorithm Adverse Drug Reaction Probability Scale with or without histopathologic evaluations can be used to describe the presence of TEN in humans [2] and dogs [1].

As a result, this case report provides us with an alternative treatment approach for topical xenogeneic exosome application in large-sized skin wounds such as TEN in dogs. Bovine-derived exosomes could be used safely without complication to shorten the improvement period of skin lesions in clinical practice.

Declarations

Availability of Data and Materials: In this case, the original images obtained during the study are available from the corresponding author (ZY) on request.

Acknowledgements: We thank Hasan Arda KARABARUT (Vet. Surgeon, VetPlanet) for contributing to the patient's examinations and treatments throughout the study.

Competing Interests: The authors declared that there is no conflict of interest.

Declaration of Generative Artificial Intelligence (AI): We declared that the article, tables, and figures were not written/created by AI and AI-assisted technologies.

Author Contributions: ZY, PLK, and TV performed diagnostic and therapeutic procedures; exosomes were obtained from ŞU and SC. TV wrote the article's draft, and ZY and SU revised it before submission. All approved the final version of the paper.

References

1. Lecru LA, Combarros D, Castilla-Castaño E, Delverdier M, Cadiergues MC, Pressanti C: Case report: Positive outcome of a suspected drug-associated (ımmune mediated) reaction in a 4-year-old male French bulldog. *Front Vet Sci,* 8:728901, 2021. DOI: 10.3389/fvets.2021.728901

2. Moral L, Toral T, Gilabert A, Sánchez A, Silvestre JF, Marco FM: Drug reexposure in children with severe mucocutaneous reactions. *Allergol Immunopathol (Madr),* 50 (1): 104-107, 2022. DOI: 10.15586/aei.v50i1.382

3. Banovic F, Olivry T, Bazzle L, Tobias JL, Atlee B, Zabel S, Hensel N, Linder KE: Clinical and microscopic characteristics of canine toxic epidermal necrolysis. *Vet Pathol,* 52 (2): 321-330, 2015. DOI: 10.1177/0300985814537530

4. Grabowski Ł, Gaffke L, Pierzynowska K, Cyske Z, Choszcz M, Wegrzyn G, Wegrzyn A: Enrofloxacin - The ruthless killer of eukaryotic cells or the last hope in the fight against bacterial ınfections? *Int J Mol Sci,* 23 (7):3648, 2022. DOI: 10.3390/ijms23073648

5. Han Y, Hong-Gu J: Determination of the toxicity of enrofloxacin on mouse bone marrow cells. *J Prev Vet,* 43, 141-145, 2019. DOI: 10.13041/jpvm.2019.43.4.141

6. Gorla N, García Ovando H, Larripa I: Chromosomal aberrations in human lymphocytes exposed in vitro to enrofloxacin and ciprofloxacin. *Toxicol Lett,* 104 (1-2): 43-48, 1999. DOI: 10.1016/s0378-4274(98)00230-6

7. Sanz-Ros J, Mas-Bargues C, Romero-García N, Huete-Acevedo J, Dromant M, Borrás C: Extracellular vesicles as therapeutic resources in the clinical environment. *Int J Mol Sci,* 24 (3):2344, 2023. DOI: 10.3390/ijms24032344

8. Shi H, Wang M, Sun Y, Yang D, Xu W, Qian H: Exosomes: Emerging cell-free based therapeutics in dermatologic diseases. *Front Cell Dev Biol,* 9:736022, 2021. DOI: 10.3389/fcell.2021.736022

9. Villiers E, Ristic J: BSAVA Manual of Canine and Feline Clinical Pathology. 1-614, Cambrian Printer, Aberystwyth, UK, 2016.

10. Sassolas B, Haddad C, Mockenhaupt M, Dunat A, Liss Y, Bork K, Haustein UF, Vileuf D, Roujeau JC, Le Louet H: ALDEN, an algorithm for assessment of drug causality in Stevens-Johnson Syndrome and toxic epidermal necrolysis: Comparison with case-control analysis. *Clin Pharmacol Ther,* 88 (1): 60-68, 2010. DOI: 10.1038/clpt.2009.252

11. Koçak P, Unsal N, Canikyan S, Kul Y, Cohen SR, Tiryaki K, Duncan D, Schlaudraff KU, Ascher B, Tiryaki TE: The effect of hybrosome (umbilical cord blood exosome-liposome hybrid vesicles) on human dermal cells *in vitro*. *Aesthet Surg J Open Forum,* 5:ojad039, 2023. DOI: 10.1093/asjof/ojad039

12. Prasai A, Jay JW, Jupiter D, Wolf SE, El Ayadi A: Role of exosomes in dermal wound healing: A systematic review. *J Invest Dermatol,* 142 (3): 662-678.e8, 2022. DOI: 10.1016/j.jid.2021.07.167

13. Jha AK, Suchismita A, Jha RK, Raj VK: Spectrum of gastrointestinal involvement in Stevens-Johnson syndrome. *World J Gastrointest Endosc,* 11 (2): 115-123, 2019. DOI: 10.4253/wjge.v11.i2.115

14. Rasti M, Parniaei AH, Dehghani L, Nasr Esfahani S, Mirhendi H, Yazdani V, Azimian Zavareh V: Enhancing the wound healing process through local injection of exosomes derived from blood serum: An *in vitro* and *in vivo* assessment. *Regen Ther,* 19 (26): 281-289, 2024. DOI: 10.1016/j.reth.2024.06.004

15. Dash NR, Dash SN, Routray P, Mohapatra S, Mohapatra PC: Targeting nonhealing ulcers of lower extremity in human through autologous bone marrow-derived mesenchymal stem cells. *Rejuvenation Res,* 12 (5): 359-366, 2009. DOI: 10.1089/rej.2009.0872

16. de la Portilla F, Alba F, García-Olmo D, Herrerías JM, González FX, Galindo A: Expanded allogeneic adipose-derived stem cells (eASCs) for the treatment of complex perianal fistula in Crohn's disease: Results from a multicenter phase I/IIa clinical trial. *Int J Colorectal Dis,* 28 (3): 313-323, 2013. DOI: 10.1007/s00384-012-1581-9

17. Widgerow AD: Toxic epidermal necrolysis - management issues and treatment options. *Int J Burns Trauma,* 1 (1): 42-50, 2011.