3rd INTERNATIONAL RHOTON SOCIETY MEETING

August 22 - 24, 2023

combined with

FUTURE OF MICRONEUROSURGERY

August 25, 2023

SEMI-SITTING POSITION IN NEUROSURGERY

August 26, 2023

Elite World Grand Istanbul Kucukyali - Istanbul

www.irs2023-istanbul.com



YEDİTEPE UNIVERSITY

TURKISH NEUROSURGICAL SOCIETY 1985

E-BOOK

TABLE OF CONTENTS

3rd International Rhoton Society Meeting – Committees and Faculty 3

3rd International Rhoton Society Meeting - Program 6

Future of Microneurosurgery & Semi-Sitting Position in Neurosurgery – Committees and faculty 17

Future of Microneurosurgery Meeting - Program 18

Semi-Sitting Position in Neurosurgery Meeting - Program 20

3rd International Rhoton Society Meeting - Oral Presentation Abstracts 22

3rd International Rhoton Society Meeting - E-Poster Abstracts 324

Future of Microneurosurgery & Semi-Sitting Position in Neurosurgery - Oral Presentation Abstracts 438

Committees

Organizing Committee

President of iRS	Toshio Matsushima
Congress President	Uğur Türe
Honorary President	Shigeaki Kobayashi
Vice President	Emel Avcı
Secretary	Hakan Emmez (President of TNS), Abuzer Güngör
Scientific Committee Chairman	Mustafa Başkaya

Scientific Committee

Hiroshi Abe, **Japan**
Juan Fernandez-Miranda, **USA**
Atul Goel, **India**
Takeo Goto, **Japan**
Wen Hung Tzu, **Brasil**
Carolina Martins, **Brasil**
Jacques Morcos, **USA**
Vicent Quilis-Quesada, **Spain**
Pablo Rubino, **Argentina**
Jeffrey Sorenson, **USA**
Xiaoguang Tong, **China**

Turkish Rhoton Fellows

Erdener Timurkaynak, **Ankara**
Necmettin Tanrıöver, **Istanbul**
Aşkın Şeker, **Istanbul**
Akın Akakin, **Istanbul**
Hüseyin Biçeroğlu, **Izmir**
Barış Küçükyürük, **Istanbul**
Kaan Yağmurlu, **Memphis**
Serhat Baydın, **Samsun**
Abuzer Güngör, **Istanbul**
Oğuz Baran, **Istanbul**
İlhan Aydın, **Istanbul**

Faculty

Abe, H.	**JAPAN**
Acar, F.	**TÜRKİYE**
Akakın, A.	**TÜRKİYE**
Akalan, N.	**TÜRKİYE**
Aljuboori, Z.	**USA**
Al-Mefty, O.	**USA**
Arnautovic, K.	**USA**
Arraez, M.	**SPAIN**
Avcı, E.	**TÜRKİYE**
Baran, O.	**TÜRKİYE**
Baskaya, M.	**USA**
Batay, F.	**TÜRKİYE**
Bauer, A.	**USA**
Baydın, S.	**TÜRKİYE**
Berker, M.	**TÜRKİYE**
Bi, W.	**USA**
Biçeroğlu, H.	**TÜRKİYE**
Bingöl, C.	**TÜRKİYE**
Bozkurt, B.	**TÜRKİYE**
Bozkurt, G.	**TÜRKİYE**
Bozkurt, M.	**TÜRKİYE**
Brogna, C.	**UK**
Bruce, J.	**USA**
Ceylan, S.	**TÜRKİYE**
Cezayirli, P.	**USA**
Chaddad-Netto, F.	**BRASIL**
Charbel, F.	**USA**
Cherian, I.	**INDA**
Chicoine, M.	**USA**
Choutka, O.	**USA**
Couldwell, W.	**USA**
Çağlar, Ş.	**TÜRKİYE**
Çeltikçi, E.	**TÜRKİYE**
Dehdashti, A.	**USA**
Demetriades, A.	**UK**
Dimeco, F.	**ITALY**
Doğan, A.	**USA**
Doğan, İ.	**TÜRKİYE**
Egemen, E.	**TÜRKİYE**
Emmez, H.	**TÜRKİYE**
Farhat, H.	**USA**
Fernandez-Miranda, J.	**USA**
Fieggen, G.	**SOUTH AFRICA**
Foroglou, N.	**GREECE**
Fukuda, H.	**JAPAN**
Gardner, P.	**USA**
Geyik, M.	**TÜRKİYE**
Goel, A.	**INDIA**
Gomez-Amador, J.	**MEXICO**
Gonzalez-Lopez, P.	**SPAIN**
Goto, T.	**JAPAN**
Göksu, E.	**TÜRKİYE**
Gunel, J.	**USA**
Gunel, M.	**USA**
Güngör, A.	**TÜRKİYE**
Gürbüz, M.	**TÜRKİYE**
Hanalioğlu, Ş.	**TÜRKİYE**
Hasan, D.	**USA**
Hopf, N.	**SWITZERLAND**
Hsu, S.	**TAIWAN**
Ieva, A.	**AUSTRALIA**
İzci, Y.	**TÜRKİYE**
Jean, W.	**USA**
Kadri, P.	**BRASIL**
Kahiloğulları, G.	**TÜRKİYE**
Kanaan, I.	**SUUDI ARABIA**
Khan, N.	**USA**
Kılıç, T.	**TÜRKİYE**
Kobayashi, S.	**JAPAN**
Kocaeli, H.	**TÜRKİYE**
Kohno, M.	**JAPAN**
Krayenbühl, N.	**SWITZERLAND**

Faculty

Krisht, A.	**USA**
Küçükyürük, B.	**TÜRKİYE**
Labib, M.	**USA**
Lafazanos, S.	**GREECE**
Lawton, M.	**USA**
Levi, E.	**USA**
Lipina, R.	**TÜRKİYE**
Martins, C.	**BRASIL**
Matsushima, T.	**JAPAN**
Milanese, V.	**BRASIL**
Misra, B.	**INDIA**
Moftakhar, R.	**USA**
Morcos, J.	**USA**
Morita, A.	**JAPAN**
Mura, J.	**CHILE**
Natori, Y.	**JAPAN**
Neto, M.	**BRASIL**
Nunez, M.	**ARGENTINA**
Oliveira, J.	**BRASIL**
Özduman, K.	**TÜRKİYE**
Özgiray, E.	**TÜRKİYE**
Özöner, B.	**TÜRKİYE**
Patel, N.	**USA**
Perra, G.	**ITALY**
Quilis-Quesada, V.	**SPAIN**
Rasulic, L.	**SERBIA**
Regli, L.	**SWITZERLAND**
Reis, B.	**BRASIL**
Ribas, E.	**BRASIL**
Ribas, G.	**BRASIL**
Richardson, A.	**USA**
Rosito, D.	**MEXICO**
Rubino, P.	**ARGENTINA**
Rzaev, J.	**RUSSIA**
Sa, M.	**PORTUGAL**
Sade, B.	**TÜRKİYE**
Sakata, K.	**JAPAN**
Samandouras, G.	**UK**
Samii, A.	**GERMANY**
Santos, J.	**USA**
Sanus, Z.	**TÜRKİYE**
Sencer, A.	**TÜRKİYE**
Serra, C.	**SWITZERLAND**
Shumkovski, R.	**MACEDONIA**
Solaroğlu, İ.	**TÜRKİYE**
Sorenson, J.	**USA**
Souto, A.	**BRASIL**
Sufianov, A.	**RUSSIA**
Sugawara, T.	**JAPAN**
Sultan, M.	**USA**
Takizawa, K.	**JAPAN**
Tanikawa, R.	**JAPAN**
Tanrıöver, N.	**TÜRKİYE**
Turel, K.	**INDIA**
Türe, U.	**TÜRKİYE**
Türkoğlu, M.	**TÜRKİYE**
Tzu, W.	**BRASIL**
Vajkoczy, P.	**GERMANY**
Xu, B.	**CHINA**
Yamamoto, J.	**USA**
Yılmaz, T.	**TÜRKİYE**
Youssef, S.	**USA**
Ziyal, İ.	**TÜRKİYE**



3rd International Rhoton Society Meeting

22 - 24 August 2023 - Istanbul

PROGRAM



22 AUGUST 2023 - TUESDAY	
Time	**HEROPHILUS HALL**
18:30-19:00	**Opening Speeches**
	Canan Aykut Bingöl - Rector of Yeditepe University
	Hakan Emmez - President of the Turkish Neurosurgical Society
	Toshio Matsushima - President of the International Rhoton Society
	Uğur Türe - President of the 3rd International Rhoton Society Meeting
19:00-21:30	**Welcome Cocktail**


Süleymaniye Mosque

23 AUGUST 2023 - WEDNESDAY	
Time	**HEROPHILUS HALL**
08.15-10:30	**SESSION-I**
	Moderators: **William T. Couldwell, Guilherme Ribas, Murad Bavbek**
08:15-08:30	History of neurosurgical anatomy research **Shigeaki Kobayashi**
08:30-08:45	Evolution of CMF opening: Its effects on posterior fossa surgeries from the fourth ventricle to the brain stem **Toshio Matsushima**
08:45-09:00	Anatomic - angiographic -surgical correlation of the MCA aneurysms and its influence on surgical strategy **Wen Hung Tzu**
09:00-09:15	The intricate interplay of anatomy and pathology in the cavernous sinus: Implications for surgical approaches and philosophy **Jacques Morcos**
09:15-09:30	What does it take to be a microneurosurgeon? **Fady T. Charbel**
09:30-09:45	Taxonomy in the management of cerebral cavernous malformations **Michael Lawton**
09:45-10:00	The anatomic basis of advanced cavernous sinus surgery **Ali Krisht**
10:00-10:15	The little big thing **Ossama Al-Mefty**
10:15-10:30	**Q/A**
10:30-11:00	COFFEE BREAK



Topkapı Palace

23 AUGUST 2023 - WEDNESDAY			
Time	**HEROPHILUS HALL**	**VESALIUS HALL**	**PRESENTATION HALL**
11.00-12:30	**SESSION-II**	**SESSION-III**	
	Moderators: Jacques Morcos, Manuel Cunha e Sa, Şükrü Çağlar	**Moderators: Hiroshi Abe, Yoshihiro Natori, Akın Akakın**	
11:00-11:10	Translab versus retrosigmoid approach for acoustic neuromas: Which one is the best? **Mustafa Başkaya**	Application of microneurosurgical anatomy to surgery of deep AVMs **Feres Chaddad-Netto**	
11:10-11:20	Demystifying the jugular foramen **Jeffrey Sorenson**	Microsurgical anatomy for transjugular approach **Katsumi Sakata**	
11:20-11:30	Prof. Rhoton and the Cavernous Sinus: Evolution and Revolution of Surgical Anatomy **Juan Fernandez-Miranda**	Extradural minipretemporal MIPLATTA approach for sphenopetroclival meningiomas. **Jorge Mura**	
11:30-11:40	Microsurgical anatomy of the vertebral artery **Carolina Martins**	History of aneurysm surgery **Giancarlo Perra**	
11:40-11:50	Making atlantoaxial fixation safer - anatomical subtleties **Atul Goel**	Combined direct and indirect bypass for adult moyamoya disease. Importance of the meningeal arteries **Junichi Yamamoto**	
11:50-12:00	Preserving the cerebellar hemispheric tentorial bridging veins through a novel tentorial cut technique for supracerebellar approaches **Uğur Türe**	Anterior clinoidectomy - no drill technique and clinical application for aneurysm surgery **Katsumi Takizawa**	
12:00-12:10	Hearing preservation in surgery for Vestibular Schwannoma **William T. Couldwell**	Cranio-orbitozygomatic approach: technique, modifications and applications **Emel Avcı**	
12:10-12:30	Q/A	Q/A	
12:30-13:30	LUNCH BREAK		
12:30-12:50			**INDUSTRY SYMPOSIUM**
			Hakan Emmez ZEISS

23 AUGUST 2023 - WEDNESDAY			
Time	**HEROPHILUS HALL**	**VESALIUS HALL**	**PRESENTATION HALL**
13.30-15:30	**SESSION-IV**	**SESSION-V**	**ORAL PRESENTATION I**
	Moderators: Wen Hung Tzu, Rokuya Tanikawa, Savaş Ceylan	**Moderators: Atul Goel, Takashi Sugawara, Barış Küçükyürük**	**Moderators: Roham Moftakhar Albert A. Sufianov İhsan Solaroğlu**
13:30-13:40	Vestibular Schwannomas: Functional Preservation Strategies **Samy Yousef**	Anatomy, vascular and skull base neurosurgery tools are perfect ingredients for surgical solutions **Ondrej Choutka**	
13:40-13:50	Complications of neurosurgery: how to reduce and prepare? **Akio Morita**	Open surgical approaches to the anterior petrous apex **Mohamed Labib**	
13:50-14:00	Microsurgical anatomy and techniques applied to middle fossa and cavernous sinus neurosurgery **Vicent Quilis-Quesada**	Use of complex systems approach in the modeling of neurosurgical disease **Zaid Aljuboori**	
14:00-14:10	Surgical anatomy applied to AVMs **Pablo Rubino**	The frontal sinus craniotomy, and other novel approaches to the anterior fossa **Michael Chicoine**	
14:10-14:20	Surgical Anatomy of the Auditory Pathway **Amir Samii**	The surgery of the pineal and talamomesencephalic region tumors **Gökhan Bozkurt**	
14:20-14:30	Surgical management of large orbital hemangiomas **David Hasan**	Orbital tumor surgery - anatomy and clinical application **Yoshihiro Natori**	
14:30-14:40	Transcavernous extension of the surgical field to basilar aneurysms. **Rokuya Tanikawa**	The history of basal ganglia **Phillip Cem Cezayirli**	
14:40-14:50	Experimental and clinical basis for preservation and improvement of altered vision in sellar lesions **Kenan Arnautovic**	Neuroanatomy and connectomes in deep brain stimulation **Vanessa Milanese**	
14:50-15:00	NTMS-enhanced fiber tract analysis improves planning for surgery of brain stem lesions **Peter Vajkoczy**	Full endoscopic removal of third ventricle colloid cysts **Altay Sencer**	
15:00-15:10	Sulcal keypoints: anatomy oriented microneurosurgery **Guilherme Ribas**	Current application of skull base procedure for complex cerebrovascular surgery **Hitoshi Fukuda**	
15:10-15:20	Microsurgery of mesencephalic tumors: A 360° approach **Miguel A Arraez**	Anatomy of the limbic system **Paulo Kadri**	
15:20-15:30	**Q/A**	**Q/A**	
15:30-16:00	COFFEE BREAK		**INDUSTRY SYMPOSIUM**
			Advanced Tractography in Neurosurgery **Bruce Leggett**

23 AUGUST 2023 - WEDNESDAY			
Time	**HEROPHILUS HALL**	**VESALIUS HALL**	**PRESENTATION HALL**
16.00-17:20	**SESSION-VI**	**SESSION-VII**	**ORAL PRESENTATION II**
	Moderators: Jeffrey Sorenson, Feres Chaddad-Netto, Nejat Akalan	**Moderators: Takeo Goto, Walter Jean, Serhat Baydın**	
16:00-16:10	**Andreas Demetriades**	Microsurgical anatomy of supracerebellar approaches **Abuzer Güngör**	
16:10-16:20	Anatomic limitations of endoscopic endonasal surgery **Paul Gardner**	Treatment strategy and surgical technique for tumor resection in and around the cavernous sinus **Takashi Sugawara**	
16:20-16:30	Ultrasound in neurosurgery, from intraoperative imaging to treatment **Francesco Dimeco**	Endoscopic endonasal anatomy of anterior fossa and surgical nuances **Gökmen Kahiloğulları**	
16:30-16:40	Posterior circulation revascularization for complex aneurysms **Amir Dehdashti**	5 patients diagnosed with galen vein aneurysm malformation **Murat Geyik**	**Moderators: Lukas Rasulic Carlo Serra M. Sabri Gürbüz**
16:40-16:50	Microsurgery for temporal lobe gliomas **Hakan Emmez**	3D-HDR Documented, stepwise dissected, MRI navigated microsurgical anatomy of human brain nuclei and fiber systems **Hüseyin Biçeroğlu**	
16:50-17:00	AVM embolization **Muhammed Aziz Sultan**	Anatomical Challenges for Endoscopic Third Ventriculostomy **Emrah Egemen**	
17:00-17:10	The transtentorial amygdalahippocampectomy for mediobasal temporal lobe epilepsy **Niklaus Krayenbühl**		
17:10-17:20	**Q/A**	**Q/A**	

24 AUGUST 2023 - THURSDAY			
Time	**HEROPHILUS HALL**	**VESALIUS HALL**	**PRESENTATION HALL**
08.20-10:30	**SESSION-VIII**	**SESSION-IX**	**ORAL PRESENTATION III 08:00-10:30**
	Moderators: Akio Morita, Paulo Kadri, Hakan Emmez	**Moderators: Kenan Arnautovic Eduardo Ribas, Mustafa Berker**	
08:20-08:30	Skull base anatomy for EC-IC bypass **Hiroshi Abe**	Brainstem fibers and surgical implications **Maximiliano Nunez**	
08:30-08:40	Microanatomy of minimal anterior and posterior combined petrosal approach **Takeo Goto**	AVM surgery without embolization for all grade Avm - safer techniques for cure. **Nirav Patel**	
08:40-08:50	Using it all: multimodality approach for resection of deep seeded tumors **Wenya Linda Bi**	Use of complex bypass techniques for aneurysm surgery **Andrew Bauer**	
08:50-09:00	MVD for TN with special emphasis on veins and transposition of arteries **Keki Turel**	Midline paramedic supracerebellar infratentorial approach **Angela Richardson**	
09:00-09:10	Microsurgery of the invasive anterior fossa lesions **Antonio Aversa do Souto**	Microsurgical resection of complex gliomas encasing cerebral arteries **Jaime Martinez Santos**	**Moderators: David Hasan Junichi Yamamoto İbrahim Ziyal**
09:10-09:20	Intracranial aneurysm genetics: implications for clinical care **Murat Gunel**	The anatomy of transnasal transsphenoidal approach to pituitary adenomas through the endoscope **Robert Shumkovski**	
09:20-09:30	Surgery for jugular foramen tumors using various surgical approaches. **Michihiro Kohno**	Cerebral arteries. Angio /anatomy relationships **Hamad Farhat**	
09:30-09:40	Pineal region anatomy and surgical technique **George Samandouras**	Microsurgical anatomy of cerebellar peduncles **Oğuz Baran**	
09:40-09:50	Tailored retrosigmoidal keyhole approaches - endoscopic anatomy and surgical strategy **Nikolai Hopf**	The interhemispheric contralateral transfalcine approach for cingulate lesions **Pablo Gonzalez-Lopez**	
09:50-10:00	Endoscopic endonasal approaches to craniopharyngiomas **Savaş Ceylan**	The thalamus: history, anatomy and surgery **Carlo Serra**	
10:00-10:10	Anatomy and transcavernous approach to the region of the pontine and para-pontine space **Aclan Doğan**	Cerebellum anatomy and fiber dissection and posterior fossa superficial anatomy **Akın Akakın**	
10:10-10:20	Surgical strategies to paraclinoid aneurysms **Sanford Hsu**	The subdiaphragmatic cistern: historic, radioanatomic, and surgical findings. **Antonio Di Ieva**	
10:20-10:30	**Q/A**	**Q/A**	
10:30-11:00	COFFEE BREAK		

24 AUGUST 2023 - THURSDAY			
Time	**HEROPHILUS HALL**	**VESALIUS HALL**	**PRESENTATION HALL**
11.00-12:30	**SESSION-X**	**SESSION-XI**	**ORAL PRESENTATION IV**
	Moderators: Imaad Kanaan, Vicent Quilis-Quesada, Emel Avcı	**Moderators: Juan Fernandez-Miranda, Niklaus Krayenbühl, Türker Kılıç**	**Moderators: Katsumi Takizawa Robert Shumkovski Oğuz Baran**
11:00-11:10	Lateral suboccipital approach to pineal region tumors **Jeffrey N. Bruce**	Preventing and managing complications in endoscopic skull base surgery **Mustafa Berker**	
11:10-11:20	Tuberculum sellae meningiomas, "does simplicity trumps complexity"? **Imaad Kanaan**	Foramen magnum meningioma **Mateus Neto**	
11:20-11:30	Unruptured aneurysms: strategies to minimize microsurgical trauma **Luca Regli**	Endovascular treatment of ICA aneursym **Mehmet Erhan Türkoğlu**	
11:30-11:40	Bilateral multiple aneurysms treated through a unilateral approach **Juan Luis Gomez-Amador**	Nucleus accumbes and its connections **Serhat Şevki Baydın**	
11:40-11:50	Surgical strategy in the treatment os intramedullary tumors **Manuel Joao Da Cunha E Sa**	Integrating microneurosurgical and mapping strategies in brain tumors **Christian Brogna**	
11:50-12:00	Paraclinoid aneurysms - pretemporal extradural transclinoidal approach **Baltazar Leao Reis**	Novel posterior transaxis approach-oriented microneurosurgical and endoscopic anatomy of CVJ **İhsan Doğan**	
12:00:12:10	Clinical correlations of the genomics of meningiomas **Jennifer Moliteiro Gunel**	Extension patterns of gliomas follow functional networks of the brain **Koray Özduman**	
12:10-12:20	Hemispherotomy for the treatment of catastrophic epilepsy syndromes **Nejat Akalan**	Anatomy and medicine in Hittites **Yusuf İzci**	
12:20-12:30	Q/A	Q/A	
12:30-13:30	LUNCH BREAK		
12:30-12:50	**Lunch Break**		**INDUSTRY SYMPOSIUM**
			Development of wide view/high resolution operative microscope MM77 **Rokuya Tanikawa** Mitaka

24 AUGUST 2023 - THURSDAY			
Time	**HEROPHILUS HALL**	**VESALIUS HALL**	**PRESENTATION HALL**
13.30-15:30	**SESSION-XII**	**SESSION-XIII**	**ORAL PRESENTATION V**
	Moderators: **Pablo Rubino, Mateus Neto, Necmettin Tanrıöver**	**Moderators:** **Andreas Demetriades, Juan Luis Gomez-Amador, İlhan Aydın**	
13:30-13:40	Transnasal endoscopic approach to CVJ . How far we can go **Nikolaos Foroglou**	Anatomic concepts in the management of complex skullbase tumors **Diego Mendez Rosito**	
13:40-13:50	Microsurgical management of irradiated CPA tumors **Şükrü Çağlar**	Microsurgical approach to distal anterior cerebral aneurysms (DACA aneurysms) **Erkin Özgiray**	
13:50-14:00	Suboccipital transtentorial approach to pineal region tumors: Microsurgical pearls **Türker Kılıç**	Extradural anterior clinoidectomy: Step by step anatomical description **Mehmet Sabri Gürbüz**	
14:00-14:10	Rhoton's influence in Turkish Neurosurgery **Necmettin Tanrıöver**	Outcomes and complications in STA MCA bypass surgery in stroke patients **Feridun Acar**	
14:10-14:20	Microsurgical anatomy of the central core of the brain **Eduardo Carvalhal Ribas**	The Middle cranial fossa approach **Zihni Sanus**	**Moderators:** **Angela Richardson** **Jamie M. Santos** **Yusuf İzci**
14:20-14:30	Maximal safe resection in glioma surgery: the "gold standard **İhsan Solaroğlu**	Microsurgery of very small ruptured anterior communicating artery aneurysms **Hasan Kocaeli**	
14:30-14:40	Anatomy of brachial plexus and peripheral nerve - surgical challenges and/or **Lukas Rasulic**	Different surgical approaches to the various pathologies of the clivus **Melih Bozkurt**	
14:40-14:50	The Rhoton legacy in the metaverse era **Walter Jean**	Cavernous sinus anatomy **Spyridon Lafazanos**	
14:50-15:00	Microneurosurgery in the core of the management of brain AVMs **Jean Gonçalves de Oliveira**	Complications of the surgery for cavernomas **Funda Batay**	
15:00-15:10	Lumbosacral lipoma **Graham Fieggen**	Neurocognitive anatomy of the frontal lobe: Cortical parcellations and subcortical connections **Baran Bozkurt**	
15:10-15:20	Overview of Bergama (Pergamum) and Yağcıbedir rugs **Edi Levi**	Transorbital neuroendoscopy for sphenoid wing meningiomas **Emrah Çeltikçi**	
15:20-15:30	**Q/A**	**Q/A**	
15:30-16:00	COFFEE BREAK		

24 AUGUST 2023 - THURSDAY			
Time	**HEROPHILUS HALL**	**VESALIUS HALL**	**PRESENTATION HALL**
16:00-17:10	**SESSION-XIV**	**SESSION-XV**	**ORAL PRESENTATION VI**
	Moderators: Carolina Martins, Jean Gonçalves de Oliveira, Abuzer Güngör	**Moderators: Amir Dehdashti, Andrew Grande, Hüseyin Biçeroğlu**	
16:00-16:10	Exo-endoscopic treatment of craniopharyngiomas **Albert A. Sufianov**	Anterior clinoidectomy - optic canal unroofing (as surgical technique alone) or (within the concept of management of perioptic meningiomas) **Burak Sade**	
16:10-16:20	Surgical management of tuberculum sella meningiomas **İbrahim Ziyal**	Patient-specific 3D virtual models for neurosurgical planning in complex vascular and tumor cases: A Practical way to optimal surgical approach and strategy selection **Şahin Hanalioğlu**	
16:20-16:30	Microsurgery for lesions of the 3rd Ventricle and my encounter with Prof. Rhoton **Basant Misra**	Microsurgery of motor area AVMs **Tevfik Yılmaz**	**Moderators: M. Aziz Sultan Mohamed Labib Baran Bozkurt**
16:30-16:40	Microsurgical anatomy of fiber tracts related to hemispherotomy **Barış Küçükyürük**	Surgical treatment of trochlear nerve schwannomas **Barış Özöner**	
16:40-16:50	What is the current literature on revascularization for MoyaMoya Disease and Atherosclerotic Steno-Occlusive Disease in 2023? An updated systematic review and meta-analysis of the literature **Nickalus Khan**	Microvascular decompression of cranial nerves: surgical anatomy and technique; **Jamil Rzaev**	
16:50-17:00	Pressure measurements for bypass of moyamoya **Bin Xu**	Optic nerve decompression; endoscopic endonasal and transcranial perspective **Ethem Göksu**	
17:10-17:10	Q/A	Q/A	
17:10-17:30			**INDUSTRY SYMPOSIUM**
			Benefits of robotic digital micro-neurosurgery with focus on semi-sitting procedures performed with Aesculap Aeos® **Radim Lipina** B BRAUN



FUTURE OF MICRONEUROSURGERY

August 25, 2023

SEMI-SITTING POSITION IN NEUROSURGERY

August 26, 2023

Elite World Grand Istanbul Kucukyali - Istanbul

www.irs2023-istanbul.com

Organizing Committee



Uğur Türe
President



Gazi Yaşargil
Honorary President



Ossama Al-Mefty
Honorary Guest



Madjid Samii
Honorary Guest

Scientific Committee

Giuseppe Lanzino, **USA (Co-Chair)** - Hatice Türe, **Türkiye (Co-Chair)**

Nejat Akalan, **Türkiye** - Mustafa Başkaya, **USA** - Ali F. Krisht, **USA**

Michael T. Lawton, **USA** - Amir Samii, **Germany**

Faculty

Akalan, N.	**TÜRKİYE**	Güngör, A.	**TÜRKİYE**	Oliveira, J.	**BRASIL**
Akça, B.	**TÜRKİYE**	İnan, G.	**TÜRKİYE**	Patel, N.	**USA**
Al-Mefty, O.	**USA**	Kadri, P.	**BRASIL**	Roser, F.	**USA**
Arnautoviç, K.	**USA**	Karacalar, S.	**TÜRKİYE**	Samii, A.	**GERMANY**
Başkaya, M.	**USA**	Kocaeli, H.	**TÜRKİYE**	Samii, M.	**GERMANY**
Bilgin, H.	**TÜRKİYE**	Köner, Ö.	**TÜRKİYE**	Serra, C.	**SWITZERLAND**
Bruce, J.	**USA**	Krisht, A.	**USA**	Sultan, M.	**USA**
Couldwell, W.	**USA**	Lanzino, G.	**USA**	Şatırlar, Z.	**TÜRKİYE**
Dimeco, F.	**ITALY**	Lawton, M.	**USA**	Tanikawa, R.	**JAPAN**
Dölen, D.	**TÜRKİYE**	Luzzi, S.	**ITALY**	Turel, K.	**INDIA**
Elbabaa, S.	**USA**	Misra, B.	**INDA**	Türe, H.	**TÜRKİYE**
Erdem, A.	**TÜRKİYE**	Morcos, J.	**USA**	Türe, U.	**TÜRKİYE**
Ersin, E.	**TÜRKİYE**	Morita, A.	**JAPAN**	Tzu, W.	**BRASIL**
Fernandez-Mi.J.	**USA**	Najjar, J.	**SYRIA**	Xu, B.	**CHINA**
Goel, A.	**INDIA**	Mura, J.	**CHILE**	Yaşargil, M.	**TÜRKİYE**
Goto, T.	**JAPAN**	Oba, S.	**TÜRKİYE**		

FUTURE OF MICRONEUROSURGERY

August 25, 2023

Elite World Grand Istanbul Kucukyali

www.irs2023-istanbul.com

PROGRAM

25 AUGUST 2023, FRIDAY

FUTURE OF MICRONEUROSURGERY

HEROPHILUS HALL

08.30-10:30	SESSION-I
	Moderators: **Jacques Morcos, Paulo Kadri**
08:30-08:40	**Introduction - Uğur Türe**
08:40-08:50	**William T. Couldwell**
08:50-09:00	**Jeffrey N. Bruce**
09:00-09:10	**Rokuya Tanikawa**
09:10-09:20	**Akio Morita**
09:20-09:30	**Giuseppe Lanzino**
09:30-09:40	**Atul Goel**
09:40-09:50	**Michael Lawton**
09:50-10:00	**Ali Krisht**
10:00-10:20	**Madjid Samii**
10:20-10:30	**Q/A**
10:30-11:00	COFFEE BREAK

11.00-12:30	SESSION-II
	Moderators: **Ali Krisht, Nirav Patel**
11:00-11:10	**Kenan Arnautoviç**
11:10-11:20	**Jacques Morcos**
11:20-11:30	**Wen Hung Tzu**
11:30-11:40	**Rokuya Tanikawa**
11:40-11:50	**Takeo Goto**
11:50-12:00	**Mustafa Başkaya**
12:00-12:20	**M. Gazi Yaşargil**
12:20-12:30	**Q/A**
12:30-13:30	LUNCH BREAK

13.30-15:30	SESSION-III
	Moderators: **Mustafa Baskaya, Carlo Serra**
13:30-13:40	**Juan Fernandez-Miranda**
13:40-13:50	**Bin Xu**
13:50-14:00	**Basant Misra**
14:00-14:10	**Jean Gonçalves de Oliveira**
14:10-14:20	**Paulo Kadri**
14:20-14:30	**Nirav Patel**
14:30-14:40	**Samer K. Elbabaa**
14:40-14:50	**Mohammad Aziz Sultan**
14:50-15:10	The sun will rise tomorrow **Ossama Al-Mefty - Honorary Guest**
15:10-15:30	**Q/A**
15:30-16:00	COFFEE BREAK

16.00-17:00	SESSION-IV
	Moderators: **Uğur Türe, Samer K. Elbabaa**
16:00-16:10	**Carlo Serra**
16:10-16:20	**Jalal Najjar**
16:20-16:30	**Abuzer Güngör**
16:30-16:40	**Sabino Luzzi**
16:40-16:50	**Jorge Mura**
16:50-17:00	**Q/A**

SEMI-SITTING POSITION IN NEUROSURGERY

August 26, 2023

Elite World Grand Istanbul Kucukyali

www.irs2023-istanbul.com

PROGRAM

26 AUGUST 2023, SATURDAY

SEMI-SITTING POSITION IN NEUROSURGERY

HEROPHILUS HALL

08.30-10:30	SESSION-I
	Moderators: **Mois Bahar, Mustafa Başkaya**
08:30-08:45	Introduction **Giuseppe Lanzino** **Hatice Türe** **Uğur Türe**
08:45-09:00	Physiological changes with Semi-sitting position **Gözde İnan**
09:00-09:15	Intraoperative Monitoring in Semi-sitting position **Başak Akça**
09:15-09:30	My Experiences in Semi-Sitting Position **Michael Lawton**
09:30-09:45	My Experiences in Semi-Sitting Position **Ali Krisht**
09:45-10:00	My Experiences in Semi-Sitting Position **Jeffrey N. Bruce**
10:00-10:20	**Madjid Samii - Honorary Guest**
10:20-10:30	**Q/A**
10:30-11:00	COFFEE BREAK

11.00-12:30	SESSION-II
	Moderators: **Ali Krisht, Nejat Akalan**
11:00-11:15	My Experiences in Semi-Sitting Position **Atul Goel**
11:15-11:30	Surgery for Neurobionic Hearing Restoration in the Semi-Sitting Position **Amir Samii**
11:30-11:45	My Experiences in Semi-Sitting Position **Keki Turel**
11:45-12:00	My Experiences in Semi-Sitting Position **Giuseppe Lanzino**
11:45-12:00	My Experiences in Semi-Sitting Position **Basant Misra**
12:00-12:20	**M. Gazi Yaşargil**
12:20-12:30	**Q/A**
12:30-13:30	LUNCH BREAK

13:30-16:00	SESSION-III
	Moderators: **Uğur Türe, Giuseppe Lanzino**
13:30-13:45	My Experiences in Semi-Sitting Position **Florian Roser**
13:45-14:00	My Experiences in Semi-Sitting Position **Nejat Akalan**
14:00-14:15	İstanbul Faculty of Medicine experience **Esra Saka Ersin - Duygu Dölen**
14:15-14:30	My Experiences in Semi-Sitting Position **Francesco Dimeco**
14:30-14:45	My Experiences in Semi-Sitting Position **Nirav Patel**
14:45-15:00	My Experiences in Semi-Sitting Position **Samer K. Elbabaa**
15:00-15:15	Uludağ University Experiences **Hülya Bilgin - Hasan Kocaeli**
15:15-15:30	Yeditepe University Experiences **Hatice Türe - Uğur Türe**
15:30-16:00	**Q/A**



3rd International Rhoton Society Meeting

22 - 24 August 2023 - Istanbul

ORAL PRESENTATIONS

OP- IV/2

The anatomy of transnasal transsphenoidal approach to pituitary adenomas and sellar anatomy through the endoscope

Robert Shumkovski[1], Ivica Kocevski[1]

[1]University Clinic for neurosurgery, University clinical center Mother Teresa, Skopje, N. Macedonia

Objectives: To present the advantages and disadvantages of the transnasal transsphenoidal endoscopic approach, including the applicable anatomy, compared to the microscopic approaches

Background: The transnasal transsphenoidal endoscopic approach became the gold standard for the majority of the pituitary pathology. The endoscopic approach to the pituitary has redefined accurate visualization of the sella. The panoramic view afforded by the endoscope is unparalleled as compared with the traditional conical view of the microscope.

Method: We conducted retrospective/prospective study during the period of 2010-2018 which included 46 microscopically and 39 endoscopically treated patients. Tumors were classified according to the diameter and clinical outcomes were evaluated.

Results: The results demonstrated more efficacious and effective disease control in the endoscopic technique group, especially in secretory active macroadenomas. Further, the extension of the resection, which was better in endoscopic approach undoubtedly contributed to better disease control. Complication rate, including endocrine, was lower following endoscopy compared with microsurgery.

nasal phase

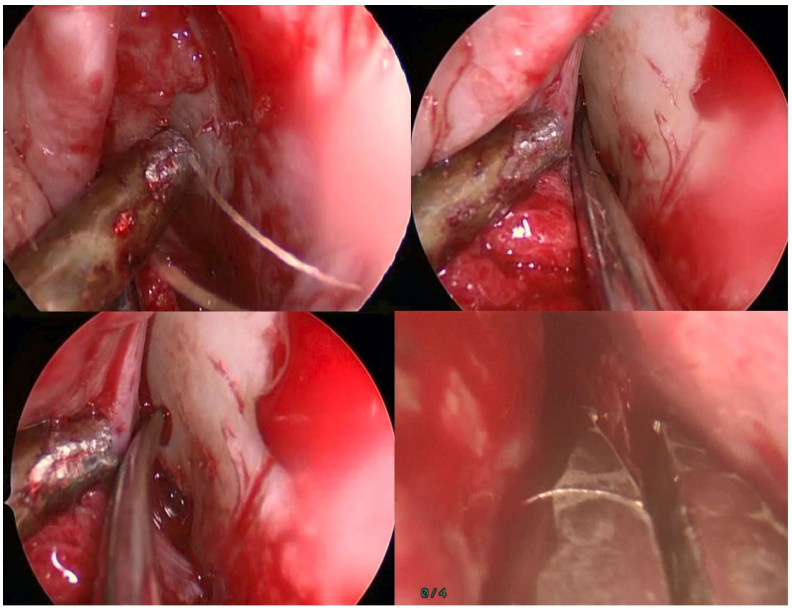

1. Nasal phase

sphenoidal phase

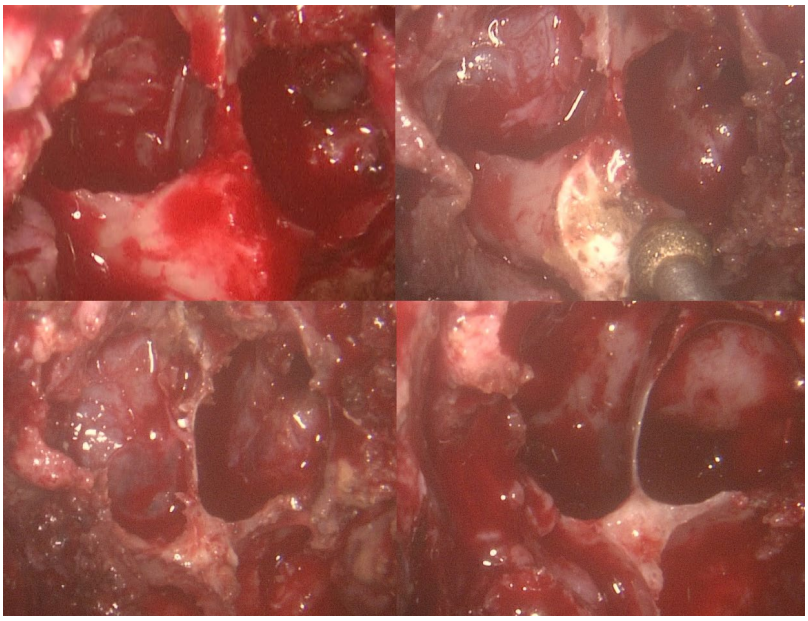

2. sphenoidal phase

sellar phase

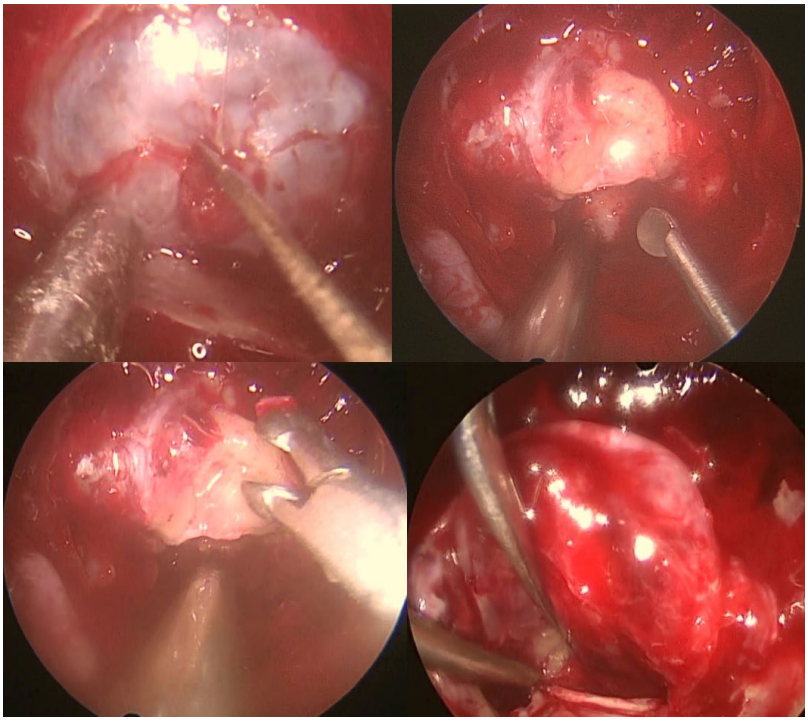

sellar phase

Extent of resection

Extent of resection	<50%	<70%	<90%	>90%	Total
Microscopic	12 (26.1%)	27 (58.7%)	7 (15.2%)	0 (0%)	46 total (100%)
Endoscopic	0 (0%)	0 (0%)	16 (41.0%)	23 (59.0%)	39 total (100%)
Total	12 (14.1%)	27 (31.8%)	23 (27.1%)	23 (27.1%)	85 total (100%)

Extent of resection

Complications

Complications	Yes	No	total
Microscopic	16 (34.8%)	30 (65.2%)	46 (100%)
Endoscopic	3 (7.7%)	36 (92.3%)	39 (100%)
Total	19 (22.4%)	66 (77.6%)	85 (100%)

Complications comparison in microscopic and andoscopic approach

Conclusions: This technique evidenced to have a statistically significant reduction in operative time and length of hospital stay, as well as more radical safe resection and complication control. There is also a trend toward improved endocrine outcomes and rate of correction of visual defects. These two approaches are still comparable with eloquent advantages and disadvantages, formulated as balanced dialectics. In addition, the use of endoscopes, including multilocular polifilament 3D endoscope, facilitates extended approaches, reaching a delicate skull base lesions that are suprasellar, retrosellar, and parasellar, which permits visualization beyond the abilities of the microscope.

Keywords: Pituitary gland, Pituitary surgery, Transsphenoidal surgery, Sella

References

1. Renn WH, Rhoton AL Jr: Microsurgical anatomy of the sellar region. J Neurosurg 43:288–298, 1975.
2. Rhoton, Albert L. Jr., M.D.. The Sellar Region. Neurosurgery 51(4):p S1-335-S1-374, October 2002.
3. Rhoton AL Jr: Anatomy of the pituitary gland and sellar region, in Thapar K, Kovacs K, Scheithauer BW, Lloyd RV (eds): Diagnosis and Management of Pituitary Tumors. Totowa, Humana Press Inc, 2000, pp 13–40.
4. Rhoton AL Jr, Maniscalco JE: Microsurgery of the sellar region, in Glaser JS (ed): Neuro-Ophthalmology. St. Louis, C.V. Mosby, 1977, pp 106–127.
5. Rhoton AL Jr, Hardy DG, Chambers SM: Microsurgical anatomy and dissection of the sphenoid bone, cavernous sinus and sellar region. Surg Neurol 12:63–104, 1979.
6. Rhoton AL Jr, Harris FS, Renn WH: Microsurgical anatomy of the sellar region and cavernous sinus. Clin Neurosurg 24:54–85, 1977.

OP- IV/3

Department of Clinical-Surgical, Diagnostic and Pediatric Sciences, University of Pavia, Pavia, Italy

Sabino Luzzi[1], Alice Giotta Lucifero[1]

[1]Department of Clinical-Surgical, Diagnostic and Pediatric Sciences, University of Pavia, Pavia, Italy

Objectives: The present study focuses on the infratrochlear (IT) transcavernous, anteromedial (AM), and anterolateral (AL) approaches, analyzing their feasibility, indications, advantages, and limitations.

Background: Understanding the working corridors used in the interdural approach to Meckel's cave is critical for the treatment of trigeminal schwannomas.

Method: Morphometric data of Meckel's cave, porus trigeminus, IT transcavernous, AM, and AL corridors were obtained from ten formalin-fixed, latex-injected cadaveric heads. Exposure areas, volumes, and opening angles of each corridor were calculated.

Results: The volume of the IT transcavernous corridor was the largest, while the opening angle of the AM middle fossa triangle was the largest.

Conclusions: The AM middle fossa corridor is strategic in schwannomas mainly involving Meckel's cave with a minor extension into the posterior fossa. It allows gross total resection through the opening of the porus trigeminus.

Keywords: Cavernous sinus, Meckel's Cave, Transcavernous Approach, Trigeminal Schwannomas

References

1. Al-Mefty O, Ayoubi S, Gaber E. Trigeminal schwannomas: removal of dumbbell-shaped tumors through the expanded Meckel cave and outcomes of cranial nerve function. *J Neurosurg.* 2002;96(3): 453-463. https://doi.org/10.3171/jns.2002.96.3.0453.
2. al-Mefty O, Anand VK. Zygomatic approach to skull-base lesions. *J Neurosurg.* 1990;73(5): 668-673. https://doi.org/10.3171/jns.1990.73.5.0668.
3. Almefty KK, Ayoubi S, Al-Mefty O. Middle Fossa Approach for Resection of a Giant Trigeminal Schwannoma Through an Expanded Meckel Cave: 2-Dimensional Operative Video. *Oper Neurosurg (Hagerstown).* 2022;22(3): e122-e123. https://doi.org/10.1227/ons.0000000000000071.
4. Al-Mefty O, Smith RR. Surgery of tumors invading the cavernous sinus. *Surg Neurol.* 1988;30(5): 370-381. https://doi.org/10.1016/0090-3019(88)90200-5.

OP-II/4

Risk Assessment and Prevalence of Work-Related Musculoskeletal Disorders among Cranial and Spinal Neurosurgeons

Mohamed Mohsen amen[1], Hazem Alkosha[1], Mo'men Mohammed Mohammed[2]

[1]Mansoura university
[2](Zagazig University

Objectives: To assess the risk and prevalence of work-related musculoskeletal disorders (WMSDs) in spine and cranial surgeons via ergonometric analysis of their physical postures during surgery .

Background: Owing to the frequent and prolonged flexing postures attained by neurosurgeons, in addition to, prolonged firm grasping of instruments and tendency to neglect awkward postures during surgeries due to full concentration, neurosurgeons are considered at high risk of experiencing Work-related musculoskeletal disorder.

Method: A cross-sectional analytic study composed of 2 sections; a risk-assessment and a questionnaire-based survey was conducted. The risk-assessment for developing WMSDs was performed on young volunteer neurosurgeons to analyze 10 most common attained postures inside the operating room using the Rapid Entire Body Assessment (REBA) tool. The survey-based questionnaire was distributed using the Google Forms software among the relevant official WhatsApp groups of the Egyptian Society of Neurological Surgeons (ESNS) and the Egyptian Spine Association (ESA).

Results: Thirteen volunteers were assessed for the risk of WMSDs with a mean age of 33 ± 6 years . The assessed 10 most commonly attained postures revealed moderate to very high risk of WMSDs, with risk index > 1 for all postures. A total of 232 respondents completed the questionnaire, half of them aged 40 to 60 years and 74% reported WMSDs symptoms. Pain was experienced by the vast majority (96%), with neck pain being the most common (62.8%), followed by low back pain (56.0%), shoulder pain (44.5%) and wrist/finger pain (43.9%).

Sample of photos taken for participants in various physical postures inside the operating room



Conclusions: WMSDs is prevalent among neurosurgeons affecting their ability to work. Ergonomics need further awareness, education and interventions to reduce injuries and pain among neurosurgeons especially neck and low back pain which proved to be substantially interfering with work ability.

Keywords: Musculoskeletal, Risk assessment, Cranial, Spinal

References

1) Work-Related Musculoskeletal Disorders & Ergonomics. National Center for Chronic Disease Prevention and Health Promotion. Updated February 12, 2020. Accessed November 10, 2022.
2) Human health and social work activities statistics in Great Britain, 2022. Updated March 2022. Accessed December 1, 2022
3) Berguer R. Surgery and ergonomics. Arch Surg. 1999;134:1011– 1016.
4) Epstein S, Sparer EH, Tran BN, et al. Prevalence of Work-Related Musculoskeletal Disorders Among Surgeons and Interventionalists: A Systematic Review and Metaanalysis. JAMA Surg. 2018;153(2):e174947. doi:10.1001/jamasurg.2017.4947
5) Park JY, Kim KH, Kuh SU, Chin DK, Kim KS, Cho YE. Spine surgeon's kinematics during discectomy according to operating table height and the methods to visualize the surgical field. Eur Spine J. 2012;21(12):2704-2712. doi:10.1007/s00586-012-2425-6
6) Park JY, Kim KH, Kuh SU, Chin DK, Kim KS, Cho YE. Spine surgeon's kinematics during discectomy, part II: operating table height and visualization methods, including microscope. Eur Spine J. 2014;23(5):1067-1076. doi:10.1007/s00586- 013-3125-6
7) Gadjradj PS, Ogenio K, Voigt I, Harhangi BS. Ergonomics and Related Physical Symptoms Among Neurosurgeons. World Neurosurg. 2020;134:e432-e441. doi:10.1016/j.wneu.2019.10.093
8) Auerbach JD, Weidner ZD, Milby AH, Diab M, Lonner BS. Musculoskeletal disorders among spine surgeons: results of a survey of the Scoliosis Research Society membership. Spine (Phila Pa 1976). 2011;36(26):E1715-E1721. doi:10.1097/BRS.0b013e31821cd140
9) Frymoyer JW. Lumbar disk disease: epidemiology. Instr Course Lect. 1992;41:217-223.

OP- IV/5

Graftless Primary Dural Closure Following Retrosigmoid Approach: Doing More with Less

Gokberk Erol[1], Neslihan Cavusoglu[4], Umut Tan Sevgi[3], Semih Fidan[4], Yucel Dogruel[2], Sabino Luzzi[5], Abuzer Gungor[4]

[1]Department of Neurosurgery, Faculty of Medicine, Gazi University, Ankara, Turkey
[2]Department of Neurosurgery, Yeditepe University Microsurgical Neuroanatomy Laboratory, Istanbul, Turkey
[3]Department of Neurosurgery, University of Health Sciences, Tepecik Training and Research Hospital, Izmir, Turkey
[4]Department of Neurosurgery, University of Health Sciences, Bakirkoy Research and Training Hospital for Neurology, Neurosurgery and Psychiatry, Istanbul, Turkey
[5]Department of Clinical-Surgical, Diagnostic and Pediatric Sciences, Neurosurgery Unit, University of Pavia, Pavia, Italy.

Objectives: The graftless primary dural closure technique has been linked to a zero rate of CSF leaks and bacterial meningitis following the retrosigmoid approach.A retrosigmoid linear dural incision is the key to the following graftless watertight reconstruction.

Background: Watertight dural closure is rarely possible with the retrosigmoid approach, which explains the nonnegligible rate of postoperative cerebrospinal fluid (CSF) leak.(1,2) This leakage can lead to serious complications such as meningitis.(3) Primary watertight dural closure is critical to prevent CSF fistula following the retrosigmoid approach.(4) The herein-reported study describes the proposed graftless primary dural closure technique following the retrosigmoid approach and summarizes the clinical data of the preliminary authors' experience.

Method: Clinical and surgical data of seven patients who underwent graftless primary dural closure technique following the retrosigmoid approach for various pathologies were retrospectively reviewed. Graftless reconstruction involves two critical and propaedeutic steps: a 1 cm transverse dura incision parallel to the foramen magnum to drain the CSF in the cisterna magna and a vertical linear opening of the retrosigmoid dura. The dural incisions are closed watertight with vicryl 4/0 running suture, without graft, fibrin glue, overlay hemostatic, or dural substitutes. Pre- or postoperative lumbar drainage is unnecessary.

Figure1

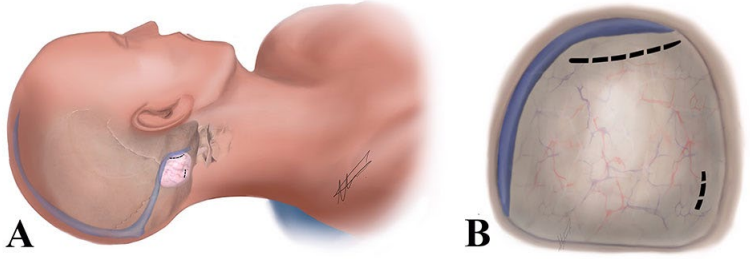

Figure 1: A, B: Dural incisions for graftless primary dural closure.

Results: A primary watertight dural closure was successfully achieved in all the patients without grafts or duraplasty.The average dura closure time was 17.8 minutes. The median hospital stay was five days. On an average follow-up of 5.8 months, no CSF leaks or meningitis occurred.

Figure2

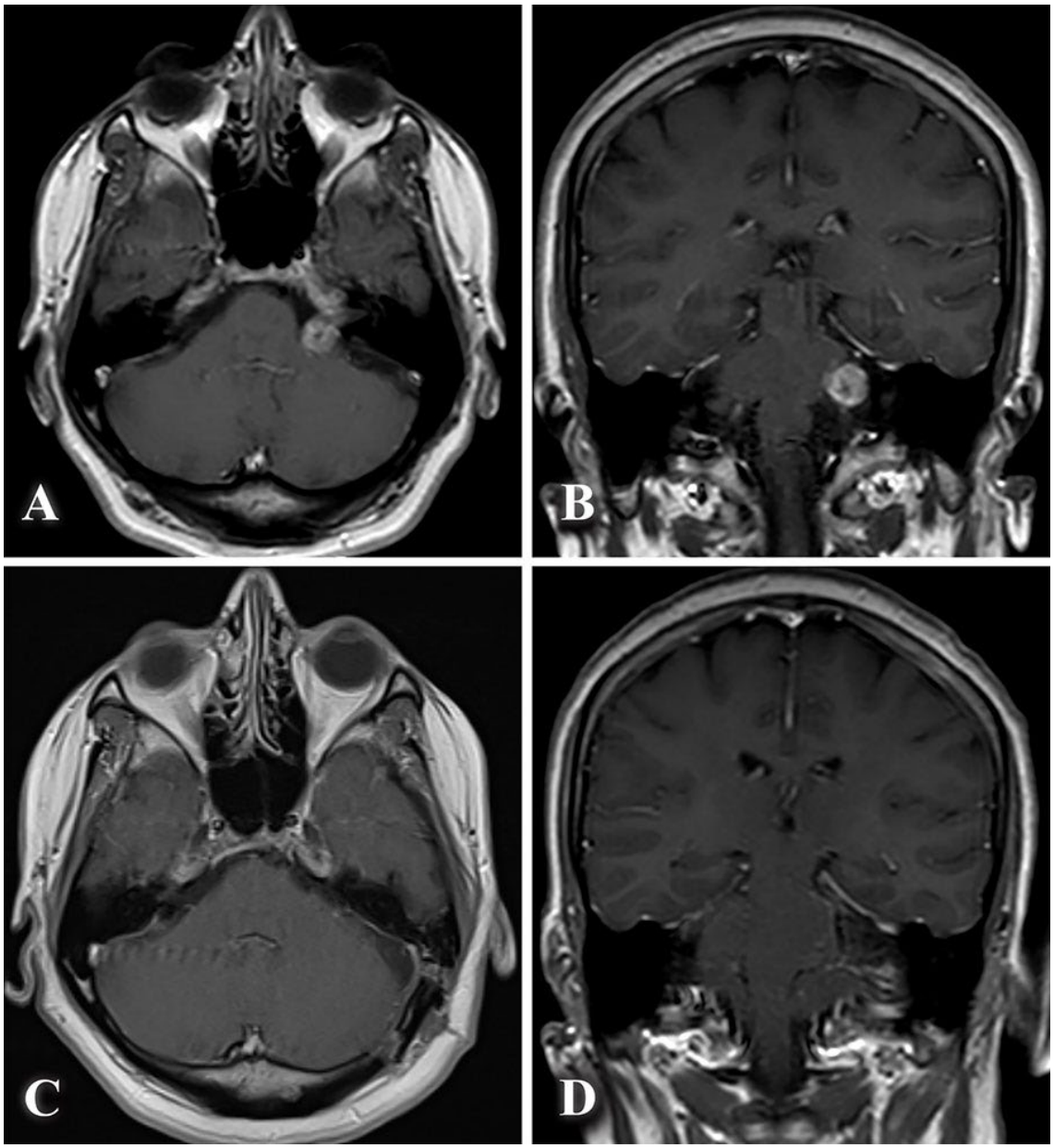

Figure 2: Pre- (A, B) and postoperative (C, D) gadolinium contrast-enhanced axial MRI of the illustrative case.

Figure3

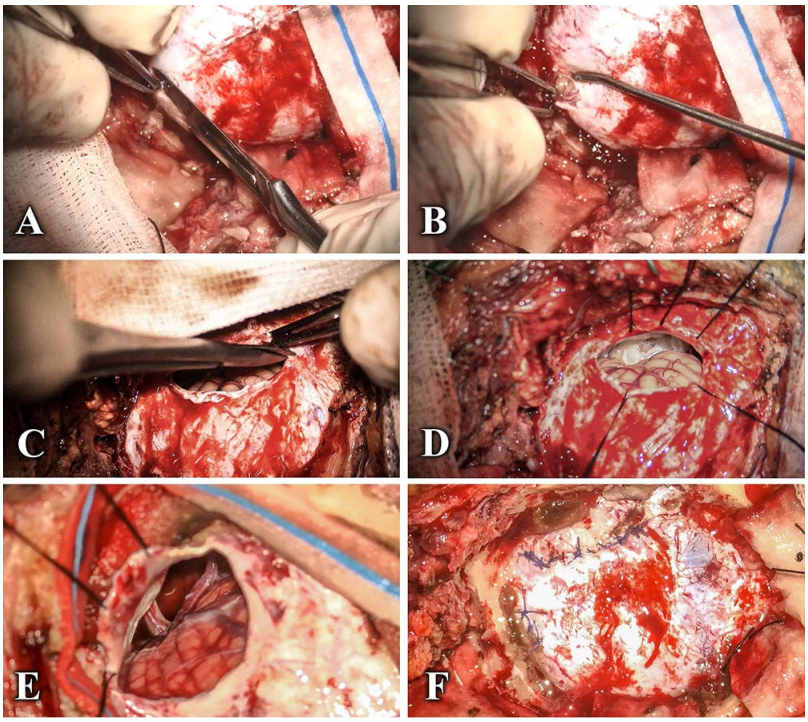

Figure 3: Intraoperative picture of the illustrative case. A, B: initial dural incision at the foramen magnum area to drain the cerebrospinal fluid. C, D: linear retrosigmoid dura opening. E: Line of sight of the microscope with the linear dural incision. F: Graftless primary dural watertight closure

Conclusions: In the authors' initial experience, the graftless primary dural closure technique has been linked to a zero rate of CSF leaks and bacterial meningitis following the retrosigmoid approach. A retrosigmoid linear dural incision is the key to the following graftless watertight reconstruction. Validation of the suggested technical note on a larger patient cohort is needed.

Keywords: CSF leak, duraplasty, retrosigmoid approach, Watertight Closure

References

1- Montano N, Signorelli F, Giordano M, et al. Factors associated with cerebrospinal fluid leak after a retrosigmoid approach for cerebellopontine angle surgery. *Surg Neurol Int.* 2021;12:258.
2- Cueva RA, Mastrodimos B. Approach design and closure techniques to minimize cerebrospinal fluid leak after cerebellopontine angle tumor surgery. *Otol Neurotol.* 2005;26(6):1176-1181.
3- Allen KP, Isaacson B, Kutz JW, Purcell PL, Roland PS. The association of meningitis with postoperative cerebrospinal fluid fistula. *J Neurol Surg B Skull Base.* 2012;73(6):401-404.
4- Venable GT, Roberts ML, Lee RP, Michael LM, 2nd. Primary Dural Closure for Retrosigmoid Approaches. *J Neurol Surg B Skull Base.* 2018;79(4):330-334.

OP- IV/6

The Role of Indocyanine Green Angiography in Preventing Vascular Malpositions during Microvascular Decompression Surgery

Mustafa SAHIN[1], Cihan Urgan[1], Burcu Goker[1], Omer Batu Hergunsel[1], Adem Yılmaz[1]

[1]Sisli Hamidiye Etfal Research Hospital

Objectives: To prevent vascular malpositions that may occur during microvascular decompression surgery in trigeminal neuralgia and to prevent possible ischemia.

Background: Microvascular decompression (MVD) is the preferred interventional treatment modality in cases of medically intractable trigeminal neuralgia(1). Although pain control rate is high and long-term outcome is favorable, the surgery harbors rare but serious complications such as cerebellar ischemia due to vascular malposition. In our study, we aimed to evaluate the integrity of the vascular structure and prevent possible ischemic complications by using indocyanine green (ICG) after Teflon decompression(2).

Method: In 12 patients who underwent MVD for trigeminal neuralgia, 5 cc ICG was injected intravenously during the operation and flow integrity was evaluated with ICG angiography.

Results: A culprit vessel was identified intraoperatively for all of the cases. Superior cerebellar artery (SCA) compression was observed in eight cases and anterior inferior cerebellar artery (AICA) compression in four cases. After ICG angiography, three cases showed disruption in flow integrity due to vascular malposition and transposition was performed to regain flow. No intraoperative reaction to ICG was observed. All patients underwent cranial magnetic resonance imaging (MRI) including diffusion-weighted imaging (DWI) and apparent diffusion coefficient (ADC) sequences within 48 hours postoperatively. None of the cases demonstrated any postoperative radiological or clinical ischemia.

Conclusions: The rates of cerebellar or brain stem ischemia after MVD for trigeminal neuralgia have been reported to be very rare. However, ischemic problems causing serious complications including mortality have been reported in various case reports. Despite the low sample size in our study, it is remarkable that ICG angiography was effective in making the transposition decision for three cases. As an easy-applicable method, ICG angiography may provide an advantage to evaluate flow integrity in transposed vessels and thus be effective for preventing ischemic complications during MVD surgery.

Keywords: Indocyanine Green Angiography, Microvascular Decompression, trigeminal neuralgia

References

1. Kaufmann AM, Price AV. A history of the Jannetta procedure. *Journal of Neurosurgery JNS*. 2020;132(2):639-646. doi:10.3171/2018.10.JNS181983Kaufmann AM, Price AV. A history of the Jannetta procedure. *Journal of Neurosurgery JNS*. 2020;132(2):639-646. doi:10.3171/2018.10.JNS181983
2. Zhang, H., Fu, W. M., Chen, P., & Shi, J. (2014). Intraoperative indocyanine green angiography during microvascular decompression surgery: report of 30 cases. *Acta neurochirurgica*, *156*, 1561-1564.

OP-III/7

Trans-eyebrow supraorbital keyhole approach with extramucosal cranialization of the frontal sinus for resection of anterobasal convexity meningiomas: technical nuances, microsurgical anatomy, and mini-series

Stefan Lieber[1], Sébastien Froelich[1]

[1]Neurosurgical Department, Lariboisière Hospital Paris

Objectives: We present a technique that amalgamates principles of keyhole skull base surgery with the advantages of a direct microscopic approach and a minimally invasive skin incision. This approach allows for preservation of the frontal sinus' mucosa, primary dural closure, and interposition of a fat graft to minimize the risk for CSF fistula and infection.

Background: Surgical access to pathologies involving the anterobasal convexity often requires a disproportionately long incision behind the hairline to mobilize the soft tissues for a basal frontal craniotomy. Endoscopic endonasal or transorbital approaches are unsuitable largely for reasons of angulation. The lateral supraorbital craniotomy provides limited exposure towards the anteromedial convexity, an extensively pneumatized frontal sinus is considered a contraindication and transgression usually avoided.

Method: A mini-series of three patients harboring small anterobasal convexity meningiomas is presented in which the extent of the frontal sinus' pneumatization and tumor attachment to its internal table rendered feasible a gross total resection via a trans-eyebrow supraorbital keyhole approach through the frontal sinus. All patients presented with size progression of their respective meningioma, two had significant perilesional edema.

Results: In all three patients of this mini-series no new neurological deficit was observed except for a transient frontal hypesthesia in one case. No meningioma recurrence, CSF fistula or facial palsy occurred, all patients were satisfied with the cosmetic outcome.

illustration of the surgical technique

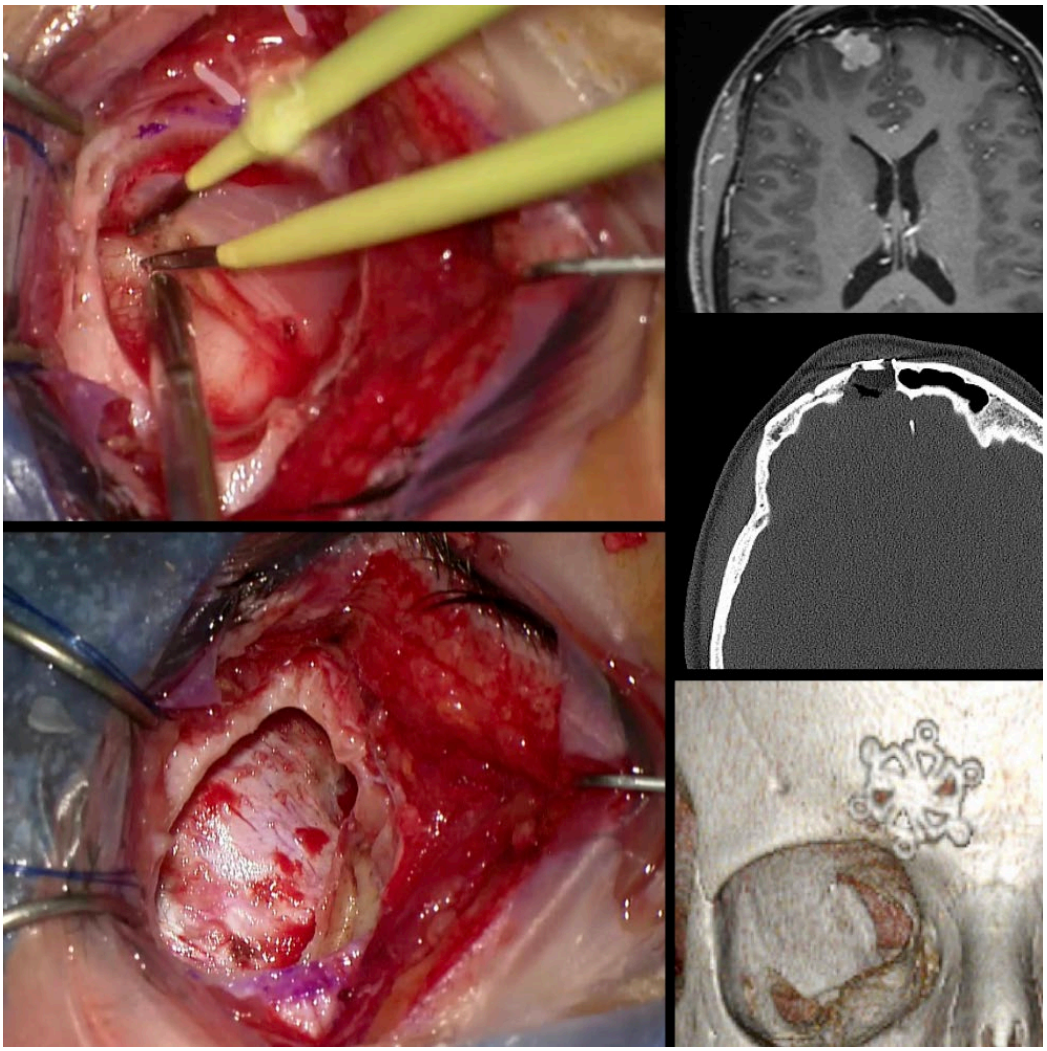

Conclusions: The described approach is a minimally invasive addition to the skullbase surgeon's armamentarium for access to pathologies involving the anterobasal convexity. In selected cases with favorable topography and morphology of frontal sinus and pathology, lesions can be removed with good functional and cosmetic outcome.

Keywords: supraorbital keyhole, frontal sinus, meningioma, extramucosal cranialization

References

1- Rhoton A (2003) Cranial Anatomy and Surgical Approaches. Lippincott

OP-III/8

Results of Intraoperative Sodium Fluorescein Video Angiography and Its Repeated Use in a Series of Brain Aneurysm Surgeries

Buruç Erkan[1], Lütfi Şinasi Postalcı[1]

[1]çam ve sakura

Objectives: To present the properities of NaF-V use in intracranial aneurysm surgery and to discuss the limitations of repeated NaF-V administration.

Background: the most significant complication of intracranial aneurysm surgery is improper clipping.Partial or complete blockage of a parent artery or perforatingarteries adjacent to an aneurysm and other arteries by clipping may result in cerebral infarction and neurological morbidity.The patency of the parent and perforating arteries branching near the aneurysm requires evaluation.Direct visual assessment of vascular flow using fluorescein dye has been practiced, and the most prevalent application thereof is the evaluation of the ocular fundus via intravenous fluorescein in various retinal disorders . Cerebral fluorescein angiography, developed by Feindel et al.), is also used to treat cerebral aneurysms . Suzuki et al. published the first report discussing sodium fluorescein video angiography (NaF-V) .

Method: The clinical findings and imaging results during and after surgery for patients with aneurysm who underwent surgery between September 2020 and June 2022 were examined. NaF-V and micro-Doppler imaging were used to control the flow of the parent and perforating arteries and obliteration of the aneurysm dome. The dose of sodium fluorescein administered via the central venous route was 5 mg/kg.

Results: Overall, 102 aneurysms were treated during 95 operations in 92 patients. NaF-V was applied at least once in all operations, twice in 17, and thrice in 3 operations. The method allowed for the desired imaging of the parent and perforating arteries in all cases but failed to provide satisfactory results regarding the complete obliteration of the aneurysm dome in three cases.

Conclusions: Sodium fluorescein is safe, with a high minimum toxic dosage, and provides benefits, even in repeated use, in the evaluation of perforating and parent arteries. NaF-V is effective when used alternatively or in combination with various methods.

Keywords: Aneurysm, Brain surgery, Sodium fluorescein

References

1. Akdemir H, Oktem IS, Tucer B, Menku A, Basşaslan K, Gunaldı O: Intraoperative microvascular Doppler sonography in aneurysm surgery. Minim Invasive Neurosurg 49:312-316, 2006
2. Bacigaluppi S, Fontanella M, Manninen P, Ducati A, Tredici G, Gentili F: Monitoring techniques for prevention of procedure- related ischemic damage in aneurysm surgery. World Neurosurg 78:276-288, 2012
3. Zhao X, Belykh E, Cavallo C, Valli D, Gandhi S, Preul MC, Vajkoczy P, Lawton MT, Nakaji P: Application of fluorescein fluorescence in vascular neurosurgery. Front Surg 6:52, 2019

OP-III/9

Navigating through the tentacles of pod- single centre institutional experience in dealing with vascular corridors in gravity assisted retractor-less occipito-transtentorial approach

rushabh chheda[1], Arun Srivastava[1], Kamlesh Bhaisora[1], Kuntal Kanti Das[1], Ashutosh kumar[1]

[1]Sanjay Gandhi Postgraduate Institute, Lucknow

Objectives: To assess the anatomical knowledge associated with the vascular corridor in the supratentorial region in the posterior aspect and the occipital region and at the same time assess the surgical nuance associated with our modification for gravity assisted retractorless occipital transtentorial approach

Background: Occipital transtentorial approach for selected posterior third ventricular or retrosplenium region tumors provides an ergonomic and safe access. Over the years, the opponents of this approach highlight the problem of postoperative visual field defect, related to the retraction of occipital lobe and ergonomic difficulties associated with same. The aim was to describe the surgical nuances of gravity-assisted retractor-less occipital-transtentorial approach (GAROTS) as a modification of originally described GAROTA to minimize the complications with a similar ease of surgery.

Method: In this study, we have retrospectively analyzed our prospectively maintained surgical databases of patients operated by occipito-transtentorial from 2015 to 2022. Demographic variables, preoperative and postoperative neurological deficits (especially visual field defect) were analyzed. Radiological data included relation of veins with tumor, presence of hydrocephalus, size, and extent of lesion.

Results: 32 patients underwent GAROTS (right-sided extension, n = 11; left-sided extension, n = 14; and midline lesions, n = 7). Headaches (71.1%) and diplopia (38%) were the most common symptoms. No patient had any postoperative visual deficits in both short-term and long-term follow-up.

Conclusions: A thorough anatomical knowledge of posterior third interhemispheric region in the semi-prone position is required for GAROTS. Meticulous arachnoid dissection around the deep venous complex and release of cerebrospinal fluid through the cisterns is required. Postoperative cortical vision loss may be prevented by following the key surgical principles in GAROTS.

Keywords: Field defect, gravity assisted, Retraction less, Transtentorial

References

1. Bassiouni H, Asgari S, König HJ, Stolke D. Meningiomas of the falcotentorial junction: Selection of the surgical approach according to the tumor type. Surg Neurol. 2008. 69: 339-49
2. Behari S, Garg P, Jaiswal S, Nair A, Naval R, Jaiswal AK. Major surgical approaches to the posterior third ventricular region: A pictorial review. J Pediatr Neurosci. 2010. 5: 97-101
3. Chi JH, Lawton MT. Posterior interhemispheric approach: Surgical technique, application to vascular lesions, and benefits of gravity retraction. Neurosurgery. 2006. 59: ONS41-9
4. Cohen-Cohen S, Cohen-Gadol AA, Gomez-Amador JL, AlvesBelo JT, Shah KJ, Fernandez-Miranda JC. Supracerebellar infratentorial and occipital transtentorial approaches to the pulvinar: Ipsilateral versus contralateral corridors. Oper Neurosurg (Hagerstown). 2019. 16: 351-9
5. Goto T, Ohata K, Morino M, Takami T, Tsuyuguchi N, Nishio A. Falcotentorial meningioma: Surgical outcome in 14 patients. J Neurosurg. 2006. 104: 47-53
6. Jameson K. Excision of pineal tumors. J Neurosurg. 1971. 35: 550-3

OP-III/10

Low-Cost Exoscope to Expand Access to Microneurosurgical Care in Low- and Middle-Income Countries

Manuel De Jesus Encarnacion Ramirez[1], Gennady Chmutin[1], Renat Nurmukhametov[1]

[1]RUDN university

Objectives: show the potential use of the low cost exoscope to become an affordable equipment for microsurgery in developing regions where they do not have the possibility of a surgical microscope

Background: Less than a quarter of the world population has access to microneurosurgical care within a range of 2 hours. We introduce a simplified exoscope system to achieve magnification, illumination, and video recording in low-resource settings.

Method: We used a 16-megapixel light-weight industrial C-mount microscope camera with a 4.5X C-mount lens and a 0.5X C-mount adapter. The camera featured automatic white balance and brightness control. The field of vision ranged from 30 mme60 mm with a 60- to 90-cm working distance. We attached the camera to a 25-mm diameter heavy-duty arm support. A portable intravenous pole allowed manual adjustment of the height. A light-emitting diode (LED) ring light, All exoscope parts were sterilized with ethylene oxide, hydrogen peroxide, or formaldehyde.

exoscope parts

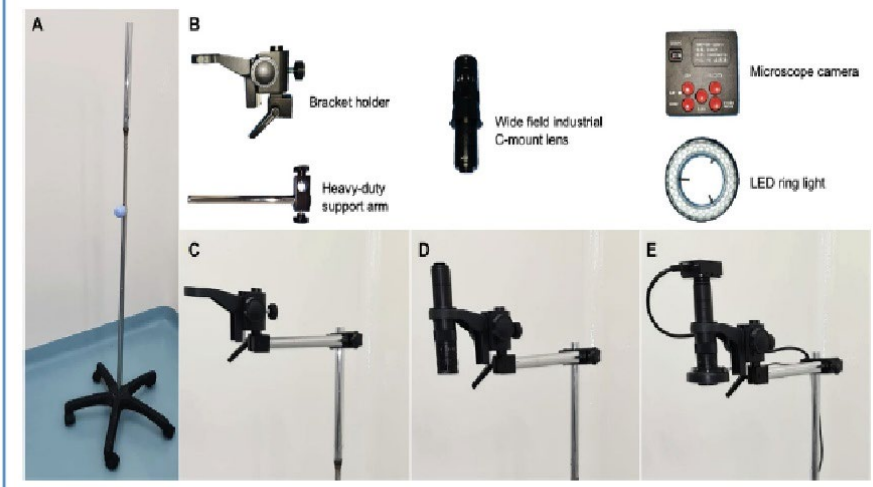

Figure 1. An adjustable intravenous pole (**A**) serves as the floor stand of our exoscope. The exoscope is then assembled by mounting the individual components (**B**) to one another in a stepwise fashion. The heavy-duty support arm is mounted to the intravenous pole. The bracket holder is attached to the free end of the support arm (**C**). The wide-field C-mount microscope tube is held by the bracket holder (**D**). The microscope camera is attached to the top of the C-mount lens. Finally, the light-emitting diode ring light is secured to the bottom of the C-mount lens (**E**).

different part of exoscope to be assamble

patients .1 cases

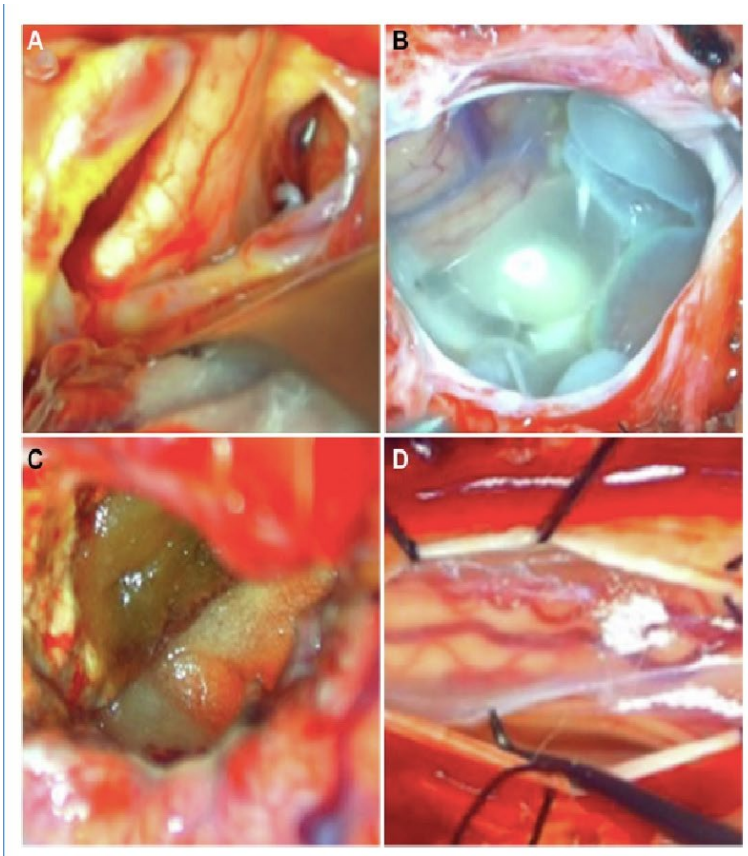

Figure 2. The surgical field as captured through the low-cost exoscope visualizing the (A) left internal carotid artery and optic chiasm of patient number 12, (B) the racemose neurocysticercosis of the posterior fossa and the (C) corresponding resection cavity in patient number 14, and (D) spinal arachnoid thickening in patient number 1.



Figure 3. The exoscope had a convenient working distance and projected the surgical field on the television screen in high definition (A). The position and angle of the exoscope as well as image focus were adjusted single-handedly (B).

example of different cases where we used the exoscope

list of components

Component Brand Specifications Cost
Microscope camera LapSun Technology Co., Ltd. (Hong Kong, China) 16-megapixel high-resolution image sensor U.S. $ 299.00
1920*1080 pixels and 60 frames per second video output
Automatic white balance and brightness control
Wide-field
industrial
C-mount lens
LapSun Technology Co., Ltd. (Hong Kong, China) Objective magnification power by 0.35e4.5X (up to 180X on
the monitor)
Included in the microscope
camera’s prize

0.5X C-mount adapter
Bracket holder LapSun Technology Co., Ltd. (Hong Kong, China) Included in the microscope camera's prize
Heavy-duty support
arm
LapSun Technology Co., Ltd. (Hong Kong, China) 25-mm diameter U.S. $ 37.68
29-cm arm length
360 rotatable
LED ring light Shenzhen Bayite Technologies Co., Ltd.
(Shenzhen, China)
White light U.S. $ 20.90
Adjustable brightness
4.5 W maximal output
Smart television TCL Technology, (Huizhou, China) 5500 LED screen U.S. $ 275.60
HDMI cable NEWLINK Cabling Systems, Inc. (Medley, FL,
USA)
U.S. $ 12.20
Intravenous pole Unknown U.S. $ 103.40
All items: $748.7
Shipping: þ$239.0
Total cost: $987.7

different part of exoscope

Results: The preoperative setup time ranged from 10 to15 minutes We zoomed through up and down movements of the camera via the support arm's vertical component that is attached to the intravenous pole. Focusing was done through a ring-type focuser located on the middle part of the microscope tube. working distance was between 40 and 60 cm . For narrow corridors to deep-seated pathologies like the right frontal lobe intra-axial cyst or the middle cerebral artery aneurysm, additional overhead lamps were needed to provide sufficient illumination. Visual quality at depth and the surgeon's comfort were superior to surgical loupes.

list of cases

Patient Number	Age, Sex	Pathology	Location	Symptoms	Preoperative Setup Time	Intraoperative Exoscope Usage (Percentage of Total Surgery Duration)	Surgical Outcome
1	46, M	Spinal arachnoid cyst	C7-T4 ventral to cord	Severe myelopathy	11.3 minutes	35 minutes, 20%	Partial drainage
2	24, F	Lumbar spondylolysis	L5 bilateral	Severe lumbar and bilateral sciatic pain	15.4 minutes	15 minutes, 10%	Successful lumbar fixation and fusion
3	39, M	Intracranial meningioma	Right frontal convexity	Generalized seizures	15.5 minutes	30 minutes, 30%	Successful gross total resection
4	61, F	Cervical herniated disc	C4-C5	Left C6 radicular pain	11.1 minutes	40 minutes, 50%	Successful complete decompression
5	41, M	Cervical hemiated disc	C5-C6	Left C6 radicular pain and numbness	10.0 minutes	1 hour, 70%	Successful complete decompression
6	51, M	Lumbar disc herniation	L3-L4 right foraminal	Right severe incapacitating sciatic pain	15.2 minutes	15 minutes, 10%	Successful complete decompression
7	41, M	Cervical hemiated disc	C5-C6	Right C6 radicular pain and numbness	10.4 minutes	1 hour, 80%	Successful complete decompression
8	49, M	Cervical herniated disc	C5-C6	Left C6 radicular pain	14.1 minutes	35 minutes, 80%	Successful complete decompression
9	71, M	Grade III traumatic dislocation	C1-C2	Quadriparesis with right-sided predominance	15.4 minutes	40 minutes, 20%	Successful complete decompression and fixation
10	55, M	Lumbar cystic schwannoma	L3-L4	Cauda equina syndrome	11.2 minutes	2 hours, 80%	Successful gross total resection
11	41, M	Dorsal subdural empyema	T4-T9 dorsal to cord	Mild myelopathy	10.3 minutes	3 hours, 100%	Successful fenestration and drainage
12	64, M	Intracranial aneurysm	Left M1 segment of the middle cerebral artery	Headache and neck stiffness	13.4 minutes	4 hours, 100%	Successful clipping
13	45, M	Lumbar extruded herniated disc	Left L5-S1	Left severe L5-S1 radicular pain	10.4 minutes	2 hours, 100%	Successful complete removal
14	44, F	Intracranial giant neurocysticercosis cyst	Right frontal lobe	Left-sided partial seizures and hemiparesis, personality changes	14.0 minutes	3 hours, 100%	Successful complete removal
15	26, F	Giant dumbbell schwannoma	Left C0-C2	Quadriparesis, severe generalized neuropathic pain	14.3 minutes	4 hours, 100%	Successful gross total resection
16	46, F	Cervical hemiated disc	C5-C6	Left cervicobrachial syndrome	12.3 minutes	1 hour, 80%	Successful complete decompression

table of list of cases

Conclusions: Assembling an exoscope from industrial microscope parts is a feasible approach to achieve high magnification and illumination at very low costs. Our exoscope proved effective in spinal surgeries in particular spine surgery, aneurysm and brain tumors surgeries. It significantly enhanced surgical ergonomics for both the first operator and the assistants.

Keywords: Low cost, Microneurosurgery, global neurosurgery

References

1. Nishiyama K. From exoscope into the next Generation.

OP-I/11

Endonasal-Endoscopic Classification of the Internal Carotid Artery And Its Relationship With Classical Historical Classifications: Unifying Terminologies to Improve Its Anatomical Understanding

Carlos Salvador Ovalle[1], Edgar Fragoza[1], Luis Arnulfo Perez[1], Aguistin Dorantes[2], Alvaro Campero[3], Albert Sufianov[4], Iype Cherian[5], Manuel Encarnación Ramírez[6], Raúl Neri Alonso[7]

[1]Department of Neurosurgery, National University of Mexico Hospital General 450, 34030, Durango, Mexico.
[2]Surgical neuroanatomy laboratory, Facultad Mexicana de Medicina, Universidad la Salle, 14070, Ciudad de México, México.
[3]Department of Neurosurgery, Hospital Padilla, 4000 Tucumán, Argentina.
[4]Federal State Budgetary Institution the Federal Center of Neurosurgery of the Ministry of Health of the Russian Federation, 625062, Tyumen, Russia
[5]Institute of Neurosciences, Krishna Vishwa Vidyapeeth, 415539 Karad, India.
[6]Department of neurosurgery, RUDN University, 121359 Moscow, Rusia.
[7]National Service of Radioneurosurgery, Centro Médico Nacional de Occidente, 44329, Guadalajara, Jalisco, México

Objectives: Identify coincidences/differences between the endonasal-endoscopic classification of the internal carotid artery (ICA) and its historical classifications, in order to improve the understanding of its anatomy. Unify the main existing terminology of the ICA segments in order to avoid nominative confusion. Carry out a simple description/correlation of the main ICA classification systems, with practical utility for the neurosurgical guild.

Background: There are multiple ICA classification systems. This essential artery for brain blood supply has bone and neurovascular relationships of neurosurgical interest since it can be found in relation to various neurosurgical pathologies. Therefore, its anatomy must be known in detail, both in its angiographic-imaging aspect, for microsurgical/endovascular approaches, and its ventral aspect, for endoscopic-endonasal approaches. There are differences between classifications, however, these may overlap each other and determine the correspondence between segments, regardless of their purpose.

Method: Literature on ICA classifications was extensively reviewed; A cadaver endonasal-endoscopic dissection study was performed, obtaining representative images of the ventral aspect of the ICA. The main existing terminology for the ICA segments was collected to find its correspondence with each other. Artistic-anatomical illustrations were made to facilitate the understanding of each classification and its relationship with the endoscopic classification.

Internal Carotid Artery and its angiographic segments

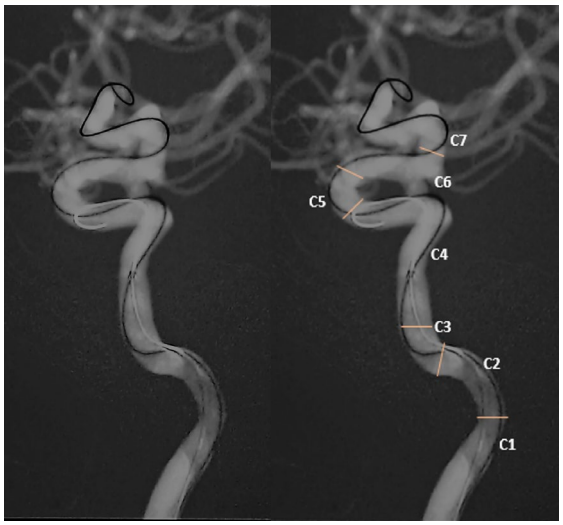

Angiographic image showing the trajectory and curvatures of the internal carotid artery as well as its segmentation according to the Boutillier classification. Catheters are observed within the lumen of the vessel because it was taken during endovascular therapy. C1: Upper portion of cervical segment; C2: Petrosal segment; C3: Lacerum segment; C4: Cavernous segment; C5, Clinoidal segment; C6 Ophthalmic segment; C7 Communicating segment. adapted and modified with permission of the author

Parapharyngeal segment of the internal carotid artery (Endonasal endoscopic view)

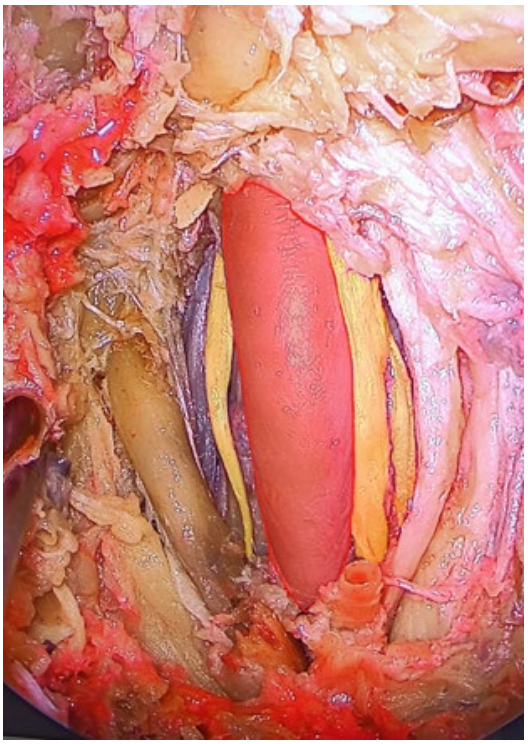

Endoscopic endonasal view of cadaveric dissection of the infratemporal fossa, where the parapharyngeal segment of the internal carotid artery and its relations with the lower cranial nerves, glossopharyngeal in lateral relation, spinal and hypoglossal in medial relation can be seen in the background; The vagus nerve cannot be seen in this photograph because it is in a posterior relationship with the internal carotid artery (it is included in other photographs of

this work), in a posterior and lateral relationship it is possible to visualize the intera jugular vein. The styloid process is also observed in a lateral situation.

Results: The shared characteristics and differences of 3 ICA classifications were compared: endonasal-endoscopic (Labib/Kassam), angiographic (Bouthillier) and anatomical (Rhoton), with a total of 17 interrelated segments, with a variety of nomenclature. The initial and terminal segments are nominatively and anatomically equivalent in all 3 classifications. There is anatomical-nominal variation in the intermediate segments. Its relationship/correspondence have been demonstrated.

Segmentation of the internal carotid artery

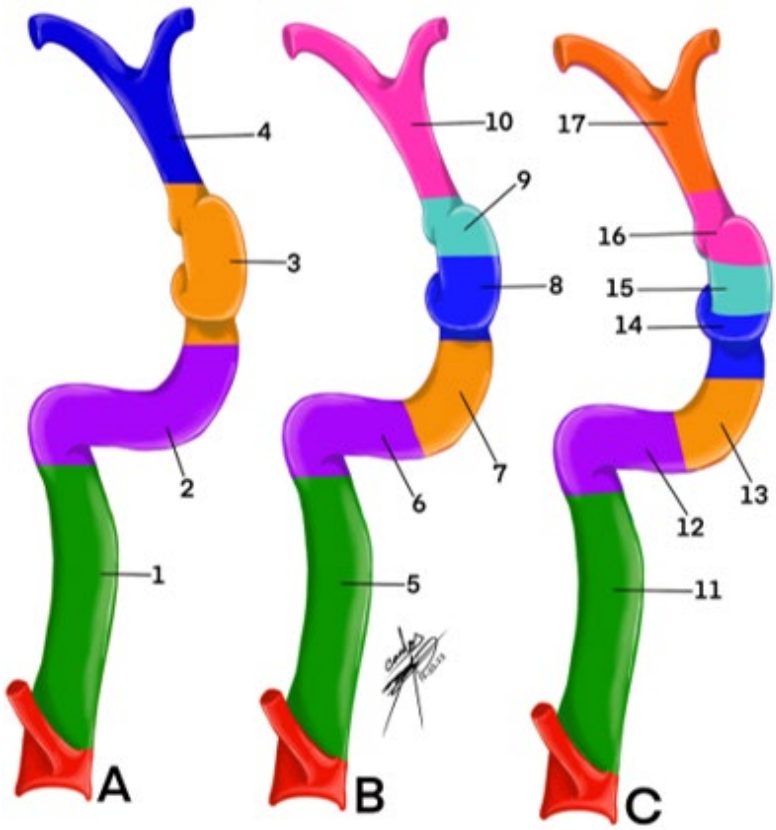

Representative artistic-anatomical illustration of the ventral aspect of the internal carotid artery and of the total sum of segments among the three classifications compared in this work, adding a total of 17 segments each with different nomenclature, presenting coincidences and variations among themselves. Figure A: segmentation according to Rhoton's anatomical classification; segments: 1.Cervical, 2.Petrosal, 3.Cavernous, 4.Supraclinoid. Figure B: Segmentation according to the Labib/Kassam endonasal endoscopic classification; segments: 5.Parapharyngeal, 6.Petrous, 7.Paraclival, 8.Parasellar, 9.Paraclinoid, 10.Intradural. Figure C: Segmentation according to Bouthillier's angiographic classification; 11.Cervical, 12.Petrous, 13.Lacerum, 14.Cavernous, 15.Clinoid, 16.Ophthalmic, 17.Communicant.

Segmentation of the internal carotid artery

Rhoton Classification	Endonasal endoscopic classification	Bouthillier classification
C1	**Parapharyngeal**	**C1**
C2	Petrous	C2
C2	Paraclival	C3
C3	Parasellar	C4
C3	Parasellar	C5
C3	Paraclinoid	C6
C4	**Intradural**	**C7**

The initial (cervical/parapharyngeal/cervical) and terminal (intradural/supraclinoid/communicating) segments are marked in bold in each classification, which are equivalent and correspond to each other. The correspondence and variation between the segments of each of the classifications is observed. finding that segment C2 of the Rhoton classification covers the petrous and paraclival carotid and is comparable to segments C2 and C3 of the Bouthillier classification; and segment C3 of the Rhoton classification covers the parasellar and supraclinoid carotid and is comparable to segments C4, C5 and C6 of the Bouthillier classification.

Conclusions: Anatomical knowledge of the microsurgical, angiographic and endonasal-endoscopic aspects of ICA, its main classifications, the relationship between them, and the diversity of nomenclature, is essential to facilitate its study and avoid anatomical-nominal confusion. It can be achieved through comparative tables/illustrations, which improves its anatomical-surgical understanding.

Keywords: Endonasal Endoscopy, Skull base, Internal carotid artery, Endoscopic classification

References

1. Alikhani P, Sivakanthan S, van Loveren H, Agazzi S. Paraclival or Cavernous Internal Carotid Artery: One Segment but Two Names. J Neurol Surg B Skull Base. 2016 Aug;77(4):304-7. doi: 10.1055/s-0035-1568870. Epub 2015 Nov 30. PMID: 27441154; PMCID: PMC4949067.

2. Bonasia S, Smajda S, Ciccio G, Bojanowski MW, Robert T. Proposed new classification for internal carotid artery segmental agenesis based on embryologic and angiographic correlation. Surg Radiol Anat. 2023 Apr;45(4):375-387. doi: 10.1007/s00276-023-03102-1. Epub 2023 Feb 14. PMID: 36786934.

3. Bouthillier A, van Loveren HR, Keller JT. Segments of the internal carotid artery: a new classification. Neurosurgery. 1996 Mar;38(3):425-32; discussion 432- doi: 10.1097/00006123-199603000-00001. PMID: 8837792.

4. Campero A, Ajler P, Alcocer V, (2019). Fosa hipofisiaria. Journal Editores, Neuroanatomia quirurgica (pag. 183-194), ISBN 978-987-4922-24-3

5. Carrau R, Kassam A, Bockmühl U, (2015). Anatomy of Anterior, Central and Posterior Skull Base, Thieme Editorial, Endonasal Endoscopic Surgery of Skull Base Tumors: An Interdiciplinary Approach (p10-38), ISBN 987-3-13-154671-5

6. Chin OY, Ghosh R, Fang CH, Baredes S, Liu JK, Eloy JA. Internal carotid artery injury in endoscopic endonasal surgery: A systematic review. Laryngoscope. 2016 Mar;126(3):582-90. doi: 10.1002/lary.25748. Epub 2015 Nov 3. PMID: 26525334.

7. Chmielewski R, Ciszek B. Internal Carotid Artery Classifi cation Systems. Pol J Aviat Med Bioeng Psychol 2018; 24(4): 27-35. DOI: 10.13174/pjambp.25.05.2020.03

8. DePowell JJ, Froelich SC, Zimmer LA, Leach JL, Karkas A, Theodosopoulos PV, Keller JT. Segments of the internal carotid artery during endoscopic transnasal and open cranial approaches: can a uniform nomenclature apply to both? World Neurosurg. 2014 Dec;82(6 Suppl):S66-71. doi: 10.1016/j.wneu.2014.07.02 PMID: 25496638.

9. Fang X, Di G, Zhou W, Jiang X. The anatomy of the parapharyngeal segment of the internal carotid artery for endoscopic endonasal approach. Neurosurg Rev. 2020 Oct;43(5):1391-1401. doi: 10.1007/s10143-019-01176-3. Epub 2019 Sep PMID: 31502030.

10. Gao F, Sun X, Guo X, Li D, Xu GD, Miao ZR. Endovascular Recanalization of Symptomatic Nonacute Intracranial Internal Carotid Artery Occlusion: Proposal of a New Angiographic Classification. AJNR Am J Neuroradiol. 2021 Jan;42(2):299-305. doi: 3174/ajnr.A6928. Epub 2020 Dec 24. PMID: 33361380; PMCID: PMC7872178.

11. Gibo H, Lenkey C, Rhoton AL Jr. Microsurgical anatomy of the supraclinoid portion of the internal carotid artery. J Neurosurg. 1981 Oct;55(4):560-74. doi: 10.3171/jns.1981.55.4.0560. PMID: 7277004.

12. Ismail M, Darwish M, Gomma M, Herzallah IR, El Tahan AER. Endoscopic Orientation of Juxta-Pituitary Carotid in Transsphenoidal Approaches: Critical Considerations for Clinical Applications. Indian J Otolaryngol Head Neck Surg. 2021 Dec;73(4):461-466. doi: 10.1007/s12070-021-02454-7. Epub 2021 Feb 23. PMID: 34692458; PMCID: PMC8520556.

13. Iwanaga J, Anand MK, Camacho A, Rodriguez F, Watson C, Caskey EL, Dumont AS, Tubbs RS. Surgical anatomy of the internal carotid plexus branches to the abducens nerve in the cavernous sinus. Clin Neurol Neurosurg. 2020 Apr;191:105690. doi: 10.1016/j.clineuro.2020.105690. Epub 2020 Jan 21. PMID: 31982693.

14. Joo W, Funaki T, Yoshioka F, Rhoton AL Jr. Microsurgical anatomy of the carotid cave. Neurosurgery. 2012 Jun;70(2 Suppl Operative):300-11; discussion 311-2. doi: 10.1227/NEU.0b013e3182431767. PMID: 22113241.

15. Kang YJ, Cho JH, Kim DH, Kim SW. Relationships of sphenoid sinus pneumatization with internal carotid artery characteristics. PLoS One. 2022 Aug 25;17(8):e0273545. doi: 10.1371/journal.pone.0273545. PMID: 36006952; PMCID: PMC9409539.

16. Kassam A, Labib MA, Prevedello DM, Carrau R. In Reply: An Endoscopic Roadmap of the Internal Carotid Artery. Neurosurgery. 2015 Jul;77(1):E154-5. doi: 10.1227/NEU.0000000000000770. PMID: 25856115.

17. Kassam AB, Vescan AD, Carrau RL, Prevedello DM, Gardner P, Mintz AH, Snyderman CH, Rhoton AL. Expanded endonasal approach: vidian canal as a landmark to the petrous internal carotid artery. J Neurosurg. 2008 Jan;108(1):177-83. doi: 10.3171/JNS/2008/108/01/0177. PMID: 18173330.

18. Kurbanov A, Zimmer LA, Theodosopoulos PV, Leach JL, Keller JT. An Endoscopic Roadmap of the Internal Carotid Artery. Neurosurgery. 2015 Jul;77(1):E153-4. doi: 10.1227/NEU.0000000000000769. PMID: 25856114.

19. Labib MA, Prevedello DM, Carrau R, Kerr EE, Naudy C, Abou Al-Shaar H, Corsten M, Kassam A. A road map to the internal carotid artery in expanded endoscopic endonasal approaches to the ventral cranial base. Neurosurgery. 2014 Sep;10 Suppl 3:448-71; discussion 471. doi: 10.1227/NEU.0000000000000362. PMID: 24717685.

20. Marcati E, Andaluz N, Froelich SC, Zimmer LA, Leach JL, Fernandez-Miranda JC, Kurbanov A, Keller JT. Paratrigeminal, Paraclival, Precavernous, or All of the Above? A Circumferential Anatomical Study of the C3-C4 Transitional Segment of the Internal Carotid Artery. Oper Neurosurg (Hagerstown). 2018 Apr 1;14(4):432-440. doi: 10.1093/ons/opx121. PMID: 28531285.

21. Melé MV, Puigdellívol-Sánchez A, Mavar-Haramija M, Juanes-Méndez JA, Román LS, De Notaris M, Catapano G, Prats-Galino A. Review of the main surgical and angiographic-oriented classifications of the course of the internal carotid artery through a novel interactive 3D model. Neurosurg Rev. 2020 Apr;43(2):473-482. doi: 10.1007/s10143-018-1012-7. Epub 2018 Jul 26. PMID: 30051302.

22. Newman H, Milne N, Lewis SB. Neurosurgical Anatomy of the Internal Carotid Artery: Magnetic Resonance Imaging Study of the Sellar Region. World Neurosurg. 2020 Jan;133:e711-e715. doi: 10.1016/j.wneu.2019.09.145. Epub 2019 Oct 4. PMID: 31589983.

23. Osawa S, Rhoton AL Jr, Tanriover N, Shimizu S, Fujii K. Microsurgical anatomy and surgical exposure of the petrous segment of the internal carotid artery. Neurosurgery. 2008 Oct;63(4 Suppl 2):210-38; discussion 239. doi: 10.1227/01.NEU.0000327037.75571.10. PMID: 18981828.

24. Paullus WS, Pait TG, Rhoton AI Jr. Microsurgical exposure of the petrous portion of the carotid artery. J Neurosurg. 1977 Nov;47(5):713-26. doi: 10.3171/jns.1977.47.5.0713. PMID: 908935.

25. Prasad KC, Gupta A, Induvarsha G, Anjali PK, Vyshnavi V. Microsurgical anatomy of the internal carotid artery at the skull base. J Laryngol Otol. 2022 Jan;136(1):64-67. doi: 10.1017/S0022215121003406. Epub 2021 Nov 2. PMID: 34725000.

26. Quisling RG, Rhoton AL Jr. Intrapetrous carotid artery branches: radioanatomic analysis. Radiology. 1979 Apr;131(1):133-6. doi: 10.1148/131.1.133. PMID: 424573.

27. Seoane E, Rhoton AL Jr, de Oliveira E. Microsurgical anatomy of the dural collar (carotid collar) and rings around the clinoid segment of the internal carotid artery. Neurosurgery. 1998 Apr;42(4):869-84; discussion 884-6. doi: 10.1097/00006123-199804000-00108. PMID: 9574652.

28. Shapiro M, Becske T, Riina HA, Raz E, Zumofen D, Jafar JJ, Huang PP, Nelson PK. Toward an endovascular internal carotid artery classification system. AJNR Am J Neuroradiol. 2014 Feb;35(2):230-6. doi: 10.3174/ajnr.A3666. Epub 2013 Aug 8. PMID: 23928138; PMCID: PMC7965739.

29. Wang C, Xie J, Cui D, Cheng Y, Zhang S. A new classification of cavernous segment of the internal carotid artery. J Craniofac Surg. 2013 Jul;24(4):1418-22. doi: 10.1097/SCS.0b013e318292c970. PMID: 23851822.

30. Ziyal IM, Ozgen T, Sekhar LN, Ozcan OE, Cekirge S. Proposed classification of segments of the internal carotid artery: anatomical study with angiographical interpretation. Neurol Med Chir (Tokyo). 2005 Apr;45(4):184-90; discussion 190-1. doi: 10.2176/nmc.45.184. PMID: 15849455.

OP-III/12

Morphological variations of ventricular anatomy in hydrocephalus based on endoscopic management

Demet Evleksiz Karımzada[1], Mehmet Can Ezgu[1]

[1]Gulhane Training and Research Hospital

Objectives: Defining normal and abnormal endoscopic ventricular anatomy in hydrocephalus of different etiologies. To contribute to the endoscopic intraventricular anatomy literature by determining normal and abnormal ventricular anatomy

Background: Hydrocephalus is a prevalent condition in pediatric neurosurgery that often necessitates surgical intervention, commonly in the form of shunt surgery. Despite advancements in shunt technology, complications related to shunt procedures remain a frequent occurrence. The utilization of endoscopic intraventricular surgical techniques is progressively increasing as they offer the advantage of reducing shunt dependency. A comprehensive understanding of both the normal ventricular anatomy and the variations resulting from diverse etiologies is crucial for the successful performing of endoscopic ventricular surgery.

Method: Endoscopic surgical video images of pediatric patients who underwent endoscopic lavage, endoscopic third ventriculostomy and endoscopic fenestration surgery for hydrocephalus between January 2017 and December 2022 were analyzed. The anatomical structures, anomalies and variations that could be seen endoscopically in the lateral ventricles and third ventricle were identified.

Results: Of the 20 patients, 7 were female(35%) and 13 were male(65%) with a mean age of 43.45 days. Post-infectious hydrocephalus was observed in 3 patients(15%)(Figure 1), post-hemorrhagic hydrocephalus in 4 patients(20%)(Figure 2), and obstructive hydrocephalus in 13 patients(65%)(Figure3). The most common lateral ventricular abnormality in all patients was abnormal ventricular septations(75%), followed by deformed foramen of Monro(65%) and particulate ependyma(65%)(Table 1). Among the third ventricle abnormalities, the most frequently observed were unrecognizable interthalamic adhesions and lamina terminalis(Table 2).

Figure 1

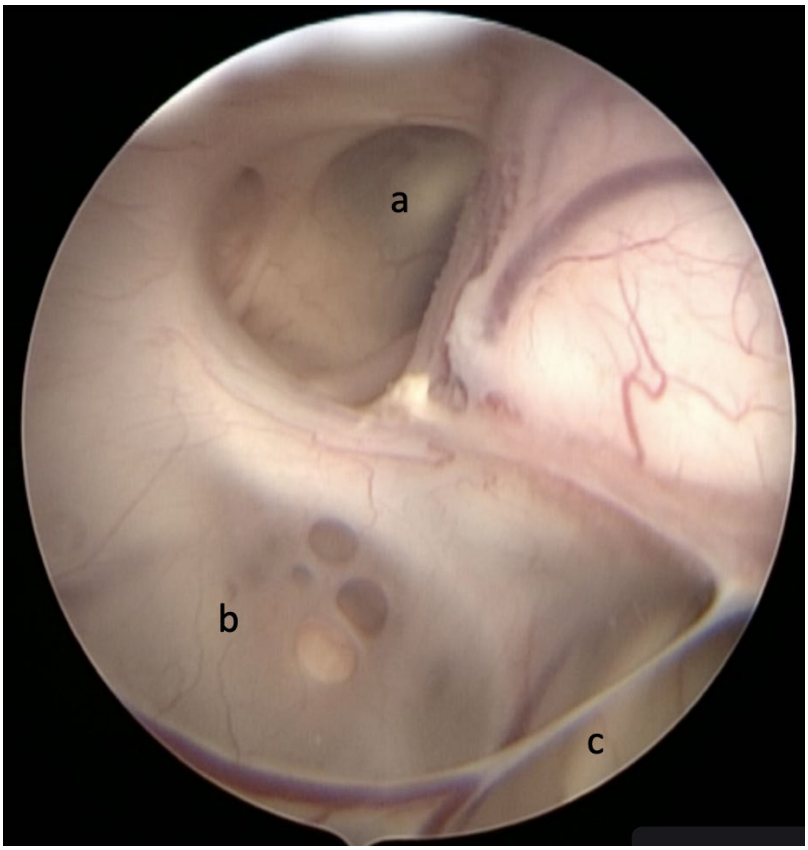

Endoscopic lateral ventricle view of a post-infectious hydrocephalus patient. a)deformed foramen of Monro, b)perforated septum, c)abnormal intraventricular septation.

Figure 2

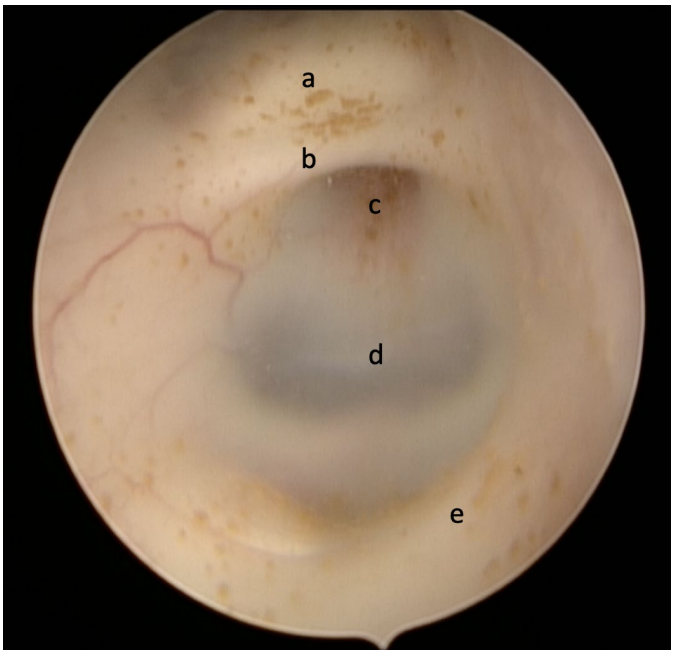

Third ventricle floor after intra-ventricular hemorrhage. a)dorsum sella and particulated ependyma, b)optic chiasm, c) unrecognizable infundibulum, d)unrecognizable basilar artery, e)unrecognizable mammillary body.

Figure 3

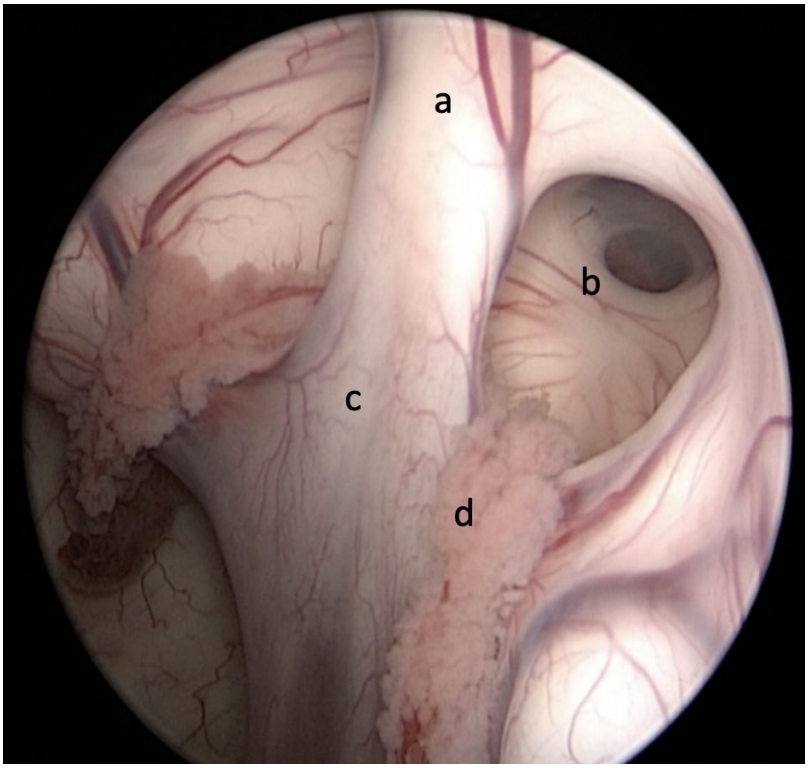

Both lateral ventricles of a obstructive hydrocephalus patient. a)anterior septal vein, b) foramen of Monro, c) absence of septum pellucidum, d)choroid plexus.

Table 1

Lateral ventricle	**Obstructive (13/20)**	**Post-hemorrhagic (4/20)**	**Post-hemorrhagic (4/20)**	**Total (20/20)**
Septum pellucidum				
Absence	6/13	1/4	1/3	8/20
Defective	3/13	2/4	1/3	6/20
Normal	4/13	1/4	1/3	6/20
Anterior septal vein				
Absence	7/13	3/4	1/3	11/20
Atypical	1/13	0/4	1/3	2/20
Normal	5/13	1/4	1/3	7/20

Thalamostriate vein				
Absence	6/13	3/4	1/3	10/20
Atypical	4/13	1/4	1/3	6/20
Normal	3/13	0/4	1/3	4/20
Choroid plexus				
Absence	3/13	1/4	0/3	4/20
Atypical	6/13	3/4	2/3	11/20
Normal	4/13	0/4	1/3	5/20
Fornix				
Absence	4/13	0/4	0/3	4/20
Atypical	8/13	2/4	2/3	12/20
Hypoplasic Dysplasic	4/13 4/13	2/4 0/4	2/3 0/3	8/20 4/20
Normal	1/13	2/4	1/3	4/20
Ependyma				
Normal	5/13	0/4	2/3	7/20
Particulate	8/13	4/4	1/3	13/20
Abnormal intraventricular septations				
Present	10/13	4/4	1/3	15/20
None	3/13	0/4	2/3	5/20
Foramen of Monro				
Absence	3/13	0/4	1/3	4/20
Deformed	9/13	3/4	1/3	13/20
Normal	1/13	1/4	1/3	3/20

Lateral ventricle findings

Table 2

Third ventricle	Obstructive (13/20)	Post-hemorrhagic (4/20)	Post-infective (3/20)	Total (20/20)
Translucent ventricle floor				
Translucent	6/13	2/4	2/3	10/20
Opaque	7/13	2/4	1/3	10/20
Abnormal intraventricular septations				
Present	10/13	1/4	1/3	12/20
None	3/13	3/4	2/3	8/20
Atypical vascular structures				
Present	8/13	2/4	1/3	11/20
None	5/13	2/4	2/3	9/20
Mammillary body				
Recognizable	5/13	2/4	3/3	10/20
Unrecognizable	8/13	2/4	0/3	10/20
Tuber cinereum				
Recognizable	8/13	4/4	3/3	15/20
Unrecognizable	5/13	0/4	0/3	5/20
Infundibulum				
Recognizable	6/13	2/4	3/3	11/20
Unrecognizable	7/13	2/4	0/3	9/20
Optic chiasm				
Recognizable	4/13	2/4	3/3	9/20
Unrecognizable	9/13	2/4	0/3	11/20
Lamina terminalis				
Recognizable	3/13	1/4	2/3	6/20
Unrecognizable	10/13	3/4	1/3	14/20
Interthalamic adhesion				
Recognizable	3/13	0/4	3/3	6/20
Unrecognizable	10/13	4/4	0/3	14/20

Basilar artery					
Recognizable	7/13	3/4	2/3	12/20	
Unrecognizable	6/13	1/4	1/3	8/20	
Aquaduct					
Recognizable	8/13	1/4	2/3	11/20	
Unrecognizable	5/13	3/4	1/3	9/20	

Third ventricle findings

Conclusions: Hydrocephalus is characterized by increased intracranial pressure and impaired brain compliance, leading to alterations in the anatomy of intraventricular structures. Moreover, significant congenital ventricular developmental anomalies are frequently observed in this patient population. As a result, the visualization of normal ventricular anatomy becomes challenging, making endoscopic orientation more difficult. The identification of endoscopic anatomy and variations in these cases will enhance the chances of performing safe surgery.

Keywords: Endoscopic anatomy, Lateral ventricle, Third ventricle, Hydrocephalus

References

1. Park YS. Treatment Strategies and Challenges to Avoid Cerebrospinal Fluid Shunting for Pediatric Hydrocephalus. Neurol Med Chir (Tokyo). 2022;62(9):416-430.
2. Estey CM. Congenital Hydrocephalus. Vet Clin North Am Small Anim Pract. 2016;46(2):217-229.
3. Pavez A, Salazar C, Rivera R, et al. Description of endoscopic ventricular anatomy in myelomeningocele. Minim Invasive Neurosurg. 2006;49(3):161-167.
4. Decq P. Endoscopic Anatomy of the Ventricles. In: Cinalli G, Sainte-Rose C, Maixner WJ, eds. Pediatric Hydrocephalus. Springer Milan; 2005:351-359.

OP-III/13

Presurgical Radiological Verification the Feasibility of the Neuronavigated Minimally Invasive Presigmoidal Suprabulbar Infralabyrinthine Approach to the Petrous Bone Without Decompression of the Jugular Bulb and Without Rerouting of the Facial Nerve.

Zafer Cinibulak[1]

[1]Department of Neurosurgery, Merheim Hospital/University of Witten/Herdecke, Cologne, Germany

Objectives: The objective of this study is to define presurgically radiological measurements on cranial computed tomography to prove the feasibility of the navigated presigmoidal suprabulbar infralabyrinthine approach (NaMIPSI-A) without decompression of the jugular bulb (JB) and without rerouting of the facial nerve (FN).

Background: Approach to intraosseous petrous body lesions.

Method: The NaMIPSI-A was performed on randomly selected human specimens. Vertical and horizontal distances of the infralabyrinthine space were measured radiologically on computed tomography prior dissection. After dissection, the area of access was evaluated on the specimens. The infralabyrinthine access to the petrous body was categorized by two raters independently. Finally, the vertical and horizonatl distances each were correlated with the area of access.

Results: Fourteen human specimens dissected on both sides, 54% obtained appropriate access to the petrous body. A significant and very high positive correlation (r = 0.99) was observed with the vertical distance. Radiologically measured vertical distances above 5.2 mm showed suitable infralabyrinthine access to the petrous body via the NaMIPSI-A without decompression of the JB and without rerouting of the FN.

Presurgical MRI

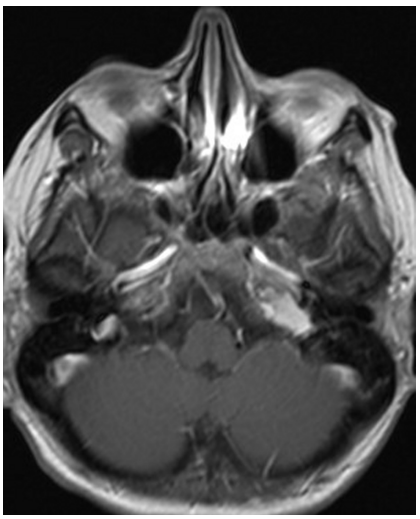

56-year-old man with left-sided chondrosarcoma at the PB and PA

Postsurgical MRI



Verification of the GTR of the tumor via the infralabyrinthine approach.

Conclusions: Prior surgery, vertical radiological measured infralabyrinthine distances above 5.2 mm gain suitable access to selected petrous body lesions with low morbidity via the NaMIPSI-A without decompression of the JB and without rerouting of the FN.

Keywords: Neuronavigation, Skull Base, Infralabyrinthine Approach, Jugular Bulb

References

1. Bawornvaraporn U, Zomorodi AR, Friedman AH, Fukushima T. Neurosurgical management of petrous bone lesions: classification system and selection of surgical approaches. Acta Neurochir (Wien). 2021;163(10):2895-2907.
2. Meling TR, Zegarek G, Schaller K. How I do it: retrosigmoid intradural inframeatal petrosectomy. Acta Neurochir (Wien). 2021;163(3):649-653.
3. Samii M, Metwali H, Samii A, Gerganov V. Retrosigmoid intradural inframeatal approach: indications and technique. Neurosurgery. 2013;73(1 Suppl Operative):ons53-9; discussion ons60.
4. Serioli S, Agosti E, Buffoli B et al. Microsurgical transcranial approaches to the posterior surface of petrosal portion of the temporal bone: quantitative analysis of surgical volumes and exposed areas. Neurosurg Rev. 2023;46(1):48.
5. Zanoletti E, Mazzoni A, Martini A et al. Surgery of the lateral skull base: a 50-year endeavour. Acta Otorhinolaryngol Ital. 2019;39(SUPPL. 1):S1-S146.
6. Lee WJ, Hong SD, Woo KI et al. Endoscopic endonasal and transorbital approaches to petrous apex lesions. J Neurosurg. 2022;136(2):431-440.
7. Paluzzi A, Gardner P, Fernandez-Miranda JC et al. Endoscopic endonasal approach to cholesterol granulomas of the petrous apex: a series of 17 patients: clinical article. J Neurosurg. 2012;116(4):792-79

8. Wang EW, Zanation AM, Gardner PA et al. ICAR: endoscopic skull-base surgery. Int Forum Allergy Rhinol. 2019;9(S3):S145-S365.
9. Zanation AM, Snyderman CH, Carrau RL, Gardner PA, Prevedello DM, Kassam AB. Endoscopic endonasal surgery for petrous apex lesions. Laryngoscope. 2009;119(1):19-25
10. Zheng Z, Otten ML, Bruce JN, Gudis DA. Endoscopic Petrous Apex Surgery: The Utilization of Frontal Sinus Instrumentation. J Craniofac Surg. 2020;31(8):2317-2319.
11. Bruchhage KL, Wollenberg B, Leichtle A. Transsphenoidal and infralabyrinthine approach of the petrous apex cholesterol granuloma. Eur Arch Otorhinolaryngol. 2017;274(7):2749-2756.
12. Cinibulak Z, Krauss JK, Nakamura M. Navigated minimally invasive presigmoidal suprabulbar infralabyrinthine approach to the jugular foramen without rerouting of the facial nerve. Neurosurgery. 2013;73(1 Suppl Operative):ons3-15.
13. Cinibulak Z, Al-Afif S, Nakamura M, Krauss JK. Surgical treatment of selected tumors via the navigated minimally invasive presigmoidal suprabulbar infralabyrinthine approach without rerouting of the facial nerve. Neurosurg Rev. 2022;45(5):3219-3229.
14. Cömert E, Cömert A, Çay N, Tunçel Ü, Tekdemir İ. Surgical Anatomy of the Infralabyrinthine Approach. Otolaryngol Head Neck Surg. 2014;151(2):301-307.
15. Jacob CE, Rupa V. Infralabyrinthine approach to the petrous apex. Clin Anat. 2005;18(6):423-427.
16. Wilson DF, Hodgson RS. Transmastoid infralabyrinthine approach to petrous temporal bone. Skull Base Surg. 1991;1(3):188-190.
17. Moussazadeh N, Kulwin C, Anand VK et al. Endoscopic endonasal resection of skull base chondrosarcomas: technique and early results. J Neurosurg. 2015;122(4):735-742.
18. Fisch U. Infratemporal fossa approach for lesions in the temporal bone and base of the skull. Adv Otorhinolaryngol. 1984;34254-266.
19. House WF. Transcochlear approach to the petrous apex and clivus. Trans Sect Otolaryngol Am Acad Ophthalmol Otolaryngol. 1977;84(5):ORL927-31.
20. Sanna M, Mazzoni A, Saleh EA, Taibah AK, Russo A. Lateral approaches to the median skull base through the petrous bone: the system of the modified transcochlear approach. J Laryngol Otol. 1994;108(12):1036-1044.
21. Shah VA, Yang GS, Randhawa S, Hansen MR, Lee AG. Cerebral venous sinus thrombosis following jugular bulb decompression. Semin Ophthalmol. 2006;21(1):41-44.
22. Borghei-Razavi H, Shibao S, Schick U. Anatomical variations of the presigmoid suprabulbar infralabyrinthine approach. Neurosurgery. 2015;76(2):E242-3.
23. Lambert PR, Johns ME, Winn RH. Infralabyrinthine approach to skull-base lesions. Otolaryngol Head Neck Surg. 1985;93(2):250-258.
24. Couloigner V, Grayeli AB, Bouccara D, Julien N, Sterkers O. Surgical treatment of the high jugular bulb in patients with Ménière's disease and pulsatile tinnitus. Eur Arch Otorhinolaryngol. 1999;256(5):224-229.
25. Miller M, Pearl MS, Wyse E, Olivi A, Francis HW. Decompression of the Jugular Bulb for Enhanced Infralabyrinthine Access to the Petroclival Region: A Quantitative Analysis. J Neurol Surg B Skull Base. 2016;77(3):249-259.
26. Kawano H, Tono T, Schachern PA, Paparella MM, Komune S. Petrous high jugular bulb: a histological study. Am J Otolaryngol. 2000;21(3):161-168.
27. Sure U, Alberti O, Petermeyer M, Becker R, Bertalanffy H. Advanced image-guided skull base surgery. Surg Neurol. 2000;53(6):563-72; discussion 572.

OP-14

Anterior Interhemispheric Transcallosal Approach For a Pilocytic Astrocytoma in the Globus Pallidus

Feride Bulgur[1], Semih Fidan[1], Neslihan Çavuşoğlu[1], Abuzer Güngör[1]

[1]T.C. Sağlık Bakanlığı İstanbul Bakırköy Prof. Dr. Mazhar Osman Ruh Sağlığı ve Sinir Hastalıkları Eğitim ve Araştırma Hastanesi

Objectives: To describe the feasibility of the Anterior Interhemispheric Transcallosal approach for resection of globus pallidus tumors.

Background: Basal ganglia region tumors are relatively rare and majority being astrocytomas (1), with the selection of the best surgical approach, gross total resection yields satisfactory outcomes. Due to their deep location and important anatomical relations, surgery in this area is particularly difficult.

Method: 10-year-old girl presented with left sided weakness. Imaging studies revealed a heterogeneously enhancing mass in the globus pallidus composed of both solid and cystic components. Postero-medial displacement of the corticospinal tract by the tumor was seen on Tractography MRI. The Anterior Interhemispheric Transcallosal approach was attempted for the resection of the tumor. After standard interhemispheric dissection, entry point to the tumor through anterior limb of the internal capsule is planned with the help of neuronavigation. Thereafter, the tumor is resected using the microsurgical technique.

Pre-operative imaging

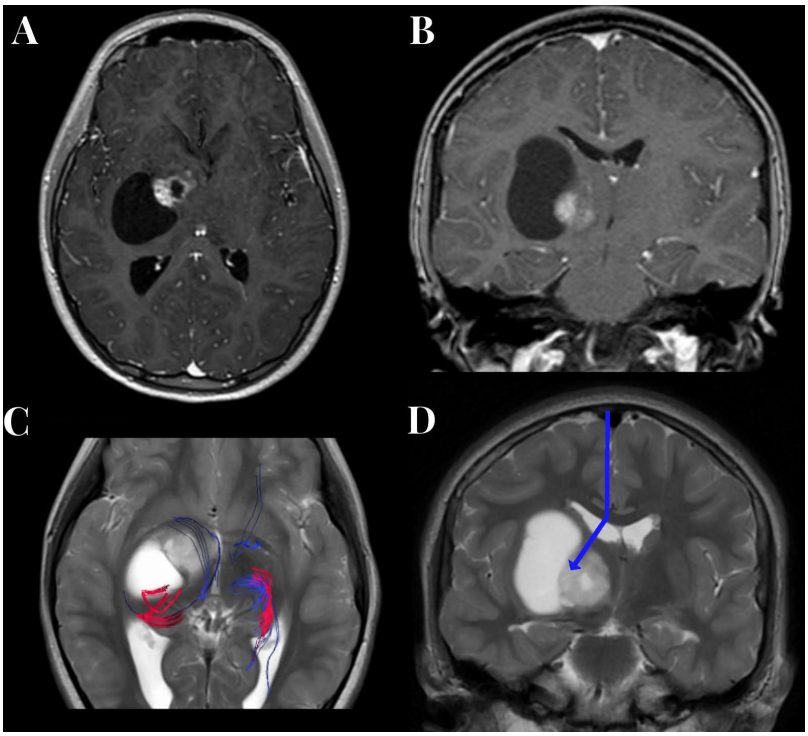

Pre-operative magnetic resonance imaging (MRI) of the brain; T1W postcontrast images (A-B) demonstrating a heterogeneously enhancing mass and accompanying cyst in the globus pallidus, overall measuring up to 5x4.3x3 cm in maximum diameter. Tractography MRI (C) shows postero-medial displacement of the corticospinal tract. Coronal T2W image demonstrating the surgical trajectory (D)

Intra-operative and Dissection Images

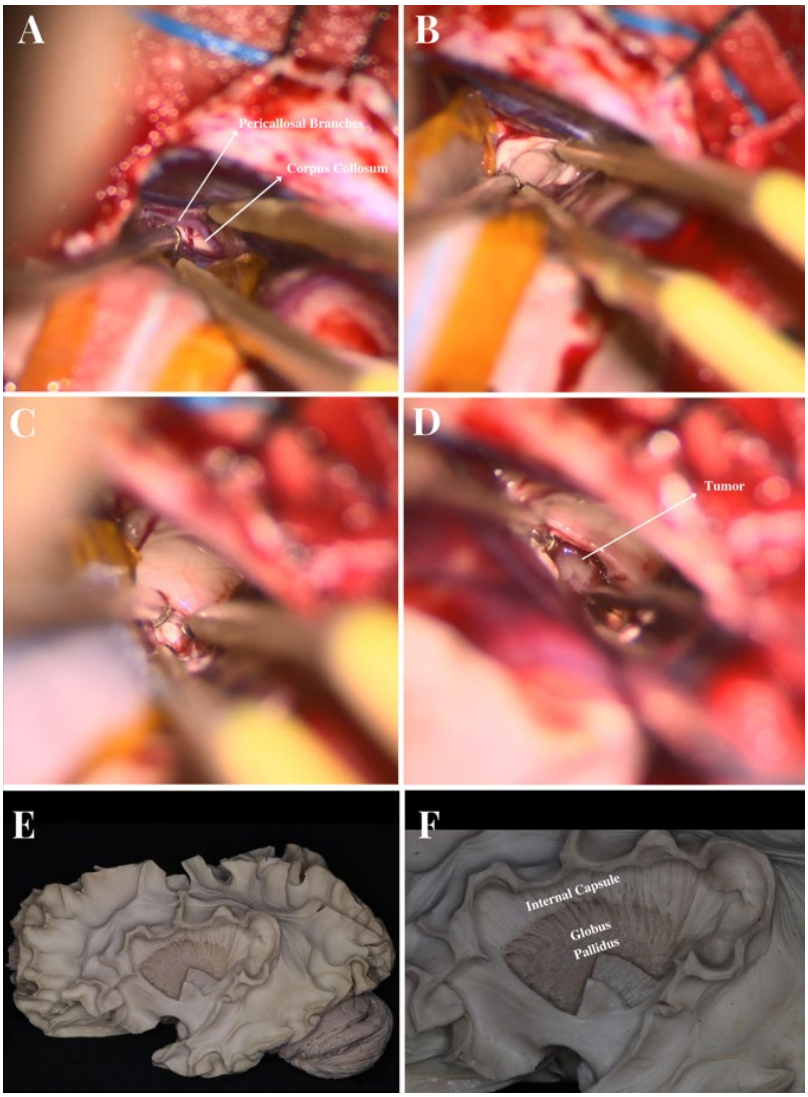

Intra-operative images showing the right interhemispheric dissection and pericallosal branches (A), callosotomy parallel to the corpus collosum fibers (B), entry point through the anterior limb of the internal capsule (C), tumor (D). Lateral hemispheric dissection shows the globus pallidus lateral to the internal capsule (E-F)

Results: Post-operative imaging showed gross total resection of the tumor and early post operative recovery of muscle power of the left hand was observed.

Post-op Imaging

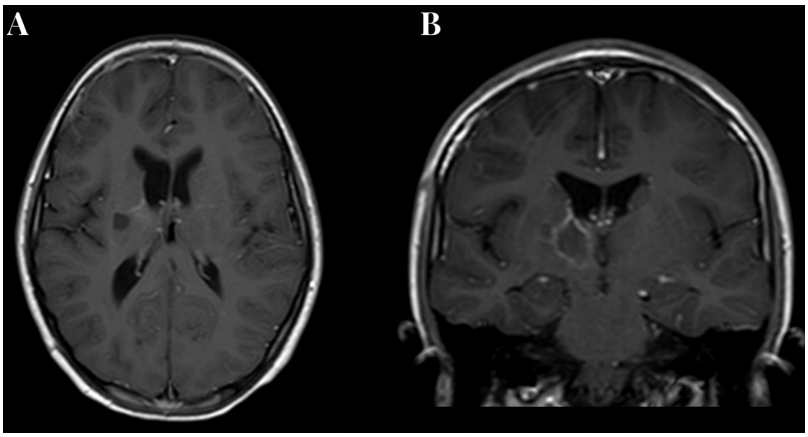

Post-operative contrast-enhanced T1W axial (A) and coronal (B) images demonstrating the gross total excision of the tumor

Conclusions: Interhemispheric Transcallosal approach not only avoids transecting the cortical fibers which might otherwise result in new neurological deficits and put putamen at risk in case of trans-insular approach but also provides a perforator free route (2) thus providing a safer trajectory to reach the basal ganglia. While it uses anatomical landmarks for intraoperative orientation, presence of bridging veins and pericallosal arteries in the surgical trajectory, necessitates meticulous handling of these structures. We thus conclude that globus pallidus tumors can be resected through Anterior Interhemispheric Transcallosal Approach with satisfactory post operative outcomes.

Keywords: Anterior Interhemispheric Transcallosal, Basal ganglia, Globus Pallidus, Internal Capsule

References

1. Ostrom, Q. T., Price, M., Ryan, K., Edelson, J., Neff, C., Cioffi, G., Waite, K. A., Kruchko, C., & Barnholtz-Sloan, J. S. (2022). CBTRUS Statistical Report: Pediatric Brain Tumor Foundation Childhood and Adolescent Primary Brain and Other Central Nervous System Tumors Diagnosed in the United States in 2014-2018. *Neuro-Oncology*, *24*(3), iii1–iii38.
2. Abla, A. A., Spetzler, R. F., & Albuquerque, F. C. (2013). Trans-striatocapsular contralateral interhemispheric resection of anterior inferior basal ganglia cavernous malformation. In *World Neurosurgery* (Vol. 80, Issue 6).

OP-I/15

Three-Dimensional Modeling and Augmented Reality and Virtual Reality Simulation of Fiber Dissection of the Cerebellum and Brainstem

Muhammet Enes Gurses[1], Abuzer Gungor[2], Serdar Rahmanov[3], Elif Gökalp[4], Sahin Hanalioglu[1], Mustafa Berker[1], Aaron A. Cohen-Gadol[5], Uğur Türe[3]

[1]Department of Neurosurgery, Hacettepe University, Ankara, Turkey
[2]Department of Neurosurgery, University of Health Sciences, Bakirkoy Prof. Dr. Mazhar Osman Training and Research Hospital for Neurology, Neurosurgery and Psychiatry, Istanbul, Turkey
[3]Department of Neurosurgery, Microsurgical Neuroanatomy Laboratory, Yeditepe University School of Medicine, Istanbul
[4]Department of Neurosurgery, Ankara University, Ankara, Turkey
[5]Department of Neurological Surgery, Indiana University School of Medicine, Indianapolis, Indiana, USA

Objectives: To create 3-dimensional (3D) models and augmented reality (AR) and virtual reality (VR) simulations of cadaveric dissections of the human cerebellum and brainstem and to examine the 3D relationships of these structures.

Background: Surgeons must understand the complex anatomy of the cerebellum and brainstem and their 3D relationships with each other for surgery to be successful. To the best of our knowledge, there have been no fiber dissection studies combined with 3D models, AR, and VR of the structure of the cerebellum and brainstem. In this study, we created freely accessible AR and VR simulations and 3D models of the cerebellum and brainstem.

Method: Ten cadaveric cerebellum and brainstem specimens were prepared in accordance with the Klingler's method. The cerebellum and brainstem were dissected under the operating microscope, and 2-dimensional and 3D images were captured at every stage. With a photogrammetry tool (Qlone, EyeCue Vision Technologies, Ltd.), AR and VR simulations and 3D models were created by combining several 2-dimensional pictures.

Results: For the first time reported in the literature, high-resolution, easily accessible, free 3D models and AR and VR simulations of cerebellum and brainstem dissections were created.

Figure 1

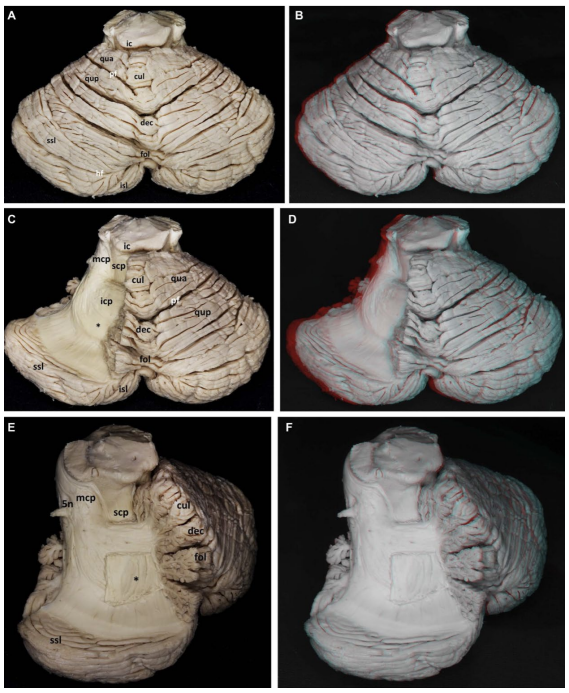

Figure 2

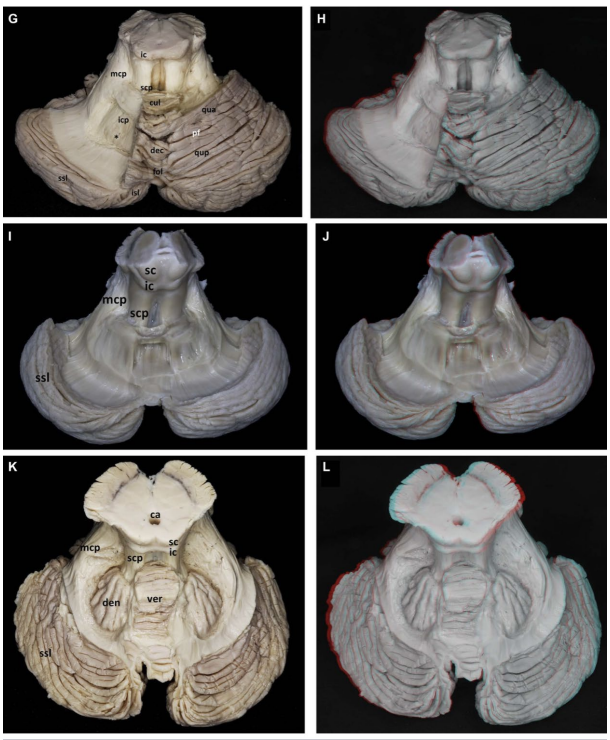

Figure 3



Conclusions: Fiber dissection of the cerebellum-brainstem complex and 3D models with AR and VR simulations are a useful addition to the goal of training neurosurgeons worldwide.

Keywords: 3D modeling, Augmented reality, Neuroanatomy, Virtual reality

References

1. Voogd J, Glickstein M. The anatomy of the cerebellum. Trends Neurosci. 1998;21(9):370-375.
2. Smith LH, DeMyer WE. Anatomy of the brainstem. Semin Pediatr Neurol. 2003;10(4):235-240.
3. Cucu AI, Turliuc S, Costea CF, et al. The brainstem and its neurosurgical history. Neurosurg Rev. 2021;44(6):3001-3022.
4. Fernández-Miranda JC, Rhoton AL Jr, Alvarez-Linera J, Kakizawa Y, Choi C, de Oliveira EP. Three-dimensional microsurgical and tractographic anatomy of the white matter of the human brain. Neurosurgery. 2008;62(6 suppl 3):989-1026; discussion 1026-1028.
5. Yagmurlu K, Rhoton AL Jr, Tanriover N, Bennett JA. Three-dimensional microsurgical anatomy and the safe entry zones of the brainstem. Neurosurgery. 2014;10(suppl 4):602-619; discussion 619-620.
6. Párraga RG, Possatti LL, Alves RV, Ribas GC, Türe U, de Oliveira E. Microsurgical anatomy and internal architecture of the brainstem in 3D images: surgical considerations. J Neurosurg. 2016;124(5):1377-1395.

7. Cappellen van Walsum AV, Henssen D. E-learning three-dimensional anatomy of the brainstem: impact of different microscopy techniques and spatial ability. Anat Sci Educ. 2021;15(2):317-329.
8. Agrawal A, Kapfhammer JP, Kress A, et al. Josef Klingler's models of white matter tracts: influences on neuroanatomy, neurosurgery, and neuroimaging. Neurosurgery. 2011;69(2):238-252; discussion 252-254.
9. Silva SM, Andrade JP. Neuroanatomy: the added value of the Klingler method. Ann Anat. 2016;208:187-193.
10. Wysiadecki G, Clarke E, Polguj M, Haladaj R, Żytkowski A, Topol M. Klingler's method of brain dissection: review of the technique including its usefulness in practical neuroanatomy teaching, neurosurgery and neuroimaging. Folia Morphol (Warsz). 2019;78(3):455-466.
11. Pruthi N, Kadri PAS, Türe U. Fiber microdissection technique for demonstrating the deep cerebellar nuclei and cerebellar peduncles. Oper Neurosurg. 2021;20(2):E118-E125.
12. Dziedzic TA, Balasa A, Jeżewski MP, Michalowski Ł, Marchel A. White matter dissection with the Klingler technique: a literature review. Brain Struct Funct. 2021;226(1):13-47.
13. Zulqar-Nain J, Burgess G, Zander HA. Photogrammetry. J Periodontol. 1967;38(suppl 6):677-683.
14. McMenamin PG, Quayle MR, McHenry CR, Adams JW. The production of anatomical teaching resources using three-dimensional (3D) printing technology. Anat Sci Educ. 2014;7(6):479-486.
15. Kockro RA, Amaxopoulou C, Killeen T, et al. Stereoscopic neuroanatomy lectures using a three-dimensional virtual reality environment. Ann Anat. 2015;201:91-98.
16. Riva G, Wiederhold BK. The new dawn of virtual reality in health care: medical simulation and experiential interface. Stud Health Technol Inform. 2015;219:3-6.
17. Clark AD, Guilfoyle MR, Candy NG, et al. Stereoscopic three-dimensional neuroanatomy lectures enhance neurosurgical training: prospective comparison with traditional teaching. World Neurosurg. 2017;108:917.e5-923.e5.
18. Petriceks AH, Peterson AS, Angeles M, Brown WP, Srivastava S. Photogrammetry of human specimens: an innovation in anatomy education. J Med Educ Curric Dev. 2018;5:2382120518799356.
19. Angeles Fernández-Gil M, Palacios-Bote R, Leo-Barahona M, Mora-Encinas JP. Anatomy of the brainstem: a gaze into the stem of life. Semin Ultrasound CT MR. 2010;31(3):196-219.
20. Cavalcanti DD, Preul MC, Kalani MY, Spetzler RF. Microsurgical anatomy of safe entry zones to the brainstem. J Neurosurg. 2016;124(5):1359-1376.
21. Matsushima K, Yagmurlu K, Kohno M, Rhoton AL Jr. Anatomy and approaches along the cerebellar-brainstem fissures. J Neurosurg. 2016;124(1):248-263.
22. Yang Y, van Niftrik B, Ma X, et al. Analysis of safe entry zones into the brainstem. Neurosurg Rev. 2019;42(3):721-729.
23. Shah A, Jhawar SS, Nunez M, Goel A, Goel A. Brainstem anatomy: a study on the basis of the pattern of fiber organization. World Neurosurg. 2020;134:e826-e846.
24. Gurses ME, Gungor A, Hanalioglu S, et al. Qlone(R): a simple method to create 360-degree photogrammetry-based 3-dimensional model of cadaveric specimens. Oper Neurosurg. 2021;21(6):E488-E493.
25. Güngör A, Baydin S, Middlebrooks EH, Tanriover N, Isler C, Rhoton AL Jr. The white matter tracts of the cerebrum in ventricular surgery and hydrocephalus. J Neurosurg. 2017;126(3):945-971.

26. Güngör A, Baydin ŞS, Holanda VM, et al. Microsurgical anatomy of the subthalamic nucleus: correlating fiber dissection results with 3-T magnetic resonance imaging using neuronavigation. J Neurosurg. 2018;130(3):716-732.
27. Türe U, Yaşargil MG, Friedman AH, Al-Mefty O. Fiber dissection technique: lateral aspect of the brain. Neurosurgery. 2000;47(2):417-426; discussion 426-427.
28. Türe U, Yaşargil MG, Pait TG. Is there a superior occipitofrontal fasciculus? A microsurgical anatomic study. Neurosurgery. 1997;40(6):1226-1232.
29. Baydin S, Gungor A, Tanriover N, Baran O, Middlebrooks EH, Rhoton AL Jr. Fiber tracts of the medial and inferior surfaces of the cerebrum. World Neurosurg. 2017;98:34-49.
30. Kelley DJ, Farhoud M, Meyerand ME, et al. Creating physical 3D stereolithograph models of brain and skull. PLoS One. 2007;2(10):e1119.
31. Estevez ME, Lindgren KA, Bergethon PR. A novel three-dimensional tool for teaching human neuroanatomy. Anat Sci Educ. 2010;3(6):309-317.
32. The Neurosurgical Atlas. Accessed February 21, 2022. Available at: https://www.neurosurgicalatlas.com/.

OP-I/16

Three-dimensional modeling and extended reality simulations of the cross-sectional anatomy of the cerebrum, cerebellum, and brainstem

Muhammet Enes Gurses[1], Sahin Hanalioglu[1], Giancarlo Mignucci-Jiménez[1], Elif Gökalp[2], Nicolas I. Gonzalez-Romo[1], Abuzer Gungor[3], Aaron A. Cohen-Gadol[4], Uğur Türe[3], Michael T. Lawton[1], Mark C. Preul[1]

[1]The Loyal and Edith Davis Neurosurgical Research Laboratory Department of Neurosurgery Barrow Neurological Institute St. Joseph's Hospital and Medical Center Phoenix, Arizona
[2]Department of Neurosurgery Ankara University Faculty of Medicine Ankara, Turkey
[3]Department of Neurosurgery Yeditepe University Faculty of Medicine Istanbul, Turkey
[4]Department of Neurological Surgery Indiana University School of Medicine Indianapolis, Indiana

Objectives: To create 3D models and AR/VR simulations from 2D images of cross-sectionally dissected cadaveric specimens of the cerebrum, cerebellum, and brainstem.

Background: Understanding the anatomy of the human cerebrum, cerebellum, and brainstem and their 3-dimensional (3D) relationships is critical for neurosurgery. Although 3D photogrammetric models of cadaver brains and 2-dimensional (2D) images of postmortem brain slices are available, neurosurgeons lack free access to 3D models of cross-sectional anatomy of the cerebrum, cerebellum, and brainstem that can be simulated in both augmented reality (AR) and virtual reality (VR).

Method: The Klingler method was used to prepare 3 cadaveric specimens for dissection in the axial, sagittal, and coronal planes. A series of 3D models and AR/VR simulations were then created using 360° photogrammetry.

Results: High-resolution 3D models of cross-sectional anatomy of the cerebrum, cerebellum, and brainstem were obtained and used in creating AR/VR simulations. Eleven axial, 9 sagittal, and 7 coronal 3D models were created. The sections were planned to show important deep anatomical structures. These models can be freely rotated, projected onto any surface, viewed from all angles, and examined at various magnifications.

figure 1



figure 2

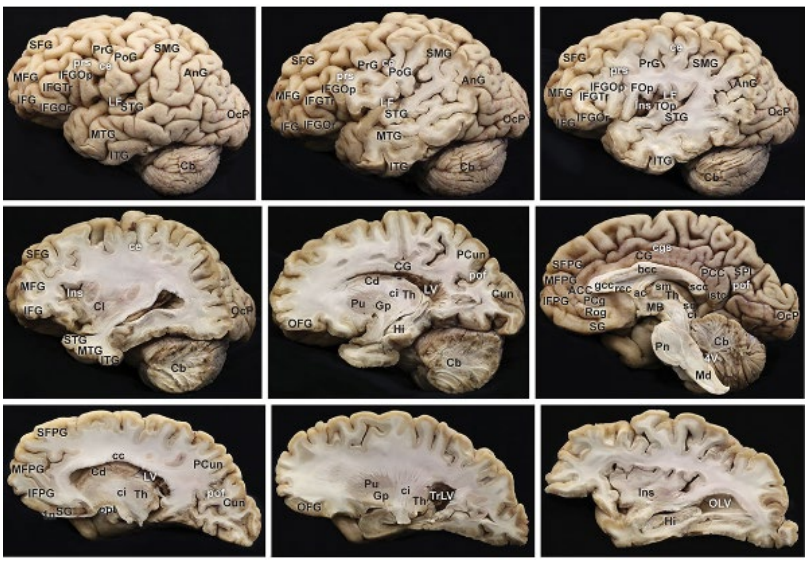

figure 3

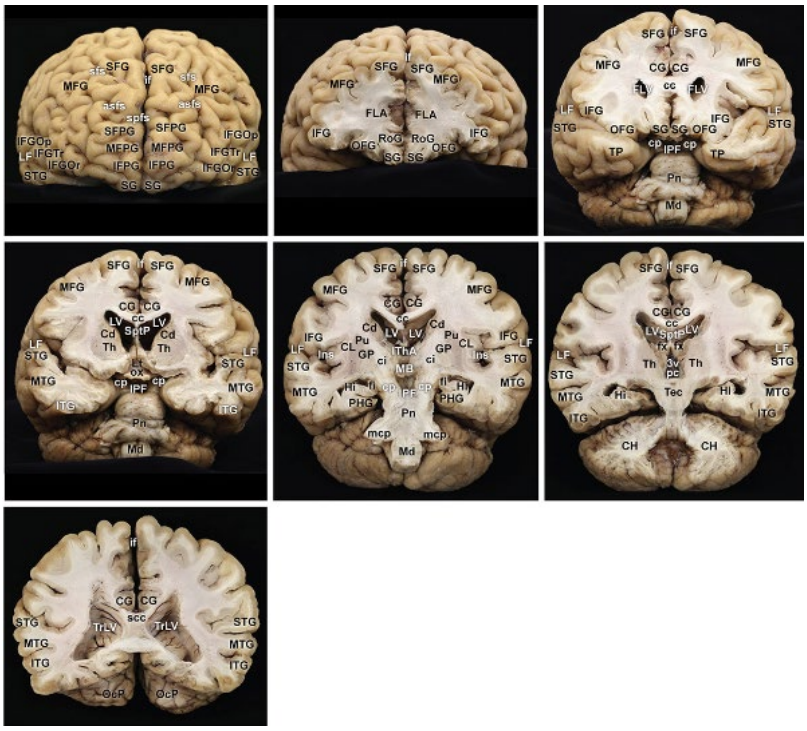

Conclusions: To our knowledge, this detailed study is the first to combine up-to-date technologies (photogrammetry, AR, and VR) for high-resolution 3D visualization of the cross-sectional anatomy of the entire human cerebrum, cerebellum, and brainstem. The resulting 3D images are freely available for use by medical professionals and students for better comprehension of the 3D relationship of the deep and superficial brain anatomy.

Keywords: 3D modeling; augmented reality; cross-sectional anatomy; neuroanatomy; virtual reality

References

1. Qualter J, Sculli F, Oliker A, et al. The biodigital human: a web-based 3D platform for medical visualization and education. Stud Health Technol Inform. 2012;173:359-361.

2. Hanalioglu S, Romo NG, Mignucci-Jimenez G, et al. Development and Validation of a Novel Methodological Pipeline to Integrate Neuroimaging and Photogrammetry for Immersive 3D Cadaveric Neurosurgical Simulation. Front Surg. 2022;9:878378.

3. Gurses ME, Gungor A, Gokalp E, et al. Three-Dimensional Modeling and Augmented and Virtual Reality Simulations of the White Matter Anatomy of the Cerebrum. Oper Neurosurg (Hagerstown). 2022;23(5):355-366.

4. Gurses ME, Gungor A, Rahmanov S, et al. Three-Dimensional Modeling and Augmented Reality and Virtual Reality Simulation of Fiber Dissection of the Cerebellum and Brainstem. Oper Neurosurg (Hagerstown). 2022;23(5):345-354.

5. Agrawal A, Kapfhammer JP, Kress A, et al. Josef Klingler's models of white matter tracts: influences on neuroanatomy, neurosurgery, and neuroimaging. Neurosurgery. 2011;69(2):238-252; discussion 252-234.

6. Klingler J. Erleichterung der makroskopischen Präparation des Gehirns durch den Gefrierprozess [Facilitation of the macroscopic dissection of the brain by the freezing process]. Schweize Archiv fur Neurologie und Psychiatr. 1935;36:247-256.

7. Klingler J, Ludwig E. Atlas Cerebri Humani [Atlas of the Human Brain]. Berlin: Karger; 1956.

8. Gurses ME, Gungor A, Hanalioglu S, et al. Qlone(R): A Simple Method to Create 360-Degree Photogrammetry-Based 3-Dimensional Model of Cadaveric Specimens. Oper Neurosurg (Hagerstown). 2021;21(6):E488-E493.

9. The Neurosurgical Atlas. https://www.neurosurgicalatlas.com. Accessed 1.May.2022.

10. Louis RG, Steinberg GK, Duma C, et al. Early Experience With Virtual and Synchronized Augmented Reality Platform for Preoperative Planning and Intraoperative Navigation: A Case Series. Oper Neurosurg (Hagerstown). 2021;21(4):189-196.

11. Kockro RA, Stadie A, Schwandt E, et al. A collaborative virtual reality environment for neurosurgical planning and training. Neurosurgery. 2007;61(5 Suppl 2):379-391; discussion 391.

12. Parraga RG, Possatti LL, Alves RV, et al. Microsurgical anatomy and internal architecture of the brainstem in 3D images: surgical considerations. J Neurosurg. 2016;124(5):1377-1395.

13. Shao X, Yuan Q, Qian D, et al. Virtual reality technology for teaching neurosurgery of skull base tumor. BMC Med Educ. 2020;20(1):3.

14. Serrato-Avila JL, Paz Archila JA, Silva da Costa MD, et al. Three-Dimensional Quantitative Analysis of the Brainstem Safe Entry Zones Based on Internal Structures. World Neurosurg. 2022;158:e64-e74.

15. Fernandez-Miranda JC, Rhoton AL, Jr., Alvarez-Linera J, et al. Three-dimensional microsurgical and tractographic anatomy of the white matter of the human brain. Neurosurgery. 2008;62(6 Suppl 3):989-1026; discussion 1026-1028.

16. Roh TH, Oh JW, Jang CK, et al. Virtual dissection of the real brain: integration of photographic 3D models into virtual reality and its effect on neurosurgical resident education. Neurosurg Focus. 2021;51(2):E16.

17. Dho YS, Park SJ, Choi H, et al. Development of an inside-out augmented reality technique for neurosurgical navigation. Neurosurg Focus. 2021;51(2):E21.

18. Perin A, Gambatesa E, Galbiati TF, et al. The "STARS-CASCADE" Study: Virtual Reality Simulation as a New Training Approach in Vascular Neurosurgery. World Neurosurg. 2021;154:e130-e146.

19. Spiriev T, Mitev A, Stoykov V, et al. Three-Dimensional Immersive Photorealistic Layered Dissection of Superficial and Deep Back Muscles: Anatomical Study. Cureus. 2022;14(7):e26727.

20. Vigo V, Pastor-Escartin F, Doniz-Gonzalez A, et al. The Smith-Robinson Approach to the Subaxial Cervical Spine: A Stepwise Microsurgical Technique Using Volumetric Models From Anatomic Dissections. Oper Neurosurg (Hagerstown). 2020;20(1):83-90.

21. Kournoutas I, Vigo V, Chae R, et al. Acquisition of Volumetric Models of Skull Base Anatomy Using Endoscopic Endonasal Approaches: 3D Scanning of Deep Corridors Via Photogrammetry. World Neurosurg. 2019;129:372-377.

22. Rodriguez Rubio R, Xie W, Vigo V, et al. Immersive Surgical Anatomy of the Retrosigmoid Approach. Cureus. 2021;13(6):e16068.

23. Johnson EO, Charchanti AV, Troupis TG. Modernization of an anatomy class: From conceptualization to implementation. A case for integrated multimodal-multidisciplinary teaching. Anat Sci Educ. 2012;5(6):354-366.

24. Ture U, Yasargil MG, Friedman AH, et al. Fiber dissection technique: lateral aspect of the brain. Neurosurgery. 2000;47(2):417-426; discussion 426-417.

25. Ture U, Yasargil DC, Al-Mefty O, et al. Topographic anatomy of the insular region. J Neurosurg. 1999;90(4):720-733.

26. Yagmurlu K, Vlasak AL, Rhoton AL, Jr. Three-dimensional topographic fiber tract anatomy of the cerebrum. Neurosurgery. 2015;11 Suppl 2:274-305; discussion 305.

27. Ribas EC, Yagmurlu K, de Oliveira E, et al. Microsurgical anatomy of the central core of the brain. J Neurosurg. 2018;129(3):752-769.

28. Kikinis R, Gleason PL, Moriarty TM, et al. Computer-assisted interactive three-dimensional planning for neurosurgical procedures. Neurosurgery. 1996;38(4):640-649; discussion 649-651.

29. Silen C, Wirell S, Kvist J, et al. Advanced 3D visualization in student-centred medical education. Med Teach. 2008;30(5):e115-124.

30. Kakizawa Y, Hongo K, Rhoton AL, Jr. Construction of a three-dimensional interactive model of the skull base and cranial nerves. Neurosurgery. 2007;60(5):901-910; discussion 901-910.

31. Yagmurlu K, Rhoton AL, Jr., Tanriover N, et al. Three-dimensional microsurgical anatomy and the safe entry zones of the brainstem. Neurosurgery. 2014;10 Suppl 4:602-619; discussion 619-620.

32. Martins C, Ribas EC, Rhoton AL, Jr., et al. Three-dimensional digital projection in neurosurgical education: technical note. J Neurosurg. 2015;123(4):1077-1080.

33. Gungor A, Baydin S, Middlebrooks EH, et al. The white matter tracts of the cerebrum in ventricular surgery and hydrocephalus. J Neurosurg. 2017;126(3):945-971.

34. Cavalcanti DD, Feindel W, Goodrich JT, et al. Anatomy, technology, art, and culture: toward a realistic perspective of the brain. Neurosurg Focus. 2009;27(3):E2.

35. Farhadi DS, Jubran JH, Zhao X, et al. The Neuroanatomic Studies of Albert L. Rhoton Jr. in Historical Context: An Analysis of Origin, Evolution, and Application. World Neurosurg. 2021;151:258-276.

36. Sahin B, Hanalioglu S. The Continuing Impact of Coronavirus Disease 2019 on Neurosurgical Training at the 1-Year Mark: Results of a Nationwide Survey of Neurosurgery Residents in Turkey. World Neurosurg. 2021;151:e857-e870.

37. Lazaro T, Srinivasan VM, Rahman M, et al. Virtual education in neurosurgery during the COVID-19 pandemic. Neurosurg Focus. 2020;49(6):E17.

38. Ogata H, Matsuka Y, Bishouty MME, et al. LORAMS: linking physical objects and videos for capturing and sharing learning experiences towards ubiquitous learning. International Journal of Mobile Learning and Organisation. 2009;3(4):337–350.

39. Kinshuk, Graf S. Ubiquitous Learning. In: N. M. Seel (ed). Encyclopedia of the Sciences of Learning. Boston: Springer; 2012;3361-3363.

40. Gonzalez-Romo NI, Hanalioglu S, Mignucci-Jiménez G, et al. Anatomical depth estimation and three-dimensional reconstruction of microsurgical anatomy using monoscopic high-definition photogrammetry and machine learning. Oper Neurosurg. 2022.

OP- IV/17

Risk Stratification for Post-Traumatic Epilepsy (PTE) with Possible Integration of AI

Noor ul Huda Maria[1], Noor ul Huda Maria[1]

[1]PINS
[2]PINS

Objectives: To propose a schematic approach to stratify risk of development of Post-Traumatic Epilepsy in patients with TBI

Background: We wish to propose an easy standardized schematic approach to stratify patients with Traumatic Brain Injury into risk groups to provide proper followup and management to those at increased risk while avoiding inadvertent medication exposure,followup and anxiety in those at lower risk. This approach should ideally allow junior level doctors and those working at primary care level to stratify patients thus providing best possible care.

Method: Literature review and hospital records

Results: We identified factors and gave them scores according to the risk they posed. The type of TBI with Brain Contusion =3 especially temporal contusion =4, DSF =3, Penetrating Injury =3, SDH =2, DAI =2 and the least EDH=0.5. Surgery when indicated performed late= 2, Early seizure (>24 hrs<7days)=2,late sezures ≥7days 3, age <5 and >65 being important and each scored 2 individually. The total score if 0-4 portends low risk, 5-9 moderate risk and we suggest FUP,assessment of biomarkers, AED beyond the AAN guideline should be tailored according to the presence of high risk features only. When the score is >10,patient is at high risk and EEG and SWI multidisciplinary approach maybe helpful. Follow the lesion and continue AED beyond 1 month with further guidance from EEG and biomarkers

Proposed Scheme

Criteria	Mild	Moderate	Severe
Structural imaging	Normal	Normal or abnormal	Normal or abnorma
Loss of consciousness	0-30 min	>30 min and <24 h	>24 h
Alteration of consciousness or mental state*	Momentary to 24 h	>24 h	>24 h
Post-traumatic amnesia	0-1 d	>1 and <7 d	>7 d
Glasgow Coma Scale score	13-15	9-12	<9

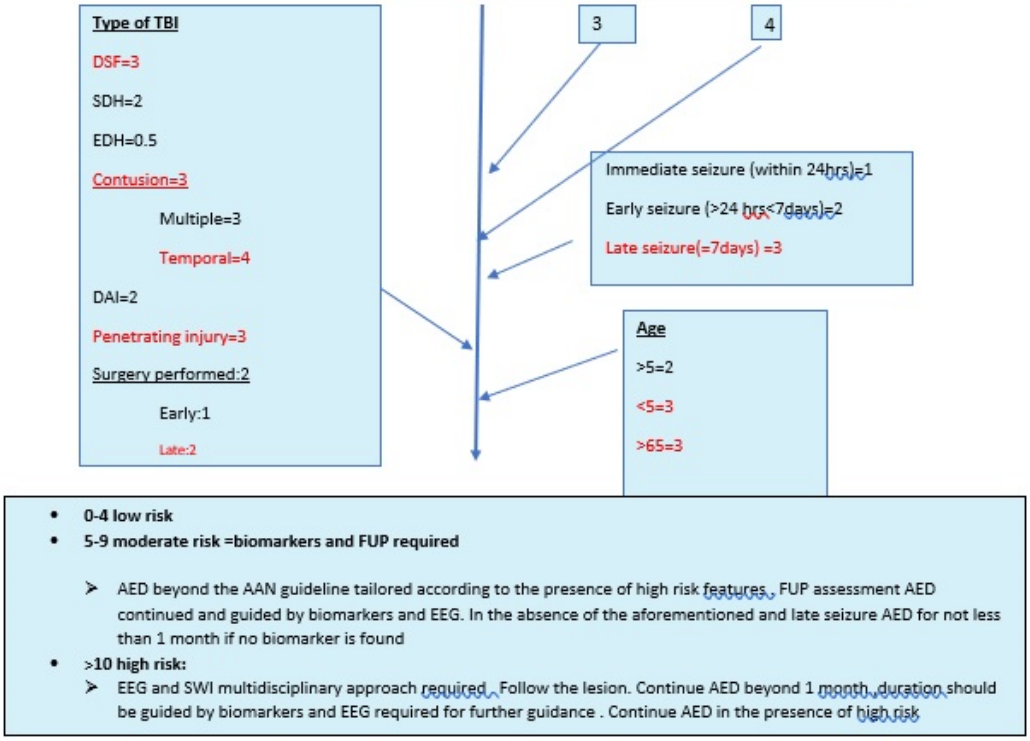

Conclusions: We suggest a schematic approach to stratify patients with TBI into risk groups to provide proper followup and management to those at increased risk while avoiding inadvertent medication,followup and anxiety to ones at lower risk

Keywords: Post-traumatic epilepsy, Traumatic brain injury

References

1. Annegers JF, Coan SP. The risks of epilepsy after traumatic brain injury. Seizure. 2000;9:453–457. [PubMed] [Google Scholar
2. Christensen J, Pedersen MG, Pedersen CB, Sidenius P, Olsen J, Vestergaard M. Long-term risk of epilepsy after traumatic brain injury in children and young adults: a population-based cohort study. Lancet. 2009;373:1105–

OP-III/19

An Innovative Solution for LMICs: A Cost-Effective High-Quality Surgical Training Microscope

Abdullah Keles[1], Cagdas Ataoglu[1], Yannick Canton Kessely[2], Alberto Acitores Cancela[3], Turab Gasimov[4], Burak Ozaydin[5], Mustafa Kemal Baskaya[1]

[1]University of Wisconsin-Madison
[2]Department of Surgery, Hôpital de la Renaissance
[3]Department of Neurological Surgery, Hospital Universitario Ramón y Cajal
[4]Department of Neurosurgery, Respublika Diaqnostika Mərkəzi
[5]Department of Neurological Surgery, University of Oklahoma College of Medicine

Objectives: In this study, we aimed to construct a low-cost high-quality surgical training microscope, evaluate its effectiveness to meet specific training needs, and promote accessibility and affordability by providing do-it-yourself guidelines, enabling broader usage of similar microscopes in LMICs.

Background: Microneurosurgery requires intensive training in surgical neuroanatomy and microsurgical techniques. Therefore, long hours of laboratory training are of utmost importance to improve manual dexterity, hand-eye coordination under microscopical magnification, and 3-dimensional surgical neuroanatomy knowledge. Such laboratories are often thought to require high-cost microscopes and instruments which are not available in most of the low-resource countries. Here we have constructed a low-cost high-quality surgical microscope to adopt in microneurosurgery training laboratories in LMICs.

Method: In order to utilize any kind of microscope for microneurosurgical laboratory training, it should meet certain criteria such as stereoscopic vision, magnification, working distance, and illumination.An old high-quality ophthalmic microscope part($76) and an external LED ring light source($25) were purchased online. Simultaneously, a high-quality used monitor arm($50) was purchased at a local furniture store. Additionally, binocular tubes with eyepieces were purchased online for $20.The ophthalmic microscope's component, consisting of a true stereoscopic magnification lens system and eyepiece, was detached and affixed to the monitor arm using its intermediate attachment component.

Ophthalmic Microscope



(a)An old high-quality ophthalmic microscope part($76) was purchased online (b) The ophthalmic microscope's stereoscopic magnification lens component and eyepiece, were detached (c) the stereoscopic magnification lens component only.

Results: The complete setup was attached to a station in Lincoln F. Ramirez Neurosurgery Operative Skill Laboratory and tested with cadaveric specimens. Our innovative solution offers true stereoscopic vision, appropriate magnification options(6-10-16-25-40-fold), adjustable working distance(200mm), and ample illumination to ensure optimal performance in training settings.

The complete setup



(a)Stereoscopic magnification lens component was attached to the monitor arm (b) complete setup.

Conclusions: We have shown that a low-cost high-quality microsurgery training microscope can be constructed and used effectively in laboratory settings. According to our experience, after enough training, it can be used easily in OR setting for other microsurgical disciplines, such as ENT, Ophthalmology, Plastic and Reconstructive Surgery, and Vascular Surgery.

Keywords: global neurosurgery, low and middle-income countries, microneurosurgical training, operative microscope

References

1. Yaşargil MG. Microsurgery Applied to Neurosurgery. vol Stuttgart, Germany. Georg Thieme Verlag; 1969.
2. Peltola TJ, Mantyjarvi M, Terasvirta M, Kemppainen H. Build your own multipurpose, economically priced portable stereo microscope. Article. Tropical Doctor. Jan 2000;30(1):28-29. doi:10.1177/004947550003000114

OP- IV/20

Cadaveric Study for Selecting Optimal Surgical Approach to Thalamus

Derya Karataş[1], Saygı Uygur[1], Ömer Ruşen Koyuncu[2], Irmak Tekeli Barut[1], Ahmet Dağtekin[1], Emel Avcı[1]

[1]Mersin University, School of Medicine
[2]Doktor Yaşar Eryılmaz State Hospital

Objectives: The objective of this study is to use cadaveric dissections to demonstrate the microsurgical anatomy specific to each thalamic approach, including regions accessed, surgical steps, potential anatomical variations, and related structures, in order to use this information to establish more objective selection criteria for thalamic tumor.

Background: The selection of an appropriate surgical approach for a particular tumor continues to be a subjective process (1).

Method: Fifteen adult brain specimens used to illustrate the micro-anatomy of the thalamus via fiber dissection and 15 formalin-fixed human cadaveric heads infused with colored silicone were dissected in a stepwise manner to demonstrate six different surgical approaches. Surgical steps, key anatomic landmarks, and critical neurovascular structures adjacent to the accessible parts of the thalamus were demonstrated.

Results: There are two main microneurosurgical routes, transcisternal and transcortical to access thalamic lesions. Transcisternal route consists of following 3 approaches; the anterior interhemispheric transcallosal approach is ideal for anterior thalamic tumors, the posterior interhemispheric transcallosal approach allows access to the posterosuperior thalamic region, the supracerebellar infratentorial approach is the best approach to the inferior and medial cisternal thalamus(Figure 1a-k). Transcortical routes consists of 3 approaches; the superior parietal lobule approach provides optimal access for tumors in the superior ventricular and cisternal thalamic regions, the trans-temporal gyrus approach may be used to reach the ventroposterior thalamic region, the transsylvian transinsular approach is an effective route for the ventral-posterior and lateral thalamic regions as well as for tumors that extend beneath the insular cortex(Figure 2a-j).

Figure 1

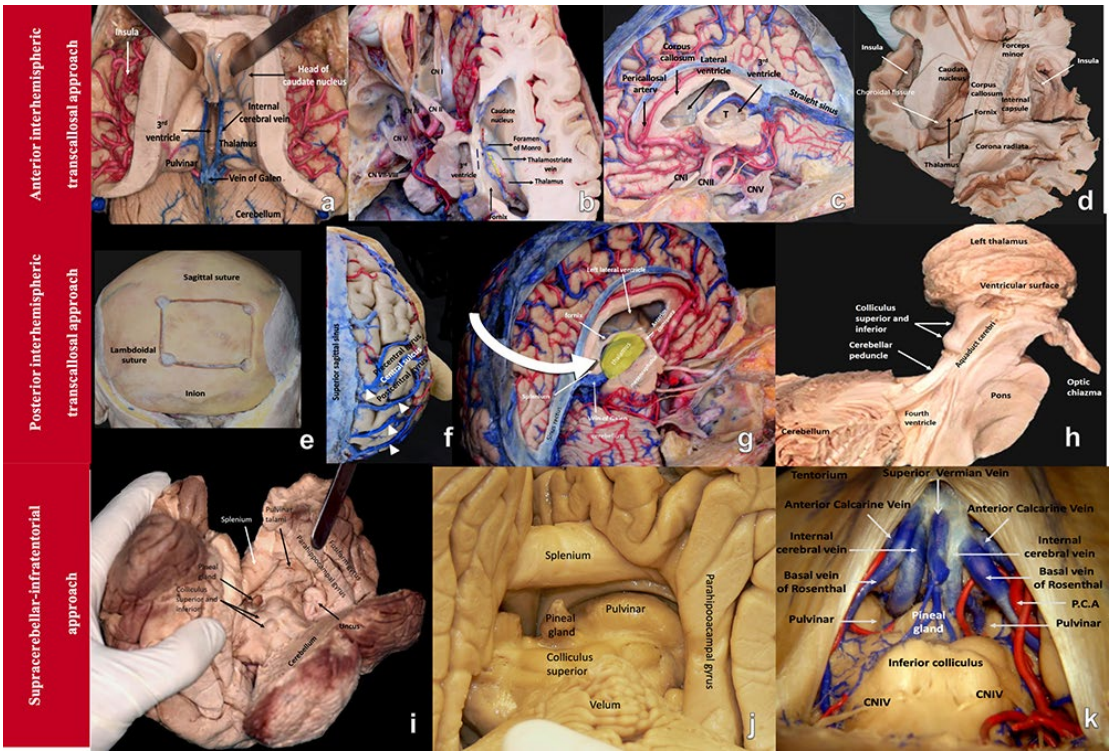

a-d: The anterior interhemispheric transcallosal approach is demonstrated. a: panoramic view of bilateral anterosuperior thalamus within the lateral ventricles. b: After left hemisphere was removed, transforaminal (red line), transchoroidal (yellow line), transforniceal incisions was showed to access the third ventricle. c: Sagittal panoramic view of anterior interhemispheric surgical route, right thalamus, lateral ventricle, third ventricle and massa intermedia. d: Fiber dissection of the overall exposure angle of the thalamus obtained through the AITA. Right internal capsula and corona radiata fibers was shown. e-h: The posterior interhemispheric transcallosal approach is demonstrated. e: Craniotomy borders. f: Following dural incision, the bridging vein-dense posterior interhemispheric region is demonstrated. g: Cadaveric demonstration of the overall exposure window of the thalamus obtained through the posterior interhemispheric transcallosal approach. h: Fiber dissection shows the third ventricular surface of thalamus. i-k: The supracerebellar-infratentorial approach is demonstrated. i: Panoramic view of pulvinar thalami and splenium after the elevation of parahippocampal gyrus. j: Anatomical structures via the surgical route. k: Pulvinar, galenic vein complex was demonstrated under the operative microscope.

Figure 2

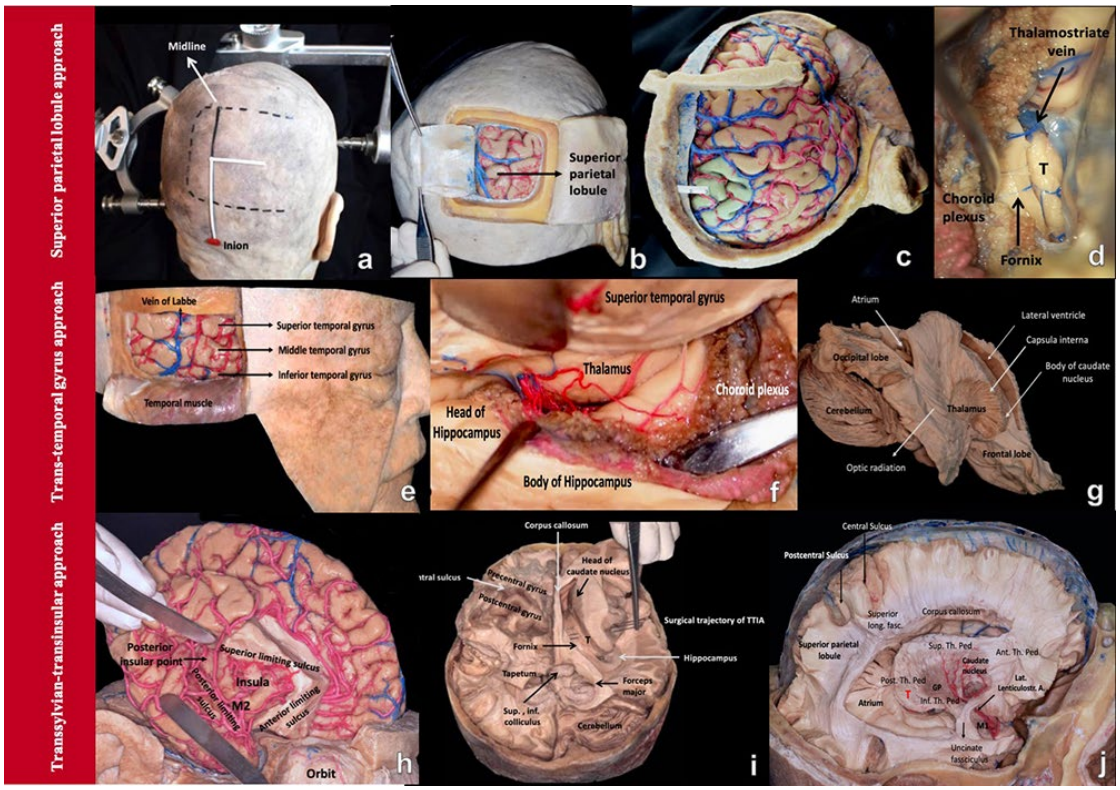

a-d: The superior parietal lobule approach is demonstrated. a: Skin incision (black dotted line) and it's relation to the inion. b-c: Craniotomy borders, dural opening, superior parietal lobule, interparietal sulcus. d: The demonstration of superior ventricular and cisternal thalamic regions under the operative microscope. e-g: The transtemporal gyrus approach was demonstrated e: Craniotomy borders and temporal gyrus. f: Through the temporal horn, the hippocampus, choroidal fissure, and thalamus can be seen. g. Fiber dissection shows the optic radiation, thalamus, temporal horn relations. h-j: The transinsular transslyvian approach is demonstrated. h: Cadaveric demonstration of the overall exposure window of the thalamus obtained through this approach. i: The needles show the surgical route on fiber dissection. j: Deep structures under the insular cortex was demonstrated.

Conclusions: Since the thalamic tumors are deep seated and surrounded with indispensable neural structures, the operative working trajectory becomes more important than the other neurosurgical fields (2, 3). The ultimate goal is to develop a decision-making scheme for selecting a personalized surgical approach that takes into account the numerous variables that can complicate thalamic glioma resection (Table 1).

Table 1

Principal factors	Modifying factors
Tumor location • Origin • Extension	Patient specific • Age • Anatomical (ventricle size, sulcal anatomy, venous anatomy etc.) • Clinical (performance status, existing neurodeficit etc.) • Previous surgery
Tumor size Tumor shape / geometry	Tumor specific • Grade • Nature (displacing / destructive) • Vascularity • Cyst
Relation to ventricular/cisternal surfaces	Surgeon's experience
Displacement of corticospinal and other white matter tracts	

Factors determining surgical approach selection for thalamic tumors

Keywords: thalamus, thalamic tumors, surgical approaches, fiber dissection

References

1. Özek M.M, Türe U. Surgical approach to thalamic tumors. Childs Nerv Syst, 2002. 18(8): p. 450-6.
2. Rangel-Castilla L and Spetzler RF, The 6 thalamic regions: Surgical approaches to thalamic cavernous malformations, operative results, and clinical outcomes. J Neurosurg, 2015. 123(3): p. 676-85.
3. Serra C, Türe U, Krayenbühl N, Şengül G, Yaşargil DC, Yaşargil MG. Topographic classification of the thalamus surfaces related to microneurosurgery: a white matter fiber microdissection study. World Neurosurg. 97:438-452, 2017

OP- IV/21

The Role of microsurgery in the Management of Severe Traumatic Brain Injury: A Triple-Center Study

Manuel de Jesus Encarnacion Ramirez[1], Renat Nurmukhametov[1], Gennady Chmutin[1]

[1]RUDN university

Objectives: The objective of this study is to demonstrate the implications of microsurgery in the treatment of TBI (Traumatic Brain Injury).

Background: Traumatic brain injury is a critical public health problem worldwide,constituting a major cause of mortality and morbidity for people of all ages, but especially in theyounger population. Decompressive craniectomy (DC) and cisternostomy are surgical procedurescommonly used in the management of severe TBI, but their effectiveness in improving outcomesremains controversial.

Method: We conducted a prospective longitudinal study on patients who underwent surgical treatment for severe TBI between 2021 and 2022. The extended Glasgow outcome scale (GOS-E) was used to assess clinical outcome at 2 weeks, 3 months, and 6 months after surgery. The inclusion criteria were patients between 18 and 70 years old without severe systemic disease, GCS < 8, shift greater than 5 mm on (CT) scan , The exclusion criteria were patients with GCS 3, moderate and mild TBI

catéter between the cistern

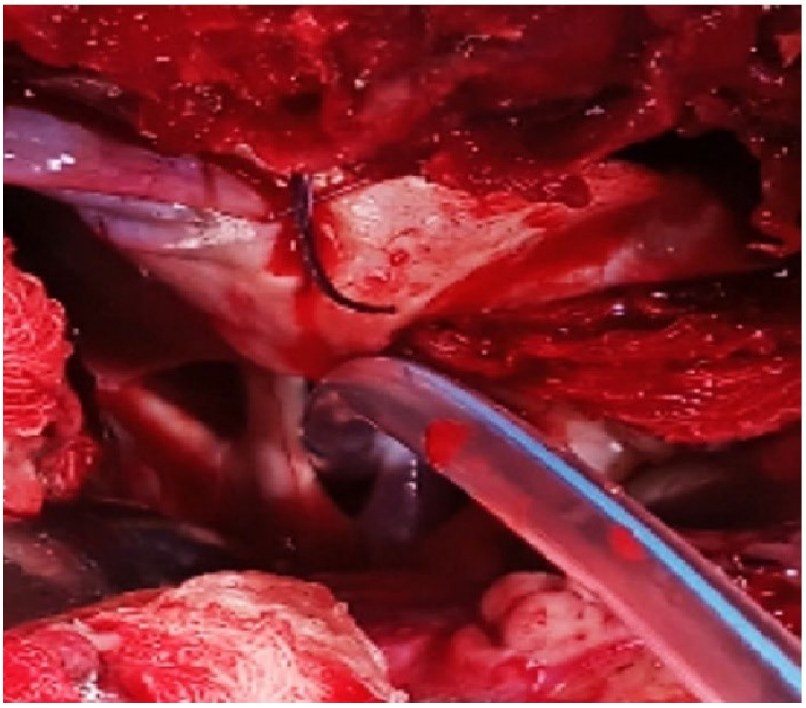

patient TBI with CSF drainage



after the cisternotomy the drainage its positioned on the pre pontine cistern

Results: The study included 30 patients (21 men and 9 women) who met the inclusion criteria. Among them, 24 patients (80%) underwent DC combined with cisternostomy, while 6 patients (20%) underwent cisternostomy alone. The initial Glasgow Coma Scale (GCS) score at admission rangedfrom 4 to 8 points, with an average score of 5.9. The overall mortality and overall morbidity was 13.3% and 20%, respectively. The mortality rate was 12.5% and 16.7% in the DC + cisternostomy group and in the cisternostomy alone group, respectively. No statistically significant difference was seen between the two groups in terms of mortality, morbidity and favorable outcome at 2 weeks, 3 months and 6 months.

Conclusions: Our preliminary multi-center study shows a good clinicaloutcome in patients who underwent DC + cisternostomy or cisternostomy alone in both early andlong-term follow-up. Larger multi-center randomized trials are needed to establish the effectivenessof cisternostomy in the management of TBI.

Keywords: TBI, Cisternostomy, Microneurosurgery, global neurosurgery

References

- Cherian, I.

OP-I/23

Clınıcal And Demographic Profile, Surgical Outcomes And Prognosis of The Rare Intramedullary Spinal Lesions – a Long Term Retrospective Observational Study From a Tertiary Referral Centre in a South India

Lokesh Dasarathan Vellore[1], Ganesh Divakar[1], Easwer HV[1], Krishnakumar Kesava Pisharady[1], Rajalakshmi P[2]

[1]Department of Neurosurgery, Sree chitra tirunal institute for medical sciences and Technology(SCTIMST),Trivandrum, Kerala, India (An institute of National importance)
[2]Department of Pathology, Sree chitra tirunal institute for medical sciences and Technology(SCTIMST),Trivandrum, Kerala, India (An institute of National importance)

Objectives: 1. To elucidate and study the incidence, clinical presentation, and demographic profile of rare intramedullary spinal cord lesions.2. To study the surgical outcomes; factors affecting the prognosis, survival, and recurrence of the rare intramedullary spinal cord lesions.

Background: Primary spinal cord tumours were classified as Extradural,IDEM, intradural and intramedullary types based on location in the neuraxis. Intramedullary tumours comprise 20 to 30% of all primary spinal cord tumours. Among these, 90% consist of tumours like astrocytoma, ependymomas, and hemangioblastomas. Rest of the lesions were rare and availability of literature regarding the clinical presentation, surgical outcomes and factors determining the prognosis were sparse.

Method: This is an observational study conducted in our institute. The data were collected from MRD(2000 to 2020). Clinical, radiological, surgical procedures,HPR report,prognosis,survival were recorded and analyzed.

Results: The total Intramedullary lesions operated were 504. Astrocytoma-274(55%),Ependymoma-135(27%),Hemangioblastoma-40(8%). Other rare lesions were 55(10%) includes Lipoma(4,0.6%),Dermoidcyst(6,1.2%),Epidermoidcyst(7,1.4%),Metastasis(3,0.6%),Cavernoma(8,1.6%),Neuroenteric cyst(3,0.6%),Schwannoma(4,0.8%),PNET/Ewings sarcoma(4,0.8%),Arteriovenous malformations(4,0.8%),abscess(5,1%),Ganglioglioma(2,0.4%), capillaryhemangioma(1,0.2%),Melanoma(1,0.2%),Germinoma(1,0.2%),Teratoma(1,0.2%),Diffuse leptomeningeal glioneuronal tumours(DLGNT) (1,0.2%). Most common location - Dorsal(55%)>Cervical(33%)>Lumbosacral(12%). Syrinx noted more in Metastasis,Schwannoma,and less in Neuroenteric cysts,cavernoma,abscess,and Ganglioglioma. STE achieved in 45%, and gross total excision achieved in 55%. 73% with residual tumour/recurrence were who underwent STE. 80% had poor planes with the cord. GTE was achievable in Epidermoidcyst and cavernoma. Epidermoidcyst had recurrence inspiteof GTE. The average preop McCormick score was 3 which has improved to 2 after surgery. Post-op neurological worsening was seen more in GTE(44%) than STE(39%). On 2 years follow-up, both STE and GTE had improvement in deficits in equal proportion(95%vs96%).

Surgical outcomes and immediate post op deficits

CATEGORY	SIZE(cm)	Extent of Resection		Immediate Post op DEFICITS status		
		PARTIAL	TOTAL	IMPROVE	SAME	WORSEN
Epidermoid cyst	7.42	0	7 (100%)	3	3	0
Dermoid cyst	2.93	3 (50%)	3 (50%)	3	1	2
Cavernoma	1.42	1 (13%)	7 (87%)	1	0	7 (88%)
Schwannoma	4.4	2 (50%)	2 (50%)	2	2	0
Neuroenteric cyst	2.65	2 (66%)	1 (34%)	1	1	1
Germinoma	-	1 (100%)	0	0	1	0
Melanoma	2.2	1 (100%)	0	0	0	1
Metastasis	3.67	2 (66%)	1 (34%)	0	2	1
Ewings / PNET	4.43	2 (50%)	2 (50%)	0	4 (100%)	0
Teratoma	-	1 (100%)	0	1	0	0
DLGT	3.4	1 (100%)	0	0	1	0
Capillary hemangioma	4.8	0	1 (100%)	1	0	0
AVM	4.3	2 (50%)	2 (50%)	1	1	2
Abscesses	2	3 (60%)	2 (40%)	2	2	1
Ganglioglioma	2.1	2 (100%)	0	0	1	1
TOTAL NO	Avg – 3.5	23	28	15	19	15

tumour characteristics and status of resection

STATUS OF RESECTION vs TUMOUR CHARACTERISTICS

Parameter		Subtotal - Decompression	Gross total - decompression
Total		23(45%)	28(55%)
Avg. size		3.535 cm	4.33 cm
Avg. spinal segment involved by tumour		4	2
Preop- MRI – Syrinx		7 (30%)	11 (39%)
Preop – MRI - Edema		12 (52%)	10 (36%)
Planes with normal parenchyma	Poor	18 (78%)	18 (64%)
	Good	5 (22%)	10 (36%)
Location of the lesion	CERVICAL	10 (45%)	8 (27%)
	DORSAL	9 (41%)	15 (52%)
	LUMBOSACRAL	3 (14%)	4 (13%)

Recurrence status after surgery in each group

CATEGORY	No	SIZE(cm)	Extent of Resection		Post op Residue / Recurrent
			PARTIAL	TOTAL	
Epidermoid cyst	7	7.42	0	7 (100%)	3
Dermoid cyst	6	2.93	3 (50%)	3 (50%)	0
Cavernoma	8	1.42	1 (13%)	7 (87%)	1
Schwannoma	4	4.4	2 (50%)	2 (50%)	2
Neuroenteric cyst	3	2.65	2 (66%)	1 (34%)	0
Germinoma	1	-	1 (100%)	0	1
Melanoma	1	2.2	1 (100%)	0	1
Metastasis	3	3.67	2 (66%)	1 (34%)	0
Ewings / PNET	4	4.43	2 (50%)	2 (50%)	1
Teratoma	1	-	1 (100%)	0	0
DLGT	1	3.4	1 (100%)	0	1
Capillary hemangioma	1	4.8	0	1 (100%)	0
AVM	4	4.3	2 (50%)	2 (50%)	1
Abscesses	5	2	3 (60%)	2 (40%)	2
Ganglioglioma	2	2.1	2 (100%)	0	2
TOTAL NO	51		23(45%)	28(55%)	15 (29%)

Conclusions: In our study, we found that either subtotal(STE) or total decompression(GTE) will result in similar long-term clinical outcomes. STE and poor planes with cord are the significant contributing factors for the Recurrence/Residual lesion. As the incidence of these lesions was very rare, our study gives an insight into the need for a multi-institutional tumour registry for future research.

Keywords: Rare intramedullary spinal lesions, rare spinal cord tumours, spine tumours

References

1. Manoharan N, Ajuyah P, Senapati A, Wong M, Mullins A, Rodriguez M, et al. Diffuse leptomeningeal glioneuronal tumour (DLGNT) in children: the emerging role of genomic analysis. Acta Neuropathol Commun. 2021 Sep 7;9(1):147.
2. Duong LM, McCarthy BJ, McLendon RE, Dolecek TA, Kruchko C, Douglas LL, et al. Descriptive Epidemiology of Malignant and Nonmalignant Primary Spinal Cord, Spinal Meninges, and Cauda Equina Tumors, United States, 2004–2007. Cancer. 2012 Sep 1;118(17):4220–7.
3. Hamburger C, Büttner A, Weis S. Ganglioglioma of the spinal cord: report of two rare cases and review of the literature. Neurosurgery. 1997 Dec;41(6):1410–5; discussion 1415-1416.
4. Shih RY, Koeller KK. Intramedullary Masses of the Spinal Cord: Radiologic-Pathologic Correlation. RadioGraphics. 2020 Jul;40(4):1125–45.
5. Watanabe M, Nomura T, Toh E, Sato M, Mochida J. Intramedullary spinal cord metastasis: a clinical and imaging study of seven patients. J Spinal Disord Tech. 2006 Feb;19(1):43–7.
6. Bhople L, Kharosekar H, Jain N, Velho V. Solitary Dorsal Intramedullary Schwanomma – A Rare Lesion. Arq Bras Neurocir Braz Neurosurg. 2022 Mar;41(01):e90–3.
7. Kabir SMR, Thompson D, Rezajooi K, Casey ATH. Non-dysraphic intradural spinal cord lipoma: case series, literature review and guidelines for management. Acta Neurochir (Wien). 2010 Jul;152(7):1139–44.
8. Timmer FA, van Rooij WJ, Beute GN, Teepen JL. Intramedullary lipoma. Neuroradiology. 1996 Feb;38(2):159–60.
9. Samartzis D, Gillis CC, Shih P, O'Toole JE, Fessler RG. Intramedullary Spinal Cord Tumors: Part II—Management Options and Outcomes. Glob Spine J. 2016 Mar 1;6(2):176–85.
10. Costigan DA, Winkelman MD. Intramedullary spinal cord metastasis. A clinicopathological study of 13 cases. J Neurosurg. 1985 Feb;62(2):227–33.
11. Dam-Hieu P, Seizeur R, Mineo JF, Metges JP, Meriot P, Simon H. Retrospective study of 19 patients with intramedullary spinal cord metastasis. Clin Neurol Neurosurg. 2009 Jan;111(1):10–7.

OP- IV/24

Is Clinical Improvement of Vision Reflected in Volume of the Visual Path Components: A Retrospective Study of Pituitary Adenomas

Özde Şenol Akbulut[1], Bilal Bahadır Akbulut[1], Mustafa Serdar Bölük[1], Nevhis Akıntürk[1], Hakan Ceylan[2], Taşkın Yurtseven[1], Hüseyin Biçeroğlu[1]

[1]Ege University Faculty of Medicine, Department of Neurosurgery
[2]Ege University Faculty of Medicine, Department of Otolaryngology

Objectives: 1.Is clinical improvement reflected as radiological changes in visual pathway components.2.Preliminary study to justify obtaining high-resolution-MRIs to re-examine these structures.

Background: After optic decompression in pituitary adenomas, visual acuity improvement occurs in three steps, and the most significant phase is the early slow phase, which is completed in the third month of the surgery. Studies demonstrated structural changes in patients with visual loss that can be seen in magnetic resonance imaging. These changes may be seen in postoperative third-month images of pituitary adenoma patients.

Method: We retrospectively analyzed patients over 18 years old that underwent first-time endoscopic transnasal surgery for pituitary adenomas by the same surgeon between 2018 and 2023. Only the patients with preoperative and third-month follow-up MRIs that were obtained within our institution are included. The patients' sex, age, preoperative and postoperative symptoms were analyzed. The corpus callosum's sagittal surface area near the midline, mammillary body volume, and superior colliculus volume were obtained from T2 sagittal images using 3D Slicer software (version 5.2.2).

Results: Out of 57 patients that were operated on, 28 were eligible for analysis. Patients were divided into two groups, with visual acuity loss (n=19) and without (n=9). Both groups were similar in terms of sex, age, and preoperative and postoperative symptoms.Linear mixed model and Brunner Langer model were performed to investigate whether there was a structural change between groups after the operation. While preliminary tests had shown there was a trend towards increased area/volumes, it was revealed that there was no statistically significant difference for corpus callosum surface area (p=0.84), mamillary body volumes (p= 0.81), and superior colliculus volume (p=0.47) for both groups.

Conclusions: While there was no statistically significant change in the structures that were examined, the small trend toward increase might justify conducting this study with a bigger sample group and with a longer follow-up period.

Keywords: pituitary adenoma, visual pathway, morphology, plasticity

References

1. Kerrison, J. B., Lynn, M. J., Baer, C. A., Newman, S. A., Biousse, V., & Newman, N. J. (2000). Stages of improvement in visual fields after pituitary tumor resection. Am. J. Ophthalmol., 11124302.
2. : Altiaylik Ozer P, Sayin R, Atac G, Sanhal E, Kocamaz MF, Sengun A. Correlation of corpus callosum index and optic coherence tomography findings in multiple sclerosis with or without optic nerve involvement. Eur Eye Res 2021;1:17-24.

OP- IV/25

Transorbital surgical corridor: an anatomical analysis of ocular globe translation and the associated exposure

Keaton Piper[1], Zeegan George[1], Miguel Saez-Alegre[2], Aneil Srivastava[3], Jeff Breton[3], Josef Williams[3], Daniel Felbaum[3], Walter Jean[2]

[1]Department of Neurologic Surgery and Brain Repair, University of South Florida, 2 Tampa General Circle, Tampa, Florida, 33606
[2]Division of Neurosurgery, Fleming Neuroscience Institute, Lehigh Valley Network, 1250 Cedar Crest Blvd, Allentown, PA, 18103.
[3]Department of Neurosurgery, MedStar Georgetown University Hospital, 2440 M St. NW #315, Washington, DC, 20037

Objectives: By utilizing computed tomography patient-specific models in virtual reality, precise areas and degrees of surgical freedom (AOF and DOF, respectively) provided by globe retraction were calculated. These measurements helped define a potential maximum safe AOF and DOF, as well as the amount of globe retraction needed to achieve a sufficient surgical corridor.

Background: The transorbital approach (TOA) to intracranial pathology varies by the extent of bony removal and the target. Orbital rim-sparing TOA with removal of only the orbit's posterior and superior wall provides optimal cosmetic results, without the need for reconstruction. This operative corridor is limited by the extent of ocular globe retraction. However, the surgical view available with progressive globe retraction has not yet been defined.

Method: Using Surgical Theater Precision Virtual Realty system, transorbital craniectomies were performed. The axial and sagittal DOF as well as AOF were calculated superior-lateral to the globe, limited by the orbital rim and globe. The anterior clinoid was utilized as the target reference point. The DOFs and AOFs were calculated for each degree of medial globe retraction.

Orbital rim-sparing craniectomy performed in virtual reality

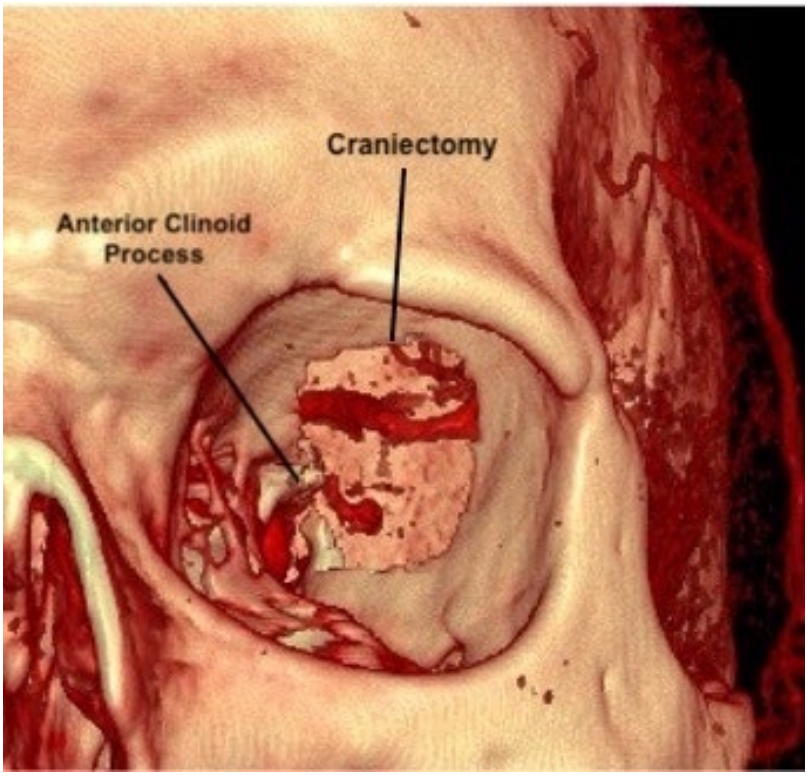

Results: At 15 mm of medial retraction (a previously studied point at which intraocular pressure raises), the AOF averaged 2189 mm2 and axial DOF averaged 23.1°. Eighteen degrees of freedom (a previously studied point needed to achieve sufficient working space for two TOA instruments) was achieved at 11 mm on average, which correlated with an AOF of 1675 mm2.

Virtual posts used as limits of surgical freedom with anterior clinoid target and globe retracted 5 mm medially.

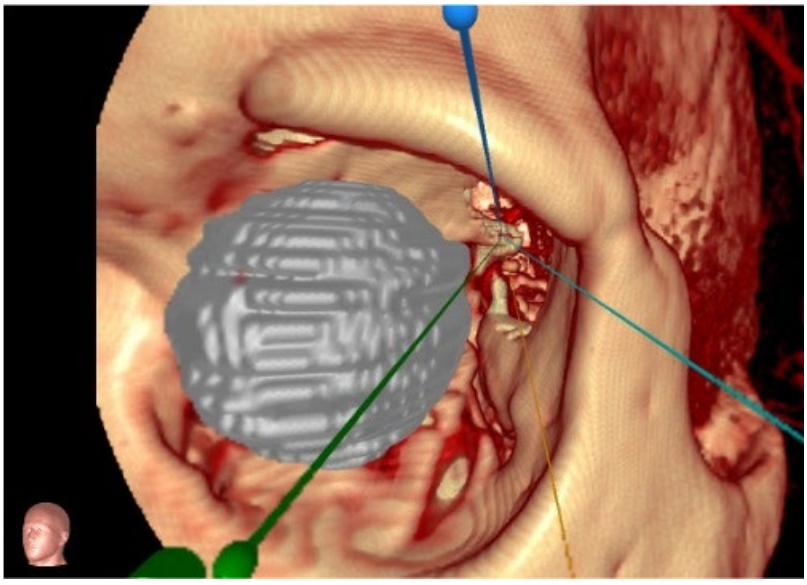

Area of surgical freedom calculated from four 14 cm posts from the anterior clinoid, in specimen with 10 mm of globe retraction medially.

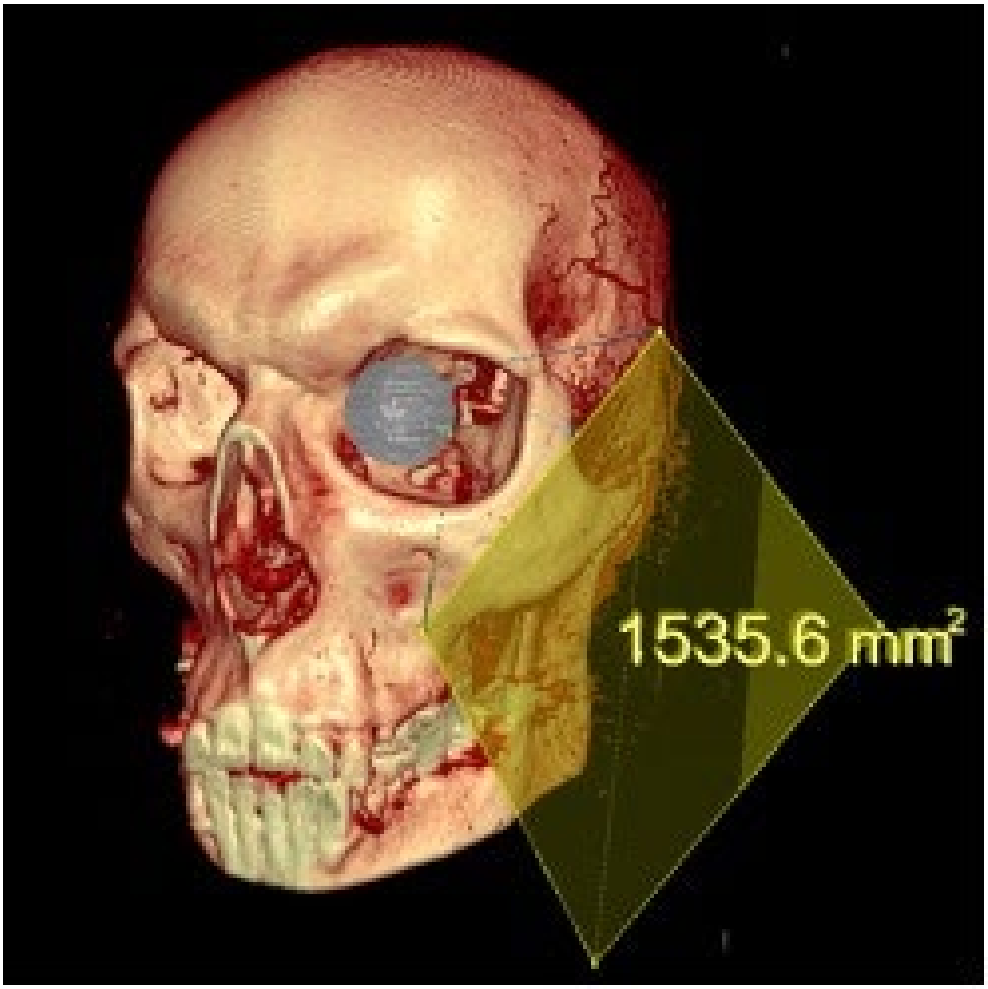

Conclusions: Without orbital rim removal, globe retraction of at least 11 mm is needed to achieve sufficient DOF for two surgical instruments. At 15 mm of medial retraction, over 2000 mm2 AOF is achieved with low risk of elevating IOP. These parameters should be considered when surgeons are planning for para-clinoid surgery via TOA to prevent ocular damage and determine if further rim resection is needed.

Keywords: Transorbital, clinoid, keyhole, skull base

References

1. Moe K. Orbital Lesions: Debate on Approaches. In: Morco J, editor. University of Miami Cerebrovascular and Skull base symposium 2023.
2. Kim W, Moon JH, Kim EH, Hong CK, Han J, Hong JB. Optimization of orbital retraction during endoscopic transorbital approach via quantitative measurement of the intraocular pressure - [SevEN 006]. *BMC Ophthalmol*. Feb 8 2021;21(1):76. doi:10.1186/s12886-021-01834-5

OP-III/26

Photorealistic three-dimensional models of the brain vascular anatomy based on layered dissections

Toma Spiriev[1], Kay Manuel Körner[2], Andrea Steuwe[3], Michael Wolf Vollenbröker[2], Vladimir Nakov[1], Jan Frederick Cornelius[4]

[1]Department of Neurosurgery, Acibadem City Clinic University Hospital Tokuda, Sofia, Bulgaria.
[2]Institute for Anatomy I, Medical Faculty & University Hospital Düsseldorf, Heinrich Heine University Düsseldorf, Germany.
[3]Department of Diagnostic and Interventional Radiology, Medical Faculty & University Hospital Düsseldorf, Heinrich Heine University Düsseldorf, Germany.
[4]Department of Neurosurgery, Medical Faculty & University Hospital Düsseldorf, Heinrich Heine University Düsseldorf, Germany.

Objectives: To present brain vascular anatomy in photorealistic three-dimensional data (3D), that can be used as teaching tool to medical students, neurosurgical and neurological residents and fellows as self-study, lecture material, augmented (AR) and virtual reality (VR) settings.

Background: Brain vascular anatomy is complicated due to numerous branches, segments and tortuosity of the main blood vessels that supply the brain. Contemporary surface scanning technology can be used to create high-quality anatomical photorealistic 3D models, based on actual dissections, that serve as a learning and teaching tool.

Method: Two formaldehyde fixed heads from the body donation program of the Heinrich-Heine-University Dusseldorf were used for the study. The arterial and venous system were injected with colored radiopaque material supplemented silicone and latex. The specimens were CT scanned prior dissections to generate post-mortem angiography. Stratigraphical anatomical dissection of the neck and brain was performed to present the brain related vascular anatomy. A simplified photogrammetry method together with open-source 3D software were used to process the 3D data.

Results: Twenty six detailed layered photorealistic 3D models were generated which allowed zooming panning, rotating the resulted data sets. Topographical relevant anatomical structures and landmarks were annotated and exported for web-viewing on a dedicated online platform, as well as incorporated to AR/VR environment. The data sets were used in our teaching curriculum which resulted in high-positive feedback from neurosurgical and neurological residents as well as medical students.

Exemplary model 1: Cortical brain vessels

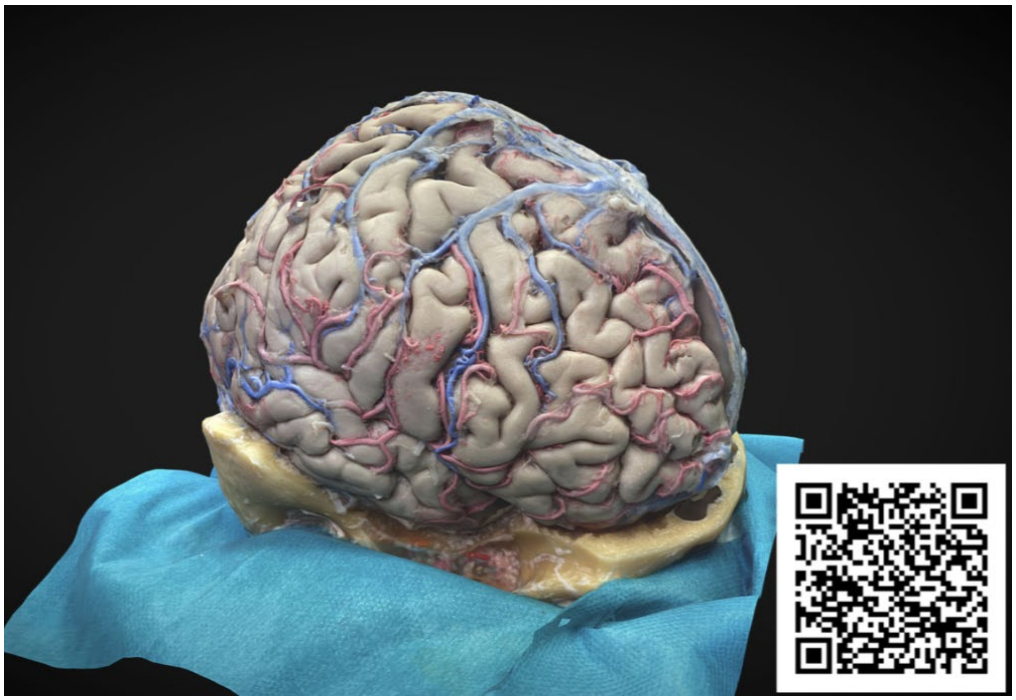

Superficial cortical brain vessels. Please scan the QR code for 3D model and augmented reality

Exemplary model 2: Choroidal and perforating arteries; tentorial incisura



The hippocamp is retracted laterally revealing the tentorial incisura, choroidal and perforating arteteries supplying the internal capsule and basal ganglia. Please scan the QR code for 3D model and augmented reality

Exemplary model 3: Deep venous anatomy

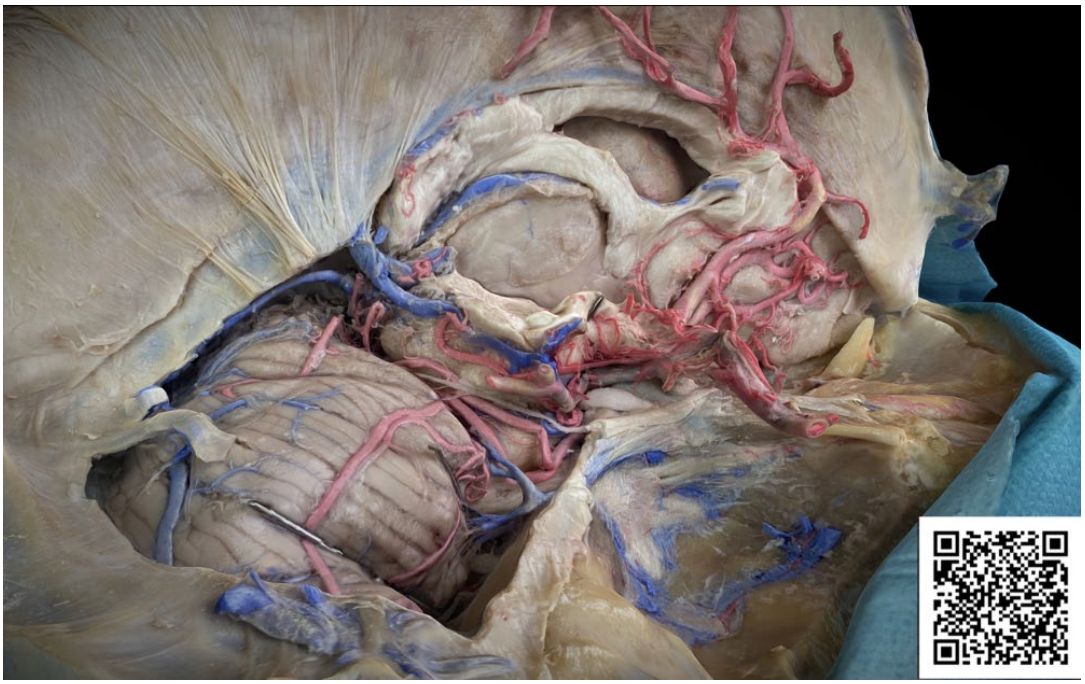

The deep venous drainage, cavernous sinus. Please scan the QR code for 3D model and augmented reality

3D models

Representative 3D models links
1) Neck Vessels: https://sketchfab.com/3d-models/5-mastoidectomy-and-vertebral-a-fca572bc7cb74edfa0a0b648ac628ebf
2)Brainstem vessels: https://sketchfab.com/3d-models/cerebellum-and-brainstem-d3a79a7028c8407ebd0f1653488d1908

Representative 3D models links

Conclusions: Photogrammetry based surface scanning is an excellent tool to generate high quality and detailed photorealistic anatomical 3D models that can be used as a teaching tool. Future surveys are needed to evaluate further benefits of this method and various possible educational applications compared to traditional teaching methods.

Keywords: Photogrammetry, Virtual reality, Augmented reality, Brain vascular anatomy

References

1. GursesME,GungorA,HanaliogluS,etal.Qlone®:asimplemethodtocreate360- degree photogrammetry-based 3-dimensional model of cadaveric specimens. Oper Neurosurg. 2021;21(6):e488-e493.
2. Vigo V, Pastor-Escart ın F, Doniz-Gonzalez A, et al. The smith-robinson approach to the subaxial cervical spine: a stepwise microsurgical technique using volumetric models from anatomic dissections. Oper Neurosurg. 2021;20(1):83-90.
3. KournoutasI,VigoV,ChaeR,etal.Acquisitionofvolumetricmodelsofskullbase anatomy using endoscopic endonasal approaches: 3D scanning of deep corridors via photogrammetry. World Neurosurg. 2019;129:372-377.
4. Rubio RR, Shehata J, Kournoutas I, et al. Construction of neuroanatomical volumetric models using 3-dimensional scanning techniques: technical note and
5. applications. World Neurosurg. 2019;126:359-368.
6. Rodriguez Rubio R, Xie W, Vigo V, et al. Immersive Surgical Anatomy of the Retrosigmoid Approach. *Curēus (Palo Alto, CA)*. 2021;13(6):e16068-e16068. doi:10.7759/cureus.16068
7. Xu Y, Vigo V, Klein J, et al. Pursuing perfect 2D and 3D photography in neuroanatomy: a new paradigm for staying up to date with digital technology. *Journal of Neurosurgery*. 01 Oct. 2022 2022:1-7. doi:10.3171/2022.9.Jns221988
8. Three-Dimensional Modeling and Extended Reality Simulations of the Cross-Sectional Anatomy of the Cerebrum, Cerebellum, and Brainstem. Muhammet Enes Gurses 1, Sahin Hanalioglu 1, Giancarlo Mignucci-Jiménez 1, Elif Gökalp 2, Nicolas I Gonzalez-Romo 1, Abuzer Gungor 3, Aaron A Cohen-Gadol 4 5, Uğur Türe 3, Michael T Lawton 1, Mark C Preul 1. Oper Neurosurg (Hagerstown) 2023 Apr 21. doi: 10.1227/ons.0000000000000703.
9. Three-Dimensional Modeling and Augmented and Virtual Reality Simulations of the White Matter Anatomy of the Cerebrum. Muhammet Enes Gurses 1 2 , Abuzer Gungor 2 3 , Elif Gökalp 4 , Sahin Hanalioglu 1 , Seda Yagmur Karatas Okumus 2 3 , Ilkan Tatar 5 , Mustafa Berker 1 , Aaron A Cohen-Gadol 6 7 , Uğur Türe 2. Oper Neurosurg (Hagerstown). 2022 Nov 1;23(5):355-366.

OP- IV/27

Neuronavigated standard suboccipital retrosigmoidal approach: Morphometric comparison of the microscopical and endoscopical surgical area of exposure of the brain stem

Zafer Cinibulak[1]

[1]Department of Neurosurgery, Merheim Hospital/University of Witten/Herdecke, Cologne, Germany

Objectives: The aim of the anatomical study is to evaluate and to compare the surgical area of exposure for the microscopical standard suboccipital retrosigmoidal approach (SSRA) and the endoscopical-assisted SSRA.

Background: Microscopical and endoscopical surgical areas of exposure of the SSRA vary widely. For surgical treatments of pathologies at the brain stem, the knowledge about the surgical area of exposure plays a crucial role.

Method: Ten adult human cadaver heads (20 sides) underwent a neuronavigated SSRA. Microsurgical and endoscopic (0 and 30 degree-optic) vector coordinates at the brain stem were marked and noted using neuronavigation. The surgical area of exposure and the corresponding angle of attack was calculated and compared.

Microscopical and endoscopical view to the brain stem.

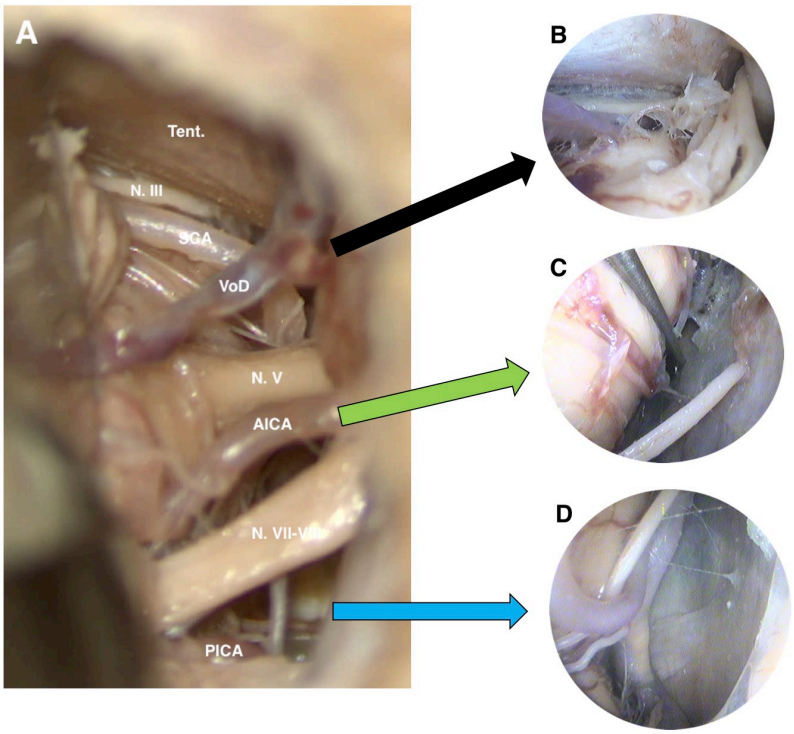

Microscopical (A) and corresponding endoscopical (B, C, D) view and access to the exposed brain stem area on the right side through different scope areas via a standard suboccipital retrosigmoidal approach.

Results: The mean endoscopic-assisted area of exposure (428, 43 mm2 ± 26,21 mm2 (Range: 386,23 – 457,29 mm2)) was significantly more than the microcopical area of exposure (338, 97 mm2 ± 24,76 mm2 (Range: 311,72 – 361,45 mm2)). Notable, the endoscope increases the view located at the ventral brain stem. However, the mean angle of attack for the microscope (39,89° ± 2,56° (Range: 36,31° - 42,06°)) and for the endoscope (39,56° ± 2,63° (Range: 36,14° - 41,88°) were almost equal.

Outlined view to the brain stem.

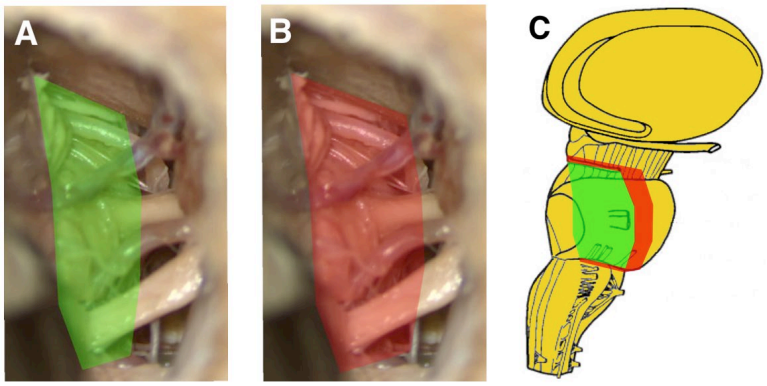

Anatomical (A and B) and outlined (C) comparison of the colour highlighted microscopical (green) and endoscopical (red) accessible brain stem area via a standard suboccipital retrosigmoidal approach.

Conclusions: Endoscopic-assisted SSRA helps to verify the microscopical complete resection of lesions and gives more additional surgical access to lesions located ventral to the brain stem provided that safe surgical maneuverability is given under this operative setting

Keywords: Endoscope, Brain Stem, Cerebellopontine Angle, Retrosigmoidal Approach

References

1. Ries Centeno T, Villamil F, Marco Del Pont F, Giovannini S, Caffaratti G, Cervio A. Posterior fossa endoscopic-assisted surgery: A systematization of its surgical corridors. *Neurochirurgie*. 2022;68(1):21-28. doi:10.1016/j.neuchi.2021.07.001
2. Kunigelis K, Yang A, Youssef AS. Endoscopic Assisted Retrosigmoid Approach for Cerebellopontine Angle Epidermoid Tumor. *J Neurol Surg B Skull Base*. 2018;79(Suppl 5):S413-S414. doi:10.1055/s-0038-1669978
3. Sun JQ, Sun JW. Endoscope-assisted retrosigmoid keyhole approach for cerebellopontine angle: cadaveric study. *Acta Otolaryngol*. 2013;133(11):1154-1157. doi:10.3109/00016489.2013.817682

OP-III/28

Qlone: A Simple Method to Create 360-Degree Photogrammetry-Based 3-Dimensional Model of Cadaveric Specimens

Muhammet Enes Gurses[1], Abuzer Gungor[3], Sahin Hanalioglu[1], Cumhur Kaan Yaltirik[4], Mustafa Berker[1], Uğur Türe[2]

[1]Department of Neurosurgery, Hacettepe University, Ankara, Turkey
[2]Department of Neurosurgery, Microsurgical Neuroanatomy Laboratory, Yeditepe University School of Medicine, Istanbul, Turkey
[3]Department of Neurosurgery, University of Health Sciences, Bakirkoy Prof. Dr Mazhar Osman Training and Research Hospital for Neurology, Neurosurgery and Psychiatry, Istanbul, Turkey
[4]Department of Neurosurgery, University of Health Sciences, Istanbul Training and Research Hospital, Istanbul, Turkey
[5]Department of Neurosurgery, Karadeniz Technical University, Trabzon, Turkey

Objectives: To provide a practical method for 3-dimensional (3D) visualization of cadaveric specimens to maximize the utility of these precious educational materials.

Background: Human cadavers are an essential component of anatomy education. However, access to cadaveric specimens and laboratory facilities is limited in most parts of the world. Hence, new innovative approaches and accessible technologies are much needed to enhance anatomy training.

Method: Embalmed cadaveric specimens (cerebrum, brain stem, and cerebellum) were used. The 3D models of cadaveric specimens were built by merging multiple 2- dimensional photographs. Pictures were taken with standard mobile devices (smartphone and tablet). A photogrammetry program (Qlone , 2017-2020, EyeCue Vision Technologies Ltd, Yokneam, Israel), an all-in-one 3D scanning and augmented reality technology, was then used to convert the images into an integrated 3D model.

Equipment for using the application. A,ARmat. B,Foldio360turntable platform. C,Cadaveric specimen on the AR mat. D, AR mat placed on the Foldio360 platform with lighting box



FIGURE 1. *Equipment for using the application. A, AR mat. B, Foldio360 turntable platform. C, Cadaveric specimen on the AR mat. D, AR mat placed on the Foldio360 platform with lighting box (optional).*

Equipment for using the application. A,ARmat. B,Foldio360turntable platform. C,Cadaveric specimen on the AR mat. D, AR mat placed on the Foldio360 platform with lighting box

Figure 2



FIGURE 2. *Scanning technique used by Qlone®. A, Specimen on the AR mat. B, AR dome digitally created by Qlone®. C, Blue columns indicate correct angle for image capture and they are cleared as the image capturing progresses. D, Red columns indicate incorrect angle, which does not allow for image capture; thus, the camera should be moved to find a correct one.*

Results: High-resolution 360-degree 3D models of the cadaveric specimens were obtained. These models could be rotated and moved freely on different planes, and viewed from different angles with varying magnifications. Advanced editing options and the possi- bility for export to virtual- or augmented-reality simulation allowed for better visualization.

Figure 3

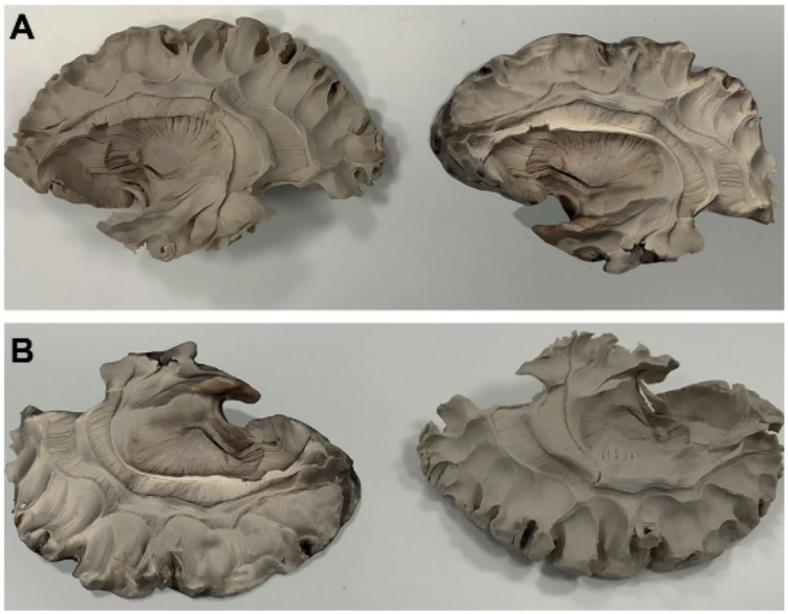

FIGURE 3. *Visualization of 360-degree 3D scanned models and real cadaveric specimens with 2 different angles.* **A**, *Lateral white matter dissection of a left hemisphere is viewed from a slightly inferior angle.* **B**, *Slightly superior angle to show the impact of different illumination angles.*

Conclusions: This inexpensive, simple, and accessible method for creating 360-degree 3D cadaveric models can enhance training in neuroanatomy and allow for a highly realistic surgical simulation environment for neurosurgeons worldwide.

Keywords: Augmented Reality, Surgical Neuroanatomy, Virtual Reality, White Matter Dissection

References

1. Javaid MA, Chakraborty S, Cryan JF, Schellekens H, Toulouse A. Understanding neurophobia: reasons behind impaired understanding and learning of neuroanatomy in cross-disciplinary healthcare students. Anat Sci Educ. 2018;11(1):81-93.
2. Ghosh SK. Human cadaveric dissection: a historical account from ancient Greece to the modern era. Anat Cell Biol. 2015;48(3):153-169.
3. Nieder GL, Scott JN, Anderson MD. Using QuickTime virtual reality objects in computer-assisted instruction of gross anatomy: Yorick–the VR skull. Clin Anat. 2000;13(4):287-293.
4. Balogh A, Preul MC, Schornak M, Hickman M, Spetzler RF. Intraoperative stereoscopic QuickTime virtual reality. J Neurosurg. 2004;100(4):591-596.

5. Goo HW, Park SJ, Yoo SJ. Advanced medical use of three-dimensional imaging in congenital heart disease: augmented reality, mixed reality, virtual reality, and three-dimensional printing. Korean J Radiol. 2020;21(2):133-145.
6. De Benedictis A, Nocerino E, Menna F, et al. Photogrammetry of the human brain: a novel method for three-dimensional quantitative exploration of the structural connectivity in neurosurgery and neurosciences. World Neurosurg. 2018;115:e279-e291. doi: 10.1016/j.wneu.2018.04.036.
7. Qlone, © 2017–2020 EyeCue Vision Technologies LTD. https://www.qlone.pro/. Accessed March 10, 2021.
8. Foldio360®, Orangemonkie Co., Ltd., San Diego. http://www.foldio360.de/. Accessed March 10, 2021.
9. Petriceks AH, Peterson AS, Angeles M, Brown WP, Srivastava S. Photogrammetry of human specimens: an innovation in anatomy education. J Med Educ Curr Dev. 2018;17(5):2382120518799356.
10. Rubio RR, Shehata J, Kournoutas I, et al. Construction of neuroanatomical volumetric models using 3-dimensional scanning techniques: technical note and applications. World Neurosurg. 2019;126:359-368. doi:10.1016/j.wneu.2019.03.099.
11. Sikes R, Bernardo C, Yavetz E, Chan J. From 3D brains to 3D PDFs: creating virtual 3D models of human brains for neuroanatomy classes through photogrammetric 3D scanning. FASEB J. 2018;31(S1):736.3.
12. Straub J, Kading B, Mcheick H, Kerlin SD. Characterization of a large, low-cost 3D scanner. Technologies. 2015;3(1):19-36.
13. Haluck RS, Krummel TM. Computers and virtual reality for surgical education in the 21st century. Arch Surg. 2000;135(7):786-792.
14. Cikla U, Sahin B, Hanalioglu S, Ahmed AS, Niemann D, Baskaya MK. A novel, low-cost, reusable, high-fidelity neurosurgical training simulator for cerebrovascular bypass surgery [published online ahead of print: May 11, 2018]. J Neurosurg. doi: 10.3171/2017.11.JNS17318.
15. Estevez ME, Lindgren KA, Bergethon PR. A novel three-dimensional tool for teaching human neuroanatomy. Anat Sci Educ. 2010;3(6):309-317.
16. Lujan HL, DiCarlo ES. First-year medical students prefer multiple learning styles. Adv Physiol Educ. 2006;30(1):13-16.
17. Alharbi Y, Al-Mansour M, Al-Saffar R, Garman A, Alraddadi A. Three-dimensional virtual reality as an innovative teaching and learning tool for human anatomy courses in medical education: a mixed methods study. Cureus. 2020;12(2):e7085.
18. Petriceks AH, Peterson AS, Angeles M, Brown WP, Srivastava S. Photogrammetry of human specimens: an innovation in anatomy education. J Med Educ Curric Dev. 2018;5. doi:10.1177/2382120518799356.
19. The Rhoton Collection, http://rhoton.ineurodb.org/mobile. Accessed March 10, 2021.
20. The Neurosurgical Atlas, https://www.neurosurgicalatlas.com/3d-models Accessed May 11, 2021.
21. Gorman PJ, Meier AH, Rawn C, Krummel TM. The future of medical education is no longer blood and guts, it is bits and bytes. Am J Surg. 2000;180(5):353-356.
22. Hoffman H, Vu D. Virtual reality: teaching tool of the twenty-first century?Acad Med. 1997;72 (12):1076-1081.

OP-III/30

Extended anterior petrosectomy with partial clivectomy for vertebrobasilar junction and adjacent area: cadaveric dissection study

Turab Gasimov[1], Nadia Morales Acosta[1], Alberto Acitores Cancela[1], Mehmet Sabri Gurbuz[1], Hilal Akdemir Aktas[1], Abdullah Keles[1], Ufuk Erginoglu[1], Mustafa Kemal Baskaya[1]

[1]University of Wisconsin-Madison

Objectives: In this study, we aim to perform a systematic cadaveric dissection to extend anterior petrosectomy with partial clivectomy to expose the VBJ and basilar trunk with the possibility of surgical manipulation.

Background: Anterior petrosectomy provides exposure to anterolateral pons. With this approach, surgical exposure of the vertebrobasilar junction and the basilar trunk is usually not possible unless the vertebral or basilar artery has a tortuous course towards the site of the approach. This approach could be extended to expose the ambient cistern and inferolateral midbrain.

Method: We performed unilateral dissections in 10 cadaveric specimens. After completing the anterior petrosectomy, extradural bone removal was continued towards the clivus. Once the inferior petrosal sinus was exposed, petrosectomy was continued towards the jugular foramen. As the main step, the bone between the carotid canal and the inferior petrosal sinus was removed, and the clivus was exposed and drilled. Dura underlying the petrous bone was opened. Inferior petrosal sinus was ligated closer to the jugular bulb to avoid the sixth nerve damage. Opening the dura underlying the removed part of the clivus exposes the area of interest.

Results: The vertebrobasilar junction area, including the anterior spinal artery along with its tributaries, was exposed in nine specimens (9/10). In one specimen, VBJ could not be seen because of the incomplete caudal fusion of the basilar artery. The course of the sixth nerve between the origin and the inferior petrosal sinus was seen in all specimens. In seven specimens, the origin of the anterior inferior cerebellar artery was seen at the uppermost part of the exposure; however, surgical manipulation around the anterior inferior cerebellar artery origin was restricted.

Right-sided extended anterior petrosectomy

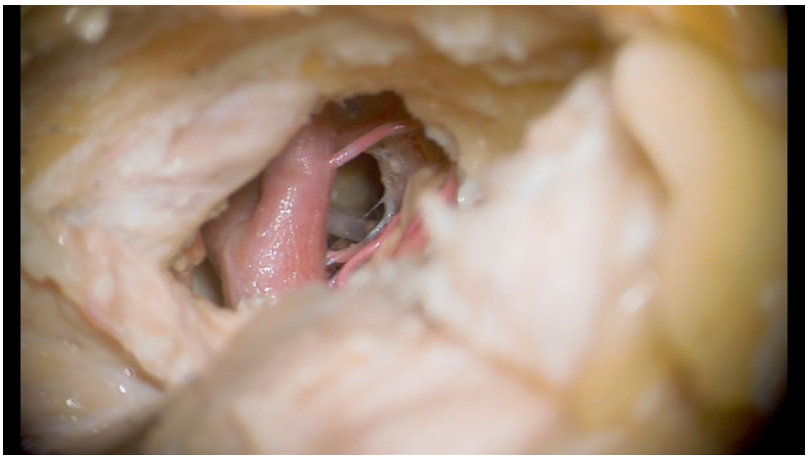

Right-sided anterior petrosectomy has been extended by partial clivectomy. The vertebrobasilar junction including both vertebral artery and proximal basilar artery are exposed. Note the right PICA(posterior inferior cerebellar artery) originating from the right vertebral artery.

Extended anterior petrosectomy, caudal exposure

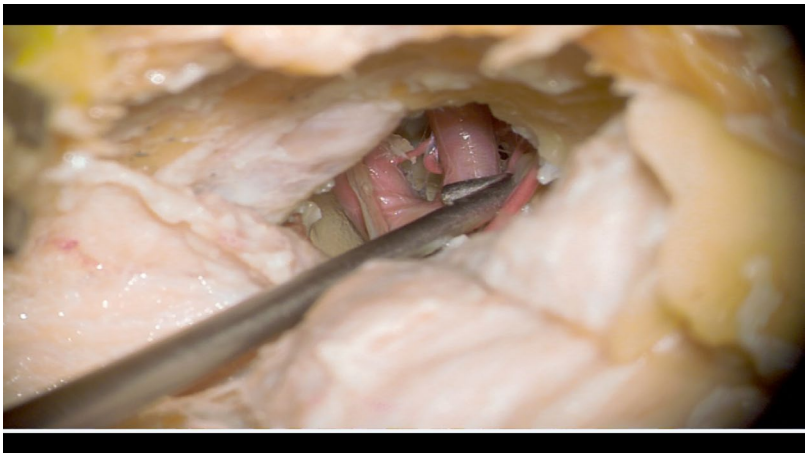

In the same specimen, more caudal directing the microscope exposes the origin of both anterior spinal arteries, arising from the medial wall of the vertebral arteries.

Conclusions: Extended anterior petrosectomy with partial clivectomy provides sufficient surgical exposure to the vertebrobasilar junction and the proximal basilar trunk.

Keywords: basilar trunk, extended anterior petrosectomy, microneurosurgical anatomy, vertebrobasilar junction

References

1- Bernardo A, Evins AI (2023): Transpetrosal Routes to the Skull Base-Anterior and Posterior Transpetrosal Approaches. World Neurosurg 172, 146–162
2- Lv X, Wu Z (2015): Anatomic variations of internal jugular vein, inferior petrosal sinus and its confluence pattern: Implications in inferior petrosal sinus catheterization. Interv Neuroradiol 21, 769–773

OP-III/32

Treatment choice of direct or endovascular surgery -from a hybrid neurosurgeon's perspective-

Hitoshi Fukuda[1]

[1]Kochi Medical School Hospital

Objectives: Endovascular therapy is widely accepted as a less invasive treatment option for cerebrovascular disorders. However, when endovascular therapy is at high risk or more durability is required, direct surgery is still an important tool.

Background: In this presentation, we discuss how we should choose direct or endovascular surgery for the equivocal lesions, and how we should combine direct and endovascular surgery for complex cerebrovascular lesions.

Method: In the aging society in Japan, one of the concerns is optimal treatment for ruptured aneurysms of the elderly. Less invasive endovascular therapy is favorable at the acute stage of subarachnoid hemorrhage. However, when the initial coil embolization is incomplete, staged surgical clipping at the chronic stage may be justified for complete cure.

Results: Direct surgery is also advantageous to treat intracranial aneurysms with mass effect, ruptured very small aneurysms (<3mm), and intractable internal carotid artery lesions. Neck clipping more effectively reduces mass effect of the posterior communicating artery (PCoA) aneurysm with oculomotor nerve palsy than intraaneurysmal coil embolization. Endovascular treatment of the very small aneurysm is associated with higher risk of procedure-related complications.

Conclusions: Although surgical clipping is favored, direct surgery for ruptured very small aneurysms is still challenging because different entity such as vessel dissection and pseudoaneurysm is sometimes included. Flow diverter is currently available for unruptured internal carotid artery pathologies. However, parent artery occlusion with bypass surgery is still required to treat atypical regions including the acute stage of the ruptured aneurysm, vessel dissection, traumatic aneurysm, and giant aneurysm. Bypass surgery is also effective as a flow alteration strategy for intractable aneurysms that repeatedly recurred after multiple sessions of endovascular therapy.

Keywords: direct surgery, endovascular therapy, treatment choice, hybrid neurosurgeon

OP- IV/33

Can Machine Learning Algorithms Be An Alternative To Invasive Procedures In The Differential Diagnosis Of ACTH-Dependent Cushing's Syndrome?

Dilan Özaydın[1], Necmettin Tanrıöver[3], Pınar Kadıoğlu[2]

[1]Department of Neurosurgery, University of Health Sciences, Kartal Dr. Lütfi Kırdar City Hospital
[2]Istanbul University-Cerrahpasa, Department of Endocrinology, Metabolism, and Diabetes, Istanbul/Turkiye
[3]Istanbul University-Cerrahpaşa, Department of Neurosurgery, Istanbul/Turkiye

Objectives: The objective of this study was to develop machine learning algorithms as an alternative to invasive procedures for the differential diagnosis of ACTH-dependent Cushing's syndrome (CS) using biochemical parameters and radiological images.

Background: Bilateral inferior petrosal sinus sampling (BIPSS) is the gold standard method in the differential diagnosis of ACTH-dependent CS. However, the widespread use of BIPSS is hampered by its high cost, invasive nature, and limited expertise. Therefore, there is a clear need for noninvasive, inexpensive, and easily applicable methods for the differential diagnosis of ACTH-dependent CS.

The patient population and the variables selected for machine learning

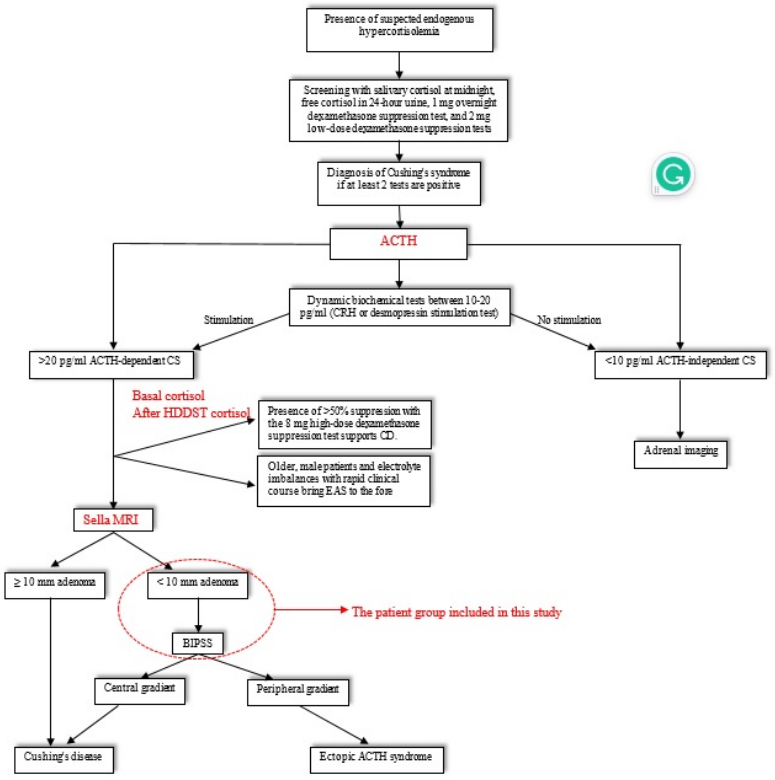

Method: Random forest algorithms were used for machine learning, and the area under the receiver operating characteristics curve (AUROC) was used to measure performance. We used Shapley Contributed comments (SHAP) values that help explain the outputs of the ML models to identify the importance of each feature and make it easy to interpret. Baseline cortisol and ACTH, high-dose dexamethasone suppression tests, and sella magnetic resonance images were selected as variables. Medical records of 60 patients who underwent bilateral inferior petrosal sinus sampling between 2016 and 2022 were reviewed. After applying exclusion criteria, 35 patients were included in the final analysis.

Results: Among the included patients, 24 had Cushing's disease and 11 had ectopic ACTH syndrome. The machine learning task was created to classify patients with ACTH-dependent CS into Cushing's disease and ectopic ACTH syndrome. The average AUROC value obtained in cross-validation was 0.960. The specificity of the machine learning algorithm for Cushing's disease was 86%, and the sensitivity was 91%. The correct diagnosis was made in 91.4% of patients. Using SHAP, we found that the most influential factor in classification was adenoma size.

Case example

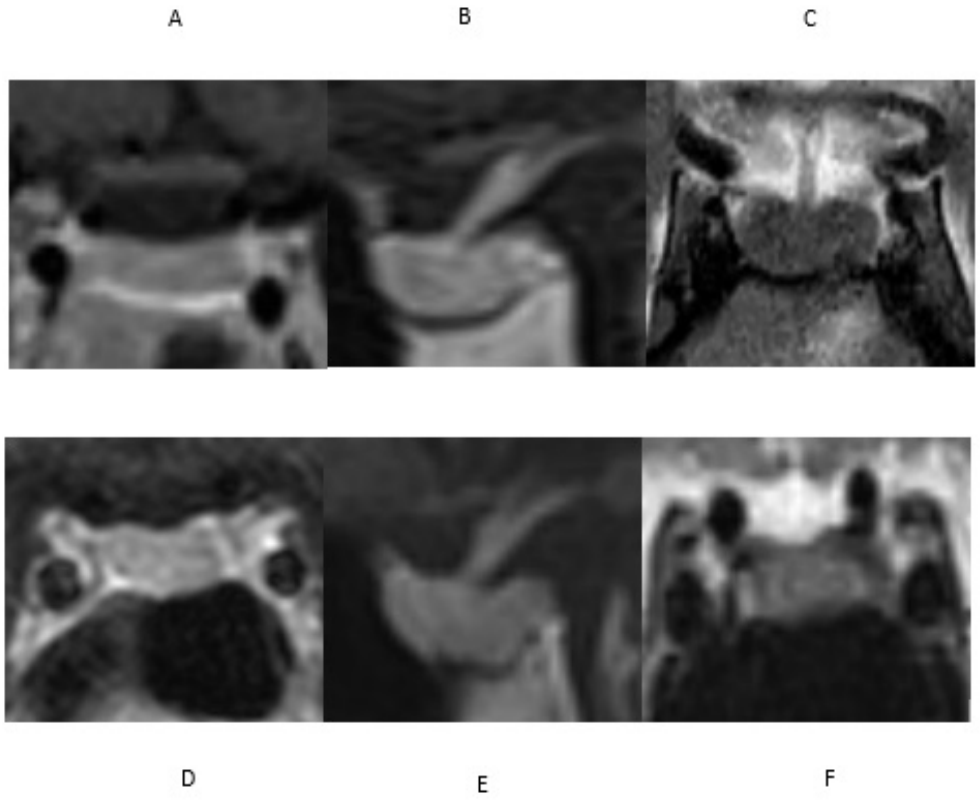

A-B-C: Sella MRI of a patient with Cushing's disease given as an example D-E-F: Sella MRI of a patient with ectopic ACTH syndrome given as an example

SHAP values of the variables of the ML model used to classify ACTH-dependent CS

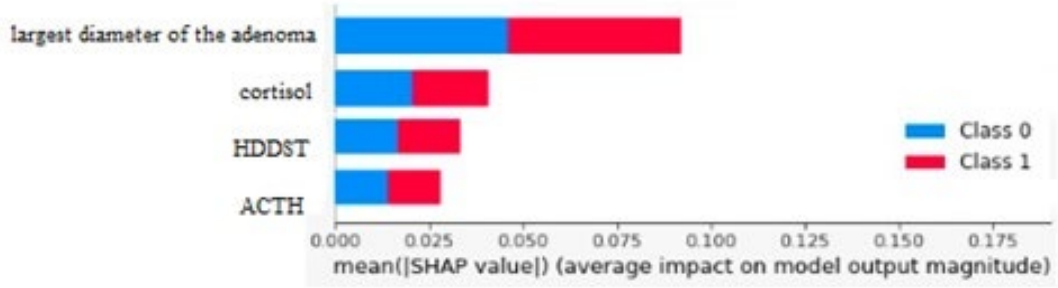

The characteristics of the patients at the time of diagnosis

	Patients with EAS	Patients with CD	p-value
Sex, female, n (%)	8 (72.7)	18 (75)	0.891
Age at diagnosis, year, mean ± SD	43.64 ± 16.31	44.88 ± 12.54	0.807
Basal ACTH, NV 0-46ng/l, median [IQR]	35.0 [20.0-84.0]	29.0 [21.75-61.63]	0.422
Basal cortisol, NV 6.2-19.4µg/dl, median [IQR]	24.0 [20.56-41.38]	18.75 [16.0-26.88]	0.072
Cortisol after HDDST, µg/dl, median [IQR]	6.76 [2.58-28.80]	2.96 [2.54-4.58]	0.025
Presence of >50% suppression after HDDST, n (%)	7 (63.6)	23 (95.8)	0.010
Presence of suspicious lesion in MRI, n (%)	3 (27.3)	22 (91.7)	<0.001
Suspicious lesion diameter in MRI, mm, mean ± SD	1.21 ± 2.07	4.5 ± 1.29	<0.001
Central/peripheral ratio before stimulation in BIPSS	1.63 ± 0.76	13.45 ± 20.86	0.071
Central/peripheral ratio after stimulation in BIPSS	2.29 ± 1.79	35.15 ± 30.29	0.001
Peak ACTH level in the center after stimulation	79.50 [28.35-209.55]	1379.50 [706-2000]	<0.001

EAS, Ectopic ACTH syndrome; CD, Cushing's disease; NV, Normal values; IQR, Interquartile range; HDDST, High dose dexamethasone suppression test; MRI, Magnetic resonance imaging; BIPSS, Bilateral inferior petrosal sinus sampling

Performance of tested parameters in the differential diagnosis of ACTH-dependent Cushing's syndrome

	AUROC	95% CI	Specificity	Sensitivity	NPV	PPV	Accuracy
Basal ACTH*	0.460	0.237-0.683	36%	63%	30.4%	66.7%	42.9%
Basal cortisol*	0.305	0.106-0.504	36%	42%	53.3%	80%	65.7%
HDDST*,γ	0.335	0.106-0.564	35%	67%	80%	76.7%	77.1%
Lesion diameter on sella MRI*	0.833	0.685-0.982	73%	92%	80%	88%	85.7%
Central/peripheral ratio before stimulation in BIPSS*	0.788	0.639-0.937	73%	71%	57.1%	85.7%	74.3%
Central/peripheral ratio after stimulation in BIPSS*	0.951	0.884-1.000	72.7%	91.7%	80%	88%	85%
Peak ACTH level in the center after stimulation*	0.904	0.802-1.000	90%	88%	86.4%	64.3%	80%
Machine learning as a clinical decision support tool	0.960	0.878-1.000	86%	91%	92.9%	88.6%	91.4%

ACTH, Adrenocorticotropin hormone; AUROC, Area under the receiver operating characteristics; BIPSS, Bilateral inferior petrosal sinus sampling; CI, Confidence intervals; HDDST, High dose dexamethasone suppression test; MRI, Magnetic resonance imaging; NPV, Negative predictive value; PPV, Positive predictive value *For the diagnosis of Cushing's Disease, the highest performing basal ACTH value was 26.67 ng/ml, basal cortisol value was 22.91 µg/dl, 215 ng/l for the peak ACTH value after stimulation in BIPSS, and the presence of lesions larger than 3 mm in sella MRI were calculated. Classically more than 50% suppression was used for HDDST, and central/peripheral ratio values of >2 for pre-stimulation and >3 post-stimulation in BIPSS were used. γ In addition, the best cut-off value for HDDST in the differential diagnosis of ACTH-dependent CS was found to be 2.73 µg/dl.

Conclusions: Machine learning algorithms have the potential to serve as an alternative decision support tool to invasive procedures in the differential diagnosis of ACTH-dependent CS.

Keywords: Bilateral inferior petrosal sinus sampling, Cushing's syndrome, Differential diagnosis, Machine learning

References

1. Nieman LK, Biller BM, Findling JW, et al.; Endocrine Society. Treatment of Cushing's syndrome: an endocrine society clinical practice guideline. *J Clin Endocrinol Metab*.2015;100(8):2807–2831
2. Hayes AR, Grossman AB. The ectopic adrenocorticotropic hormone syndrome: rarely easy, always challenging. *Endocrinol Metab Clin North Am*.2018;47(2):409–425
3. Lacroix A, Feelders RA, Stratakis CA, Nieman LK. Cushing's syndrome. *Lancet*.2015;386(9996):913–927
4. Lonser RR, Nieman L, Oldfield EH. Cushing's disease: pathobiology, diagnosis, and management. *J Neurosurg*.2017;126(2):404–417
5. Findling JW, Raff H. Cushing's syndrome: important issues in diagnosis and management. *J Clin Endocrinol Metab*.2006;91(10):3746–3753
6. Lindsay JR, Nieman LK. Differential diagnosis and imaging in Cushing's syndrome. *Endocrinol Metab Clin North Am*.2005;34(2):403–21, x
7. Lefournier V, Gatta B, Martinie M, et al. One transient neurological complication (sixth nerve palsy) in 166 consecutive inferior petrosal sinus samplings for the etiological diagnosis of Cushing's syndrome. *J Clin Endocrinol Metab.*1999;84(9):3401–3402
8. Kaltsas GA, Giannulis MG, Newell-Price JD, et al. A critical analysis of the value of simultaneous inferior petrosal sinus sampling in Cushing's disease and the occult ectopic adrenocorticotropin syndrome. *J Clin Endocrinol Metab*.1999;84(2):487–492
9. Pecori Giraldi F, Cavallo LM, Tortora F, et al.; Altogether to Beat Cushing's Syndrome Group. The role of inferior petrosal sinus sampling in ACTH-dependent Cushing's syndrome: review and joint opinion statement by members of the Italian Society for Endocrinology, Italian Society for Neurosurgery, and Italian Society for Neuroradiology. *Neurosurg Focus*.2015;38(2):1–7
10. Swearingen B, Katznelson L, Miller K, et al. Diagnostic errors after inferior petrosal sinus sampling. *J Clin Endocrinol Metab*.2004;89(8):3752–3763
11. 11.Cleophas TJ. Machine Learning in Therapeutic Research: The Hard Work of Outlier Detection in Large Data. *Am J Ther*. 2016;23(3):e837-e843

OP- IV/109

Photo-Stacking Technique for Neuroanatomical Education

Daniel Ballesteros-Herrera[1], Jose Alfonso Alvarez-Castro[1]

[1]National Institute of Neurology and Neurosurgery "Manuel Velasco Suarez"

Objectives: 1.Assess the ability to identify and label key neuroanatomical structures using photo-stacking technique.2.Assess the ability to create 3-D models of the brain using photo-stacking technique.

Background: Photo-stacking can be used in a variety of medical fields, including anatomy, pathology, and surgery. It can be applied to various types of medical imaging, including radiography, CT scans, MRI, and ultrasound. Detailed three-dimensional neuroanatomical knowledge is of paramount importance in neurosurgical training.

Method: We describe in a stepwise approach the photo-stacking method used to produce those mentioned above. Time for picture acquisition, file conversion, processing, and final production was measured using two processing methods. We also report the total number and file size of pictures. Measures of central tendency and dispersion report the measurements.

Results: Ten models were used in both methods for 20 models and high-definition photographs. The mean number of acquired pictures was 40.6 (14-67), picture acquisition time 51.50 ± 18.8s, time of file conversion 250 ± 134.6s, processing time 50.46 ± 21.46 s and 41.97 ± 20.84s, and 3D reconstruction time was 4.29 ± .74 s and 3.89 ± 0.60s for methods B and C, respectively. The mean file size of RAW files is 1010 ± 452 MB and 101.06 ± 38.09 MB for JPG files after conversion. The final image means size is 71.9 ± 0.126 MB, and the 3D model means file size 37.4 ± 0.516 MB using both methods. The equipment used was cheaper than other systems reported.

Photography with Photo-Stacking Technique



Photography showing high-definition structures close the cerebellum

Brain Photography with Photo-Stacking Technique

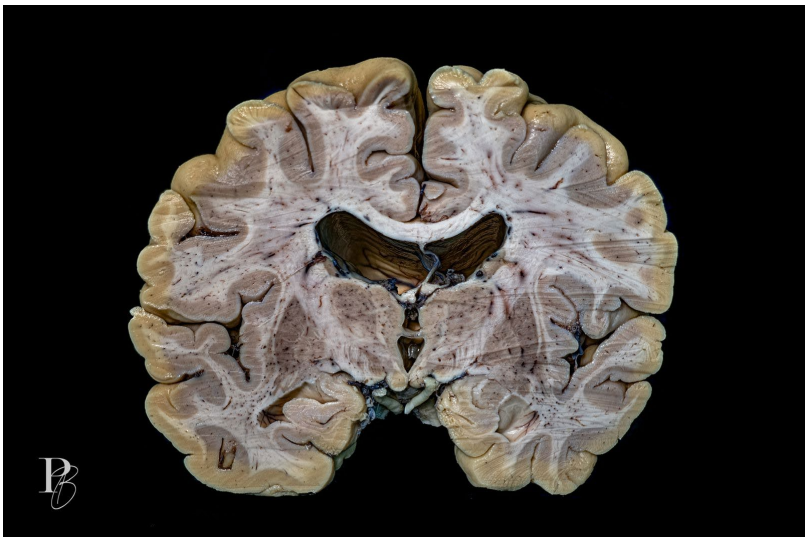

Brain Photography with Photo-Stacking Technique



Conclusions: Photo-stacking is a powerful tool that can enhance medical education and improve patient care. By providing clearer and more detailed visualizations of medical conditions and procedures, it can help medical professionals make better-informed decisions and improve outcomes. Thus, the reported technique is a simple and inexpensive method to create 3D models and high-definition pictures that could prove valuable in neuroanatomy training.

Keywords: Neuroanatomy, Photo-staking, Neurosurgery, 3-D modeling.

OP- IV/35

Surgical approach of management for sciatic nerve injuries: a 10-year experience.

Nursultan Abilkhanov[1], Zhulduz Sadykova[1], Alimkhan Khalimov[1], Yermek Dyussembekov[1]

[1]kazakh national medical university S.D. Asphendiyarov

Objectives: Objective 1: To evaluate surgical approaches and their corresponding curative effects for sciatic nerve injuries.Objective 2: To determine the effectiveness of a two-stage approach for nerve function restoration on extensive sciatic nerve defects.

Background: Sciatic nerve injuries are prevalent and contributing to prolonged disability among working-age individuals. The present study aimed to investigate medical and socioeconomic significance of these injuries.

during the operation



operating process

Method: Our retrospective study was conducted at the Neurosurgery Department of KazNMU with Neurosurgical Center at the City Clinical Hospital 7 Almaty (Kazakhstan). A comparative analysis the surgical treatment of 2 groups with lesions of the sciatic nerve with diastasis more than 5 cm. Surgical treatments were performed in 227 patients from 2013 to 2022. The treatments included neurolysis, nerve repair, nerve autoplasty by nerve graft, tendon-muscle plasty. Compared of the second group from 2003 to 2012 when were performed only reconstructive nerve surgeries.

nerve repair

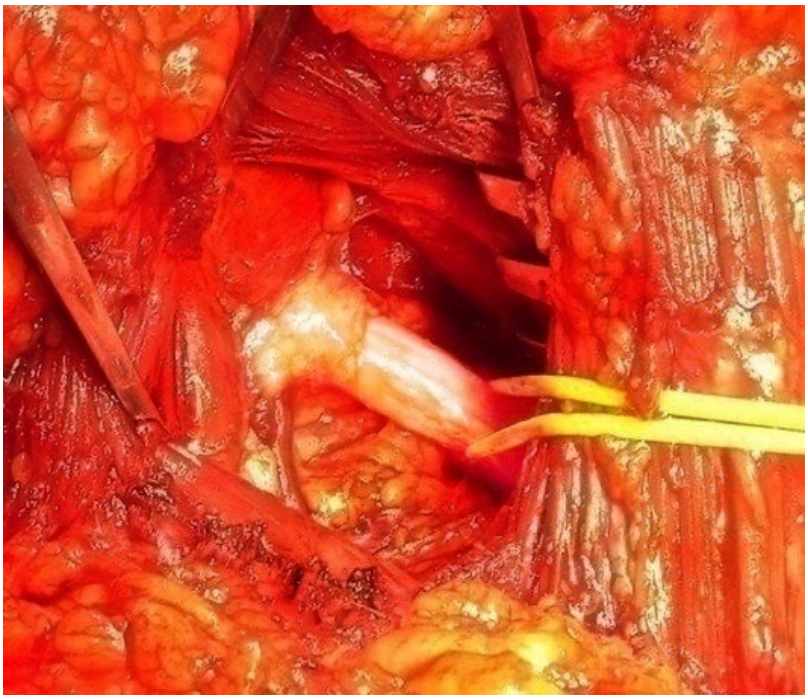

nerve autoplasty by nerve graft (transplant taken from the peroneal nerve)

Distribution of patients by age and sex.

	age				
sex	up to 20 years	20-40 years old	40-60 years old	Over 60 years old	Total
male	13	114	39	5	171
female	2	28	17	9	56
result	15	142	56	14	227

Results: Excellent and good surgical outcomes were 176 (patients) cases, 21 fair, 30 poor. Implementation a two-stage approach of nerve function restoration for patients with nerve diastasis exceeding 5 cm (37 patients) resulted to useful motor function and walking recovery within 2-3 years for 33 cases. Comparatively, previous restorative nerve operations resulted in lower rates of motor recovery 11 patients and walking improvement - 13, with unsatisfactory outcomes – 6.

result of tendon-muscle plasty.



shows an incision for tendon-muscle plasty

Evaluation of the results of surgical interventions on the scale of muscle strength

	degree of muscle strength					
Operation types	0-1	2	3	4	5	total
Autoplasty	4	3	2	12	18	39
Neurolysis	3	4	7	19	15	48
muscle tendon plasty	0	2	3	15	22	42
Nerve suture	1	1	1	4	2	9
Total	8	10	13	50	57	138

Conclusions: Our study highlights the significance of addressing extensive defects to sciatic nerve reconstruction. The two-stage restoration approach, involving tendon-muscle grafting after signs of conductive regeneration in the tibial nerve, leads to useful motor recovery and improved walking ability, ultimately enhancing the patient's quality of life.

Keywords: sciatic nerve, peripheral nerve injuries

References

1- Mathieu L. et al. Defects of the sciatic nerve and its divisions treated by direct suturing in 90 degrees knee flexion: report on the first clinical series. / L. Mathieu,Y. Cloquell, J.C. Murison, G. Pfister, C Gaillard, C Oberlin, Z. Belkheyar. // Eur.J. Trauma Emerg. Surg. – 2022 Dec. – 48(6). – P. 4955-4962
2- Garbuzov A. et al. Advances in lower extremity peripheral nerve surgery. / A.Garbuzov, R. Shekouhi, D.S. H. Nichols, H. Chim. // Plast. and Aesthet. Research.– 2023, 10:9.

OP- IV/37

Percutaneous radiofrequency neurotomy in patients with trigeminal neuralgia associated with multiple sclerosis

Sergey Kondrahov[1]

[1]Clinical Hospital №1 of Department of Presidential Affairs, Moscow, Russia

Objectives: To demonstrate and to evaluate the effectiveness of percutaneous radiofrequency selective neurotomy (PRSN) in treating patients suffering of trigeminal neuralgia associated with multiple sclerosis (NTN and MS).

Background: Multiple sclerosis (MS) is a chronic inflammatory disease central nervous system causing demyelination and degeneration axons. The course of this disease in 1-2% of cases is accompanied by trigeminal neuralgia (TN), which significantly reduces the quality of life of these patients [1].

Method: A retrospective analysis of outcomes 18 patients with TN and MS treated with PRSN in 2017-2022 has been made. 16 patients had typical facial pain, 2 patients had atypical facial pain. Pain intensity and numbness severity in the face were assessed with modern scales on pain intensity and facial numbness severity developed by Barrow Neurological Institute.

The point of insertion of the needle for PRSN.



Correct needle position. Needle end perforated dura mater, CSF enters in drops through the needle.



Lateral fluorogram on the right. The needle is set in projection 3 branches of the trigeminal nerve on the right.

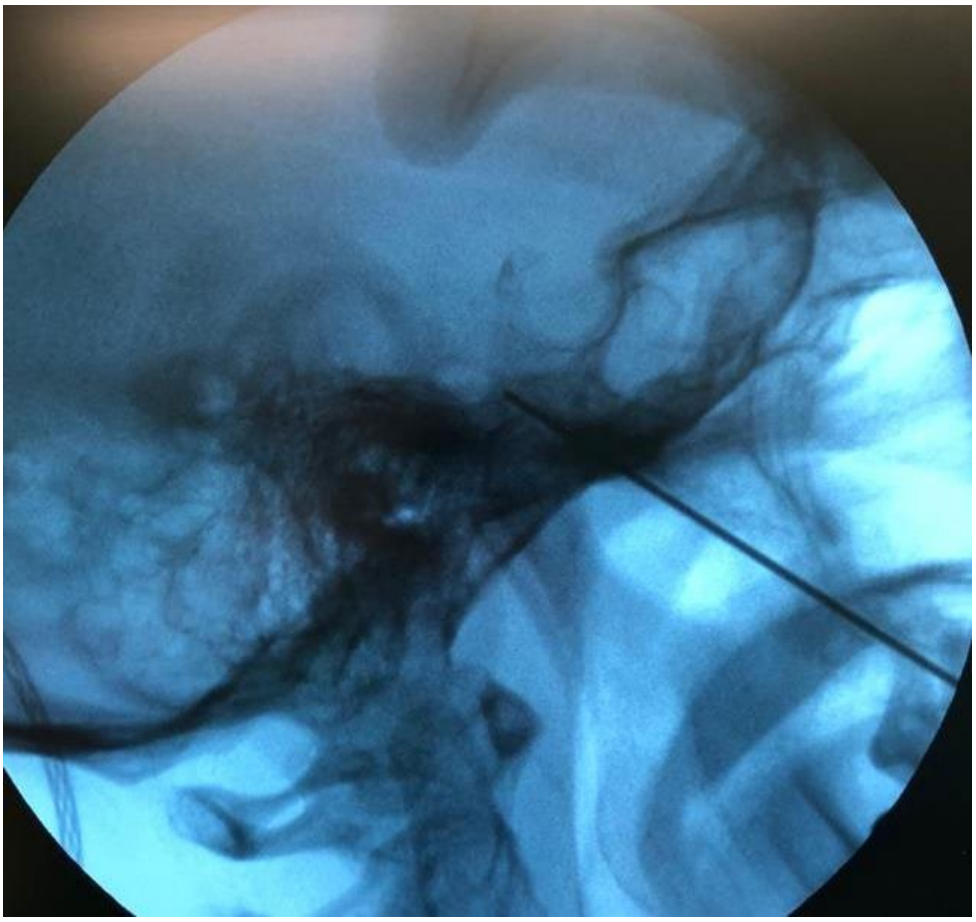

Results: Pain regression (grades I and II by BNI scale) was seen in 15 (83.3%) out of 18 patients with TN and MS. In two patients with atypical facial pain, PRSN treatment was ineffective. After surgery, 13 patients experienced mild numbness that did not bring discomfort and anxiety (class II by BNI scale). 3 patients with persistent pain after the PRSN procedure, sensory disturbances in the face were not determined (class I on the BNIscale). It two cases numbness was observed, causing anxiety and discomfort (class III by BNI scale). Long-term postoperative observation revealed pain relapse in 4 patients (25%). All these patients were successfully treated by the repeated PRSN procedure with a good clinical effect (Grades I and II by BNI scale).

Conclusions: PRSN technique is the method of choice for patient suffering of classical TN and MS since this procedure is effective and safe. PRSN effectiveness in patients with atypical TN and MS is doubtful.

Keywords: trigeminal neuralgia, multiple sclerosis, radiofrequency neurotomy

References

1. Solaro C., Trabucco E., Uccelli M. M. Pain and multiple sclerosis: pathophysiology and treatment //Current neurology and neuroscience reports. – 2013. – Т. 13. – №. 1. – P. 320

OP-III/38

Posterior fossa tumors in children: experience from a national neurosurgical hospital

Iroda Mammadinova[1], Gabit Olenbay[1], Gauhar Ibatova[1], Abay Iskanov[1], Sayagul Abdykarimova[1], Dmitriy Surdin[1], Saparbek Seitbekov[1], Serik Akshulakov[1]

[1]National centre for neurosurgery

Objectives: The aim of this study was to evaluate the prevalence and describe the characteristics of PFTs in children based on the data of the sole pediatric neurosurgical department in the country.

Background: According to the American Cancer Society, brain tumors of the posterior fossa are the second leading cause of death among those younger than 14 y.o. Pilocytic astrocytoma, medulloblastoma, ependymoma, brainstem glioma are the most common histological types of pediatric posterior fossa tumors (PFT). However, no epidemiological data on PFTs is available in Kazakhstan.

Method: A retrospective analysis was conducted at a single national neurosurgery clinic. Two hundred fourteen pediatric patients with PFT, who underwent primary tumor resection between January 1st 2015 and December 31st 2020 were retrospectively reviewed. Demographic data and clinical data, such as tumor histology, extent of tumor resection was collected.

Results: The median age at diagnosis in the sample was 6.9±4.2, 59.8% of patients were male, and 9 children (4.2%) were infant (younger than 1 year of age). Almost all children were symptomatic, and the majority (89.7%) had symptoms of intracranial hypertension and gait disturbance (75.7%). Medulloblastoma (33.28%) and pilocytic astrocytoma (32.7%) were the most common pathologies, followed by ependymoma (15.4%) and diffuse midline glioma (5.1%). Patients underwent primary tumor resection, and the majority had (79%) subtotal resection. After the 5 years of follow-up the mortality rate was 35.1 % for all tumor types: 10% for pilocytic astrocytoma, 57,5% for anaplastic ependymoma and 46,7% for medulloblastoma.

Conclusions: This is the first study to report prevalence of pediatric PFTs in Kazakhstan, and to describe characteristics of the patients. Death rates among children with PFT was comparable with data from other population studies and the impact of the extent of tumor resection and the histological type for lethality has been confirmed.

Keywords: posterior fossa tumor, pediatric tumor, surgery, survival

OP-I/39

The TIGR triangle of the Pineal Region: a Virtual Reality Morphometric Anatomic Study

Mıguel Saez-Alegre Md. Ph.D.[1], Chrıstıan Ríos-Vıcıl Md[1], Ana Sofía Álvarez Md[1], John Sagratı[1], Keaton Pıper Md[1], Walter Jean Md[1]

[1]Department of Neurological Surgery, Lehigh Valley Fleming Department of Neuroscience Institute

Objectives: Describe the TIGR triangle, a deep "key hole" of the pineal region and its application in pineal region surgery.

Background: In this morphometric study, we describe the anatomy of the TIGR triangle, which is bordered by the tentorial surface of the cerebellum, the internal cerebral vein and vein of Galen complex, and the vein of Rosenthal. These structures define the window, or deep keyhole, to access the pineal region in non-midline supracerebellar infratentorial approaches.

Method: The posterior fossa anatomy of 16 patients were studied in Virtual Reality (VR), and the TIGR triangles were defined and measured with special attention on its angular orientation in the posterior fossa. The angular expanse of the posterior fossa was measured and recorded as the transverse-sigmoid junction (TSJ) angle. Because a perpendicular corridor through an anatomic aperture provides the best exposure, we studied the starting point along the TSJ angle that offers the best exposure of TIGR.

TIGR

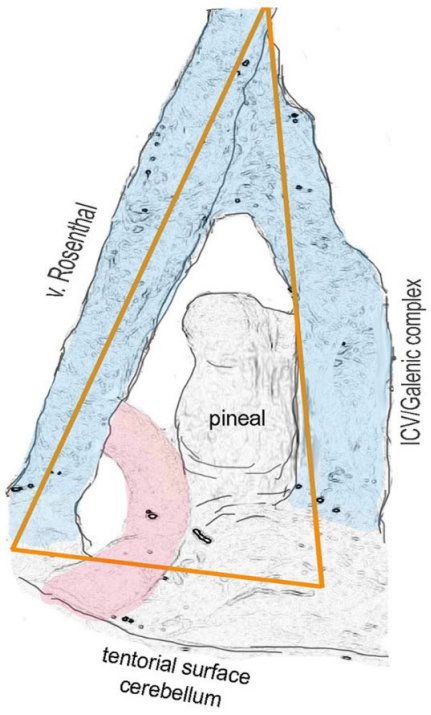

Description of the TIGR triangle

Measurements

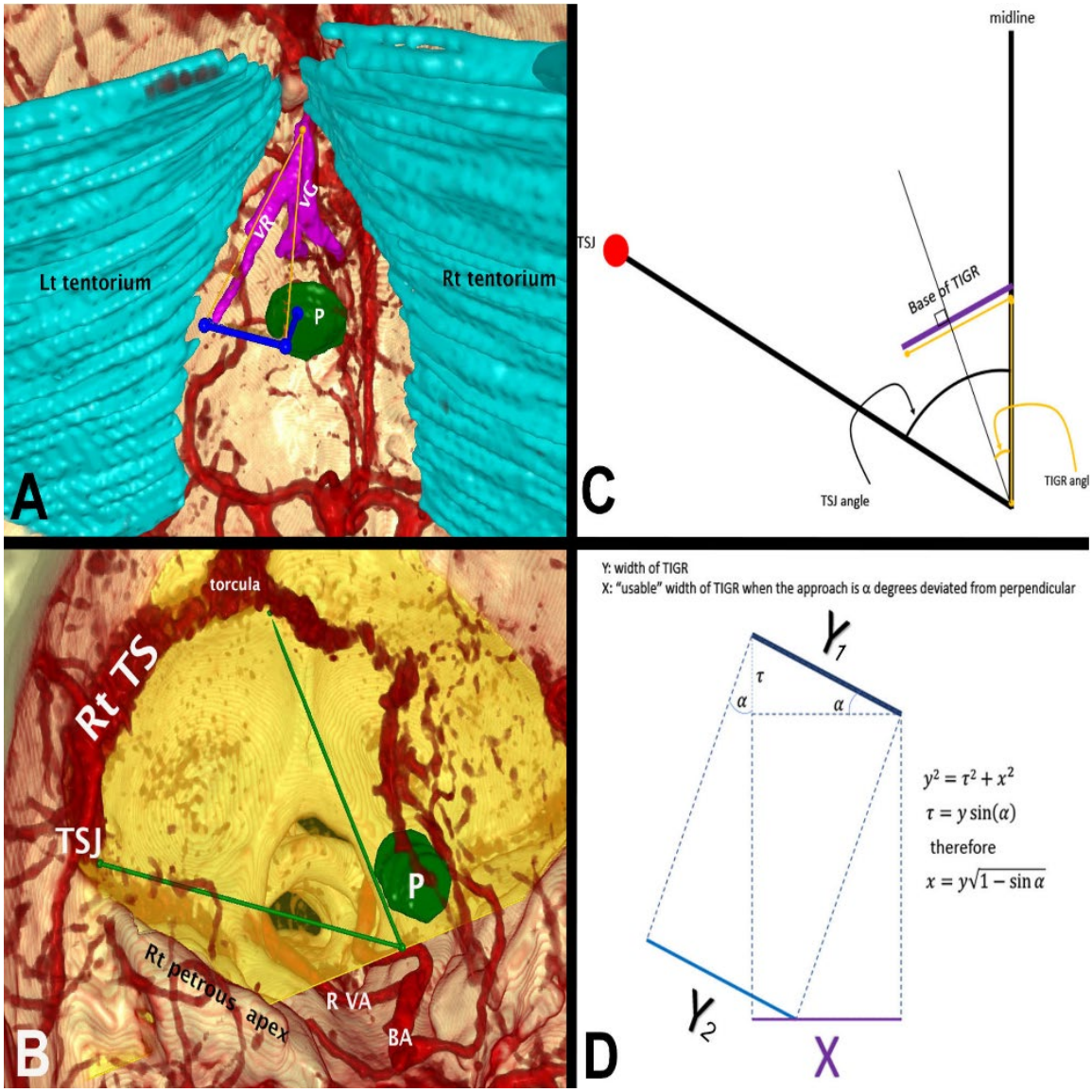

Example of the virtual reality structures and their measurements

Results: In the 31 posterior fossa sides included in the study, the perpendicular trajectory through the TIGR triangle was on average 27.13º CI 95% (range: 5.97º - 48.53º) from the midline. When comparing the SCIT variants, both the paramedian and lateral approaches provided near-perpendicular trajectory through the TIGR triangle in a majority of specimen. However, the modified paramedian approach, with starting point defined as TSJ angle/3, provided the most perpendicular path through the TIGR triangle.

Results

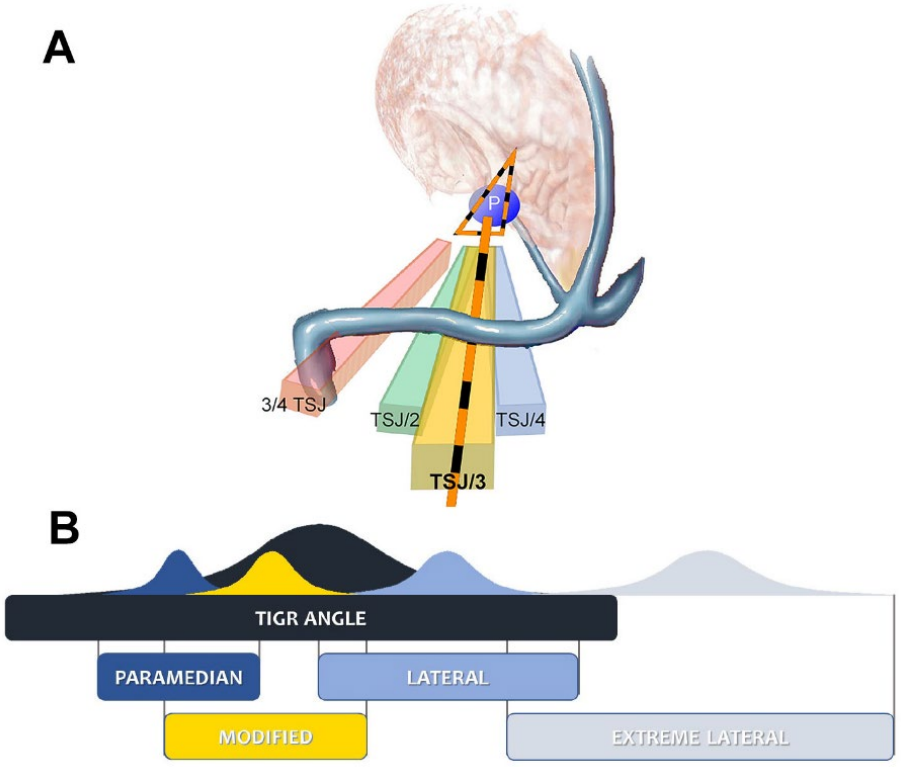

Choice of the best approach based on the perpendicularity to TIGR triangle

Conclusions: We studied the size, spatial orientation and morphology of the TIGR triangle. Our data indicated that the best exposure of TIGR is through a modified paramedian SCIT approach, in which the starting point one third of the way from midline to the transverse-sigmoid junction.

Keywords: pineal, neuroanatomy, virtual reality, skull base

References

1. Ammirati M, Bernardo A, Musumeci A, Bricolo A (2002) Comparison of different infratentorial-supracerebellar approaches to the posterior and middle incisural space: a cadaveric study. J Neurosurg 97(4):922-928. doi:10.3171/jns.2002.97.4.0922
2. Bonney PA, Boettcher LB, Cheema AA, Maurer AJ, Sughrue ME (2015) Operative results of keyhole supracerebellar-infratentorial approach to the pineal region. J Clin Neurosci. 22(7):1105-1110. doi:10.1016/j.jocn.2014.12.029
3. Choque-Velasquez J, Resendiz-Nieves J, Rezai Jahromi B, Colasanti R, Baluszek S, Muhammad S Hernesniemi J (2020) Midline and Paramedian Supracerebellar Infratentorial Approach to The Pineal Region: A Comparative Clinical Study in 112 Patients. World Neurosurg 137: 194-207
4. de Oliveira JG, Lekovic GP, Safavi-Abbasi S, Reis CV, Hanel RA, Porter RW, Preul MC, Spetzler RF (2010) Supracerebellar infratentorial approach to cavernous malformations of the brainstem: surgical variants and clinical experience with 45 patients. Neurosurgery 66(2):389-99. doi: 10.1227/01.NEU.0000363702.67016.5D.

5. de Oliveira Manduca Palmiero H, Solla DJF, Dos Santos LB, Teixeira MJ, Figueiredo EG (2020) Anatomic, qualitative, and quantitative evaluation of the variants of the infratentorial supracerebellar approach to the posteroinferior thalamus. Neurosurg Rev. 44(4):2309-2318. doi: 10.1007/s10143-020-01405-0
6. Fain JS, Tomlinson FH, Scheithauer BW, Parisi JE, Fletcher G P, Kelly PJ, Miller GM (1994) Symptomatic glial cysts of the pineal gland, Journal of Neurosurgery, *80*(3), 454-460.
7. Fleck S, Damaty AE, Lange I, Matthes M, Rafaee EE, Marx S, Baldauf J, Schroeder HWS (2022) Pineal cysts without hydrocephalus: microsurgical resection via an infratentorial-supracerebellar approach-surgical strategies, complications, and their avoidance. Neurosurg Rev. 45(5):3327-3337. doi: 10.1007/s10143-022-01831-2
8. Giordano M, Lüdemann WO, Stieglitz L, Gerganov VM, Columbano L, Samii A, Samii M (2011) Identification of venous variants in the pineal region with three-dimensional preoperative magnetic resonance imaging navigation in patients harbouring tumors in this area: significance for surgical approach to the lesion. Clin Neurol Neurosurg. 113(5):387-92. doi: 10.1016/j.clineuro.2010.12.019
9. Gu Y, Zhou Q, Zhu W, Wu Q, Xie T, Wu S, Hu F, Yu Y, Sun C, Li C, Zhang B, Zhan L, Zhang X. (2019) The Purely Endoscopic Supracerebellar Infratentorial Approach for Resecting Pineal Region Tumors with Preservation of Cerebellomesencephalic Vein: Technical Note and Preliminary Clinical Outcomes. World Neurosurg. 128:e334-e339. doi: 10.1016/j.wneu.2019.04.146
10. Jean WC, Tai AX, Hogan E, Herur-Raman A, Felbaum DR, Leonardo J, Syed HR (2019) An anatomical study of the foramen of Monro: implications in management of pineal tumors presenting with hydrocephalus. Acta Neurochir (Wien) 161(5):975-983. doi: 10.1007/s00701-019-03887-4
11. Krause F, Haubold HA, Thorek M (1912) Surgery of the Brain and Spinal Cord: Based on Personal Experiences. In: Krause, F. Surgery of the Brain and Spinal Cord Based on Personal Experience. Trans. Rebman, New York, NY
12. Quest DO, Kleriga E (1980) Microsurgical anatomy of the pineal region. Neurosurgery 6(4):385-390. doi:10.1227/00006123-198004000-00006
13. Ringertz N, Nordenstam H, Flyger G (1954) Tumors of the pineal region. J Neuropathol Exp Neurol.13(4):540-561. doi:10.1097/00005072-195410000-00004
14. Syed HR, Jean WC (2018) A Novel Method to Measure the Tentorial Angle and the Implications on Surgeries of the Pineal Region. World Neurosurg. 111:e213-e220. doi: 10.1016/j.wneu.2017.12.037
15. Tai AX, Herur-Raman A, Jean WC (2020) The Benefits of Progressive Occipital Condylectomy in Enhancing the Far Lateral Approach to the Foramen Magnum. *World Neurosurg*. 134:e144-e152. doi:10.1016/j.wneu.2019.09.152
16. Tai AX, Srivastava A, Herur-Raman A, Cheng Wong PJ, Jean WC (2021) Progressive Orbitotomy and Graduated Expansion of the Supraorbital Keyhole: A Comparison with Alternative Minimally Invasive Approaches to the Paraclinoid Region. *World Neurosurg*. 146:e1335-e1344. doi:10.1016/j.wneu.2020.11.173
17. Xie T, Qu C, Zhang X, Yang Q, Yeh Y, Li C, Liu T, Liu S, Li Z, Hu F, Yang L, Yang H (2022) Endoscopic Midline and Paramedian Supracerebellar Infratentorial Approaches to Pineal Region Tumors: A Clinical Study and Approach Comparison. World Neurosurg. 168:63-73. doi: 10.1016/j.wneu.2022.09.074
18. Zaidi HA, Elhadi AM, Lei T, Preul MC, Little AS, Nakaji P (2015) Minimally Invasive Endoscopic Supracerebellar-Infratentorial Surgery of the Pineal Region: Anatomical Comparison of Four Variant Approaches. *World Neurosurg*. 84(2):257-266. doi:10.1016/j.wneu.2015.03.009

OP-I/40

Classification of Brain Tumors and Differentiation of Tumor Borders from Normal Tissue Through Deep Learning Technique Applied Over MR and Microscopic Images Taken During Surgeries

Efecan Cekic[1], Ertuğrul Pınar[2], Merve Pınar[4], Adnan Dağçınar[3]

[1]Polatlı Duatepe State Hospital,Department of Neurosurgery,Ankara,Turkey
[2]Private Pendik Yuzyil Hospital,Department of Neurosurgery, Istanbul, Turkey
[3]Marmara University Hospital, Department of Neurosurgery, Istanbul, Turkey
[4]Marmara University,Department of Computer Engineering, Istanbul, Turkey

Objectives: Distinguishing tumor borders(1) and making pathological predictions(2) with the artificial intelligence deep learning software by using operational and MRI images in 3 tumor types.

Background: Most common brain tumors are metastases,meningiomas, and gliomas(1).Radiological images guide physicians to diagnosis (2).Type of tumor is determined by pathological examination.Removing the tumor without damaging the normal tissue is the fundamental surgery purpose(3)(4).To reduce damaging normal tissues during surgery,new technologies are needed(5).In this study, the classification of tumor types and distinguishing borders is estimated separately and hybrid by deep learning software using the surgical video images and patient's MRI images.By this way we want to achieve intraoperative histopathological diagnosis of the tumor, modify the surgery according to it and increase amount of tumor resection with maximum safety.

Method: Dataset was created with videos recorded by a surgical microscope and MRI images of patients.Images were labeled with VGG Image Annotator(Oxford University).Mask R-CNN was used as algorithm.Classification and border prediction were studied together.Precision, recall, DICE, and JAC indexes are used as evaluation metrics.Surgical microscope dataset was divided into 3: training (2436 (73%)), validation(463 (14%)),test set(424 (13%)).MRI dataset was divided into 2: training (2400 (85.2%)) and test sets (420 (14.8%)).

Figure 1

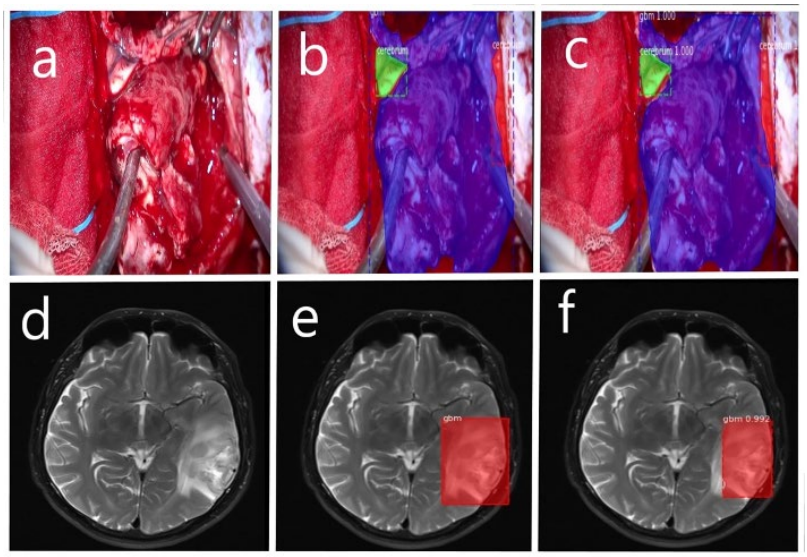

Original, marked, and algorithm-determined images of high-grade glial tumor in MR and microscope images (a) original microscope image (b) marked microscope image (c) image determined by deep learning algorithm on microscope image (d) original MR image (e) marked MR image (f) image determined by the deep learning algorithm on the MR image in the test set

Figure 2

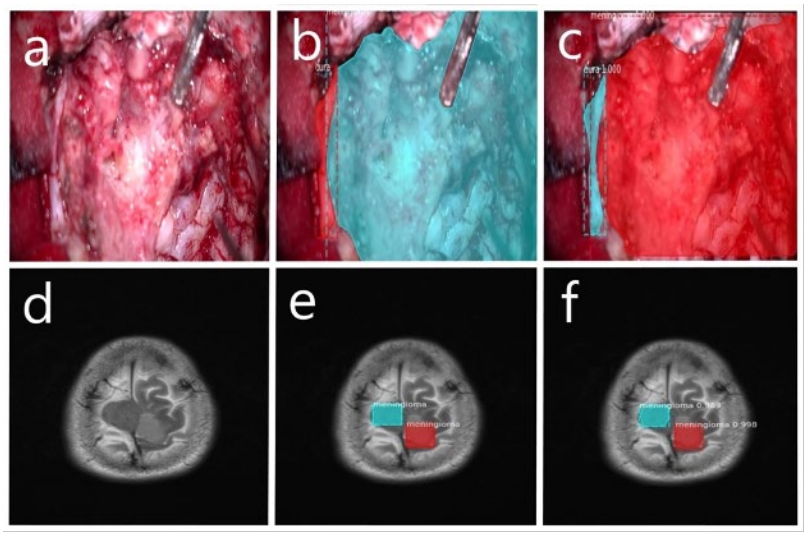

The original, marked images of the meningioma tumor in the MR and microscope images and the images determined by the algorithm in the test set (a) the original microscope image (b) the marked microscope image (c) the image determined by the deep learning algorithm on the microscope image (d) the original MR image (e) marked MR image (f) image determined by the deep learning algorithm on the MR image in the test set

Figure 3

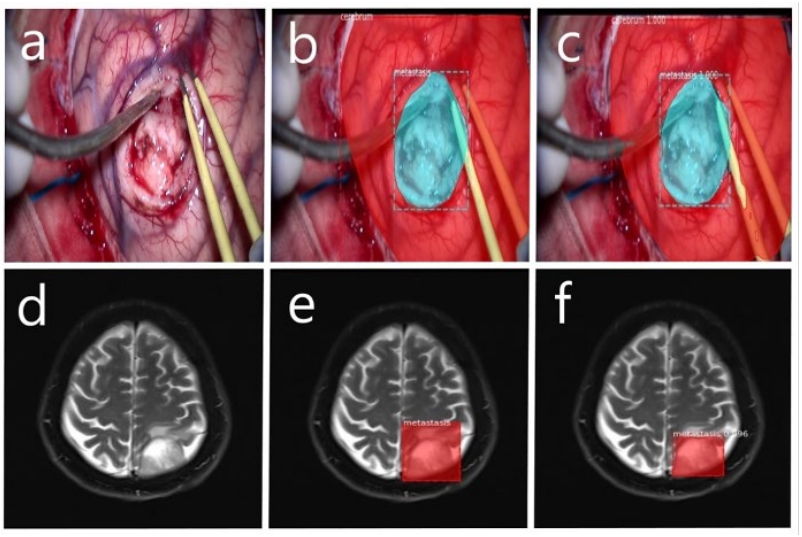

The original, marked images of the metastasis tumor in the MR and microscope images, determined by the algorithm in the test set (a) the original microscope image (b) the marked microscope image (c) the image determined by the deep learning algorithm on the microscope image (d) the original MR image (e) the marked MR image (f) is the image that the deep learning algorithm determines on the MR image in the test set.

Results: DICE score results were 94-95% in the validation set,JAC scores were 89-91%.Validation set reached 96-98% accuracy in pathological prediction(Table 1).In test set, the JAC scores were 69-76% and the DICE scores were 72-81%(Table 2).In pathology prediction, the algorithm reached 83-85% accuracy.Prediction of the pathology type in MRI images was 90-93% on test set.Accuracy rates in the microscope test set were increased to range of 93-96% using algorithm hybrid with both datasets(Table3). The results were calculated based on the pathology results.

Table 1

Validation Set	JAC	DİCE	Pathology Precision
High Grade Glial Tumor	%91	%95	%96
Meningioma	%89	%94	%98
Metastasis	%91	%95	%95

Prediction results in the validation set of borders and pathology of tumor tissues in microscope images

Table 2

Test set	JAC	DİCE	Pathology Precision
High Grade Glial Tumor	%69	%72	%83
Meningioma	%74	%79	%85
Metastasis	%76	%81	%84

Prediction results in the test set of borders and pathology of tumor tissues in microscope images

Table 3

Pathology Precision (Test Set)	MR İmages	Microscope Images	Hybrid Results
High-Grade Glial Tumor	%91	%83	%94
Meningioma	%93	%85	%96
Metastasis	%90	%84	%93

Deep learning algorithm pathology prediction in MR images, microscope images, and hybrid results

Conclusions: Deep learning algorithms are successful both in terms of border and pathological type prediction using microscope and MRI images.Integrated operation with augmented reality and neuronavigation may contribute to robotic surgery.

Keywords: artificial intelligence, deep learning, surgical microscope, MRI images

References

1. McFaline-Figueroa JR, Lee EQ. Brain Tumors. Am J Med. 2018 Aug;131(8):874–82.
2. Jaju A, Yeom KW, Ryan ME. MR Imaging of Pediatric Brain Tumors. Diagnostics. 2022 Apr 12;12(4):961.
3. Hollon T, Stummer W, Orringer D, Suero Molina E. Surgical Adjuncts to Increase the Extent of Resection. Neurosurg Clin N Am. 2019 Jan;30(1):65–74.
4. Fountain DM, Bryant A, Barone DG, Waqar M, Hart MG, Bulbeck H, et al. Intraoperative imaging technology to maximise extent of resection for glioma: a network meta-analysis. Cochrane Database of Systematic Reviews. 2021 Jan 4;2021(1).
5. Kiesel B, Freund J, Reichert D, Wadiura L, Erkkilae MT, Woehrer A, et al. 5-ALA in Suspected Low-Grade Gliomas: Current Role, Limitations, and New Approaches. Front Oncol. 2021 Jul 30;11.

OP-V/41

A Minimal Invasive Approach For T12-L1 Level Intradural Lesions

Yunus Emre Ozbilgi[1], İrem Nur ALTUN[1], Muhammed Emin AKSU[1], Mehmet Sabri GÜRBÜZ[1]

[1]Istanbul Medeniyet University

Objectives: To present two cases of intradural extramedullary tumors at T12-L1 level that were operated on via partial hemilaminotomy. This minimally invasive approach was chosen to avoid instability and/or an additional surgery for stabilization.

Background: Spinal Intradural tumors are accessed via laminectomy, laminoplasty or hemilaminotomy. Although laminectomy doesn't neccessarily cause instability, it is not the case when the tumor is at T12-L1 level. Thoracolumbar junction is the transition area between the fixed thoracal spine and relatively mobile lumbar spine. Any degenerative process, fracture or laminectomy make this region very prone to developing instability. For this reason, laminectomy or laminoplasty can easily cause instability at T12-L1 level.

Method: The first case was a 35-years old male having schwannoma and the second case was a 75 years old female having meningioma at T12-L1 level. Both patients underwent surgery via unilateral partial hemilaminotomy in prone position under neuromonitoring. After midline skin incision and regular partial hemilaminotomy, the patient was rotated towards the contraleteral site almost 30 degrees. Then, high speed drill was used for drilling the bone underneath the spinous process. This step improved the exposure of the whole dorsal spinal dura. After the dura and arachnoid were incised and retracted laterally, the tumor was easily exposed. The tumors were explored and removed with the well-known microneurosurgical principles.

Postoperative CT scan



Sagittal (A) and axial (B) Thoracolumbar CT shows Unilateral Partial Hemilaminectomy.

Results: Gross-total removal of the tumor was achieved in both patients. Both patients were mobilized on postoperative first day. Both patients were discharged on the third postoperative days without any neurological deficit. At the 6th and 3rd months of follow-up respectively, no sign of instability was observed.

pre and post operative MRI scans of schwannoma

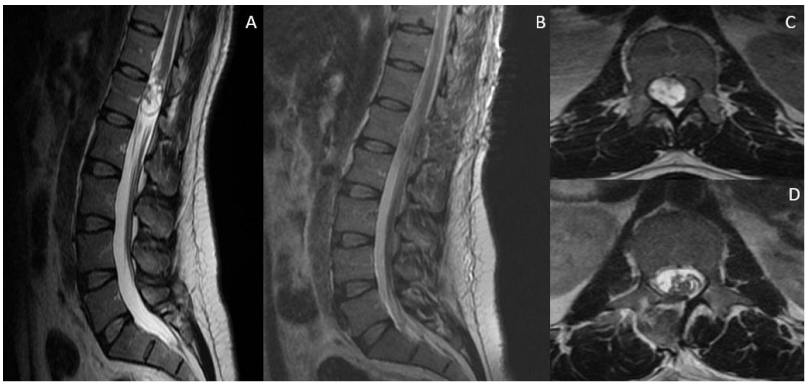

Preoperative sagital and axial (A,C) MRI scans show intradural extramedullary schwannoma. Postoperative sagital and axial (B,D) MRI scans show gross total removal of the lesion.

MRI scans of meningioma

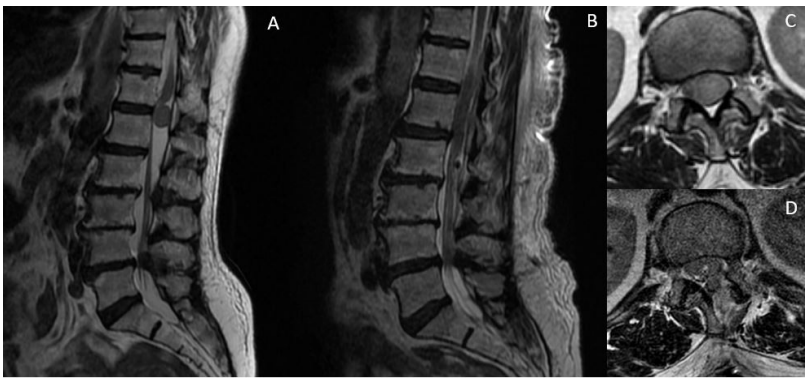

Preoperative sagital and axial (A,C) MRI scans show intradural extramedullary meningioma. Postoperative sagital and axial (B,D) MRI scans show gross total removal of the lesion.

Conclusions: Unilateral hemilaminotomy technique is a safe minimal invasive technique for removal of intradural extramedullary tumors. This technique, particularly at the level of T12-L1, helps avoid instability and additional surgery.

Keywords: Minimal İnvasive, Intradural Extramedullary, Unilateral Partial Hemi-Laminectomy

References

1. Yaşargil MG, Tranmer BI, Adamson TE, Roth P. Unilateral partial hemi-laminectomy for the removal of extra- and intramedullary tumours and AVMs. Adv Tech Stand Neurosurg. 1991;18:113-32.--
2. Boström A, Burgel U, Reinacher P. A less invasive surgical concept for the resection of spinal meningiomas. Acta Neurochir. 2008;150(6):551–556.
3. Eggert HR, Scheremet R, Seeger W, Gaitzsch J. Unilateral microsurgical approaches to extramedullary spinal tumors. Operative technique and results. Acta Neurochir. 1983;67(3-4):245–253
4. Sun CX, Meng XL, Xie SN, Yu Y, Yang HJ, Wu B. Unilateral hemilaminectomy for patients with intradural extramedullary tumors. J Zhejiang Univ Sci B. 2011 Jul;12(7):575-81

OP-I/43

The Venous Circle of Trolard: An Anatomical Study with Application to Approaches to the Basal Brain

Juan J. Cardona[1], William H. Eskew[1], Arada Chaiyamoon[2], Ana Carrera[3], Francisco Reina[3], Yücel Doğruel[4], Abuzer Güngör[5], Joe Iwanaga[1], Aaron S. Dumont[1], R. Shane Tubbs[1]

[1]Department of Neurosurgery, Tulane University School of Medicine, New Orleans, Louisiana, USA
[2]Department of Anatomy, Faculty of Medicine, Khon Kaen University, Khon Kaen, Thailand
[3]Department of Medical Sciences, Clinical Anatomy, Embryology and Neurosciences Research Group, University of Girona, Girona, Spain
[4]Department of Neurosurgery, Microsurgical Neuroanatomy Laboratory, Yeditepe University School of Medicine, Istanbul, Turkey
[5]Department of Neurosurgery, University of Health Sciences, Bakirkoy Research and Training Hospital for Neurology, Neurosurgery and Psychiatry, Istanbul, Turkey

Objectives: To evaluate in detail the anatomy of the circle of Trolard.

Background: The arterial circle of Willis is a well-known and interconnecting set of blood vessels at the base of the brain. Nevertheless, its lesser-known venous counterpart, the circle of Trolard, an anastomosis of the deep venous system at the base of the skull, has had almost no attention in the extant medical literature.

The venous circle of Trolard

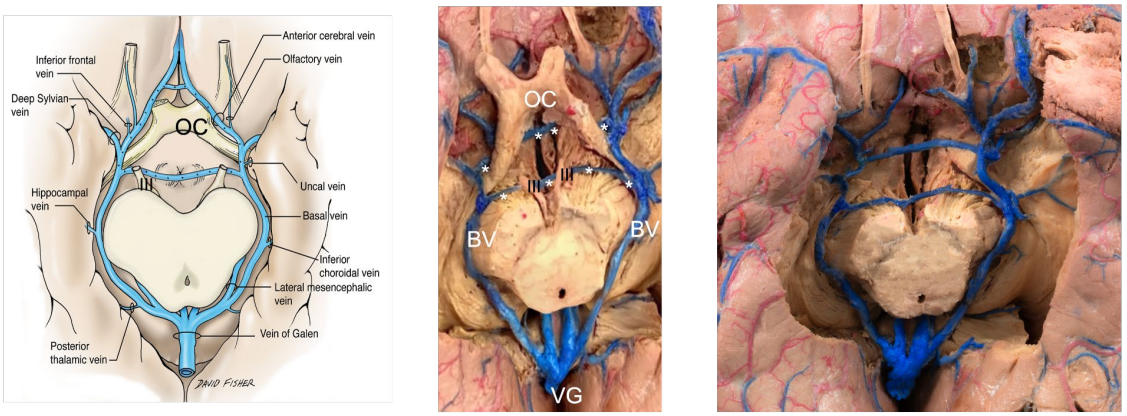

Left: Schematic drawing of the major veins seen at the base of the brain. Note the circle of Trolard (*) formed anteriorly by the anterior communicating vein and posteriorly by the posterior communicating vein. OC=optic chiasm. Middle: Latex injected cadaveric brain noting the circle of Trolard (*). Also note the optic chiasm (OC), basal veins of Rosenthal (BV), vein of Galen (VG), and oculomotor nerves (III). Right: The middle image following removal of the optic nerves, chiasm and tracts in order to best view the entire circle of Trolard.

Method: Twenty-four adult human brains underwent dissection of the circle of Trolard. When identified, its component vessels and relationships with adjacent structures were confirmed and

documented with photography and measured using microcalipers. Dissections of the base of the brain were carried out using a surgical microscope.

Sequential cadaveric dissections to expose the circle of Trolard

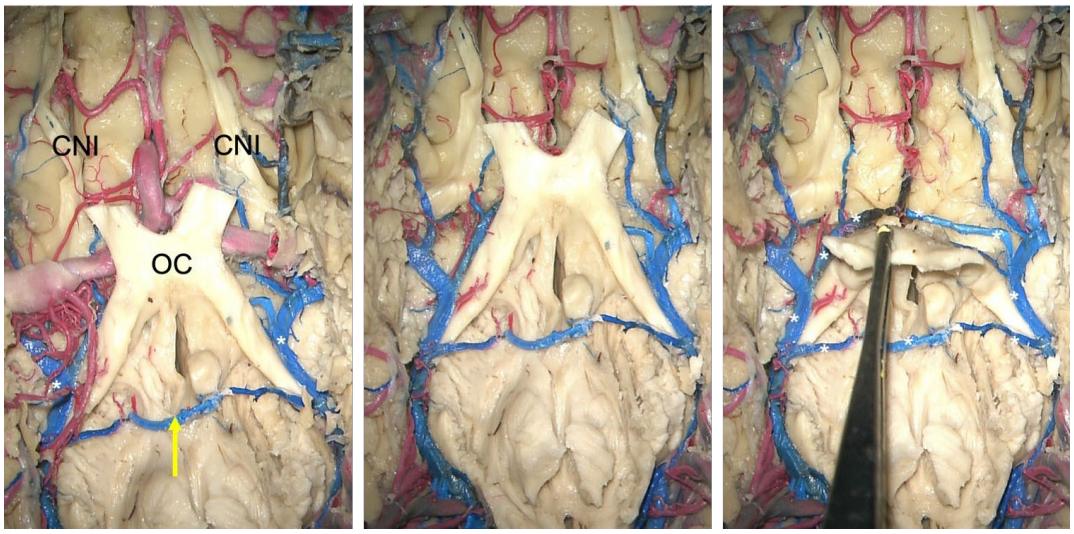

Left: The left and right basal veins of Rosenthal are seen at the * and the posterior communicating vein at the yellow arrow. Note the olfactory tract (CNI) and optic chiasm (OC). Middle: The surrounding arteries have been removed. Right: the optic chiasm is reflected so that the entirety of the circle of Trolard (*) can be seen.

Results: A complete circle of Trolard was identified on 42% of specimens. Most (64%) incomplete circles were incomplete anteriorly with no anterior communicating vein. The anterior communicating veins joined the anterior cerebral veins superior to the optic chiasm and continued posteriorly. The anterior communicating veins had a mean diameter of 0.45 mm. The length of these veins ranged from 0.8 mm to 1.45 mm. Thirty-six percent of circles were incomplete posteriorly with lack of a posterior communicating vein. The posterior communicating veins were always larger and longer than the anterior cerebral veins. The posterior communicating veins had a mean diameter of 0.8 mm. The length of these veins ranged from 2.8 to 3.9 cm. In general, the circles of Trolard were more or less symmetrical. However, in 2 specimens, asymmetry existed.

Asymmetrical circle of Trolard

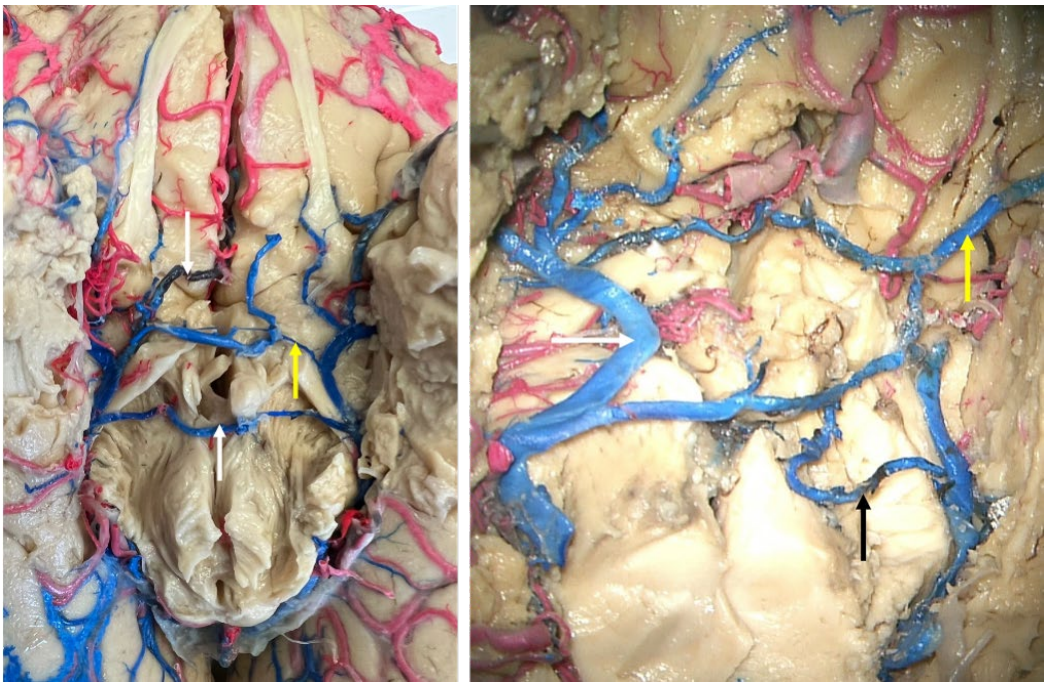

Left: Asymmetrical circle of Trolard with a right sided azygos anterior cerebral vein (upper white arrow). In this specimen, the anterior communicating vein connects the azygos anterior cerebral vein directly to the left sided basal vein of Rosenthal via a small, tapered vein (yellow arrow). A large left inferior frontal vein drains into the anterior communicating vein. Right: Asymmetrical circle of Trolard with a much larger right sided basal vein of Rosenthal (white arrow). Also note the left sided basal vein of Rosenthal has an additional communicating vein (black vein) that joins the posterior communicating vein. For reference, note the left Sylvian vein (yellow arrow).

Conclusions: Ultimately, there is a relative dearth of knowledge about the circle of Trolard and its detailed anatomy. A better understanding of this venous structure might decrease iatrogenic injury during approaches to the base of the brain and improve diagnoses based on imaging of the skull base. To our knowledge, this is the first anatomical study dedicated to the circle of Trolard.

Keywords: Circle of Trolard, Circle of Willis, Neurosurgery, Skull base

References

1. Roostaei T, Nazeri A, Sahraian MA, Minagar A. The human cerebellum: a review of physiologic neuroanatomy. Neurol Clin. 2014;32:859-69. https://doi.org/10.1016/j.ncl.2014.07.013
2. Moini J, Avgeropoulos NG, Samsam M. Epidemiology of brain and spinal tumors. *Anatomy and Physiology*. Elsevier;2021:3-40. https://doi.org/10.1016/C2019-0-03764-8
3. Stopford JSB. The Arteries of the pons and medulla oblongata. J Anat Physiol. 1916;50:131–164.
4. Liu Y, Zhu L, Hou B, et al. Study on the correlation between the circle of Willis structure and collateral circulation in bilateral carotid artery occlusion. Neurol Sci. 2021;42:5335-5342. https://doi.org/10.1007/s10072-021-05265-4
5. Komiyama M. Functional venous anatomy of the brain for neurosurgeons. Jpn J Neurosurg (Tokyo). 2017;26:488-49 https://doi.org/10.7887/jcns.26.488
6. Grand W, Hopkins LN. Vasculature of the brain and cranial base variations in clinical anatomy. 1st ed. New York, NY: Thieme; 1999.
7. Huang YP, Wolf BS. The basal cerebral vein and its tributaries. In: Newton TH, Poos DG, eds. *Radiology of the Skull and Brain*. St. Louis, Mo: Mosby; 1974;2111-2154.
8. Johanson C. The central veins and deep dural sinuses of the brain; an anatomical and angiographic study. Acta Radiol Suppl. 1954;107:8-184.
9. Duvernoy HM. The superficial veins of the human brain: veins of the brain stem and of the base of the brain. Heidelberg, Berlin: Springer; 1975. https://doi.org/10.1007/978-3-642-65929-4
10. Lavin PJ, McCrary JA 3rd, Roessmann U, Ellenberger C Jr. Chiasmal apoplexy: hemorrhage from a cryptic vascular malformation in the optic chiasm. Neurology. 1984;34:1007- https://doi.org/10.1212/wnl.34.8.1007
11. Regli L, de Tribolet N, Regli F, Bogousslavsky J. Chiasmal apoplexy: haemorrhage from a cavernous malformation in the optic chiasm. J Neurol Neurosurg Psychiatry. 1989;52:1095-9. https://doi.org/10.1136/jnnp.52.9.1095
12. Mukerji N, Cahill J, Tzerakis N, Nath FP, Dervin JE. Venous anastomotic circle, multiple varices and oculomotor palsy--a rare coincidence. Acta Neurochir (Wien). 2010;152:2205-9. https://doi.org/10.1007/s00701-010-0819-y
13. Tanaka K, Suesada N, Homma T, Mori H, Okazaki M. Reliability of temporal vascular anastomosis and techniques for better outcomes. J Reconstr Microsurg. 2022;38:41-46. https://doi.org/10.1055/s-0041-1729883
14. Cullen S, Demengie F, Ozanne A, et al. The anatomic venous circle of the base of the brain. Interv Neuroradiol. 2005;11:325-332. https://doi.org/10.1177/159101990501100404
15. Iwanaga J, Singh V, Ohtsuka A, et al. Acknowledging the use of human cadaveric tissues in research papers: recommendations from anatomical journal editors. Clin Anat. 2021;34:2-4. https://doi.org/10.1002/ca.23671

OP-I/44

Relationship between oral and intestinal bacteria and the onset of subarachnoid hemorrhage: SAH-FLORA study

Akio Morita[1], Fumihiro Matano[2], Yasuo Murai[2]

[1]Treraoka Memorital Hospital
[2]Nippon Medical School

Objectives: To clarify the relation ship between microbiota and subarachnoid hemorrahge.

Background: Influence of oral and/or intestinal bacteria with the origin of cerebral aneurysm and its rupture have been recently interested. To clarify the relation with bacteria and subarachnoid hemorrhage, we are now conducting prospective multi-center study creating biobank and analysis.

Method: We collected clinical data including food habits, saliva, stool and blood specimen of 175 cases(Subarachnoid hemorrhage:86, unruptured intracranial aneurysm:59, and reference (no history of stroke): 30cases). From saliva specimen, we cultured periodontoid bacteria and checked the incidence of cnm+ Streptcoccus Mutans, which is previously reported to be related with hemorrhagic cerebrovascular disease. For stool specimen, we have extracted DNA and analyzed bacteria using 16sRNA method and RDB, and DB (Technosuruga Co., Japan) library.

Results: We have cultured saliva of 171cases and found positive cnm+ Streptcoccus Mutans strain in 18 cases out of 74 positive S. Mutans cultures(24.3%). There was no difference in the positive rate between types of specimen. Stool flora analysis was done in 119 (SAH 68, UCA:29, REF:22) cases, and stool specimen from SAH patients showed dominancy of Prevotella intermedia, Peptacetobacter hiranonis, Corynebacterium mycetoides, Aggregatibacter segnis and Gemella asaccharolytica.

Conclusions: We could not find difference in the positive culture rate of cnm+ S. Mutans between types of specimen. Some organisms specially found from stool specimen of SAH patients were reported to be responsible for infections endocarditis. Relationship between stool bacteria and onset of subarachnoid hemorrhage is yet to be clarified including blood bioproduct analysis. Also at the same time, we are trying to find difference of oral and stool flora between European and Japanese population, where incidence of subarachnoid hemorrhage is 3times higher.

Keywords: Subarachnoid hemorrhage, Microbiota, cerebral aneurysms, intestinal bacteria

References

1. Greving JP, Wermer MJ, Brown RD Jr, Morita A, et al.: Development of the PHASES score for prediction of risk of rupture of intracranial aneurysms: a pooled analysis of six prospective cohort studies. **Lancet Neurol.** 2014 Jan;13（1）:59-66.

OP- V/45

Clinical outcomes in parasagittal meningiomas

Abdul Basit Khan[1], Collin English[1], Akash J Patel[1]

[1]Baylor College of Medicine

Objectives: Identify how sinus occlusion in parasagittal meningiomas contributes to morbidity and to intraoperative risk.

Background: Parasagittal meningiomas, filling the angle along the superior sagittal sinus (SSS), represent a devastating subset of meningioma[1]. Occlusion of the SSS can potentially increase the risk of complications and morbidity, however further research is needed.

Table

	Overall, N = 34[1]	**Occlusion**, N = 12[1]	**Patent**, N = 22[1]	**p-value**[2]
Pre-Operative Data				
Functional Neurological Deficit	21 / 34 (62%)	6 / 12 (50%)	15 / 22 (68%)	0.5
Pre-operative KPS	80 (80, 90)	80 (75, 90)	80 (80, 90)	0.6
Intraoperative Data				
Level of Resection				0.036
GTR	20 / 34 (59%)	4 / 12 (33%)	16 / 22 (73%)	
STR	14 / 34 (41%)	8 / 12 (67%)	6 / 22 (27%)	
Estimated Blood Loss (mL)	250 (100, 400)	550 (288, 1,000)	150 (100, 250)	<0.001
Histology				
WHO Grade				>0.9
Grade I	26 / 34 (76%)	9 / 12 (75%)	17 / 22 (77%)	
Grade II	8 / 34 (24%)	3 / 12 (25%)	5 / 22 (23%)	
MIB Index (%)	5.7 (2.9, 10.1)	6.6 (3.7, 15.0)	4.7 (2.6, 8.9)	0.4
Follow Up				
FND Change from Preoperative				0.014
Improved/Stable	15 / 20 (75%)	2 / 6 (33%)	13 / 14 (93%)	
Worsened	5 / 20 (25%)	4 / 6 (67%)	1 / 14 (7.1%)	
KPS Change from Preoperative				0.018
Improved/Stable	26 / 32 (81%)	7 / 12 (58%)	19 / 20 (95%)	
Worsened	6 / 32 (19%)	5 / 12 (42%)	1 / 20 (5.0%)	

[1] n / N (%); Median (IQR)

[2] Fisher's exact test; Wilcoxon rank sum test

Method: An institutional database of 330 meningiomas was reviewed for parasagittal tumors. Pre-operative MRI scans were assessed by a blinded neuroradiologist who graded SSS invasion. Clinical data were obtained from the electronic medical record.

Results: A total of 34 parasagittal tumors were identified, with 17/34 (50%) male patients and a median follow up time of 16 months. In this cohort, 12/33 (35%) showed sinus occlusion on pre-operative imaging. On presentation, patients with and without occlusion had similar rates of neurological deficits (6/12 vs. 15/22, p=0.5) and similar Karnofsky Performance Status (KPS) scores (median 80 vs. 80, p=0.6). Patients with SSS occlusion had lower rates of gross total resection (4/12 vs 16/22. p=.036) and higher estimated blood loss (median 550 mL vs 150 mL, p<.001). Histologically, occluding and non-occluding meningiomas showed similar WHO grading (p>.9) and MIB indexes (median 6.7% vs. 4.4%, p=.4). At last follow up, patients who presented with focal neurological deficits had worsened deficits if the sinus was occluded (4/6 vs. 1/14, p=.014), and patients with occlusion were more likely to have a worsened KPS from their pre-operative score (5/12 vs. 1/20, p=.018).

Conclusions: Parasagittal tumors with SSS occlusion present with similar levels of neurological deficits and impairment. However, patients with SSS occlusion have higher rates of intraoperative blood loss and poorer long-term outcomes – indicating that occlusion of the sinus represents an important prognostic factor.

Keywords: parasagittal, meningiomas

References

1. Pettersson-Segerlind, J., et al., *Long-term 25-year follow-up of surgically treated parasagittal meningiomas.* World Neurosurg, 2011. **76**(6): p. 564-71.

OP- V/46

Investigation of the relationship of demographic characteristics of patients and morphometric characteristics of AVMs with treatment approaches and supplemented Spetzler-Martin scores, a single-center study

Emre Çavuş[1], Çağhan Tönge[1], Ömer Selçuk Şahin[1], Mehmet Erhan Türkoğlu[1]

[1]Etlik City Hospital Neurosurgery Clinic

Objectives: In this study, aim was to investigate the effects of treatment modalities and also the effects of the diameters and dominance of the feeders of arteriovenous malformations on the clinical outcomes of AVMs.

Background: Arteriovenous malformations (AVM) are rare intracerebral vascular pathologies. AVMs inherently carry the risk of stealing or bleeding. Some studies suggest that morphometric changes in vascular structures in AVMs may give an idea about bleeding risk and prognosis. In this study, it was planned to investigate how treatment approaches and patient outcomes were affected by evaluating the morphometric characteristics of AVMs performed in our clinic with the demographic data of the patients.

DSA images of the right parietal AVM fed from the MCA and draining into the SSS

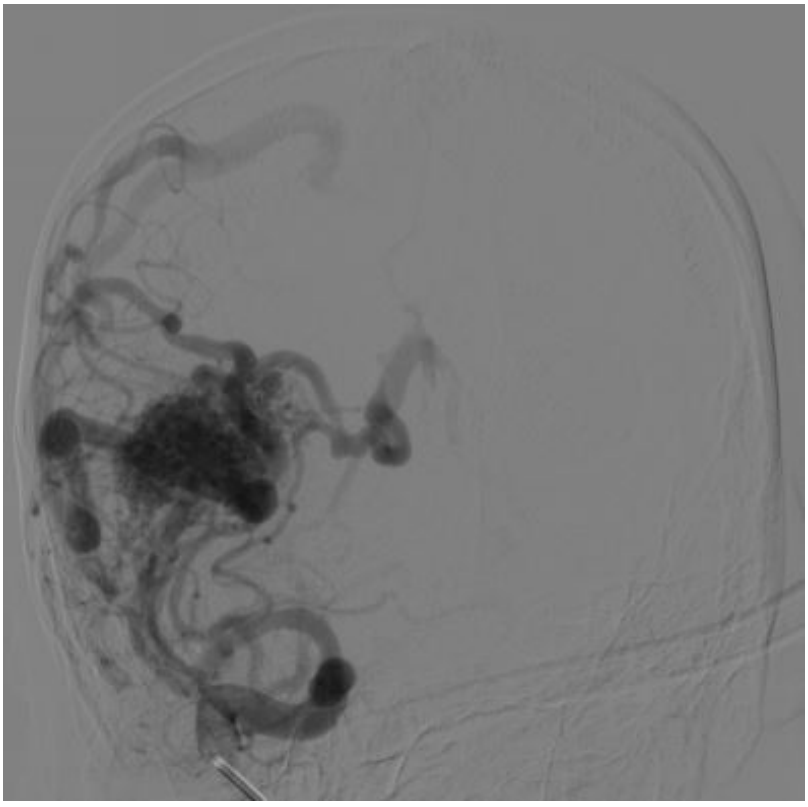

Method: AVM cases treated in our clinic since the last 2015 were evaluated retrospectively. In addition to the demographic data, vertebral artery dominance, presence of bleeding, Glasgow

coma scale at admission, Spetzler-Martin score, and type of nidus were evaluated. One way ANOVA was used for statistical analysis and $p<0.05$ was considered statistically significant.

Results: 48 patients between the years 2015-2023 were included. There were 36 male and 12 female patients. The mean age was 41.2 years. 62.5% (n=30) of the patients were treated with non-bleeding AVM. The average GCS among bled AVMs was 13.7. While the mean VA diameter difference was 0.82 in non-bleeding AVMs, it was 0.86 in bleeding AVMs, which was not statistically significant ($p>0.05$). Also, the rate of settling in the eloquent area of the bleeding patients were statistically significantly higher than the non-bleeding patients ($p<0.05$). The increase in the number of feeders was negatively affected clinical outcomes ($p<0.05$).

Pre and post embolization DSA images of left temporal AVM fed from MCA and PcoA and draining into SSSS

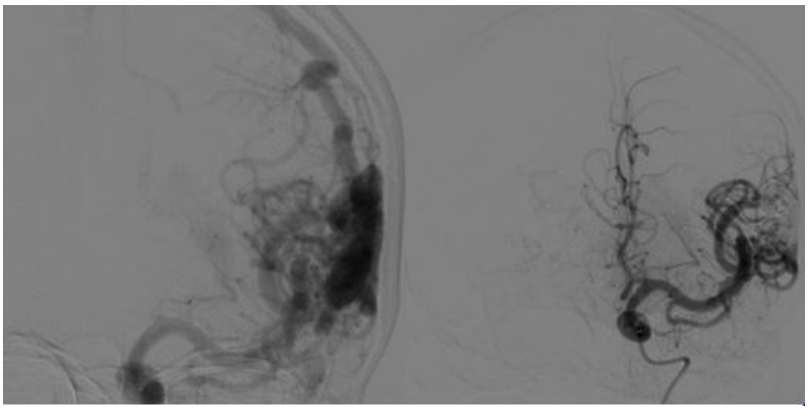

Pre and post embolization DSA images of the right temporobasal AVM, which is completely occluded after endovascular treatment

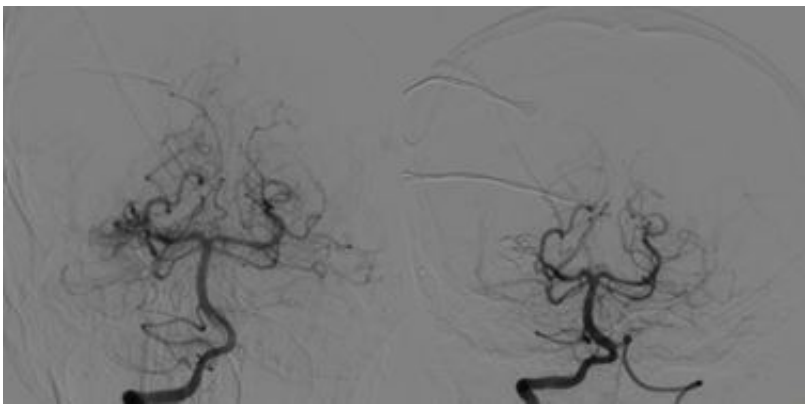

Conclusions: In the approach to AVMs, patient-related factors such as the patient's age and compliance, and also the morphometric and anatomical features of the AVM such as its location, feeders, and drainage are also important. These factors should be considered when planning the treatment of AVMs.

Keywords: Arteriovenous malformation, morphometric study, clinical outcomes

OP- V/47

Practicing Micro Neurosurgery and Skull base in limited resources areas and the importance of classical surgical approaches

jalal najjar[1]

[1]Aleppo University

Objectives: the new technology and the minimal invasive, endoscopic or key hole surgical techniques and approaches can not replace our traditional and standard neurosurgical techniques but it can surely improve it.

Background: Neurosurgery in areas with limited resources and in which advanced tools such as navigation and intra operative MRI are not available , or even CUSA device, endoscopy, and intra operative neuro monitoring, these practice depends on traditional surgical approaches and techniques as only way to practice and save patients life.

Method: In our center during the last three years, we performed about 250 microscopic neurosurgical procedures (one surgeon) without the availability of any of these advanced tools, mostly brain tumors , 40 cases of trigeminal micro vascular decompression .This experience proved to us that relying on traditional surgical techniques and approaches are the gold standard basis for the success of these operations we use standard steps like adequate bone removal of skull base, opening basal cisterns, opening sylvian fissure , and anterior clinedectomy for retractless surgery

Results: advanced tools can improve our practice of course because it can tells us where we are and how much tumor left for example , but it can not tells us what to do in brain swelling during surgery , and what is the safest way of dissection to protect the vital structures, or even gives us the accurate arachnoidal plan for safety dissection in meningiomas and other tumors surgery, but all these steps can be performed by our standard microsurgical approaches and can not be replaced by any modern tools or performed by what is called the minimal approaches and key hole and endoscopic surgeries.

Conclusions: modern tools are very welcome to support our classical neurosurgical techniques but its not candidate to replaced it and these standard technique will stay the corner stone in our practice

Keywords: microsurgery, limited resources, classical approaches, modern technology

References

2. Microneurosurgery
   in 4 Volumes
   M.G.Yasargil
3. Al_Mefty's_Meningiomas_2nd_2011_DeMonte_McDermott_&_Al_Mefty

OP- V/48

Endoscopic assisted transcranial removal of parasellar neoplasms

Abdishukur Abdilatipov[1], Pavel Kalinin[2], Maksim Kutin[2], Jamil Rzaev[1]

[1]Federal Neurosurgical Center, Novosibirsk, Russia, Nemirovich-Danchenko str., 132\1, 630087.
[2]N.N. Burdenko National Medical Research Center of Neurosurgery, Moscow, Russia, 4th Tverskaya-Yamskaya str., 16, Moscow, Russian Federation, 125047.

Objectives: Evaluation of the efficacy and appropriateness of endoscopic assistance in transcranial removal of neoplasms of the parasellar region

Background: To date, despite the successes of surgical treatment of parasellar tumors, there are a number of unresolved problems. One of them is the radicality of tumor removal, which varies depending on nosology from 40 to 99%. Since the radicality of tumor removal greatly affects the recurrence-free and overall survival rate, modern neurosurgeons are faced with the question of finding methods that increase the radicality of tumor removal. One such method is endoscopic assistance.

Method: The work is devoted to the analysis of the results of surgical treatment of 64 patients with various neoplasms of the parasellar region, operated on from 2018 to 2020 by transcranial access with endoscopic assistance.

Results: In the total group of patients (n 64) total excision was achieved in 28 (43.75%) patients, subtotal excision was achieved in 24 (37.5%) patients, partial excision was achieved in 12 (18.75%) patients (Figure 1), radicality of operations by nosology in percentage (Figure 2).

Figure 1

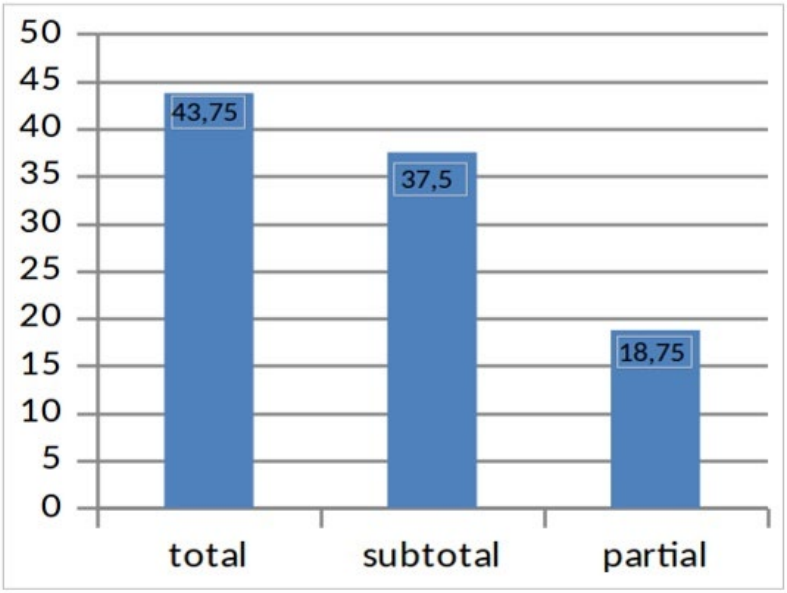

Radicality of operations in the study group as a percentage.

Figure 2

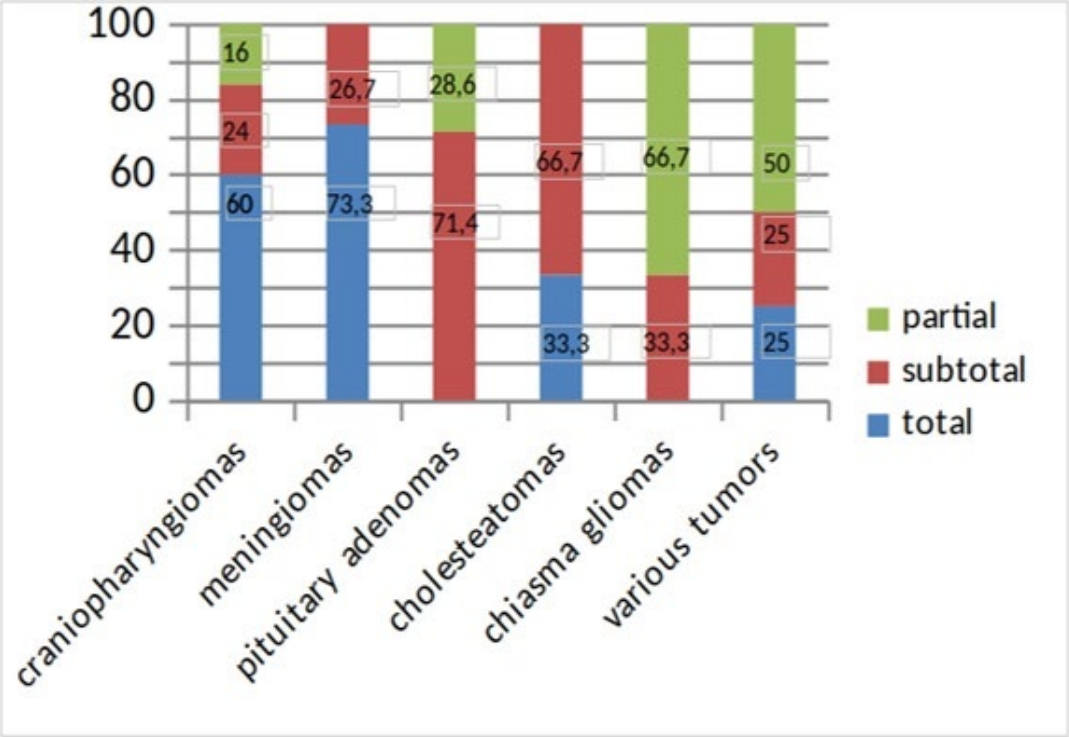

Radicality of operations by nosologies in percent.

Conclusions: The use of the endoscopic technique in the transcranial removal of parasellar neoplasms is particularly effective in the surgery of craniopharyngiomas and cholesteatomas, and in some situations in the surgery of pituitary adenomas and meningiomas. The technique allows the endoscope to inspect inaccessible areas for microscopic review, visualizing possible neoplasm remnants, blood accumulations, and identifying important anatomical structures for comfortable orientation in the operating wound.

Clinical case study

Male, 45 years old with visual impairments.

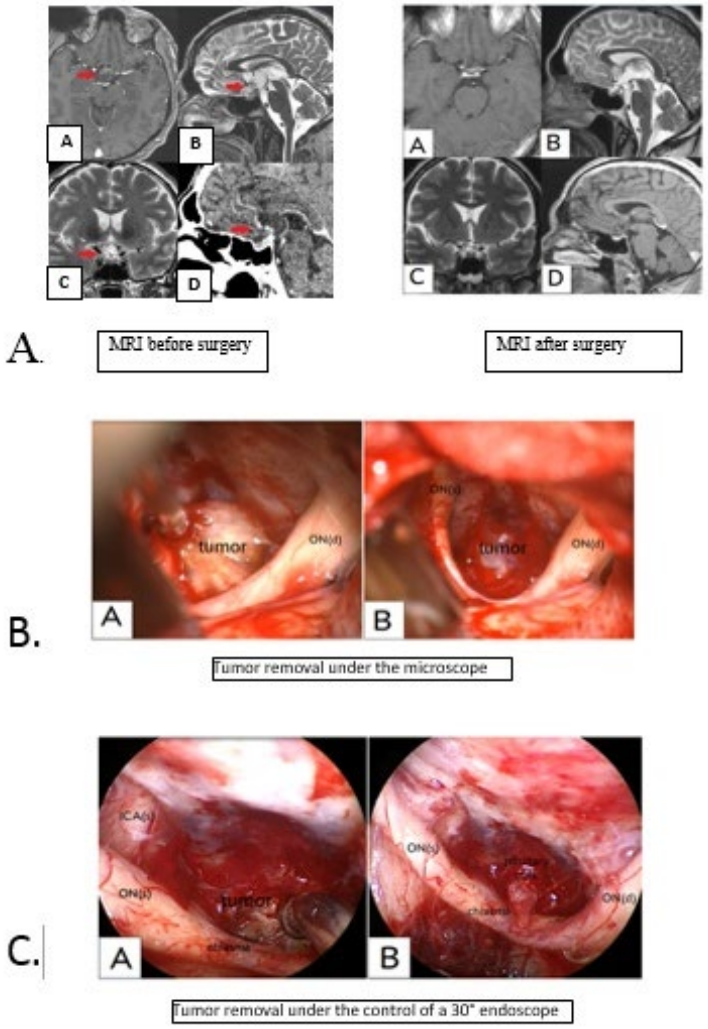

A. MRI before surgery, MRI after surgery B. Tumor removal under the microscope C. Tumor removal under the control of a 30° endoscope

Keywords: transcranial removal, endoscopic assistance, parasellar region

References

1. Fries G. Endoscope-assisted Brain Surgery: Part 2—Analysis of 380 Procedures / G. Fries, A. Perneczky // Neurosurgery – 1998. – V. 42 – № 2 – 226–231p.
2. Gazzeri R. Endoscopic supraorbital eyebrow approach for the surgical treatment of extraaxialand intraaxial tumors / R. Gazzeri, Y. Nishiyama, C. Teo // Neurosurg. Focus – 2014. – V. 37 – № 4 – E20p.
3. Linsler S. Endoscopic Assisted Supraorbital Keyhole Approach or Endoscopic Endonasal Approach in Cases of Tuberculum Sellae Meningioma: Which Surgical Route Should Be Favored? / S. Linsler, G. Fischer, V. Skliarenko, A. Stadie, J. Oertel // World Neurosurg. – 2017. – V. 104 – 601–611p.

OP-III/49

The Era of Web Based Learning & its Impact on Neurosurgical Training: Do We Need to Listen to the Call of the Void to Take the Leap of Faith?

Noor ul Huda Maria[1]

[1]PINS

Objectives: To evaluate the efficacy of the web-based learning methodology, recently promoted in keeping with the ongoing COVID-19 pandemic, through online courses, webinars and web conferences in neurosurgery.

Background: During the Covid-19 pandemic, everything came to a sudden halt. Doctors were relocated to manage Covid-19 patients and academic activities including grand ward rounds were being witheld potentially threatening neurosurgical education. During this pandemic, the dedicated teachers came up with a solution to continue education and training in Neurosurgery through virtual platform. With my association with Virtual Education as WFNS Education Committee member, I decided to conduct this study to see whether people are finding it effective and what do we need to change to make it more beneficial

Method: survey with the neurosurgery trainees and junior consultants

Results: 44.8% attended 5-10 webinars each week 34.5% spent ~2hrs, 40.7% agreed that web-based learning is better than book reading, 40.7% remained neutral, 11.1% strongly agreed,51.9% agreed that web based learning enhanced their ward based clinical knowledge withsupport from book,65.5% showed satisfaction with web-based learning,100% agreement that ward based learning should be combined with textbook reading 85.6% agreed that web-based learning should be integrated as a part of future neurosurgical training.53.8% agreed that they do not have stress during web-based training program as compared to their traditional learning program,38.5% agreed that they remain more attentive during web based training as compared to ward rounds and class,On a scale of 1-5, 48.5% gave grade5 to web-based learning69.2% agreed that web-based learning cause them to learn more per duration spent during web-based learning program as compared to the number of hours spent with the conventional learning method

Conclusions: The newly introduced and raging teacjing methodology of web based learning is extremely effective and it should be integrated as a part of neurosurgery training even after the end of pandemic.

Keywords: COVID-19, Pandemic, Web-Based learning, Neurosurgery

References

1) Lazaro T, Srinivasan VM, Rahman M, Asthagiri A, Barkhoudarian G, Chambless LB, Kan P, Rao G, Nahed BV, Patel AJ. Virtual education in neurosurgery during the COVID-19 pandemic. Neurosurg Focus. 2020 Dec;49(6):E17. doi: 10.3171/2020.9.FOCUS20672. PMID: 33260121.
2) El-Ghandour NMF, Ezzat AAM, Zaazoue MA, Gonzalez-Lopez P, Jhawar BS, Soliman MAR. Virtual learning during the COVID-19 pandemic: a turning point in neurosurgical education. Neurosurg Focus. 2020 Dec;49(6):E18. doi: 10.3171/2020.9.FOCUS20634. PMID: 33260124.

OP-I/50

Enhancıng Mıcrosurgıcal Skills In Neurosurgery Residents Of Low-Income Countries: A Comprehensive Guide To Establishing An Affordable Microsurgery Laboratory

Carlos Salvador Ovalle[1], Alfredo Espinosa Mora[7], Alvaro Campero[2], Iype Cherian[3], Albert Sufianov[4], Edgar Fragoza Sanchez[1], Manuel Encarnación Ramírez[5], Macario Arellano Beltrán[1], Eduardo Diaz Juarez[1], Arturo Muñoz Cobos[6], Matias Baldoncini[8]

[1]Department of Neurosurgery, National University of Mexico Hospital General 450, 34030, Durango, Mexico.
[2]Laboratorio de Inovaciones Neuroquirurgicas de Tucuman (LINT), Facultad de Medicina, Universidad Nacional de Tucumán, 4000 Tucuman, Argentina.
[3]Institute of Neurosciences, Krishna Vishwa Vidyapeeth, 415539 Karad, India.
[4]Federal State Budgetary Institution the Federal Center of Neurosurgery of the Ministry of Health of the Russian Federation, 625062, Tyumen, Russia
[5]Department of neurosurgery, RUDN University, 121359 Moscow, Rusia.
[6]Neurosurgery service, Hospital Star Medica, 31110, Chihuahua, Mexico.
[7]Neurosurgery service, Centenario, Hospital Miguel Hidalgo, 20230 Aguascalientes, Mexico
[8]Laboratorio de Neuroanatomía Microquirúrgica (LaNeMic), Segunda Catedra de Anatomia, Universidad de Buenos Aires, 1646, Buenos Aires, Argentina.

Objectives: *Identify key components required to set up an affordable laboratory for low-resource hospitals. *Offer strategies for laboratory setup/optimization, providing step-by-step instructions, layout-ergonomic recommendations, and medical waste processes. *Develop training curriculum to enhance microsurgical skills. *Evaluate effectiveness of low-cost microsurgery laboratory: evaluation framework, gathering feedback, tracking progress, measuring outcomes.

Background: Microsurgery plays a crucial role in neurosurgery. Throughout history, cadaveric dissections study has been carried out, achieving surgical-scientific advances. In 1957, microscope was used in neurosurgery, it was the basis of microneurosurgical revolution of the last 60 years, with microsurgery laboratories foundation around the world, almost all of them located in great cities/large medical centers, with high cost courses. This inspired our work in an attempt to bring micrneurosurgery to any low in-come countries/low resource hospitals in the world.

Method: We used own economic resources, low-cost material, knowledge exchange, economic/material donations by scientifically justifying our project, and finally establishing the laboratory after 6 months. Simultaneously we did exhaustive research on publications related to microsurgery laboratory, microsurgical techniques, and neuroanatomy; and for 4 months, we develop practices, based in the literature and in a self-taught way, from basic concepts to the most complex aspects.

Results: The result is an affordable microsurgery laboratory, replicable in low-resource hospitals/low-income countries; consists of 4 workstations with basic microsurgery equipment; a step-by-step guide to its realization, and a training curriculum, with high quality results

regarding microsurgical techniques, repletion techniques, and surgical approaches, ensuring cost-effectiveness.

Supracerebellar approach to the pineal region.

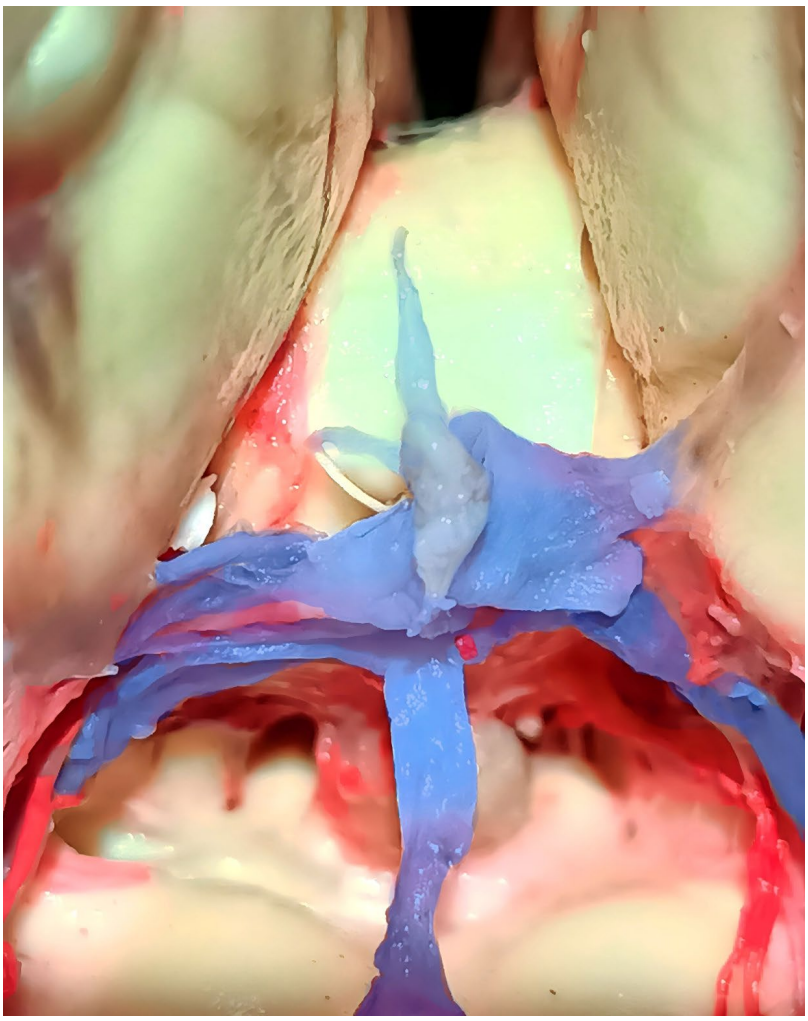

The lower edge of the image shows the upper portion of the lamina quadriggemina (superior mesencephalic coliculles); The upper border shows the interhemispheric space and the greater forceps of the corpus callosum; in the center is observed the confluence of venous vessels that give rise to the vein of Galen, and its relationship with branches of the posterior cerebral artery; In the background, behind the superior vermian vein, the silhouette of the pineal gland is observed.

Delimitation of the paracentral lobe in the left lateral aspect of the brain



After the microdissection of the arachnoid and vessels, we perform the macroscopic study of the grooves and gyrus, delimiting in this case the so-called paracentral lobe, formed by the precentral gyrus (part of the frontal lobe) and postcentral (part of the parietal lobe), taking as reference the central sulcus, with its anterior limit corresponding to the precentral sulcus and posterior limit corresponding to the postcentral sulcus. This lobe has great functional importance (motor and sensitive homunculi); as well as great surgical importance when we are faced with lesions located or adjacent to this lobe (for example; a convexity or parasagital meningioma).

White fiber dissection

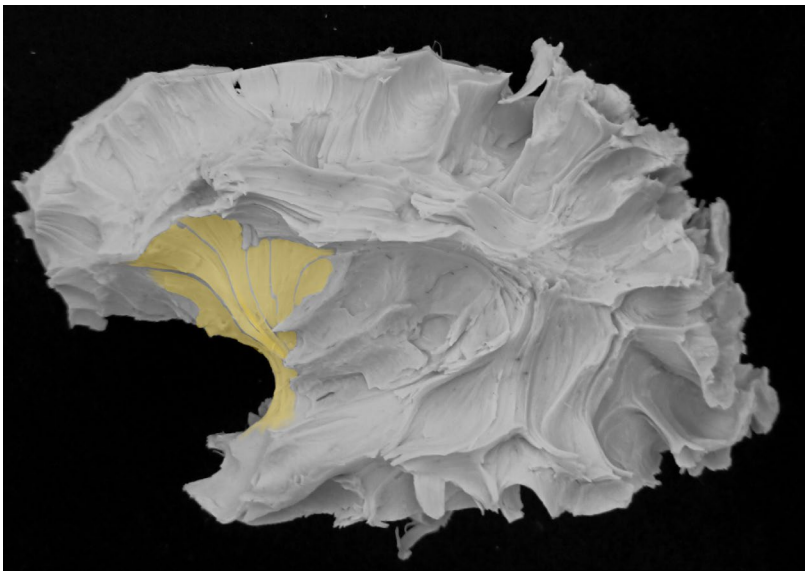

After the microscopic and macroscopic study of the brain, the dissection of white fibers is performed. Components of the superior longitudinal fasciculus, arcuate fasciculus and in the most anterior part of the area marked in yellow, part of the uncinate fasciculus is observed.

Results of microsuture and fine movements practice.

Microsuture and fine movements Practice	10 Separate Stiches (Initial) *10mm space	10 Continuous Stiches (Initial) *10mm space	10 Separate Stiches (Final) *Less than 10mm space	10 Continuous Stiches (Final *Less than 10mm space
Average "Surgical" Time (min)	30.6	19.84	21.4	13.3
Bad quality	36.36%	36.36%	63.63%	63.63%
Regular quality	36.36%	36.36%	36.37%	36.37%
Good quality	27.28%	27.28%	0%	0%

An example of the results obtained after performing the practices of microsuture and fine movements in the laboratory is shown. A decrease in the average "surgical" microsuture" was obtained, with average decrease of 8.65 minutes for the separated single stiches and 6.51 minutes for the continuous single stiches. As well as increase in the quality of the stitches improving the suture pattern, reducing the space between each stitch and finding more resistant stitches.

Conclusions: Establishing an affordable microsurgery laboratory in low-income countries is a challenging but achievable goal; by teamwork, knowing key steps in setting up, tailored to the specific necessities, cost-effective alternatives, developing training curriculum, evaluating effectiveness; we conclude: it is possible to get a complete functional laboratory with high level quality in low in-come countries and it may help improving training programs, refine protocols, and enhance patient outcomes.

Keywords: Microsurgery Laboratory, Neurosurgery, Microsurgical skills, Low in-come countries

References

1) Altunrende ME, Hamamcioglu MK, Hıcdonmez T, Akcakaya MO, Bırgılı B, Cobanoglu S. Microsurgical training model for residents to approach to the orbit and the optic nerve in fresh cadaveric sheep cranium. J Neurosci Rural Pract. 2014 Apr;5(2):151-4. doi: 10.4103/0976-3147.131660. PMID: 24966554; PMCID: PMC4064181.
2) Baldoncini M, Campero A, Pérez Cruz JC, Recalde R, Parraga R, Sanchez Gonzalez FJ, Fortte M, López PG. Microsurgical Anatomy and Approaches to the Cerebral Central Core. World Neurosurg. 2019 Sep;129:e23-e34. doi: 10.1016/j.wneu.2019.04.139. Epub 2019 May 17. PMID: 31103755.
3) Camacho García FJ, Ramírez León JF, Rojas Galvis MA, Cortés Barré M, Cogua Cogua LN. Guía de microcirugía en técnicas de entrenamiento en cirugía de mínima invasión. Revista Colombiana de Ortopedia y Traumatología. 2019;33(2):84-90
4) Encarnacion Ramirez, M., Ramirez Pena, I., Barrientos Castillo, R. E., Sufianov, A., Goncharov, E., Soriano Sanchez, J. A., Nurmukhametov, R., Cerda Céspedes, J. R., & Montemurro, N. (2023). Development of a 3D Printed Brain Model with Vasculature for Neurosurgical

Procedure Visualisation and Training. *Biomedicines*, *11*(2), 330. https://doi.org/10.3390/biomedicines11020330

5) Campohermoso Rodríguez OF, Soliz Soliz RE, Campohermoso Rodríguez O, Zúñiga Cuno W. Galeno de Pérgamo príncipe de los médicos. Revista 'Cuadernos'. 2016;57(2):84.
6) Cherian I, Yi G, Munakomi S. Cisternostomy: Replacing the age old decompressive hemicraniectomy? Asian J Neurosurg. 2013 Jul;8(3):132-8. doi: 10.4103/1793-5482.121684. PMID: 24403955; PMCID: PMC3877499.
7) Chung SB, Ryu J, Chung Y, Lee SH, Choi SK. An Affordable Microsurgical Training System for a Beginning Neurosurgeon: How to Realize the Self-Training Laboratory. World Neurosurg. 2017 Sep;105:369-374. doi: 10.1016/j.wneu.2017.05.174. Epub 2017 Jun 27. PMID: 28599906.
8) Ramirez M, Nurmukhametov R, Musa G, et al. (July 30, 2022) Three-Dimensional Plastic Modeling on Bone Frames for Cost-Effective Neuroanatomy Teaching . Cureus 14(7): e27472. doi:10.7759/cureus.27472.
9) Dave A, Singhal M, Tiwari R, Chauhan S, De M. Effectiveness of a microsurgery training program using a chicken wing model. J Plast Surg Hand Surg. 2022 Aug;56(4):191-197. doi: 10.1080/2000656X.2021.1953043. Epub 2021 Aug 2. PMID: 34339351.
10) Gadea Nieto MS. Dr. Sergio Gómez-Llata Andrade (1931-2011) Príncipe de la neurocirugía obituario. Rev Neuroeje. San Jose, Costa Rica, Mayo - Diciembre 2011; 24(2): 40-42.
11) Gómez-Vega JC, Mancera Pérez J, Reghin Neto M, Holanda V, de Oliveira E. Desarrollo de técnicas microquirúrgicas usando tinción vascular con y sin silicona en placenta humana con modelos craneales 3D. Rev Argent Neuroc 2021;35(2):160-171.
12) Gusmão S. Evandro de Oliveira: from Anatomy to Science and the Art of Microneurosurgery. Arq Bras Neurocir Braz Neurosurg. 2020;39(3):200-201
13) Hosain MM. Microsurgery Training: Are the Live Models Era Coming in to the Tail? – A Literature Review. J Advances in Medicine and Medical Research. 2021 33(2): 97-109
14) Javid et al. Current status of simulation and training models in microsurgery: A systematic review. Microsurgery. 2019 August; 30(8):1-14.
15) Joseph FJ, Vanluchene HER, Bervini D. Simulation training approaches in intracranial aneurysm surgery-a systematic review. Neurosurg Rev. 2023 May 3;46(1):101. doi: 10.1007/s10143-023-01995-5. PMID: 37131015; PMCID: PMC10154262.
16) Juratli MA, Becker F, Palmes D, Stöppeler S, Bahde R, Kebschull L, Spiegel HU, Hölzen JP. Microsurgical training course for clinicians and scientists: a 10-year experience at the Münster University Hospital. BMC Med Educ. 2021 May 24;21(1):295. doi: 10.1186/s12909-021-02737-1. PMID: 34024279; PMCID: PMC8142514.
17) Kriss TC, Kriss VM. History of the operating microscope: from magnifying glass to microneurosurgery. Neurosurgery. 1999 Aug;45(2):418
18) Liu JK, Kshettry VR, Recinos PF, Kamian K, Schlenk RP, Benzel EC. Establishing a surgical skills laboratory and dissection curriculum for neurosurgical residency training. J Neurosurg. 2015 Nov;123(5):1331-8. doi: 10.3171/2014.11.JNS14902. Epub 2015 May 26. PMID: 26052729.
19) Marian-Magaña R. Microsurgical training through laboratory experience: a step-by-step practical guideline. Interdiciplinary Neurosurgery. 2022 March; Vol. 7 doi.org/10.1016/j.inat.2021.101400
20) Martins PN, Montero EF. Basic microsurgery training: comments and proposal. Acta Cir Bras. 2007 Jan-Feb;22(1):79-81. doi: 10.1590/s0102-86502007000100014. PMID: 17293955.
21) Matsushima T, Matsushima K, Kobayashi S, Lister JR, Morcos JJ. The microneurosurgical anatomy legacy of Albert L. Rhoton Jr., MD: an analysis of transition and evolution over 50 years. J Neurosurg. 2018 Nov 1;129(5):1331-1341. doi: 10.3171/2017.7.JNS17517. PMID: 29393756.
22) Matsushima T, Richard Lister J, Matsushima K, de Oliveira E, Timurkaynak E, Peace DA, Kobayashi S. The history of Rhoton's Lab. Neurosurg Rev. 2019 Mar;42(1):73-83. doi: 10.1007/s10143-017-0902-4. Epub 2017 Sep 6. PMID: 28879421.

23) Muñoz Cobos A. Lecona Butrón H. et al. Manual práctico de Microcirugía Cirugía vascular y nerviosa. Primera edición. Mexico. Tercer Escalón Editoriales 2017
24) Encarnacion Ramirez MDJ, et al. Three-dimensional Cerebrovascular Bypass Training. A New Low-Cost Home-MadeModel. Front Med Case Rep 2021; 2(2): 1-10.
25) Ocampo-Navia Maria Isabel, Gómez-Vega Juan Carlos. Técnicas para el estudio anatómico del cerebro: una revisión. Univ. Med. 2021 Mar [cited 2023 March 13] ; 62(1): 22-32.
26) Omar Félix Campohermoso Rodríguez*, Ruddy Eusebio Soliz Soli, Andreas Vesalius Padre de la Anatomía Moderna. Historia de la Medicina. 2017 "Cuadernos" Vol. 58(1): 79-90
27) Padilla Luis, Tapia-Jurado Jesús, Goldberg Jonathan, Landero Takeshi, Carranza Pilar, Di Silvio Mauricio. Unidad de Microcirugía: 30 años de experiencia clínica, entrenamiento continuo e investigación. Cir. gen. 2011 Sep [citado 2023 Abril 14] ; 33(3): 196-202
28) Pérez-Zabala J., Beldi Florencia Modelo integral de entrenamiento microquirúrgico y neuroendovascular con placenta humana. Rev Argent Neuroc. 2020; 34(4): 300-314.
29) Pipolo DO, Luzzi S, Baldoncini M, Di Pietrantonio A, Brennan W, Asmus H, Miyara SJ, Lucifero AG, Campero A. Virtual preoperative planning and 3D tumoral reconstruction with Horos open-source software. Surg Neurol Int. 2023 Jan 27;14:32. doi: 10.25259/SNI_1075_2022. PMID: 36895211; PMCID: PMC9990789.
30) Romero Reveron Rafael. Andreas Vesalius (1514-1564): Fundador de la Anatomía Humana Moderna. Int. J. Morphol. 2007 Dic [citado 2023 Marzo 13] ; 25(4): 847-850
31) Ramirez, M. E., Sanchez, J. S., Barsa, J., Barrietos, R., & Musa, G. (2021). Training in cerebral aneurysm clipping using self made 3 dimensional models including blood flow. *Brain and Spine*, *1*, 100815. https://doi.org/10.1016/j.bas.2021.100815
32) Samprónf Nicolas Manual de microcirugia neurovascular. Primera edición. Donostia España. Comunicación OSI Donostialdea. Febrero 2017
33) Wen HT, Matsushima T, Morcos JJ; Rhoton Society. Evandro Pinto da Luz de Oliveira, MD, PhD (November 8, 1945-February 11, 2021): A Giant of Microneurosurgery and Neuroanatomy. Neurosurgery. 2021 Sep 15;89(4):E229-E232. doi: 10.1093/neuros/nyab252. PMID: 34293166.
34) Yadav YR, Parihar V, Ratre S, Kher Y, Iqbal M. Microneurosurgical Skills Training. J Neurol Surg A Cent Eur Neurosurg. 2016 Mar;77(2):146-54. doi: 10.1055/s-0034-1376190. Epub 2015 Apr 27. PMID: 25915501.
35) Yaşargil MG. A legacy of microneurosurgery: memoirs, lessons, and axioms. Neurosurgery. 1999 Nov;45(5):1025-92. doi: 10.1097/00006123-199911000-00014. PMID: 10549924.
36) De Jesus Encarnacion Ramirez, M., Peralta, I., Ramirez, I., Dauly, V., Mainer, G., Nurmukhametov, R., & Efe, I. E. (2022). Development of a Novel Low-Cost Exoscope to Expand Access to Microneurosurgical Care in Low- and Middle-Income Countries. *World Neurosurgery*, *163*, 5-10. https://doi.org/10.1016/j.wneu.2022.03.144
37) Encarnacion Ramirez, M., Peralta Baez, I., Nurmukhametov, R., Goncharov, E., Efe, I. E., Sufianov, A., & Ramirez Pena, I. (2023). Comparative survey study of the use of a low cost exoscope vs. microscope for anterior cervical discectomy and fusion (ACDF). *Frontiers in Medical Technology*, *4*. https://doi.org/10.3389/fmedt.2022.1055189

OP-I/51

A Novel Direct Pathway of Dural Venous Outflow from the Basilar Venous Plexus via the Diploic Space of the Clivus

Juan J. Cardona[1], Marissa Tucci[1], Arada Chaiyamoon[2], Athikhun Suwannakhan[3], Ayhan Comert[4], Joe Iwanaga[1], Aaron S. Dumont[1], R. Shane Tubbs[1]

[1]Department of Neurosurgery, Tulane Center for Clinical Neurosciences, Tulane University School of Medicine, New Orleans, LA, USA
[2]Department of Anatomy, Faculty of Medicine, Khon Kaen University, Khon Kaen, Thailand
[3]Department of Anatomy, Faculty of Science, Mahidol University, Bangkok, Thailand; In Silico and Clinical Anatomy Research Group (iSCAN), Bangkok, Thailand
[4]Department of Anatomy, School of Medicine, Ankara University, Ankara, Turkey

Objectives: To better elucidate and understand the venous outflow of the basilar venous plexus via cadaveric dissection and histological examination.

Background: The internal jugular vein is the pre-eminent outflow of the dural venous sinuses in the supine position, while the vertebral venous plexus dominates venous outflow in the upright position. Emissary veins can also be an accessory pathway for this venous egress. To our knowledge, alternative dural venous sinus directly drainage via the diploic space has not been previously reported in the literature.

Schematic drawing of the basilar venous plexus and other venous sinuses of the skull base.

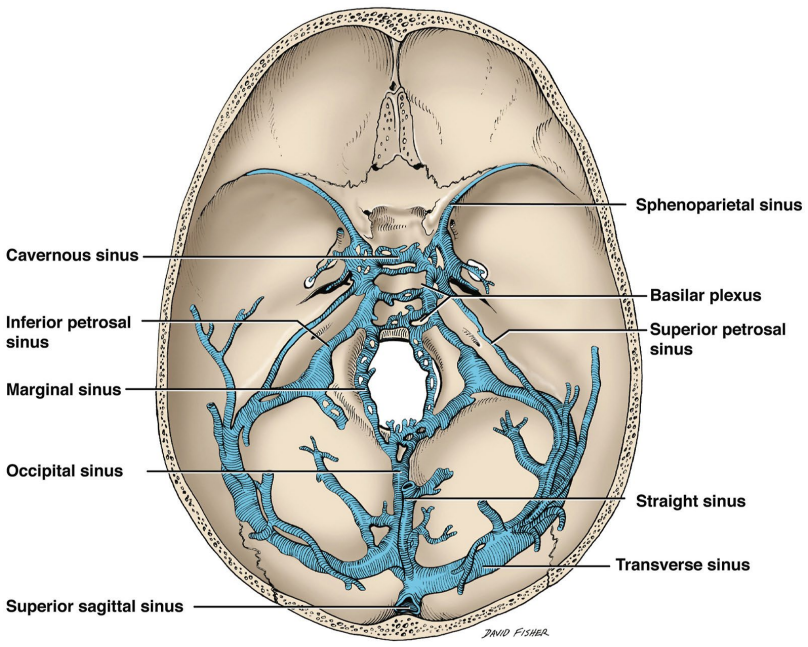

Method: Ten fresh frozen adult cadavers underwent exposure of the basilar venous plexus. The entire plexus, still adhered to the underlying clivus, was removed with its underlying bone and submitted for histological examination following decalcification (Masson Trichrome, 5 µm slices).

Results: All specimens were found to have direct communication between the basilar venous plexus and underlying diploic space of the clivus i.e., no intermediate clival emissary vein. These were concentrated near the midline and were more numerous over the clivus near the junction of the occipital and sphenoid bones. The endothelium of the venous sinus was continuous at the opening into the diploic space and these openings ranged in size from 500 to 750 µm (mean 650 µm).

Histological example illustrating the direct connection between the basilar venous plexus (BVP) and the underlying diploic space of the clivus.

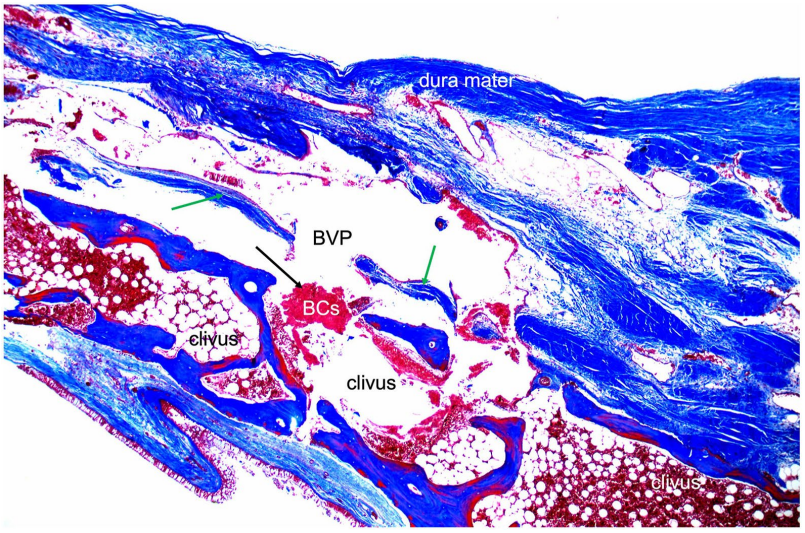

Note the collection of blood cells (BCs) at the black arrow with free communication between the basilar venous plexus and diploic space of the clivus. The meningeal layer of dura is seen as the thicker and more superficially located 'dura mater' and the periosteal layer of dura is seen at the green arrows. (Masson trichrome x40)

Conclusions: An improved understanding of the cerebral venous drainage can assist clinicians and surgeons in recognizing normal, pathologic, and variant anatomy in this region. Literature on the anatomy of the clival diploic veins is sparse, and their course and clinical significance are incompletely described. Based on our study, direct venous sinus to diploic space drainage offers an additional pathway for venous egress from the intracranium. Therefore, removal of the dura over the clivus during various skull base procedures might be associated with increased venous bleeding from the basilar venous plexus on its deep surface where it interfaces with the clivus.

Keywords: Basilar venous plexus, Clivus, Diploic space, Skull base

References

1) Tobinick E, Vega CP. The cerebrospinal venous system: anatomy, physiology, and clinical implications. MedGenMed. Feb 22 2006;8(1):53.
2) Carpenter K, Decater T, Iwanaga J, et al. Revisiting the Vertebral Venous Plexus-A Comprehensive Review of the Literature. World Neurosurg. Jan 2021;145:381-395. doi:10.1016/j.wneu.2020.10.004

3) Valdueza JM, von Münster T, Hoffman O, Schreiber S, Einhäupl KM. Postural dependency of the cerebral venous outflow. Lancet. Jan 15 2000;355(9199):200-1. doi:10.1016/s0140-6736(99)04804-7
4) Gisolf J, van Lieshout JJ, van Heusden K, Pott F, Stok WJ, Karemaker JM. Human cerebral venous outflow pathway depends on posture and central venous pressure. J Physiol. Oct 1 2004;560(Pt 1):317-27. doi:10.1113/jphysiol.2004.070409
5) Wang H, Kim M, Normoyle KP, Llano D. Thermal Regulation of the Brain-An Anatomical and Physiological Review for Clinical Neuroscientists. Front Neurosci. 2015;9:528. doi:10.3389/fnins.2015.00528
6) Zenker W, Kubik S. Brain cooling in humans--anatomical considerations. Anat Embryol (Berl). Jan 1996;193(1):1-13. doi:10.1007/bf00186829
7) Batson OV. The vertebral system of veins as a means for cancer dissemination. Prog Clin Cancer. 1967;3:1-18.
8) Batson OV. The vertebral vein system. Caldwell lecture, 1956. Am J Roentgenol Radium Ther Nucl Med. Aug 1957;78(2):195-212.
9) Groen RJ, Groenewegen HJ, van Alphen HA, Hoogland PV. Morphology of the human internal vertebral venous plexus: a cadaver study after intravenous Araldite CY 221 injection. Anat Rec. Oct 1997;249(2):285-94. doi:10.1002/(sici)1097-0185(199710)249:2<285::Aid-ar16>3.0.Co;2-k
10) Tubbs RS, Demerdash A, Loukas M, et al. Intracranial Connections of the Vertebral Venous Plexus: Anatomical Study with Application to Neurosurgical and Endovascular Procedures at the Craniocervical Junction. Oper Neurosurg (Hagerstown). Jan 1 2018;14(1):51-57. doi:10.1093/ons/opx080
11) Schreiber SJ, Lurtzing F, Gotze R, Doepp F, Klingebiel R, Valdueza JM. Extrajugular pathways of human cerebral venous blood drainage assessed by duplex ultrasound. J Appl Physiol (1985). May 2003;94(5):1802-5. doi:10.1152/japplphysiol.00782.2002
12) Kopelman M, Glik A, Greenberg S, Shelef I. Intracranial Nonjugular Venous Pathways: A Possible Compensatory Drainage Mechanism. American Journal of Neuroradiology. 2013;34(7):1348-1352. doi:10.3174/ajnr.a3402
13) Tubbs RS, Hansasuta A, Loukas M, et al. The basilar venous plexus. Clin Anat. Oct 2007;20(7):755-9. doi:10.1002/ca.20494
14) Mizutani K, Akiyama T, Yoshida K, Toda M. Skull Base Venous Anatomy Associated with Endoscopic Skull Base Neurosurgery: A Literature Review. World Neurosurg. Dec 2018;120:405-414. doi:10.1016/j.wneu.2018.09.067
15) San Millán Ruíz D, Gailloud P, Rüfenacht DA, Delavelle J, Henry F, Fasel JH. The craniocervical venous system in relation to cerebral venous drainage. AJNR Am J Neuroradiol. Oct 2002;23(9):1500-8.
16) Altafulla JJ, Rai R, Shrager S, et al. Transclival Venous Circulation: Anatomic Study. World Neurosurg. Jan 2019;121:e136-e139. doi:10.1016/j.wneu.2018.09.038
17) Chun JY, Dillon WP, Berger MS. Symptomatic enlarged cervical anterior epidural venous plexus in a patient with Marfan syndrome. AJNR Am J Neuroradiol. Apr 2002;23(4):622-4.
18) Choi HY, Kim SB, Park S. Recurrent abducens nerve palsy due to basilar venous plexus engorgement. Neurol Sci. Oct 2015;36(10):1913-5. doi:10.1007/s10072-015-2271-5
19) Graf CJ. Carotid-basilar venous plexus fistulas. J Neurosurg. Aug 1970;33(2):191-7. doi:10.3171/jns.1970.33.2.0191
20) Pouw AE, Rabin RL, Karanjia R, Bababeygy SR, Amar AP, Sadun AA. Angioarchitectural Evolution of Clival Dural Arteriovenous Fistulas in Two Patients. Case Reports in Ophthalmology. 2015;6(1):93-100. doi:10.1159/000381176
21) Cabanac M, Brinnel H. Blood flow in the emissary veins of the human head during hyperthermia. Eur J Appl Physiol Occup Physiol. 1985;54(2):172-6. doi:10.1007/bf02335925
22) Mortazavi MM, Tubbs RS, Riech S, et al. Anatomy and pathology of the cranial emissary veins: a review with surgical implications. Neurosurgery. May 2012;70(5):1312-8; discussion 1318-9. doi:10.1227/NEU.0b013e31824388f8

23) Tsutsumi S, Sugiyama N, Ueno H, Ishii H. Does diploic venous flow drain extracranially in the pterional area? A magnetic resonance imaging study. Surgical Neurology International. 2022;13:425. doi:10.25259/sni_760_2022
24) Yokota H, Noguchi H, Yokoyama K. Epidermoid Cyst with Torcular Herophili Obstruction and Unusual Venous Drainage. World Neurosurg. Aug 2019;128:14-17. doi:10.1016/j.wneu.2019.04.223
25) Yamashiro K, Muto J, Wakako A, et al. Diploic veins as collateral venous pathways in patients with dural venous sinus invasion by meningiomas. Acta Neurochir (Wien). Jun 2021;163(6):1687-1696. doi:10.1007/s00701-021-04777-4
26) Jo JI, Ryu CW, Ko HC, Shin HS. Direct Cannulation of a Calvarial Diploic Vein for Embolization of a Symptomatic Intraosseous Arteriovenous Fistula: A Case Report. Taehan Yongsang Uihakhoe Chi. May 2022;83(3):712-718. doi:10.3348/jksr.2021.0088
27) Jeevan DS, Anlsow P, Jayamohan J. Abnormal venous drainage in syndromic craniosynostosis and the role of CT venography. Childs Nerv Syst. Dec 2008;24(12):1413-20. doi:10.1007/s00381-008-0667-8
28) Akram H, Prezerakos G, Haliasos N, O'Donovan D, Low H. Sinus pericranii: an overview and literature review of a rare cranial venous anomaly (a review of the existing literature with case examples). Neurosurg Rev. Jan 2012;35(1):15-26; discussion 26. doi:10.1007/s10143-011-0325-6
29) Mizutani K, Toda M, Kurasawa J, et al. Analysis of the venous channel within the clivus using multidetector computed tomography digital subtraction venography. Neuroradiology. 2017;59(3):213-219. doi:10.1007/s00234-017-1784-4
30) Inal M, Muluk NB, Ozveren MF, et al. The Presence of Clival Foramen Through Multidetector Computed Tomography of the Skull Base. J Craniofac Surg. Oct 2015;26(7):e580-2. doi:10.1097/scs.0000000000002129
31) Tubbs RS, Griessenauer CJ, Loukas M, Zurada A, Shoja MM, Cohen-Gadol AA. The enigmatic clival canal: anatomy and clinical significance. Childs Nerv Syst. Sep 2010;26(9):1207-10. doi:10.1007/s00381-010-1100-7
32) Tsutsumi S, Ono H, Yasumoto Y. A possible venous connection between the cranial and nasal cavity. Surgical and Radiologic Anatomy. 2016;38(8):911-916. doi:10.1007/s00276-016-1650-9
33) Bulbul E, Yanik B, Demirpolat G, Koksal V. Extraordinary cerebral venous drainage pathway with mastoid emissary and posterior external jugular veins detected by contrast-enhanced neck computed tomography. Surgical and Radiologic Anatomy. 2015;37(10):1191-1194. doi:10.1007/s00276-015-1496-6
34) Doepp F, Schreiber SJ, von Münster T, Rademacher J, Klingebiel R, Valdueza JM. How does the blood leave the brain? A systematic ultrasound analysis of cerebral venous drainage patterns. Neuroradiology. Jul 2004;46(7):565-70. doi:10.1007/s00234-004-1213-3
35) Kresakova L, Purzyc H, Schusterova I, Fulton B, Maloveska M, Vdoviakova K, Kravocova Z, Boldizar M. Non-standard intracranial connection and alternative pathways between dural venous sinuses and cerebral veins in the rat. Anat Sci Int. 2015;90:172-9.

OP- V/54

Hybrid Positron Emission Tomography And Magnetic Resonance Imaging In The Management Of Recurrent Glial Tumors

Murat Buyuktepe[1], Ihsan Dogan[2], Yusuf Sukru Caglar[2]

[1]Unye State Hospital, Ordu, Turkey
[2]Ankara University School of Medicine, Ankara, Turkey

Objectives: The aim of this study is to report our clinical experience with hybrid positron emission tomography (PET) and magnetic resonance imaging (MRI) navigation in the management of recurrent glial brain tumors in terms of gross-total resection rate and 1-year survival.

Background: Hybrid imaging with integrated PET/MRI allows to obtain metabolic information provided by positron emission tomography (PET), beside the functional and morphological information provided by magnetic resonance imaging (MRI), in a single session. In addition to define tumor margins preoperatively, integrated PET/MRI images may also differentiate the non-tumor changes secondary to radiotherapy, and presence of residual tumor tissue or tumor recurrence in postoperative period.

Method: The files of consecutive recurrent neuroglial brain tumor patients who underwent PET/MRI imaging at preoperative or intraoperative period were reviewed retrospectively. Clinical and demographic data were recorded. Patients with non-glial intracranial tumors including metastasis, lymphoma and meningioma were excluded from the study. Hybrid images were used for differential diagnosis, treatment planning as well as the intraoperative guidance.

Results: Eight patients (mean age 50.1±11.0 years) with suspicion of recurrent glioma tumor were included in the study. Gross total tumor resection of the PET/MRI positive area was achieved in 7 patients, whereas 1 patient diagnosed as radiation necrosis, and surgery was avoided. All patients survived at 1-year follow-up. Five (71.4%) of the recurrent patients remained free of recurrence for the entire follow-up period. Two patients with glioblastoma had tumor recurrence at postoperative sixth and eight months.

Conclusions: Hybrid PET/MRI imaging provides reliable and accurate information to distinguish recurrent glial tumor from radiation necrosis. With the help of this differential diagnosis, hybrid imaging may provide gross total resection of recurrent tumors without harming eloquent brain areas.

Keywords: hybrid imaging, high grade glioma, positron emission tomography, recurrent glial tumor

References

1. Stupp R, Mason WP, van den Bent MJ, Weller M, Fisher B, Taphoorn MJB, et al. Radiotherapy plus Concomitant and Adjuvant Temozolomide for Glioblastoma. N Engl J Med. 2005 Mar 10;352(10):987–96.
2. McKinney PA. Brain tumours: incidence, survival, and aetiology. J Neurol Neurosurg Psychiatry. 2004;75:12–4.
3. Tempany CMC, Jayender J, Kapur T, Bueno R, Golby A, Agar N, et al. Multimodal imaging for improved diagnosis and treatment of cancers. Cancer. 2015;121(6):817–27.
4. Boellaard R, Quick HH. Current Image Acquisition Options in PET/MR. Semin Nucl Med. 2015 May;45(3):192–200.
5. van de Weijer T, Broen MPG, Moonen RPM, Hoeben A, Anten M, Hovinga K, et al. The Use of 18F-FET-PET-MRI in Neuro-Oncology: The Best of Both Worlds—A Narrative Review. Diagnostics. 2022 May 11;12(5):1202.
6. Preuss M, Werner P, Barthel H, Nestler U, Christiansen H, Hirsch FW, et al. Integrated PET/MRI for planning navigated biopsies in pediatric brain tumors. Child's Nerv Syst. 2014;30:1399–403
7. Sogani S, Jena A, Taneja S, Gambhir A, Mishra A, D'Souza M, et al. Potential for differentiation of glioma recurrence from radionecrosis using integrated 18 F fluoroethyl-L-tyrosine (FET) positron emission tomography/magnetic resonance imaging: A prospective evaluation. Neurol India. 2017;65(2):293

OP- V/55

Evaluation of the effectiveness of using various types of bypasses for complex MCA aneurysms over the past 10 years: analysis of our data and literature review.

Agaev Rasim[1], Andrei Dubovoy[1], Alexei Sosnov[1], Galina Moisak[1], Jamil Rzaev[1]

[1]FSBI "Federal Neurosurgical Center" Novosibirsk, Russia

Objectives: The aim of this research is to study the effectiveness of using various types of bypasses for complex aneurysms of the MCA region over the past 10 years.

Background: Some complex MCA aneurysms cannot be safely occluded without risking the parent artery or the branch vessels. In cases where a high risk of ischemic complications is known, bypass is required to prevent these complications. These days, the creation of various calibers bypasses are widely used in vascular neurosurgery.

Method: We retrieved and retrospectively analyzed the data of patients treated for complex aneurysms of the MCA region using different types of revascularization surgery at the Federal Neurosurgical Center (FNC) city of Novosibirsk between 2014 and 2022, and also we do literature review in period between 2009 and 2022. A total of 82 patients were selected from our center, and 18 articles from which 298 patients were selected.

Results: Of the 82 patients operated in our center, the bypass was patent in 97.5% of cases (80 patients), occlusion occurred in two cases, which was 2.43%. Of the 298 patients selected according to the literature review, it was found that the bypass was patent in 90.93% of cases (271 patients), occlusion occurred in 9.06% (27 patients). A total of 90 cases of complications were identified.

Results of literature review data and our center

№	Authors	N of patients	occlusion	ischemia	hemorrhage	lethal outcomes	other
1	Rabih Aboukais, Barbara Verbraeken 2019	4	0	0	0	0	0
2	Long Wang, MD, PhD, Shuaibin Lu, MD 2017	6	1	1	0	0	0
3	Ali Tayebi Meybodi, Michael T Lawton 2017	30	3	1	0	0	0
4	Long Wang Shuaibin Lu Li Cai, Xiang'en Shi 2019	12	2	4	1	0	0

5	Amin-Hanjani, S., Alaraj, A. & Charbel, F.T. 2010	7	0	0	0	0	0
6	Lee CH,. Ci Ji Yi Xue Za Zhi. 2018	6	0	0	0	0	0
7	Wessels, L., Fekonja, L.S. & Vajkoczy, P. 2019	50	2	0	1	2	0
8	Peng Hu Hong, Qi Zhang Xiao 2019	6	0	1	0	0	0
9	Aboukaisa,b,,T.Menovskyc 2021	3	0	0	0	0	0
10	Kivipelto L, Niemelä M 2014	24	2	6	6	1	2 skin necrosis (STA), 5 meningitis, 6 pneumonia, 1 deep vein thrombosis
11	Yuri Pilipenko, Sergey Arustamyan 2021	19	7	4	0	0	0
12	Wei Ni, Heng Yang, Ying Mao, 2019	43	5	0	0	0	0
13	Feng Xu, Michael T. Lawton, 2018	10	1	1	0	0	1 vasospasm, 1 cerebral edema
14	Wonhyoung Park, Byung Duk Kwun, 2017	12	0	3	1	0	0
15	Hung Manh Ngo, Lieu Van Nguyen, 2021	4	0	0	0	0	0
16	Bo-Ra Seo, Soo Han Kim, 2009	9	0	2	0	1	0
17	Sabareesh K. Natarajan, Laligam N. Sekhar, 2019	43	2	5	1	1	0
18	Fumihiro Matano, Akira Teramoto, 2013	10	2	5	0	0	0
19	FNC Novosibirsk	82	2	13	2	0	0

Conclusions: This report presents the data of our center and the worldwide literature, which show that the treatment of complex MCA aneurysms using various types of bypasses has good results with a minimum percentage of complications. This suggests that it is necessary to use

this technique, but it is also worth considering the complexity of the operation, which requires good preparation and more practice by the surgeon.

Keywords: Giant MCA aneurysms, bypass, high-flow bypasses, Cerebral revascularization

References

1. **Aboukais R, Verbraeken B, Leclerc X, Gautier C, Vermandel M, Bricout N, Lejeune JP, Menovsky T. Protective STA-MCA bypass to prevent brain ischemia during high-flow bypass surgery: case series of 10 patients. Acta Neurochir (Wien). 2019 Jun;161(6):1207-1214.**
2. **Wang L, Lu S, Qian H, Shi X. Internal Maxillary Artery Bypass with Radial Artery Graft Treatment of Giant Intracranial Aneurysms. World Neurosurg. 2017 Sep;105:568-584.**
3. **Tayebi Meybodi A, Huang W, Benet A, Kola O, Lawton MT. Bypass surgery for complex middle cerebral artery aneurysms: an algorithmic approach to revascularization. J Neurosurg. 2017 Sep;127(3):463-479.**

OP- V/56

The Outcome Of Surgical Management Of Post-Infectious Hydrocephalus With Multiple Intraventricular Septations

Mohamed Mohsen Amen[1], mahmoud saad[1], Ahmed Zaher[1], Mohamed Badran[1], Amr Farid Khalil[1]

[1]Mansoura university hospitals
[2]Mansoura university hospitals

Objectives: We tried to modify some steps in the surgical procedure of complex hydrocephalic patients with multiple intraventricular septations aiming to simplify the complicated nature of this challenging disease , minimize the morbidity and mortality and decrease the rate of the need to repeat surgical interventions.

Background: Hydrocephalus with multiple intraventricular septations poses a challenging neurosurgical condition, often attributed to various etiological factors. The primary targets for management include controlling hydrocephalus, managing increased intracranial pressure symptoms, and reducing the risk of compartmentalization through proper management and anticipation of ventriculitis. Given its progressive nature, hydrocephalus with multiple intraventricular septations necessitates difficult surgical procedures that are often repeated over time due to the formation of new membranes within the decompressed loculi. These study findings may potentially aid in the diagnosis, treatment, and management of Post-Infectious Hydrocephalus with Multiple Intraventricular Septations.

Method: Medical records of 76 patients with post-infection hydrocephalus and multiple intraventricular septations who underwent endoscopic treatment were collected and analyzed.

Results: After confirming clearance of CSF infection, all patients underwent ventriculoscopic cyst fenestration and insertion of a ventriculoperitoneal shunt to create a single communicating system drained by one ventricular catheter. Fifty-five patients underwent De novo shunt implantation, while 20 patients required shunt revision. Endoscopy reduced the shunt revision rate from 3.4 per year before fenestration to 0.4 per year after fenestration. During the mean follow-up period of 7.7 months (range: 1-20 months), complications were reported in 13 patients (17.1%), including CSF leakage in eight (10.5%), VPS malfunction in five (6.5%), and two deaths (2.6%).

Conclusions: The authors concluded that neuroendoscopic fenestration with the aid of CSF drainage by intraventricular catheter is an effective treatment for managing multiloculated post-infection hydrocephalus with much lower rates of morbidity and mortality than traditional procedures.

Keywords: Fenestration, Cyst, Septations, Hydrocephalus

References

1. Gabbita A.C. and Raju S.: Management of Complex Hydrocephalus. Neurol India 2021; 69, Suppl S2:350-6.
2. Kalsbeck J.E., Desousa A.L., Kleiman M.B., Goodman J.M., And Franken E.A.: Compartmentalization Of The Cerebral Ventricles As A Sequela Of Neonatal Meningitis. J. Neurosurg. 1980; 52: 547-52.
3. Schultz P. and Leeds N.E.: Intraventricular septations complicating neonatal meningitis. J Neurosurg 1973; 38: 620-6.
4. Andresen M. and Juhler M.: Multiloculated hydrocephalus: A review of current problems in classification and treatment. Childs Nerv Syst 2012; 28: 357-62.
5. Akbari S.H., Holekamp T.F., Murphy T.M., Mercer D., Leonard J.R., Smyth M.D., Park T.S., and Limbrick D.D. Jr.: Surgical management of complex multiloculated hydrocephalus in infants and children. Childs. Nerv. Syst. 2015; 31 (2): 243-9.
6. David I Sandberg: Endoscopic management of hydrocephalus in pediatric patients: a review of indications, techniques, and outcomes. J Child Neurol 2008; 23(5):550–560
7. El-Tantawy M.D., M.H.: Endoscopic Fenestration of Multiloculated Post-Infection Hydrocephalus. The Medical Journal of Cairo University, 2018; 86: 2995-3002.
8. Eshra M.A.: Endoscopic management of septated, multiloculated hydrocephalus. Alexandria Journal of Medicine 2014; 50:123–126
9. Lewis A.I., Keiper G.L., and Crone K.R.: Endoscopic treatment of multiloculated hydrocephalus. J. Neurosurg.1995; 82: 780-5.

OP-I/57

The Mustafa K. Baskaya Laboratory: A Leading Global Training Center in the Post-Covid-19 Era

Abdullah Keles[1], Ufuk Erginoglu[1], Cagdas Ataoglu[1], Derin Tuna[1], Burak Ozaydin[1], Mustafa Kemal Baskaya[1]

[1]University of Wisconsin-Madison

Objectives: In this study, we aimed to present the contributions of Mustafa K. Baskaya Laboratory in global neurosurgery in the post-covid era and share our experiences as a rol model for other microneurosurgery training centers.

Background: The Mustafa K. Baskaya Laboratory(UW-Madison), serves as a central facility offering a unique chance for medical professionals worldwide to enhance their understanding of neuroanatomy and refine their microneurosurgical expertise1.

Mustafa K Baskaya Laboratory



Mustafa K Baskaya Laboratory

Method: After the Covid-19 pandemic, we started to accept international fellows in May 2021 after a year-long suspension, complying with pandemic regulations. In our laboratory, we offered (1) basic bypass training, (2) OR and Clinical Observership, (3) access to Baskaya Microneurosurgery Video Archive, (4) participation in research projects, (5) the opportunity to perform cadaveric dissections, (6) participation in our annual courses, (7) participation for all department meetings and events.

Results: Since May 2021, we have hosted 42 international research fellows and observers from 24 countries in our laboratory. %88 (37) of those trainees were from fifteen different LMICs whereas %12 (5) were from high-income countries. 40(%95) of them have successfully completed the Baskaya Microvascular Bypass Training Curriculum and got certified. All of the fellows had the opportunity to access Baskaya Microneurosurgery Video Archive and observe Dr. Baskaya and learn from him in both the OR and outpatient clinics. With the contributions of research fellows, 15 abstracts were submitted and presented at national/international

congress and some of them were published in journals afterward. 31(%74) of them were interested in working with cadavers. Since May 2021, ten hands-on cadaveric courses(Skull Base, Microanastosis, Spine, and Peripheric Nerve) and two research days were held in our facility with the participation of all our fellows.

Mustafa K Baskaya Laboratory Fellows



Since May 2021, we have hosted 42 international research fellows and observers from 24 countries in our laboratory. %88 (37) of those trainees were from fifteen different LMICs whereas %12 (5) were from high-income countries.

Conclusions: Mustafa K. Baskaya Laboratory will further continue to host international research fellows and observers to contribute to neurosurgeons from all over the world, especially from LMICs.

Keywords: global neurosurgery, neuroanatomy, microneurosurgery training, operative skills laboratory

References

1. Sayyahmelli S, Kessely YC, Chen X, et al. From Ibni Sina (Avicenna) to Present, History of International Fellowship and Observership: University of Wisconsin-Madison Experience. *Turk Neurosurg*. 2020 2020;30(2):159-162. doi:10.5137/1019-5149.Jtn.28738-19.0

OP- V/58

Lateral ventricular anatomy and surgery

Robert Shumkovski[1], Ivica Kocevski[1]

[1]Clinic for neurosurgery, University Clinical center Mother Teresa, Skopje, N. Macedonia.

Objectives: To present the anatomy of the lateral ventricles applicable for intraventricular surgery, as well as the various surgical approaches to the lateral ventricles

Background: The walls of the lateral ventricles can be the emerging site of growth for a variety of tumors, mostly of glial or neuroepithelial origin. Lateral ventricular tumors are rare lesions and very often they represent a significant technical challenge, especially for less experienced surgeons. The differential diagnosis is determined by tumor location in the ventricular system, clinical presentation, age of the patient, and the imaging characteristics of the lesion. Here we review the relevant anatomy and try to simplify the surgical approaches to this challenging region.

intraventricular tumor pre op

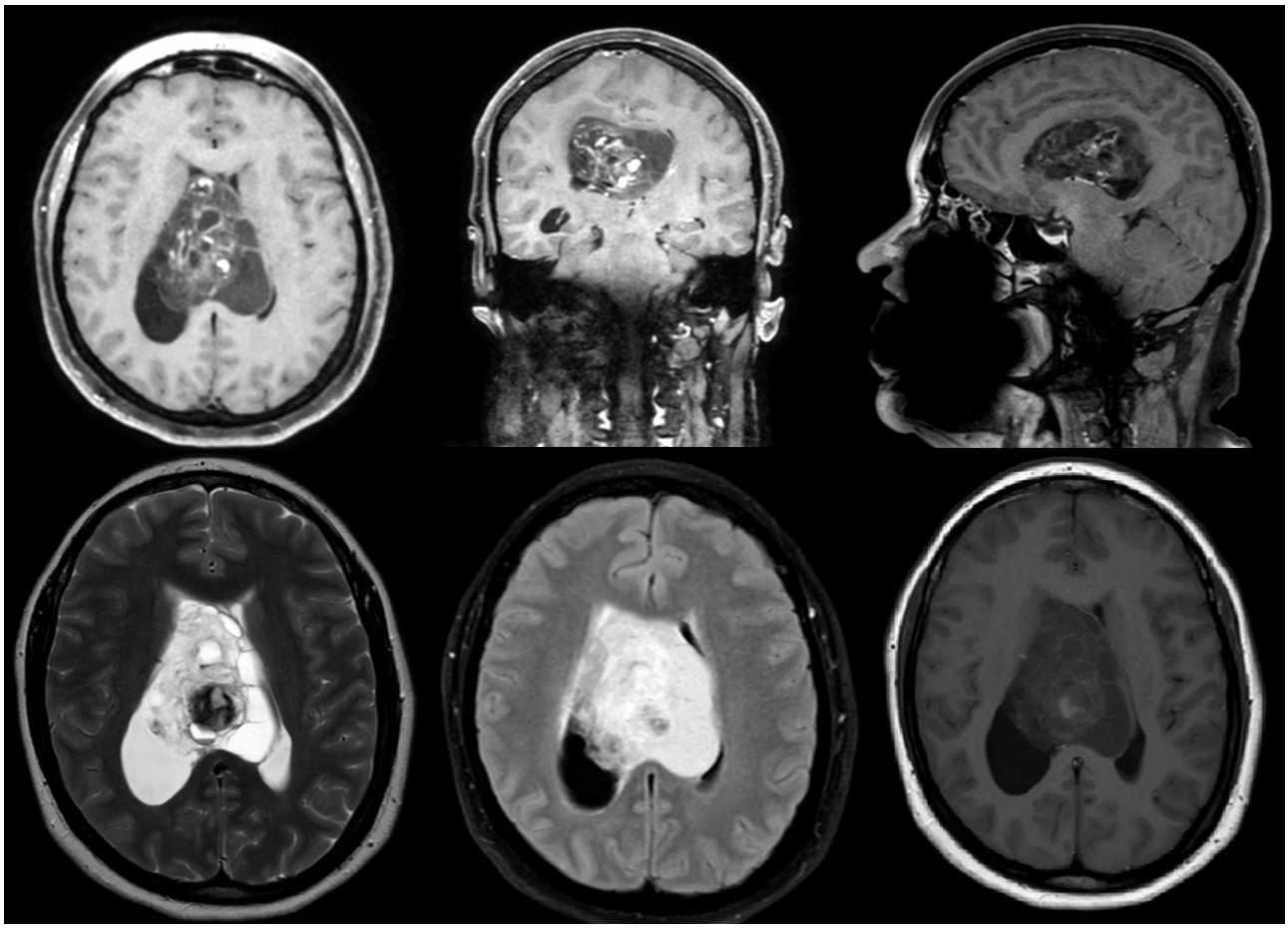

Intraventricular tumor pre op

anatomy of lateral ventricles

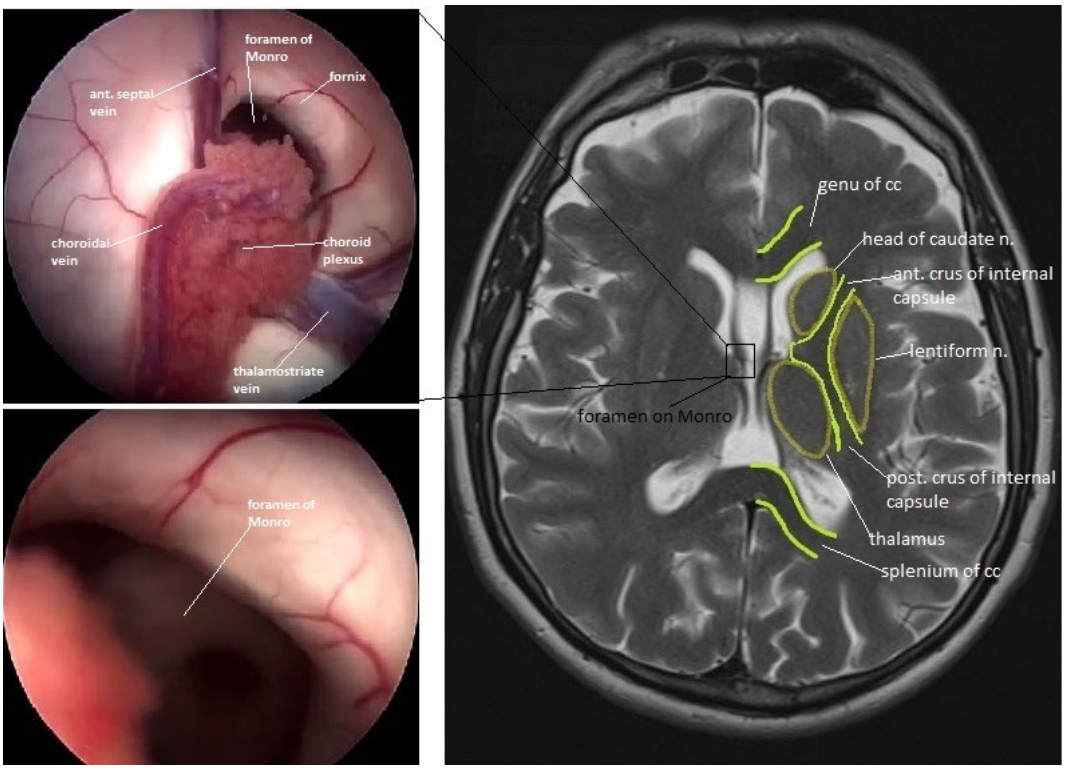

The anatomy of the lateral ventricles

Method: We present a single surgeon cases of interesting and technically challenging intraventricular tumors. All of these patients belongs to a different age group, with a different kind of tumor localized in the lateral ventricles.

Results: All of the patients survived, some with varying degrees of neurological deficits. The microsurgical approach, transcortical or transcallosal, seems to depend on the experience of the surgeon. Pros and cons are reviewed for each of the approaches. However, the surgical approach cannot be standardized, because the specific location, size, and vascularization of these deep-seated tumors are fundamental elements influencing the choice of surgical approach. Although access to the lateral ventricles may require additional preoperative considerations and planning, the combination of proper knowledge of the cortical and intraventricular anatomy with the familiarity and selection of an appropriate surgical approach will optimize the surgical outcome.

Intraventricular tumor post op

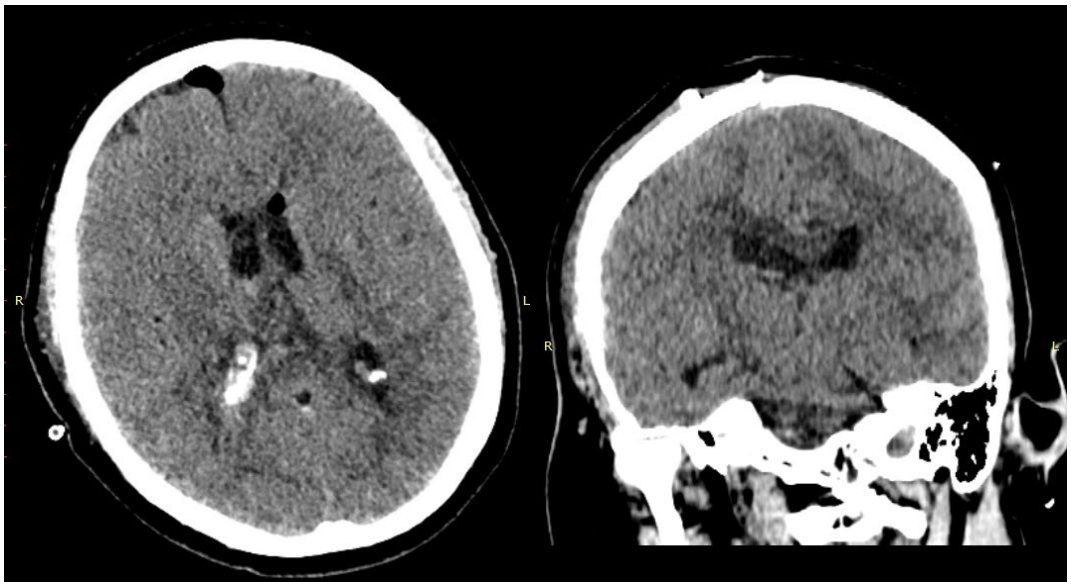

Intraventricular tumor post op

Conclusions: The majority of the lateral ventricular tumors are benign, with are relatively slow growth rate, although some of them can be malignant or even metastasis. The choice of approach, namely Interhemispheric transcallosal or transcortical approaches seemed to depend on the personal preferences and the experience of the surgeon.

Keywords: Lateral ventricles, ventricular tumor, transcortical approach, Transcallosal Approach

References

1. D'Angelo, Vincenzo A. M.D.; Galarza, Marcelo M.D.; Catapano, Domenico M.D.; Monte, Vincenzo M.D.; Bisceglia, Michele M.D.; Carosi, Illuminato M.D.. Lateral Ventricle Tumors: Surgical Strategies According to Tumor Origin and Development— A Series of 72 Cases. Operative Neurosurgery 56(1):p 36-45, January 2005. | DOI: 10.1227/01.NEU.0000144778.37256.EF
2. Rhoton, Albert L. Jr. M.D.. THE CEREBRUM. Neurosurgery 61(1):p SHC-37-SHC-119, July 2007. | DOI: 10.1227/01.NEU.0000255490.88321.CE
3. Rhoton, Albert L. Jr., M.D.. The Lateral and Third Ventricles. Neurosurgery 51(4):p S1-207-S1-271, October 2002.
4. Timurkaynak, Erdener M.D.; Rhoton, Albert L. Jr. M.D.; Barry, Margaret M.S.. Microsurgical Anatomy and Operative Approaches to the Lateral Ventricles. Neurosurgery 19(5):p 685-723, November 1986.
5. Yaşargil, M. Gazi M.D.; Abdulrauf, Saleem I. M.D.. SURGERY OF INTRAVENTRICULAR TUMORS. Neurosurgery 62(6):p SHC1029-SHC1041, June 2008. | DOI: 10.1227/01.NEU.0000316427.57165.01

OP- V/59

Microvascular decompression (MVD) of cranial nerves: surgical anatomy and technique

Jamil Rzaev[1]

[1]Federal Neurosurgical Center

Objectives: To define characteristics of different cranial nerves decompression types in cerebello-pontine angle (CPA).

Background: MVD is a golden standard in management of hyperfunctional syndromes of cranial nerves. There are special features in this "crowded" brain region in process of nerves exploration in CPA.

Method: 581 patients had been analyzed in our series from 2013 till 2022. The number of patients was proportioned as follows: Trigeminal neuralgia (TN) – 498; Hemifacial spasm (HFS) – 67; Vagoglassopharyngeal neuralgia – 9; Vestibulocochlear neuralgia – 1; Geniculate neuralgia – 6.

Results: CPA exploration was performed in patients with TN by two methods – rostral approach on upper-lateral cerebellum surface and "caudal" approach by arachnoid dissection over the VIII nerve. Offending vessel transposition was performed in 90% of cases, and interposition - in 10% of cases. In patients with HFS is necessary to perform decompression next to the brain stem. The vascular decompression of the IX-X nerves complex was performed in 4 cases of Vagoglassopharyngeal neuralgia and partial rhizotomy in 5 cases. In cases of geniculate neuralgia the XIII nerve was found in 4 patients and was excisioned. It was impossible to find the intermediate nerve in 2 patients; it passed directly within the VII nerve.

Conclusions: Hyperfunctional syndromes of cranial nerves in CPA may be conditionally divided into the following groups according to the efficiency level (relation "the best immediate result" to "recurrence"): 1 – a group of success – trigeminal neuralgia; 2 - the patients with HFS may be included into a group with a postponed result. The 3 group is a difficult group. Vagoglossopharyngeal neuralgia and geniculate neuralgia belong to rare diseases. This means that the possibility of misdiagnosis is high.

Keywords: Trigeminal neuralgia, hemifacial spasm, geniculate neuralgia, vago-glossopharyngeal neuralgia

OP-I/60

The Occipitalis Muscle as an Adjunct Superficial Landmark for the Transverse Sinus and Transverse Sigmoid Junction: Anatomical Study with Application to Posterior Cranial Fossa Surgery

Juan J. Cardona[3], Aishwarya Gilkes[1], Mathangi Rajaram-Gilkes[2], Francisco Reina[4], Ana Carrera[4], Joe Iwanaga[3], Aaron S. Dumont[3], Carmine Antonio Donofrio[5], Filippo Badaloni[6], Antonio Fioravanti[5], R. Shane Tubbs[3]

[1]Department of Anatomical Sciences, St. George's University, Grenada
[2]Department of Medical Education, Geisinger Commonwealth School of Medicine, Scranton, PA, USA
[3]Department of Neurosurgery, Tulane Center for Clinical Neurosciences, Tulane University School of Medicine, New Orleans, LA, USA
[4]Department of Medical Sciences, Clinical Anatomy, Embryology and Neurosciences Research Group, University of Girona, Girona, Spain
[5]Department of Neurosurgery, ASST Cremona, Cremona, Italy
[6]Department of Neurosurgery, IRCCS Istituto delle Scienze Neurologiche di Bologna, Bologna, Italy

Objectives: To investigate the potential of the occipitalis muscle, rarely mentioned in neurosurgical literature, as a superficial landmark for the transverse sinus (TS) and transverse-sigmoid sinus junction (TSJ).

Background: The occipitalis muscle (OM) is a very thin quadrangular-shaped muscle located on the posterolateral surface of the cranium, posteromedially to the pinnae. Although neuronavigation systems are widely used for identifying deep intracranial structures, additional superficial anatomical landmarks can be useful when this technology is not available or is not working properly.

Three dissections of the occipitalis muscle.

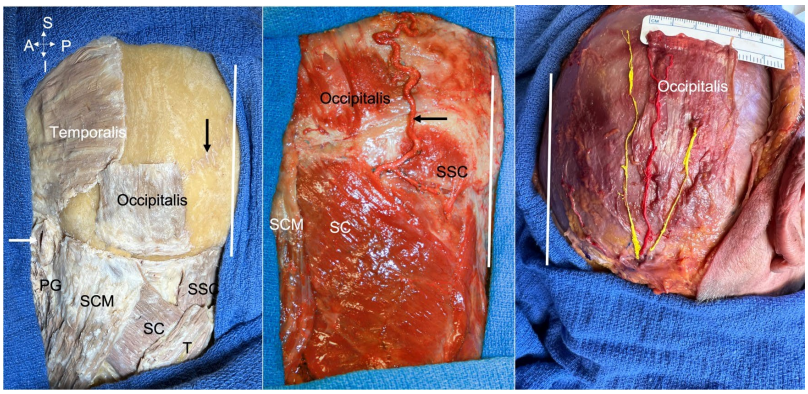

Left: The muscle borders of the left occipitalis are defined and its relationships to surrounding structures are shown; lambdoid suture (black arrow), external acoustic meatus (white arrow), parotid gland (PG), sternocleidomastoid (SCM), splenius capitis (SC), semispinalis capitis (SSC), trapezius (T). Middle: Left occipitalis muscle. Note the semispinalis capitis (SSC) and occipital artery (arrow). Right: Right occipitalis muscle. Note

the relationships between the occipitalis muscle and overlying occipital artery and greater occipital nerve. For each image, the vertical white line marks the midline

Method: Eighteen adult cadaveric heads underwent dissection. The borders of the occipitalis muscle were identified and measured. The muscle was then removed and the bone underlying the muscle drilled. The relationships between the occipitalis muscle and the underlying dural venous sinuses were then investigated by using a surgical microscope.

In the lateral position, the stepwise dissection of the occipitalis muscle.

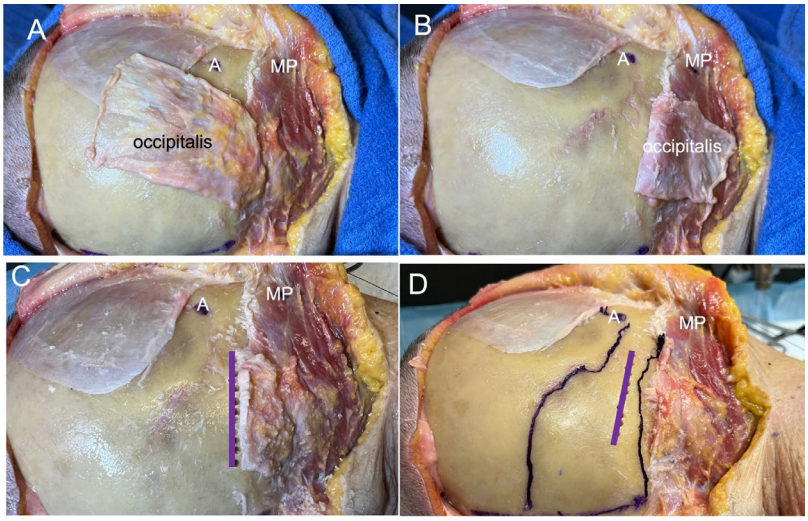

A. Note the muscle is intact the asterion (A) anteriorly positioned and the mastoid process (MP) seen inferolateral. B. The occipitalis is reflected while maintaining its inferiorly attachment. C. The inferior attachment of the muscle (purple line) has pilot holes drilled into the skull to identify this line's relationship to the underlying transverse sinus. D. The relationships between the inferior attachment of the occipitalis (straight purple line) and the lambdoid suture and superior nuchal line, the left and right of it, respectively. The midline is shown at the very bottom of the image as the horizontal purple line

Results: The occipitalis muscle is a quadrangular-shaped muscle, that invariably crosses the lambdoid suture, showing relationships with the TS inferiorly and the TSJ laterally. The medial border was located a mean of 2.7 cm from the midline and its lower edge was a mean of 1.6 cm above the TS. The inferior border was found between the lambdoid suture and the superior nuchal line in all the specimens. The medial half of the inferior margin was placed on average 1.1 cm superiorly to the TS while the lateral margin ran just above or over the TS. The lateral border was located a mean of 1.1 cm medially to the asterion and approximated the mastoid notch, being within 1-2 cm from it. The TSJ was between 2.1 and 3.4 cm lateral to occipitalis muscle lateral border.

Upper: Posterolateral view with the OM outlined (blue box) and schematic drawing of the left image. Bottom: Schematic drawing of the posterior occiput and left cadaveric dissection of the OM with the underlying skull removed.

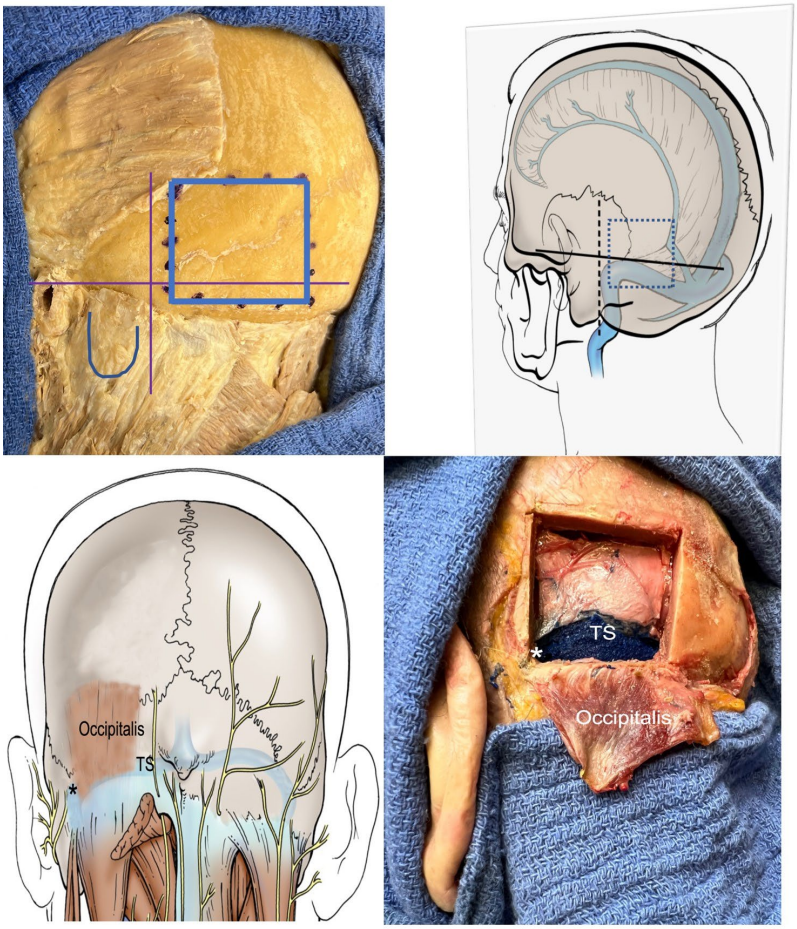

Upper left: The mastoid is outlined as well as the mastoid notch (vertical line) and zygomatic arch/inion line (horizontal line). Upper right: Note the underlying dural venous sinuses shown in blue. Also, the inferior border of the occipitalis (dotted box) overlies the transverse sinus and that its lateral edge in over the transverse sigmoid junction. Bottom left: Note the position of the occipitalis muscle and its superficial relationship inferiorly to the transverse sinus and TSJ (*). Bottom right: Note the relationship between the lower margin of the occipitalis attachment and the underlying transverse sinus (TS). The * marks the transverse sigmoid junction

Conclusions: A combination of superficial anatomical landmarks can be useful for surgical planning. We found that the occipitalis muscle represents a valuable aide for neurosurgeons and is a reliable landmark for the deeper lying TS and TSJ.

Keywords: Occipitalis muscle, Transverse sinus, Transverse sigmoid junction, Landmark

References

1. Duangthongpon P, Thanapaisal C, Kitkhuandee A, Chaiciwamongkol K, Morthong V (2016) The Relationships between asterion, the transverse-sigmoid junction, the superior nuchal line and the transverse sinus in Thai cadavers: surgical relevance. J Med Assoc Thai Suppl 5:S127-31
2. Doğan I, Özgüral O, Eroğlu Ü, Al-Beyati ESM, Kilinç CM, Cömert A, Uğur HÇ (2018) Preoperative exposure of sigmoid sinus trajectory in posterolateral cranial base approaches

using a new landmark through a neurosurgical perspective. J Craniofac Surg 29:220-225. https://doi.org/10.1097/SCS.0000000000004182
3. Hwang RS, Turner RC, Radwan W, Singh R, Lucke-Wold B, Tarabishy A, Bhatia S (2017) Relationship of the sinus anatomy to surface landmarks is a function of the sinus size difference between the right and left side: anatomical study based on CT angiography. Surg Neurol Int 8:58. https://doi.org/10.4103/sni.sni_351_16
4. Rui D, Wood BA (2012) Comparative anatomy and phylogeny of primate muscles and human evolution. CRC Press, Boca Raton, FL
5. Yildirim A, Adatepe T, Gunduz A, Yagiz O, Uzun N (2020) Occipitalis muscle: using for repetitive facial nerve stimulation in myasthenia gravis. Acta Neurol Belg 120:609-613. https://doi.org/10.1007/s13760-018-0889-9
6. Adatepe T, Gündüz A, Yildirim A, Uzun N (2017) Repetitive facial nerve stimulation using occipitalis muscle. J Clin Neurophysiol 34:348-352. https://doi.org/10.1097/WNP.0000000000000367
7. Uzun N, Adatepe T, Azizli E, Alkan Z, Yiğit Ö, Gündüz A, Karaali-Savrun F (2016) A novel muscle for electroneurography in peripheral facial palsy: occipitalis. Eur Arch Otorhinolaryngol 273:755-60. https://doi.org/10.1007/s00405-015-3569-x
8. Tubbs RS, Rizk E, Loukas M, Shoja M, Barbaro N, Spinner RJ (eds.) (2015) Nerves and nerve injuries: vol 2: pain, treatment, injury, disease and future directions. Elsevier, Philadelphia
9. Simons DG, Travell JG, Simons LS (1999) Travell & Simons' myofascial pain and dysfunction: upper half of body. Williams & Wilkins, Philadelphia, PA
10. Hall S, Peter Gan YC (2019) Anatomical localization of the transverse-sigmoid sinus junction: Comparison of existing techniques. Surg Neurol Int 10:186. https://doi.org/10.25259/SNI_366_2019
11. Li RC, Li K, Qi L, Xu GF, Xie WF, Wang MD, Bao G (2014) A novel reference coordinate system to locate the inferomedial point of the transverse-sigmoid sinus junction Acta Neurochir (Wien) 156:2209-13. https://doi.org/10.1007/s00701-014-2204-8
12. Ribas GC, Rhoton AL Jr, Cruz OR, Peace D (2005) Suboccipital burr holes and craniectomies. Neurosurg Focus 19:E1. https://doi.org/10.3171/foc.2005.19.2.2
13. Tubbs RS, Loukas M, Shoja MM, Bellew MP (2009) Surface landmarks for the junction between the transverse and sigmoid sinuses: application of the "strategic" burr hole for suboccipital craniotomy. Neurosurgery 65:37-41 https://doi.org/10.1227/01.NEU.0000341517.65174.63
14. Teranishi Y, Kohno M, Sora S, Sato H (2014) Determination of the keyhole position in a lateral suboccipital retrosigmoid approach Neurol Med Chir 54:261-6. https://doi.org/10.2176/nmc.oa2013-0020
15. Day JD, Kellogg JX, Tschabitscher M, Fukushima T (1996) Surface and superficial surgical anatomy of the posterolateral cranial base significance for surgical planning and approach. Neurosurgery 38:1079-83
16. Lang J, Samii A (1991) Retrosigmoidal approach to the posterior cranial fossa. An anatomical study. Acta Neurochir 111:147-53. https://doi.org/10.1007/BF01400505
17. Rhoton AL Jr (1996) Surface and superficial surgical anatomy of the posterolateral cranial base: significance for surgical planning and approach (comment). Neurosurgery 38:1083-4
18. Avci E, Kocaogullar Y, Fossett D, Caputy A (2003) Lateral posterior fossa venous sinus relationships to surface landmarks Surg Neurol 59:392-7 https://doi.org/10.1016/s0090-3019(03)00037-5
19. Kubo M, Mizutani T, Shimizu K, Matsumoto M, Iizuka K (2021) New methods for determination of the keyhole approach to avoid transverse-sigmoid sinus injury: proposition of the groove line as a new surgical landmark. Neurochirurgie 67:325-329. https://doi.org/10.1016/j.neuchi.2020.12.009
20. Iwanaga J, Watanabe K, Khan PA, Nerva JD, Amenta PS, Dumont AS, Tubbs RS (2020) The longissimus capitis insertion as a superficial landmark for the sigmoid sinus: an anatomical study. J Neurol Surg B Skull Base 83:28-32. https://doi.org/10.1055/s-0040-1716890

OP-III/61

Skull base approaches for intracranial aneurysms

Sabino Luzzi[1], Alice Giotta Lucifero[1]

[1]Department of Clinical-Surgical, Diagnostic and Pediatric Sciences, University of Pavia, Pavia, Italy

Objectives: To review target exposure and surgical freedom of skull base approaches used for intracranial aneurysms.

Background: Skull base approaches allow early proximal and distal vascular control, shortening and widening of the surgical field, increasing surgical freedom to the target, and avoiding brain retraction. All these aspects are essential for intracranial aneurysm surgery.

Method: An extensive literature review of anatomic morphometric studies of skull base approaches used for intracranial aneurysms was performed.

Results: Ophthalmic aneurysms require differential diagnosis between the true ophthalmic type and the dorsal internal carotid type, as the former can be treated with optic foraminotomy and the latter with anterior clinoidectomy. The cranio-orbito-zygomatic approach allows the treatment of high-rising basilar tip aneurysms, while the anterior petrosectomy and the pretemporal transcavernous approach allow the clipping of low-rising basilar tip aneurysms. Far lateral and transcondylar approaches are the cornerstones for vertebro-basilar junction, vertebral-artery-posterior inferior cerebellar artery, and proximal posterior inferior cerebellar artery aneurysms.

Conclusions: Perfect knowledge of the target exposure and surgical freedom of each anterior and posterior skull base approach is critical for clipping intracranial aneurysms.

Keywords: Anterior clinoidectomy, Paraclinoid aneurysms, Basilar tip, Cranio-orbito-zygomatic approach

References

1. Lai LT, O'Neill AH. History, Evolution, and Continuing Innovations of Intracranial Aneurysm Surgery. World Neurosurg. 2017 Jun;102:673-681. doi: 10.1016/j.wneu.2017.02.006.
2. Sekhar LN, Kalia KK, Yonas H, Wright DC, Ching H. Cranial base approaches to intracranial aneurysms in the subarachnoid space. Neurosurgery. 1994 Sep;35(3):472-81; discussion 481-3. doi: 10.1227/00006123-199409000-00016.

OP-I/62

Neuroanatomy Training with Photorealistic Dissection-Based Annotated 3D Models in Immersive Virtual Reality Environment.

Martin Trandzhiev[1], Theodoros Koundouras[2], Milko Milev[1], Lili Laleva[1], Atanas Mitev[2], Viktor Stoykov[2], Nikolay Dimitrov[2], Ivan Maslarski[2], Vladimir Nakov[1], Toma Spiriev[1]

[1]Department of Neurosurgery, Acibadem City Clinic University Hospital Tokuda, Sofia, Bulgaria
[2]Department of Anatomy and Histology, Pathology and Forensic Medicine, University Hospital Lozenetz, Medical Faculty, Sofia University, Sofia, Bulgaria

Objectives: To evaluate the potential benefits and disadvantages of photogrammetrically-scanned and annotated layered-dissection 3D models uploaded into immersive virtual reality for training in neuroanatomy.

Background: The human brain and spine's complex anatomy presents a challenge for both the learner and the teacher. The creation of photorealistic 3D models and their uploading into a Virtual Reality environment has the potential to greatly facilitate this process by creating a more engaging form of study not directly dependent on cadaver dissection practice, which is not readily available.

Method: Twenty-six medical students went through several combined exercises, featuring both conventional methods of teaching (2D atlases, lectures) along with time in an immersive and interactive VR environment with a large dataset of 3D photorealistic cadaver dissection models. A survey with 12 questions encompassing the subject was conducted to assess their experience and impressions of the method.

Photorealistic Skull Base Model

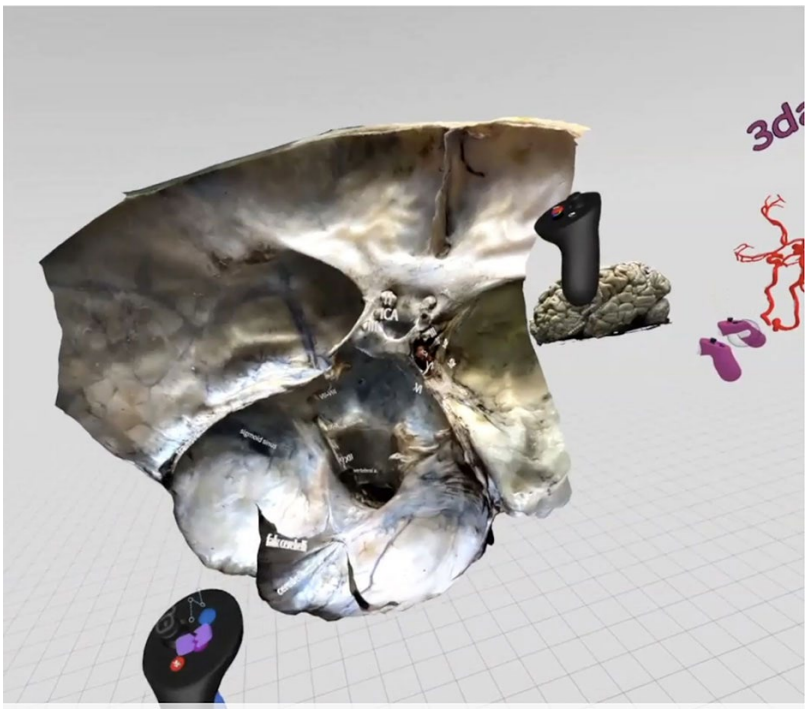

Examining a photorealistic, annotated model of the skull base. Major structures, such as the cranial nerves, sinuses, and the ICA are observed.

Virtual Lecture in Spatial

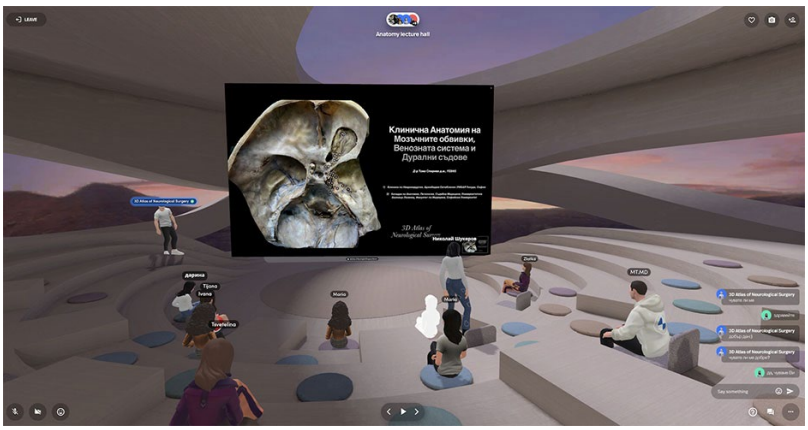

A group of students observing a virtual lecture on the Spatial platform, where the lecturer is presenting photorealistic 3D models.

Photorealistic Brain Hemisphere Dissection Model

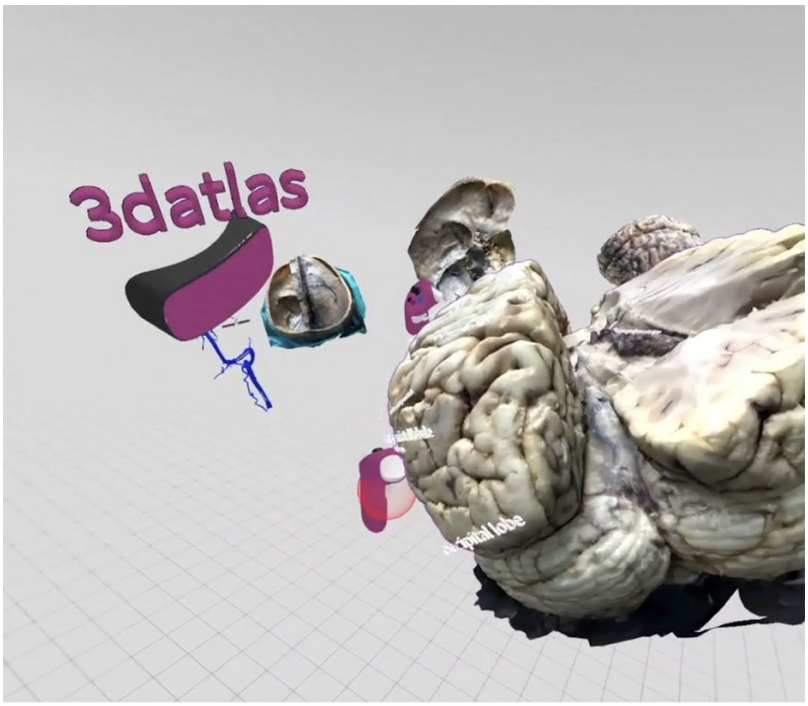

Examination of a model demonstrating an intact left and a dissected right hemisphere by 2 examiners simultaneously.

Results: Most students find virtual reality training more interactive and engaging (>96%) than conventional methods of training, as interactivity, good visualization due to photorealism, and the possibility to examine the models from multiple angles with the headset's control were the advantages most agreed upon (>80%). Approximately 23% of responders report some minor dizziness or discomfort and 38% report the limited time of use as the main disadvantage of the method. Most students (>92%) will recommend this form of neuroanatomy training and self-study in the future.

Advantages of the Method

Interactivity	21 (80.8%)
Easy to work with	15 (57.7%)
Good visualisation of the models	22 (84.6%)
Possibility to study the models from many points of view	22 (84.6%)
Sufficient variety of the models	16 (61.5%)
Enhanced motivation and engagement during work	15 (53.8%)
Neither of the above	0 (0%)

Tables showing the major advantages and and the number of students that agreed with each of the components.

Comparison to conventional methods

Very advantageous	16 (61.5%)
Advantageous	9 (34.6%)
Neutral	1 (3.8*)
Disadvantageous	0 (0%)
Very disadvantageous	0 (0%)

Chart showing the perceived advantageousness of the method for the medical students when compared to conventional methods.

Future recommendation

Very likely	18 (69.2%)
Likely	6 (23.1%)
Neutral	1 (3.8%)
Unlikely	1 (3.8%)
Very unlikely	0 (0%)

How likely is it that the medical student recommends the method to their fellow colleagues?

Conclusions: According to our survey, applying photorealistic 3D models in virtual reality to neuroanatomy education of medical students is useful and makes neuroanatomy training more interactive and engaging when compared to the conventional methods of teaching and self-study. Further study comparing VR training and conventional training as exam results will be useful to further test the effectiveness of the method.

Keywords: Neuroanatomy, Virtual Reality, Photorealistic, Education

References

1. Lopez M, Arriaga JGC, Nigenda Álvarez JP, et al. Virtual reality vs traditional education: Is there any advantage in human neuroanatomy teaching? *Computers & Electrical Engineering*. 2021;93:107282. doi:10.1016/j.compeleceng.2021.107282
2. Stepan K, Zeiger J, Hanchuk S, et al. Immersive virtual reality as a teaching tool for neuroanatomy. *Int Forum Allergy Rhinol*. 2017;7(10):1006-1013. doi:10.1002/alr.21986
3. Xu Y, Vigo V, Klein J, et al. Pursuing perfect 2D and 3D photography in neuroanatomy: a new paradigm for staying up to date with digital technology. *Journal of Neurosurgery*. 2022;1(aop):1-7. doi:10.3171/2022.9.JNS221988
4. Gurses ME, Gungor A, Hanalioglu S, et al. Qlone®: A Simple Method to Create 360-Degree Photogrammetry-Based 3-Dimensional Model of Cadaveric Specimens. *Oper Neurosurg (Hagerstown)*. 2021;21(6):E488-E493. doi:10.1093/ons/opab355
5. Vigo V, Pastor-Escartín F, Doniz-Gonzalez A, et al. The Smith-Robinson Approach to the Subaxial Cervical Spine: A Stepwise Microsurgical Technique Using Volumetric Models From Anatomic Dissections. *Oper Neurosurg (Hagerstown)*. 2020;20(1):83-90. doi:10.1093/ons/opaa265
6. Kournoutas I, Vigo V, Chae R, et al. Acquisition of Volumetric Models of Skull Base Anatomy Using Endoscopic Endonasal Approaches: 3D Scanning of Deep Corridors Via Photogrammetry. *World Neurosurg*. 2019;129:372-377. doi:10.1016/j.wneu.2019.05.251
7. Rubio RR, Shehata J, Kournoutas I, et al. Construction of Neuroanatomical Volumetric Models Using 3-Dimensional Scanning Techniques: Technical Note and Applications. *World Neurosurg*. 2019;126:359-368. doi:10.1016/j.wneu.2019.03.099
8. Rodriguez Rubio R, Xie W, Vigo V, et al. Immersive Surgical Anatomy of the Retrosigmoid Approach. *Cureus*. 2021;13(6):e16068. doi:10.7759/cureus.16068
9. Gurses ME, Hanalioglu S, Mignucci-Jiménez G, et al. Three-Dimensional Modeling and Extended Reality Simulations of the Cross-Sectional Anatomy of the Cerebrum, Cerebellum, and Brainstem. *Oper Neurosurg (Hagerstown)*. Published online April 21, 2023. doi:10.1227/ons.0000000000000703
10. Gurses ME, Gungor A, Gökalp E, et al. Three-Dimensional Modeling and Augmented and Virtual Reality Simulations of the White Matter Anatomy of the Cerebrum. *Oper Neurosurg (Hagerstown)*. 2022;23(5):355-366. doi:10.1227/ons.0000000000000361

OP- V/63

Evaluation of the effectiveness of neuromodulation in patients with drug-resistant epilepsy after unsuccessful surgical treatment.

Rasim Agaev[1], Fedor Efremov[1], Aleksandr Dmitriev[1], Galina Moisak[1], Jamil Rzaev[1]

[1]FSBI "Federal Neurosurgical Center" Novosibirsk, Russia

Objectives: The purpose of this study is to evaluate the effectiveness of neuromodulation in patients with drug-resistant epilepsy (DRE) after unsuccessful resective surgeries.

Background: Resection surgeries for DRE are highly effective and allow to achieve complete relief from seizures in most patients. 20-30% of patients have seizures after resective surgery. In these cases, we can talk about the failure of surgery. Such patients can be offered one of types of neuromodulation.

Method: We performed a retrospective analysis of data from 24 patients operated on at the Federal Center for Neurosurgery in Novosibirsk from 2014 to 2022, who underwent VNS or DBS therapy after unsuccessful surgery for DRE. The results were evaluated according to the Engels and McHugh scale.

Results: The mean follow-up period was 44.5 months. In the group of patients implanted with the VNS system (19 patient), the outcome of therapy in 13 patients (68.42%) was MH Ia-IIIb, in 6 (31.57%) MH IV-V. Of these, MH Ia-IIb in 3 (15.79%), MH IIIa-IIIb in 10 (52.63%). In the Hippocampal Depth Stimulation (HP-DBS) group (3 patient), 2 patients showed a reduction in seizure frequency by more than 50% from baseline during two years of follow-up. In one patient, there was no decrease in the frequency of seizures, but there was some relief in the severity of seizures. In the thalamic deep stimulation (ANT-DBS) group, 1 patient experienced a 60% reduction in seizure frequency and relief in seizure severity. In the second patient, there was no change in the frequency of seizures.

Results of neuromodulation

№	First surgery	Results of surgery by Engel scale	Second surgery/ Type of neuromodulation	Results after implantation of VNS/ decrease frequency of seizures after DBS	Third surgery/ Type of neuromodulation	Results after implantation of VNS/ decrease frequency of seizures after DBS
1	right side temporal lobe resection	Engel 4b	VNS	McHugh V	HP DBS	no change
2	left side temporal lobe resection, extended	Engel 4a	ANT DBS	>60%		
3	right side temporal lobe resection	Engel 4a	ANT DBS	no change		

4	right side temporal lobe resection	Engel 4a	HP DBS	>50%		
5	right side temporal lobe resection, extended	Engel 4b	HP DBS	>50%		
6	right side temporal lobe resection	Engel 3b	VNS	McHugh IA		
7	stereotactic callosotomy	Engel 4b	VNS	McHugh IIA		
8	stereotactic callosotomy	Engel 4b	VNS	McHugh IIB		
9	left side temporal lobe resection	Engel 3a	VNS	McHugh IIIB		
10	resection of epileptogenic zone right parietal lobe	Engel 4b	VNS	McHugh IIIB		
11	stereotactic callosotomy	Engel 4a	VNS	McHugh IIIA		
12	left side temporal lobe resection	Engel 4b	VNS	McHugh IIIA		
13	right side selective amygdalohippocampectomy, resection of epileptogenic zone right parietal lobe	Engel 4b	VNS	McHugh IIIA		
14	left side temporal lobe resection	Engel 4b	VNS	McHugh IIIA		
15	selective amygdalohippocampectomy, right side left side temporal lobe resection	Engel 4b	VNS	McHugh IIIA		
16	left side temporal lobe resection	Engel 3a	VNS	McHugh IIIB		
17	stereotactic callosotomy	Engel 4a	VNS	McHugh IIIB		
18	left side selective amygdalohippocampectomy, left side temporal lobe resection	Engel 4b	VNS	McHugh IIIB		

19	resection of ganglioglioma right fronto-parietal lobe	Engel 4b	VNS	McHugh IV		
20	stereotactic callosotomy	Engel 3b	VNS	McHugh V		
21	resection of epileptogenic zone left parietal lobe	Engel 4a	VNS	McHugh V		
22	stereotactic callosotomy	Engel 4a	VNS	McHugh V		
23	right side temporal lobe resection	Engel 4a	VNS	McHugh V		
24	resection of ganglioglioma right frontal lobe	Engel 4b	VNS	McHugh V		

Conclusions: According to our study, we can say that in cases where resective surgery did not bring the expected result, neuromodulation can significantly reduce the frequency of seizures and improve the quality of life in patients which get resective surgeries.

Keywords: neuromodulation, neurostimulation, Vagus nerve stimulation (VNS), Drug Resistant Epilepsy

References

1. Salanova V, Sperling MR, Gross RE, Irwin CP, Vollhaber JA, Giftakis JE, Fisher RS; SANTÉ Study Group. The SANTÉ study at 10 years of follow-up: Effectiveness, safety, and sudden unexpected death in epilepsy. Epilepsia. 2021 Jun;62(6):1306-1317.
2. Ryvlin P, Rheims S, Hirsch LJ, Sokolov A, Jehi L. Neuromodulation in epilepsy: state-of-the-art approved therapies. Lancet Neurol. 2021 Dec;20(12):1038-1047.
3. Vale FL, Ahmadian A, Youssef AS, Tatum WO, Benbadis SR. Long-term outcome of vagus nerve stimulation therapy after failed epilepsy surgery. Seizure. 2011 Apr;20(3):244-8.
4. Amar AP, Apuzzo ML, Liu CY. Vagus nerve stimulation therapy after failed cranial surgery for intractable epilepsy: results from the vagus nerve stimulation therapy patient outcome registry. Neurosurgery. 2004 Nov;55(5):1086-93.

OP- III/91

Photogrammetry for Reconstruction of High-Quality 3D Models to Aid Residents Education and Intraoperative Surgical Field Documentation and Measuring

Daniel Ballesteros-Herrera[1], José Alfonso Alvarez-Castro[1]

[1]National Institute of Neurology and Neurosurgery "Manuel Velasco Suarez"

Objectives: 1.Assess the ability to create 3D models of complex objects and scenes using photogrammetric techniques.2.Assess theability to apply photogrammetric techniques to real-world scenarios in residents' education and intraoperative surgical field documentation and measuring.

Background: Photogrammetry is a powerful tool for creating high-quality 3D models that can be used in medical education and intraoperative surgical field documentation and measuring. In the last years the advancements have been develop in medical fields as 3D printed prosthetics, and virtual imaging produced models. Unfortunately, the infrastructure needed for it is expensive and needs the aid of professionals involved in photography, 3D modeling, virtual reality building and huge servers to store information.

Method: Materials used were a cellphone with LiDAR technology and the software 3DScanner for image acquisition, and iMac with M1 processor, 8GB RAM memory for 3D processing. The most important step is image acquisition, performed with good illumination and at least 60-100 pictures taken in an ordered fashion. Posterior 3DScanner software is opened and image processing option is clicked. After some minutes depending on the complexity of the model, the model will appear, and some post processing could be performed in Sketchfab a program made to display 3D objects that is free and accessible.

Results: 56 models have been produced during the development of this technique. 31 intraoperatively (55%) and the rest inside the laboratory (45%) with several specimens. All models have VR and AR capabilities. Measurements were made in several models to compare with the real models with high precision. 25 students were challenged using the model with better understanding of 3D conception.

High definition photography of Skull



High-Quality 3D Model of Dissected Brain



High-Quality 3D Model of the Skull



Conclusions: Photogrammetry is a valuable technique that enhance medical education and improve patient outcomes. By providing detailed 3D models used for education and surgical planning, photogrammetry can help to improve the skills and knowledge of medical professionals, ultimately leading to better outcomes.

Keywords: Education, Neurosurgery, 3-D models. Photogrammetry, Reconstruction.

References

1. Barbero-García I, Lerma JL, Marqués-Mateu Á, Miranda P. Low-Cost Smartphone-Based Photogrammetry for the Analysis of Cranial Deformation in Infants. *World Neurosurg*. 2017;102:545-554. doi:10.1016/j.wneu.2017.03.015
2. Van Veelen MC, Jippes M, Carolina JA, et al. Volume measurements on three-dimensional photogrammetry after extended strip versus total cranial remodeling for sagittal synostosis: A comparative cohort study. *J Craniomaxillofac Surg*. 2016;44(10):1713-1718. doi:10.1016/j.jcms.2016.07.029

OP- V/65

Endoscopic Endonasal Accessibility and Maneuverability Around the Internal Carotid Artery from Distal Dural Ring to Foramen Lacerum: Cadaveric Study.

Alhusain Nagm[1]

[1]Department of Neurosurgery University of Maryland School of Medicine, Baltimore, MD, United States of America
[2]Department of Neurosurgery, Al-Azhar University School of Medicine, Cairo, Egypt.

Objectives: Understanding of eEEA restrictions and delivering advice for operating room.

Background: Expanded-endoscopic endonasal approaches (eEEA) to surgical targets around the internal carotid artery (ICA) remain inspiring and necessitate a special learning curve.

Method: Six formalin-fixed heads were dissected to study the 360° accessibility and manoeuvrability around ICAs from the distal dural ring (DDR) to the foramen lacerum (FL) on each side (n=12) via eEEA. The ICA course was divided into three segments: ICA in cavernous sinus (CS-ICA), paraclival-ICA and lacerum-ICA. Following total exposure of each ICA, the three-dimensional (3D= medial/lateral, superficial/deep and above/below) anatomical targets (n= 35) around each ICA were evaluated. The data were collected and analyzed.

Results: Distinctively, we included 35 anatomical targets (pertinent to CS-ICA, paraclival-ICA and lacerum-ICA were 16, 10, and 9, respectively) in 360° around every ICA (n=12) from the DDR to FL. Although reasonable visual validation was possible for all targets, microdissections were safely achievable for 19 targets (54.3%) through full or limited surgical freedom in 73.7% and 26.3%, respectively. In the remaining 45.7%, the accessibility to targets were abandoned due to hazardous manipulation. The most unreachable targets were around the lacerum-ICA (55.6%) with extremely restricted manoeuvrability (75%). Though, favourable accessibility (60%) and full surgical freedom (100%) were around the paraclival-ICA.

Figure 1

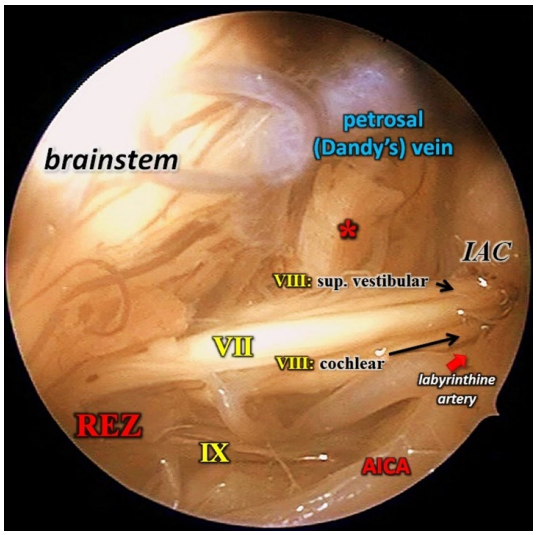

30° endoscopic video-captured view following cadaveric dissection. The beautiful arrangement of VII/VIII complex from the REZ: root entry/exit zone (REZ) of 9th cranial nerve (IX) to IAC with no access to lesion simulation (red *).

Figure 2

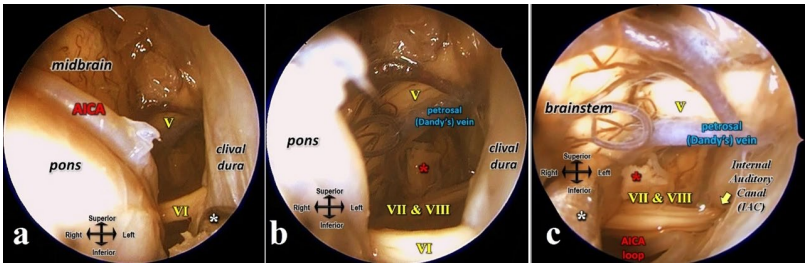

30° endoscopic video-captured view following cadaveric dissection. A) access to Dorello's canal with instruments (white *), VI, trigeminal nerve (V) and anterior inferior cerebellar artery (AICA). B) lesion simulation (red *) at the deepest point between V and facial-vestibulocochlear nerve complex (VII&VIII).C) restricted access to lesion simulation (red *) with instruments (white *) or internal auditory canal (IAC).

Conclusions: Succeeding eEEA with extensive skull base drilling that places neurovascular bundles at serious risk and scarifying selected blocking structures, 54.3%% of surgical targets around the ICA are reasonably maneuverable. Refining these facts promotes to the understanding of eEEA restrictions and delivering advice for operating room.

Keywords: Endoscopic Endonasal approach, Internal Auditory Meatus, Foramen lacerum, EEA

References

1. Nagm, Alhusain (2023) "Endoscopic Endonasal Accessibility and Maneuverability Around the Internal Carotid Artery from Distal Dural Ring to Foramen Lacerum: Cadaveric Study," *Al-Azhar International Medical Journal*: Vol. 4: Iss. 2, Article 31

OP-I/66

Proximal (A1 segment) anterior cerebral artery aneurysms: Clinico-Radiological Analysis, Review and Road ahead.

Waseem Ahamed TP[1], Kuntal Kanti Das[1]

[1]Sanjay Gandhi Postgraduate Institute, Lucknow

Objectives: •To analyse clinico-radiological, surgical characteristics of patients with Proximal Anterior cerebral artery aneurysm(ACAa) and review their classification,•Highlight need for future collaborative studies on A1 aneurysm in an august Neurosurgical Forum.

Background: Proximal anterior cerebral artery aneurysms(ACAa) are rare, constitute <1% of all intracranial aneurysms. They are smaller and prone to an early rupture needing aggressive intervention. Their relationship to the medial lenticulostriate perforators and the recurrent artery of Huebner determines the outcome. Data on proximal ACAa are limited by small sample sizes due to its rarity and multi centre collaborative studies will help throw further clarity on this entity.

Method: All surgically clipped aneurysms, operated by a single surgeon at a tertiary centre between 2015-2022, were analysed. Of the total 94 cases, four cases were Proximal ACAa. This is a retrospective subgroup analysis of these four patients (4.3%, mean age 42 years). The data collected included clinical features, computed tomography (CT) scan and CT-angiography /digital subtraction angiography findings, modified Hunt and Hess (H and H) grade, surgical steps and difficulties encountered. The pertinent literature related to the surgical nuances associated with dealing with A1 segment aneurysms is reviewed.

Results: The modified Hunt and Hess (H and H) grades in the 4 patients were: grade I in one, grade II in one, grade III in two patients. The mean ictus-surgery duration was 2.75 days (range: 1-4 days).. Multiple aneurysms were not seen in any patients. Surgical approach, location , clip characcters, intra-op rupture, post-op hydrocephalus , follow up, mRS were noted.

A1 segment ACA Aneurysm

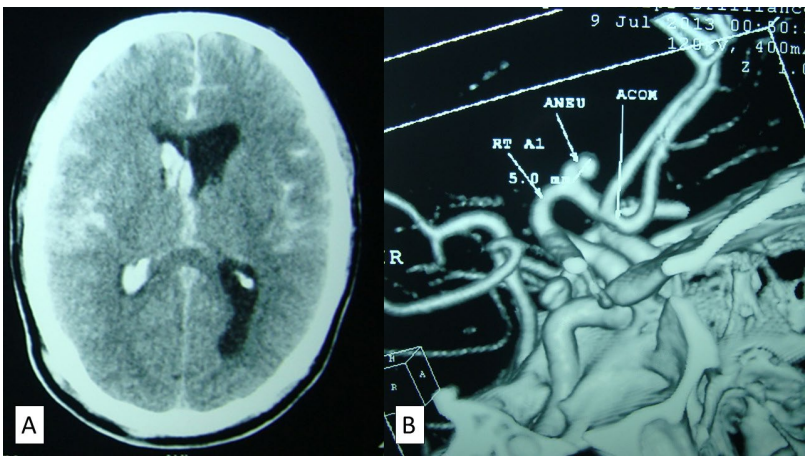

Plain CT scan showing diffuse subarachnoid haemorrhage along with intraventricular bleed. Ventriculomegaly is also present. The three dimensional reconstruction CT angiography showed a 5mm sacular aneurysm arising from the mid portion of A1 segment ACA. It is seen arising from the postero-superior surface of ACA and is directed superiorly.

Conclusions: Proximal ACAa are rare and are anatomically unique.. It is recommended to aggressively obliterate them. These pose technical challenges during their management due to their unique location, their fundi being surrounded by perforators and the unique morphology of the parent vessel. This study highlights the need for future collaborative studies on A1 aneurysm.

Keywords: Proximal A1 Segment, Aneurysm, Microsurgical clipping, Anterior cerebral artery.

References

1. Bhaisora KS, Behari S, Prasadh G, et al. A I-segment aneurysms: management protocol based on a new classification. *Neurol India*. 2014;62(4):410-416. doi:10.4103/0028-3886.141284
2. Dashti R, Hernesniemi J, Lehto H, et al. Microneurosurgical management of proximal anterior cerebral artery aneurysms. *Surg Neurol*. 2007;68(4):366-377. doi:10.1016/j.surneu.2007.07.084
3. Maiti TK, Bir S, Konar S, Bollam P, Cuellar-Saenz HH, Nanda A. Management of Proximal Anterior Cerebral Artery Aneurysms: Anatomical Variations and Technical Nuances. *World Neurosurg*. 2016;85:85-95. doi:10.1016/j.wneu.2015.07.022
4. Rhoton AL. The cerebrum. Anatomy. *Neurosurgery*. 2007;61(1 Suppl):37-118; discussion 118-119. doi:10.1227/01.NEU.0000255490.88321.CE
5. Fujiwara K, Saito K, Ebina T. Saccular aneurysm of the accessory middle cerebral artery--case report. *Neurol Med Chir (Tokyo)*. 2003;43(1):31-34. doi:10.2176/nmc.43.31
6. Rhoton AL, Rhoton AL, Congress of Neurological Surgeons. *Rhoton Cranial Anatomy and Surgical Approaches*. Lippincott Williams & Wilkins; 2003.
7. Wilkins L, Philadelphia, Pa. Osborn AG, Diagnostic Cerebral Angiography. *undefined*. Published online 1999. Accessed February 21, 2022. https://www.semanticscholar.org/paper/Osborn-AG%2C-Diagnostic-Cerebral-Angiography.-Wilkins-Philadelphia./79e294dcea080d365ed8659099eaa9cd24c50d0a
8. Rhoton AL, Saeki N, Perlmutter D, Zeal A. Microsurgical anatomy of common aneurysm sites. *Clin Neurosurg*. 1979;26:248-306. doi:10.1093/neurosurgery/26.cn_suppl_1.248
9. Microsurgical anatomy of the anterior cerebral artery in Indian cadavers Kedia S, Daisy S, Mukherjee KK, Salunke P, Srinivasa R, Narain MS Neurol India. Accessed February 21, 2022. https://www.neurologyindia.com/article.asp?issn=0028-3886;year=2013;volume=61;issue=2;spage=117;epage=121;aulast=Kedia
10. Suzuki M, Onuma T, Sakurai Y, Mizoi K, Ogawa A, Yoshimoto T. Aneurysms arising from the proximal (A1) segment of the anterior cerebral artery. A study of 38 cases. *J Neurosurg*. 1992;76(3):455-458. doi:3171/jns.1992.76.3.0455
11. Jang CK, Jang EW, Cho KC, et al. Radiographic and microsurgical characteristics of proximal (A1) segment aneurysms of the anterior cerebral artery. *Neurol Sci Off J Ital Neurol Soc Ital Soc Clin Neurophysiol*. 2018;39(10):1735-1740. doi:10.1007/s10072-018-3492-1
12. Mäurer J, Mäurer E, Perneczky A. Surgically verified variations in the A1 segment of the anterior cerebral artery. Report of two cases. *J Neurosurg*. 1991;75(6):950-953. doi:10.3171/jns.1991.75.6.0950

13. Friedlander RM, Oglivy CS. Aneurysmal subarachnoid hemorrhage in a patient with bilateral A1 fenestrations associated with an azygos anterior cerebral artery. Case report and literature review. *J Neurosurg*. 1996;84(4):681-684. doi:10.3171/jns.1996.84.4.0681
14. Taylor R, Connolly ES, Duong H. Radiographic evidence and surgical confirmation of a saccular aneurysm on a hypoplastic duplicated A1 segment of the anterior cerebral artery: case report. *Neurosurgery*. 2000;46(2):482-484. doi:10.1097/00006123-200002000-00042
15. Kwon WK, Park KJ, Park DH, Kang SH. Ruptured saccular aneurysm arising from fenestrated proximal anterior cerebral artery : case report and literature review. *J Korean Neurosurg Soc*. 2013;53(5):293-296. doi:10.3340/jkns.2013.53.5.293
16. Kachhara R, Nair S, Gupta AK. Fenestration of the proximal anterior cerebral artery (A1) with aneurysm manifesting as subarachnoid hemorrhage--case report. *Neurol Med Chir (Tokyo)*. 1998;38(7):409-412. doi:10.2176/nmc.38.409
17. Teal JS, Rumbaugh CL, Bergeron RT, Segall HD. Angiographic demonstration of fenestrations of the intradural intracranial arteries. *Radiology*. 1973;106(1):123-126. doi:10.1148/106.1.123
18. Kumar R, Behari S, Singh K, Sahu RN, Jaiswal AK. . Trilobulated fusiform aneurysm from proximal fenestrated segment of dominant A1 causing subarachnoid hemorrhage. *Neurol India*. 2013;61(3). doi:10.4103/0028-3886.115082
19. Wakabayashi T, Tamaki N, Yamashita H, Saya H, Suyama T, Matsumoto S. Angiographic classification of aneurysms of the horizontal segment of the anterior cerebral artery. *Surg Neurol*. 1985;24(1):31-34. doi:10.1016/0090-3019(85)90059-x
20. Wanibuchi M, Kurokawa Y, Ishiguro M, Fujishige M, Inaba K. Characteristics of aneurysms arising from the horizontal portion of the anterior cerebral artery. *Surg Neurol*. 2001;55(3):148-154; discussion 154-155. doi:10.1016/s0090-3019(01)00396-2
21. Kataoka K, Taneda M, Asai T, Kinoshita A, Ito M, Kuroda R. Structural fragility and inflammatory response of ruptured cerebral aneurysms. A comparative study between ruptured and unruptured cerebral aneurysms - PubMed. Accessed February 21, 2022. https://pubmed.ncbi.nlm.nih.gov/10390313/
22. Wilkinson IM. The vertebral artery. Extracranial and intracranial structure. *Arch Neurol*. 1972;27(5):392-396. doi:10.1001/archneur.1972.00490170024004
23. Czepko R, Libionka W, Lopatka P. Characteristics and surgery of aneurysms of the proximal (A1) segment of the anterior cerebral artery. *J Neurosurg Sci*. 2005;49(3):85-95.
24. Handa J, Nakasu Y, Matsuda M, Kyoshima K. Aneurysms of the proximal anterior cerebral artery. *Surg Neurol*. 1984;22(5):486-490. doi:10.1016/0090-3019(84)90308-2
25. Hino A, Fujimoto M, Iwamoto Y, Oka H, Echigo T. Surgery of proximal anterior cerebral artery aneurysms. *Acta Neurochir (Wien)*. 2002;144(12):1291-1296; discussion 1296. doi:10.1007/s00701-002-1014-6
26. Lee JM, Joo SP, Kim TS, Go EJ, Choi HY, Seo BR. Surgical management of anterior cerebral artery aneurysms of the proximal (A1) segment. *World Neurosurg*. 2010;74(4-5):478-482. doi:10.1016/j.wneu.2010.06.040
27. Yasargil, M. *Proximal Anterior Cerebral Artery Aneurysms. In: Clinical Considerations, Surgery of the Intracranial Aneurysms and Results. Vol 2. Thieme,Stuttgart, Germany; 1984:165–169.*
28. Zhang YY, Fang YB, Wu YN, et al. Angiographic Characteristics and Endovascular Treatment of Anterior Cerebral Artery A1 Segment Aneurysms. *World Neurosurg*. 2017;97:551-556. doi:10.1016/j.wneu.2016.08.117
29. Kim MK, Lim YC. Aneurysms of the Proximal (A1) Segment of the Anterior Cerebral Artery: A Clinical Analysis of 31 Cases. *World Neurosurg*. 2019;127:e488-e496. doi:10.1016/j.wneu.2019.03.178
30. Cho YD, Ahn JH, Jung SC, et al. Coil embolization in precommunicating (A1) segment aneurysms of anterior cerebral artery. *Neuroradiology*. 2014;56(3):219-225. doi:10.1007/s00234-014-1319-1

31. Singh V, Phadke RV. Endovascular treatment of A1 segment aneurysms. *Neurol India*. 2016;64(4):701-702. doi:10.4103/0028-3886.185383
32. Hirao J, Okamoto H, Watanabe T, Asano S, Teraoka A. Dissecting aneurysms at the A1 segment of the anterior cerebral artery--two case reports. *Neurol Med Chir (Tokyo)*. 2001;41(5):271-278. doi:10.2176/nmc.41.271
33. Park HS, Choi JH, Kang M, Huh JT. Management of aneurysms of the proximal (A1) segment of the anterior cerebral artery. *J Cerebrovasc Endovasc Neurosurg*. 2013;15(1):13-19. doi:10.7461/jcen.2013.15.1.13
34. Ding X, Nisson PL, James WS, et al. Aneurysms of the Proximal Segment of the Anterior Cerebral Artery: A New Classification System with Corresponding Therapeutic Options. *World Neurosurg*. 2017;104:291-302. doi:10.1016/j.wneu.2017.04.106
35. Yilmaz M, Kalemci O, Yurt A, Durmaz MO, Arda NM. Treatment of aneurysms arising from the proximal (A1) segment of the anterior cerebral artery. *Bosn J Basic Med Sci*. 2014;14(1):8-11. doi:10.17305/bjbms.2014.2282
36. Lehecka M, Niemelä M, Hernesniemi J. Surgical management of anterior cerebral artery aneurysms of the proximal (A1) segment. *World Neurosurg*. 2010;74(4-5):439-440. doi:10.1016/j.wneu.2010.07.032
37. Yaşargil MG, Yaşargil MG. *Microsurgical Anatomy of the Basal Cisterns and Vessels of the Brain, Diagnostic Studies, General Operative Techniques and Pathological Considerations of the Intracranial Aneurysms*. Thieme; 1984.
38. Sakamoto S, Ohba S, Shibukawa M, et al. Characteristics of aneurysms of the internal carotid artery bifurcation. *Acta Neurochir (Wien)*. 2006;148(2):139-143; discussion 143. doi:10.1007/s00701-005-0682-4
39. Aarabi B, Chambers J. Giant thrombosed aneurysm associated with an arteriovenous malformation. Case report. *J Neurosurg*. 1978;49(2):278-282. doi:10.3171/jns.1978.49.2.0278
40. Bakker SL, Hasan D, Bijvoet HW. Compression of the visual pathway by anterior cerebral artery aneurysm. *Acta Neurol Scand*. 1999;99(3):204-207. doi:10.1111/j.1600-0404.1999.tb07347.x
41. Drake CG, Peerless SJ, Ferguson GG. Hunterian proximal arterial occlusion for giant aneurysms of the carotid circulation. *J Neurosurg*. 1994;81(5):656-665. doi:10.3171/jns.1994.81.5.0656
42. Morota N, Kobayashi S, Sugita K, et al. Giant aneurysms of the horizontal segment of the anterior cerebral artery: report of two cases. *Neurosurgery*. 1991;29(1):97-101. doi:10.1097/00006123-199107000-00016
43. Juvela S, Porras M, Poussa K. Natural history of unruptured intracranial aneurysms: probability of and risk factors for aneurysm rupture. *J Neurosurg*. 2008;108(5):1052-1060. doi:10.3171/JNS/2008/108/5/1052
44. Wiebers DO, Whisnant JP, Huston J, et al. Unruptured intracranial aneurysms: natural history, clinical outcome, and risks of surgical and endovascular treatment. *Lancet Lond Engl*. 2003;362(9378):103-110. doi:10.1016/s0140-6736(03)13860-3
45. UCAS Japan Investigators, Morita A, Kirino T, et al. The natural course of unruptured cerebral aneurysms in a Japanese cohort. *N Engl J Med*. 2012;366(26):2474-2482. doi:10.1056/NEJMoa1113260
46. Chang HW, Youn SW, Jung C, et al. Technical strategy in endovascular treatment of proximal anterior cerebral artery aneurysms. *Acta Neurochir (Wien)*. 2011;153(2):279-285. doi:10.1007/s00701-010-0804-5
47. Yu B, Wu Z, Lv X, Liu Y, Sang M. Endovascular treatment of A1 segment aneurysms of the anterior cerebral artery. *Neurol India*. 2010;58(3):446-448. doi:10.4103/0028-3886.65538

48. Perlmutter D, Rhoton AL. Microsurgical anatomy of the anterior cerebral-anterior communicating-recurrent artery complex. *J Neurosurg*. 1976;45(3):259-272. doi:10.3171/jns.1976.45.3.0259
49. Lubicz B, Lefranc F, Levivier M, et al. Endovascular treatment of intracranial aneurysms with a branch arising from the sac. *AJNR Am J Neuroradiol*. 2006;27(1):142-147.
50. Xiaochuan H, Xiaoyun S, Youxiang L, Ning G, Wenshi G, Junsheng L. Endovascular Treatment of Unruptured A1 Segment Aneurysms. *Interv Neuroradiol*. 2013;19(2):186-194. doi:10.1177/159101991301900207
51. Li CY, Chen CC, Chen CT, et al. Endovascular Treatment of Ruptured Proximal Segment of the Anterior Cerebral Artery Aneurysms: Single-Center Experience and Literature Review. *World Neurosurg*. 2020;135:e237-e245. doi:10.1016/j.wneu.2019.11.135
52. Lee HY, Ahn JS, Suh DC, Lee DH. Z-shaped microcatheter tip shaping for embolization of aneurysms at the proximal A1 segment of the anterior cerebral artery: a technical note. *Neurointervention*. 2011;6(2):95-99. doi:10.5469/neuroint.2011.6.2.95
53. van Rooij WJ, Sluzewski M. Perforator infarction after placement of a pipeline flow-diverting stent for an unruptured A1 aneurysm. *AJNR Am J Neuroradiol*. 2010;31(4):E43-44. doi:10.3174/ajnr.A2034
54. Ko JK, Cha SH, Lee TH, Choi CH, Lee SW, Lee JI. Endovascular treatment of aneurysms arising from the proximal segment of the anterior cerebral artery. *J Korean Neurosurg Soc*. 2013;54(2):75-80. doi:10.3340/jkns.2013.2.75
55. Liu P, Lv X, Li Y, Lv M. Endovascular treatment of A1 aneurysms of the anterior cerebral artery. *Neurol India*. 2016;64(4):694-700. doi:10.4103/0028-3886.185405

OP-I/67

Endoscopic endonasal transpterygoid approach: anatomical description and surgical nuances

Joaquín Ignacio Marini[1], Juan Cruz Rodríguez Ferrero[1], Osvaldo San Martín García[1], Vanessa Milanese[1], Mateus Roghin[1]

[1]Beneficência Portuguesa de São Paulo

Objectives: Understand and study relevant anatomic landmarks encountered during endonasal transpterygoid approach (EETPA), addressing how these could be of use for preoperative planning. Also, we aim to identify the ones that could be adopted as a "safe reference" to prevent vascular lesions such as carotid rupture and which ones could be sacrificed or incised in order to provide surgical corridors to approach properly the targeted lesion.

Background: EETPA was first described to provide access to sphenoid sinus lateral recess although recent advances in endoscopy techniques allow approach to a variety of regions while ensuring excellent intraoperative visualization of anatomic structures and pathology. The minimally-invasive nature of the procedure allows for rapid postoperative recovery. Anatomy dissection fosters surgical skills thus reducing operative times and increasing possibilities of gross total resection.

Method: We dissected and perform EETPA in cadaveric specimens, including a wide nasoantral window. Photographic register of each surgical step was carried out, depicting vascular, neural and relevant anatomic landmarks. Intravascular injection of colored material was achieved using carotid injection technique.

Initial steps 2



Uncinate process, ethmoid bulla and maxilar sinus osteum below middle turbinate

Initial steps 1

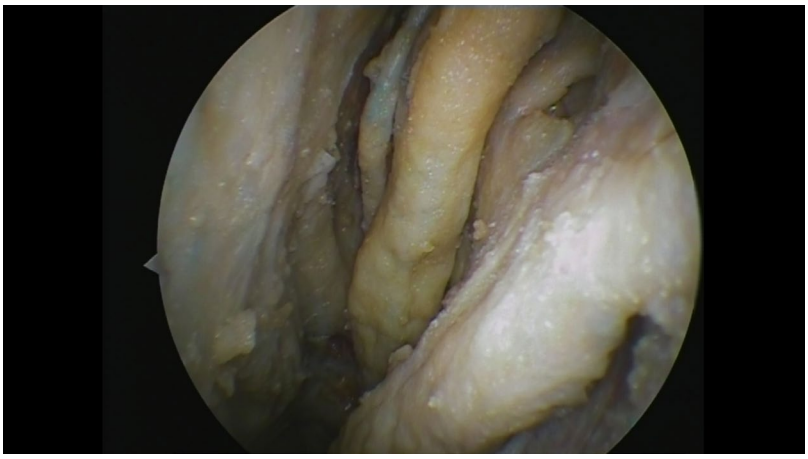

View of nasal cavity with inferior, middle and superior turbinates in its lateral wall

Results: Important landmarks are the posterior wall of the maxillary sinus, vidian foramen that leads to lacerum carotid artery, foramen rotundum remarking gasserian ganglion, sphenoidal identification of paraclival and parasellar internal carotid artery. A retrograde dissection of the sphenopalatine artery helped to identify the internal maxillary artery and its branches. The approach enables access to regions such as foramen lacerum, petrous ICA, petrous apex, Meckel's cave, cavernous sinus, lateral nasopharynx (fossa of Rosenmüller), pterygopalatine fossa and infratemporal fossa.

Conclusions: Anatomical models facilitate learning of the surgical anatomy and the acquisition of surgical skills in complex skull base areas such as pterygopalatine fossa. The EETPA should be performed with thorough recognition of key anatomic landmarks and surgical corridors in order to extend the approach to the targeted pathology while identifying and preventing nerve or vascular lesion.

Keywords: Endoscopic endonasal transpterygoid approach, surgical instruction, skull base anatomy

References

No conflicts of interest are declared by the authors.

1. Cavallo LM, Messina A, Gardner P, Esposito F, Kassam AB, Cappabianca P, et al: Extended endoscopic endonasal approach to the pterygopalatine fossa: anatomical study and clinical considerations. Neurosurg Focus 19(1):E5, 2005.
2. Falcon RT, Rivera-Serrano CM, Miranda JF, Prevedello DM, Snyderman CH, Kassam AB, et al: Endoscopic endonasal dissection of the infratemporal fossa: anatomic relationships and importance of eustachian tube in the endoscopic skull base surgery. Laryngoscope 121:31–41, 2011.
3. Fortes FS, Sennes LU, Carrau RL, Brito R, Ribas GC, Yasuda A, et al: Endoscopic anatomy of the pterygopalatine fossa and the transpterygoid approach: development of a surgical instruction model. Laryngoscope 118:44–49, 2008.
4. Freeman JL, Sampath R, Quattlebaum SC, Casey MA, Folzenlogen ZA, Ramakrishnan VR, et al: Expanding the endoscopic transpterygoid corridor to the petroclival region: anatomical study and volumetric comparative analysis. J Neurosurg 128:1855–1864, 2018.
5. Kasemsiri P, Solares CA, Carrau RL, Prosser JD, Prevedello DM, Otto BA, et al: Endoscopic endonasal transpterygoid approaches: anatomical landmarks for planning the surgical corridor. Laryngoscope 123:811–815, 2013.
6. Kassam AB, Vescan AD, Carrau RL, Prevedello DM, Gardner P, Mintz AH, et al: Expanded endonasal approach: vidian canal as a landmark to the petrous internal carotid artery. J Neurosurg 108:177–183, 2008.
7. Schmidt RF, Choudhry OJ, Raviv J, Baredes S, Casiano RR, Anderson Eloy J,et al: Surgical nuances for the endoscopic endonasal transpterygoid approach to lateral sphenoid sinus encephaloceles. Neurosurg Focus 32 (6):E5, 2012.
8. Kaen A, Cárdenas Ruiz-Valdepeñas E, Di Somma A, Esteban F, Márquez Rivas J and Ambrosiani Fernandez J: Refining the anatomic boundaries of the endoscopic endonasal transpterygoid approach: the “VELPPHA area” concept. J Neurosurg 131:911–919, 2019.
9. Pinheiro-Neto CD, Fernandez-Miranda JC, Rivera-Serrano CM, Paluzzi A, Snyderman CH, Gardner PA, et al: Endoscopic anatomy of the palatovaginal canal (palatosphenoidal canal): a landmark for dissection of the vidian nerve during endonasal transpterygoid approaches. Laryngoscope 122:6– 12, 2012.
10. Stamm AC, Mangussi- Gomes J: Transnasal endoscopic skull base and brain surgery. Surgical anatomy and its aplications. 2nd Ed. Thieme. 2019.
11. Al-Nashar IS, Carrau RL, Herrera A, Snyderman CH. Endoscopic transnasal transpterygopalatine fossa approach to the lateral recess of the sphenoid sinus. Laryngoscope 2004;114:528–532.

OP-III/68

Anatomy and Histology of the Petrous Carotid Membrane: Application to Skull Base Surgery

Juan J. Cardona[1], Scott A. McCraney[1], Devendra Shekhawat[1], Arada Chaiyamoon[2], Francisco Reina[3], Ana Carrera[3], Abuzer Güngör[4], Joe Iwanaga[1], Aaron S. Dumont[1], R. Shane Tubbs[1]

[1]Department of Neurosurgery, Tulane Center for Clinical Neurosciences, Tulane University School of Medicine, New Orleans, Louisiana, USA
[2]Department of Anatomy, Faculty of Medicine, Khon Kaen University, Khon Kaen, Thailand
[3]Medical Sciences Department. Clinical Anatomy, Embryology and Neurosciences Research Group. University of Girona, Girona, Spain
[4]Department of Neurosurgery, Bakirkoy Research and Training Hospital for Psychiatry, Neurology and Neurosurgery, Istanbul, Turkey

Objectives: This study aims to further investigate the membrane surrounding the internal carotid artery (ICA) on its course through the carotid canal via cadaveric dissection and histological examination.

Axial section of cadaveric specimens at the skull base noting the left and right internal carotid artery and surrounding membrane (arrows) lining the carotid canal.

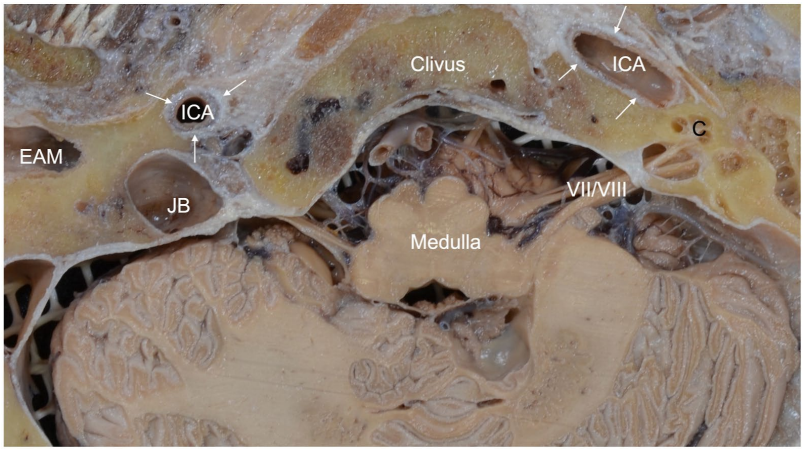

Note that the sectioning is more inferiorly placed on the right side so that the internal carotid artery is cut axially versus longitudinally on the left side. Note the facial/vestibulocochlear complex on the left and jugular bulb and external acoustic meatus on the right. The left cochlea is seen on the left side. ICA, internal carotid artery; VII/VIII, facial/vestibulocochlear complex; JB, jugular bulb; EAM, external acoustic meatus; C, cochlea.

Background: Published reports regarding the tissue types that surround the ICA as it travels through the carotid canal vary. Reports have variably defined this membrane as periosteum, loose areolar tissue, or dura mater. Understanding the exact course of the ICA through the petrous part of the temporal bone is important for reducing complications and iatrogenic injury. With such discrepancies and realizing that knowledge of this tissue might be important for

skull base surgeons who expose or mobilize the ICA at this location, the present study was performed.

Descriptions of the Membrane Surrounding the Petrous Part of the ICA.

Author(s)	Year	Petrous ICA Membrane Classification
Wilson et al.[9]	1856	Periosteum derived from dura mater
Gray[8]	1880	Dura mater
Paullus et al.[1]	1977	Periosteum
Quisling et al.[5]	1979	Periosteum
Leonetti et al.[4]	1990	Loose areolar tissue
Umansky et al.[10]	1994	Endosteal layer of dura mater
Bouthillier et al.[3]	1996	Periosteum
Ferreira et al.[6]	2002	Periosteum
Liu et al.[14]	2009	Periosteum
Desai et al.[7]	2017	Dura mater

Method: In 8 adult cadavers (16 sides), the contents of the carotid canal were evaluated; specifically, the membrane surrounding the petrous part of the ICA was studied, and its relationship to the deeper lying artery was observed. These specimens were stored in formalin and submitted for histological evaluation.

Results: Grossly, the membrane within the carotid canal traversed the entire carotid canal and was loosely adherent to the underlying petrous part of the ICA. Histologically, all membranes surrounding the petrous part of the ICA were consistent with dura mater. The dura mater of the carotid canal had an outer endosteal layer and an inner meningeal layer as well as a clear dural border cell layer in most specimens that approximated and was loosely applied to the adventitial layer of the petrous part of the ICA.

Axial section of the membrane surrounding the petrous part of the internal carotid artery.

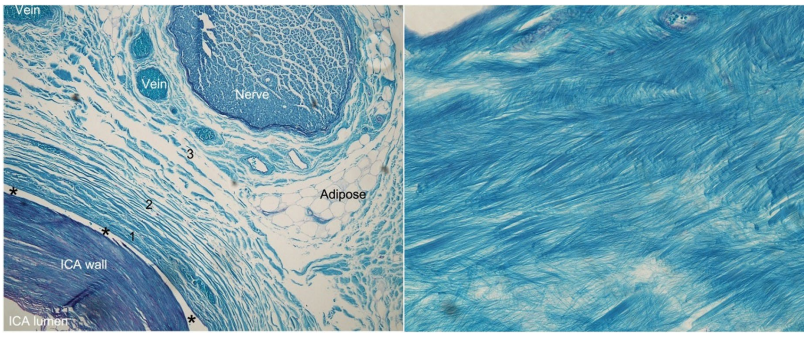

Left: Note the petrous part of the internal carotid artery (left corner), intervening space (asterisks), and overlying dura mater with a dural border layer (1), meningeal layer (2), and endosteal layer (3). Note the overlying sympathetic nervous plexus and venous plexus traveling in the endosteal layer of the dura mater. ICA, internal carotid artery. (Periodic acid–

Schiff counterstained for elastin, ×100). Right: Note the typical feathery appearance of the dura mater. (Periodic acid–Schiff, ×40).

Section of the dura mater surrounding the petrous part of the ICA.

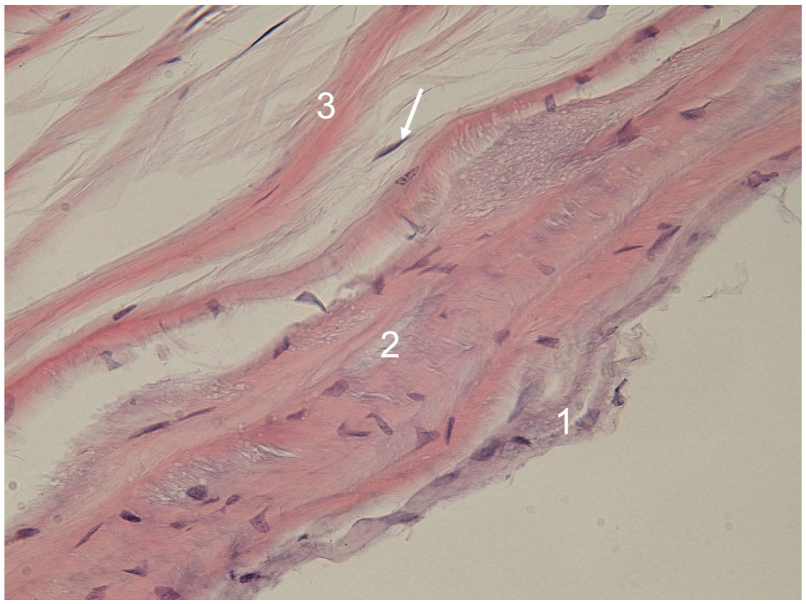

Note the dural border layer (1), meningeal layer (2), and endosteal layer (3). Note one of the fibroblast nuclei (arrow) in the outer endosteal layer. (Hematoxylin and eosin, ×100).

Conclusions: The membrane that surrounds the petrous part of the ICA is dura mater. To our knowledge, this is the first histological investigation of this structure and thus serves to establish the true identity of this membrane and correct previous reports in the literature that have erroneously concluded that it is periosteum or loose areolar tissue.

Keywords: Internal carotid artery, Morphology, Skull base, Temporal bone

References

1. Paullus WS, Pait TG, Rhoton AL. Microsurgical exposure of the petrous portion of the carotid artery. Journal of Neurosurgery. 1977;47(5):713-726.
2. Fischer E. Die Legeabweichungen der vorderen hirnarterie im gefässbild. Zentralbl Neurochir. 1938;3:300-313.
3. Bouthillier A, van Loveren HR, Keller JT. Segments of the internal carotid artery: a new classification. Neurosurgery. 1996;38(3):425-43
4. Leonetti JP, Smith PG, Linthicum FH. The petrous carotid artery: Anatomic relationships in skull base surgery. Otolaryngol Head Neck Surg. 1990;102(1):3-12.
5. Quisling RG, Rhoton AL. Intrapetrous carotid Artery Branches: Radioanatomic Analysis. Radiology. 1979;131(1):133-136.
6. Ferreira MAT, Spetzler RF, Preul MC, Zabamski JM, Deshmukh P, Feiz-Erfan I. Microsurgical Anatomy of the Anterior Cerebral Circulation: Part 1. The Infraclinoid Internal Carotid Artery. Barrow Neurological Institute. https://www.barrowneuro.org/for-physicians-researchers/education/grand-rounds-publications-media/barrow-quarterly/volume-18-no-2-2002/microsurgical-anatomy-of-the-anterior-cerebral-circulation-part-1-the-infraclinoid-internal-carotid-artery/. Published November 11, 2020. Accessed April 8, 2021.
7. Desai M, Rolls A, Girish G, Baker DM. Surgical Approaches to the Internal Carotid Artery at the Extracranial Middle Skull Base. Clin Surg. 2017;2:1551.
8. Gray H. Anatomy, Descriptive and Surgical. 9th ed. London: Longmans, Green, and Co.; 1880.
9. Wilson SE. Dissector's Manual of Practical and Surgical Anatomy. 3rd ed. Philadelphia, Pennsylvania: Blanchard and Lea; 1856.
10. Umansky F, Valarezo A, Elidan J. The superior wall of the cavernous sinus: a microanatomical study. *J Neurosurg*. 1994;81(6):914-920. doi:10.3171/jns.1994.81.6.0914
11. Protasoni M, Sangiorgi S, Cividini A, et al. The collagenic architecture of human dura mater. *J Neurosurg*. 2011;114(6):1723-1730. doi:10.3171/2010.12.jns101732
12. Allen MR, Hock JM, Burr DB. Periosteum: biology, regulation, and response to osteoporosis therapies. *Bone*. 2004;35(5):1003-1012. doi:10.1016/j.bone.2004.07.014
13. Junqueira LC, Mescher AL. *Junqueira's Basic Histology: Text and Atlas*. London: McGraw-Hill Medical Publishing; 2013.
14. Liu XD, Xu QW, Che XM, Mao RL. 2009. Anatomy of the petrosphenoidal and petrolingual ligaments at the petrous apex. Clinical Anatomy 22:302—306.

OP-III/71

Microsurgical resection of intracranial tumors with preoperative embolization: Retrospective analysis of a single center experience

Erkin Özgiray[1], Nevhis Akıntürk[1], Özde Şenol Akbulut[1], Kadri Emre Çalışkan[1], Mustafa Serdar Bölük[1], Hüseyin Biçeroğlu[1], Celal Çınar[2], Mehmet Sedat Çağlı[1], Taşkın Yurtseven[1], İsmail Oran[1]

[1]Ege University, Department of Neurosurgery
[2]Ege University, Department of Radiology

Objectives: 1. Preoperative embolization is still controversial2. Investigation of the safety and efficacy of preoperative embolization will be discussed.

Background: Preoperative embolization for hypervascular tumors is still a controversial procedure. However, it is a relatively safe method of reducing intraoperative bleeding. This study aims to investigate the safety and outcome of preoperative embolization in neurosurgical practice.

Method: In selected cases, arterial feeders of the tumor were embolized before surgical resection in a one or two-staged fashion at our institution. Clinical data, tumor characteristics, intraoperative bleeding, blood transfusion, decrease in hematocrit levels, and complications regarding embolization were collected retrospectively.

Results: From January 2016 to May 2023, 35 adult patients with intracranial tumors, which were evaluated as hypervascular lesions on pre-operative MRI, operated on with preoperative embolization, were enrolled in this study. 14 of the patients were male, and the mean age was 52.6. The most common pathology was meningioma (77,1%), followed by hemangioblastoma (11,4 %). 18 of the patients (51,4%) were treated in a one-staged fashion. The mean percentage of tumor devascularization was 85%, and gross total resection was achieved in 29 of the patients (82,8%). There was no major complication regarding the angiogram; however, one patient had skin necrosis due to embolization. The overall mean blood loss was 303,3 mL. The average decrease in hematocrit levels was 3,6 after the surgery. 17 (48,6%) of the patients received a blood transfusion.

Conclusions: Preoperative embolization is an effective method with selected hypervascular tumors. It helps to decrease intraoperative blood loss and facilitates tumor resection.

Keywords: meningioma, preoperative embolization, neurosurgery

References

Yin Y, Li Y, Jiang Z, Zhang C, Ge H, Chen Z, Hu R, Chen Y, Li X, Li F, Feng H. Clinical Outcomes and Complications of Preoperative Embolization for Intracranial Giant Meningioma Tumorectomy: A Retrospective, Observational, Matched Cohort Study. Front Oncol. 2022 Mar 8;12:852327. doi: 10.3389/fonc.2022.852327. PMID: 35350565; PMCID: PMC8957910.

OP-III/72

Multimodal use of contact endoscopy in neurosurgery: preliminary results and review of the literature

Francesco Carbone[1], Antonio Colamaria[2], Sergio Corvino[3], Matteo Sacco[4], Giorgio Iaconetta[5], Francesco Corrivetti[6], Domenico Di Maria[7], Giuseppe Catapano[7], Nicola Pio Fochi[8], Augusto Leone[1], Uwe Spetzger[1], Matteo de Notaris[7]

[1]Städtisches Klinikum Karlsruhe
[2]Policlinico "Riuniti"
[3]University Federico II
[4]IRCCS Ospedale Casa Sollievo della Sofferenza
[5]University of Salerno
[6]San Filippo Neri Hospital/ASL 1
[7]"San Pio" Hospital
[8]University of Foggia

Objectives: In this pilot study, we evaluate multimodal applications of contact endoscopy (CE) during a variety of endoscopic intracranial neurosurgical procedures.

Background: Originally adopted for the cytological screening of cervical and uterine cancer[1], CE is currently a well-established practice in different fields of oncological surgery.[2-4] In general, the CE method (up to 150x magnification power) was designed as an enhanced visualization technique, allowing to identify subtle microscopic changes pathognomonic of pre-cancerous and cancerous lesions in the early stage.[5]

Method: Twenty patients with several skull base lesions underwent surgery through different minimally invasive endoscopic approaches (endonasal, transorbital, and supraorbital). In all patients, CE was used to discriminate the pathology from the surrounding normal parenchyma by positioning the endoscope either in proximity or directly onto the target tissue. Particular attention was paid to the visualization of the margins of the lesion, to differentiate compression/displacement from infiltration of the normal surrounding tissue.

Results: With its unprecedented magnification range, CE could clearly identify the microvascular patterns and cytological architecture not detectable under simple white light endoscopy, without any reported damage secondary to heat transmission or iatrogenic injuries. All the lesions diagnosed as "presumed neoplastic tissue" by contact endoscopy were confirmed by histopathology. Applications in meningioma and pituitary adenoma surgeries yielded the most promising results due to the distinctive microvascular networks that these lesions host.

Dural infiltration in a case of planum sphenoidale meningioma

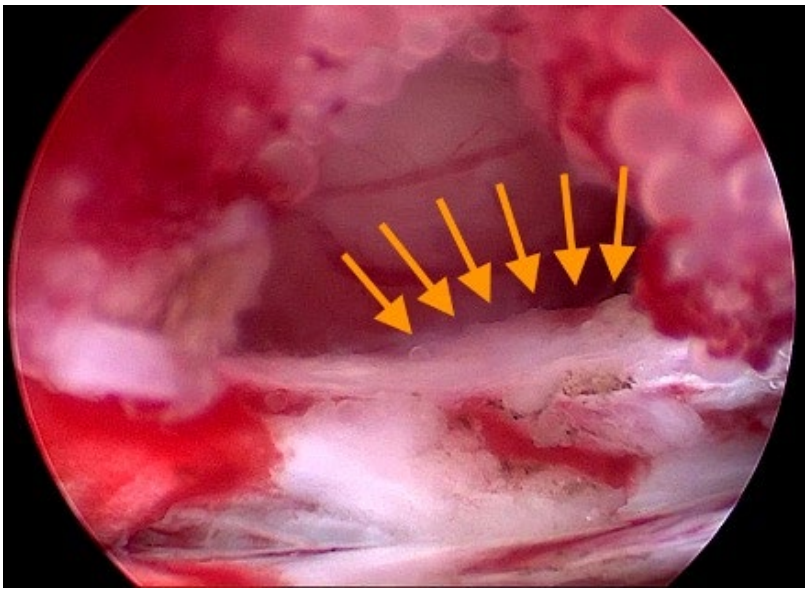

CE visualization following meningioma resection, showing the peculiar psammoma bodies in the upper part of the figure suggestive of the histological diagnosis and the dural infiltration of the meningioma, valuable information when performing these types of endoscopic surgeries (orange arrows).

Abnormal vascular architecture in a pituitary adenoma



Loose and disorganized structure of blood vessels characterizing the lesion contrasting with the archetypal vascular pattern of the normal pituitary

Temporal lobe metastasis from a pharyngeal tumor

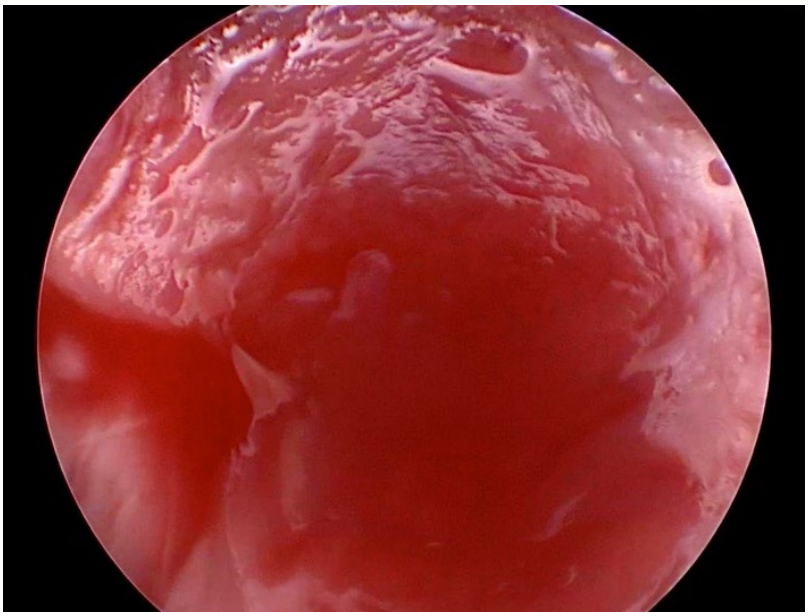

Close proximity CE demonstrating the peculiar edematous infiltrated dura adjacent to the tumor, further demonstrated by setting the endoscope directly on the tissue. In this case, a clear distinction of the tissues allowed a targeted biopsy to avoid false negative specimens.

Conclusions: CE represents a new and effective technique for the in vivo identification of pathological microvascular and tissue features, preserving normal parenchyma during different endoscopic approaches. The use of contact endoscopy improves diagnostic accuracy and could help the intraoperative decision-making process in establishing an accurate diagnosis and in guiding clinical management. CE has proved to be a valuable technical advancement in the armamentarium of endoscopic neurosurgeons and has the potential to become a critical tool for different applications in the field of neurosurgery.

Keywords: Contact endoscopy, skull base, neuroendoscopy, brain tumor

References

1. [1] Barbot J, Parent B, Dubuisson JB. Contact hysteroscopy: Another method of endoscopic examination of the uterine cavity. *American Journal of Obstetrics and Gynecology*. 1980;136(6):721-726. doi:10.1016/0002-9378(80)90447-0
2. [2] Guimarães AV, Brandão LG, Dedivitis RA. Contact endoscopy for identifying the parathyroid glands during thyroidectomy. *Acta Otorhinolaryngol Ital*. 2010;30(1):20-26.
3. [3] Andrea M, Dias O, Macor C, Santos A, Varandas J. Contact Endoscopy of the Nasal Mucosa. *Acta Oto-Laryngologica*. 1997;117(2):307-311. doi:10.3109/00016489709117793
4. [4] Eguchi H, Ishikawa O, Ohigashi H, et al. Real-time and the in vivo detection of minute cancer invasion to the portal-superior mesenteric vein using contact endoscopy during a pancreatic cancer resection. *The American Journal of Surgery*. 2009;198(5):e66-e71. doi:10.1016/j.amjsurg.2009.03.009
5. [5] Piazza C, D. Bon F, Peretti G, Nicolai P. 'Biologic endoscopy': optimization of upper aerodigestive tract cancer evaluation. *Current Opinion in Otolaryngology & Head & Neck Surgery*. 2011;19(2):67-76. doi:10.1097/MOO.0b013e328344b3ed

OP-I/73

Surgical Treatment of Selected Tumors via the Navigated Minimally Invasive Presigmoidal Suprabulbar Infralabyrinthine Approach without Rerouting of the Facial Nerve

Zafer Cinibulak[1]

[1]Department of Neurosurgery, Merheim Hospital/University of Witten/Herdecke, Cologne, Germany

Objectives: Here, we present our clinical experience with this approach for selected JFTs, with a particular focus on its efficacy and safety.

Background: The feasibility of a novel skull base approach, the navigated minimal ly invasive presigmoidal suprabulbar infralabyrinthine approach (NaMIPSI-A) without rerouting of the fallopian canal for selected jugular foramen tumors (JFTs), has been demonstrated in a neuroanatomical laboratory study.

Method: All patients with JFTs who were treated via the NaMIPSI-A were included in this study. The JFTs were classified according to a modified Fisch classification. The neurological and neuroradiological outcome, the extent of tumor resection, and the approach-related morbidity were examined.

Results: Five patients (two women, three men; mean age 57y, range 48-65) were available. According to the modified Fisch classification, two JFTs were graded as C1, one as De1 and two as De2. Gross total resection (GTR) was achieved in three patients and near-total resection (NTR) in two. Postsurgically, no new neurological deficits and no approach-related morbidity and mortality occurred. One case with a postoperative cerebrospinal fluid leak was managed successfully with lumbar drainage. During the follow-up period (mean 67,6 months, range 12-119 months) tumor recurrence was noted in the NTR group but not in the GTR group.

Conclusions: The NaMIPSI-A to the jugular foramen without rerouting of the fallopian canal is highly valuable for selected tumors of the jugular foramen. It is less invasive than other skull approaches, and it allows safe and complete tumor removal in appropriate patients.

Keywords: infralabyrinthine approach, jugular foramen, neuronavigation, tumor

References

1. Angeli SI, De la Cruz A, Hitselberger W (2001) The transcochlear approach revisited. Otol Neurotol 22 (5):690-695. https://doi.org/10.1097/00129492-200109000-00023
2. Ayeni SA, Ohata K, Tanaka K, Hakuba A (1995) The microsurgical anatomy of the jugular foramen. J Neurosurg 83 (5):903-909. https://doi.org/10.3171/jns.1995.83.5.0903
3. Bambakidis NC, Gonzalez LF, Amin-Hanjani S, Deshmukh VR, Porter RW, Daspit PC et al. (2005) Combined skull base approaches to the posterior fossa. Technical note. Neurosurg Focus 19 (2):8. https://doi.org/10.3171/foc.2005.19.2.9

4. Basma J, Michael LM, Sorenson JM, Robertson JH (2019) Deconstruction of the Surgical Approach to the Jugular Foramen Region: Anatomical Study. J Neurol Surg B Skull Base 80 (5):518-526. https://doi.org/10.1055/s-0038-1676512
5. Bruneau M, George B (2008) The juxtacondylar approach to the jugular foramen. Neurosurgery 62 (3 Suppl 1):75-80; discussion 80. https://doi.org/10.1227/01.neu.0000317375.38067.55
6. Bulsara KR, Sameshima T, Friedman AH, Fukushima T (2008) Microsurgical management of 53 jugular foramen schwannomas: lessons learned incorporated into a modified grading system. J Neurosurg 109 (5):794-803. https://doi.org/10.3171/JNS/2008/109/11/0794
7. Chen QQ, Liu Y, Chang CD, Xu YP (2019) Chordoma located in the jugular foramen: Case report. Medicine (Baltimore) 98 (21):e15713. https://doi.org/10.1097/MD.0000000000015713
8. Cinibulak Z, Krauss JK, Nakamura M (2013) Navigated minimally invasive presigmoidal suprabulbar infralabyrinthine approach to the jugular foramen without rerouting of the facial nerve. Neurosurgery 73 (1 Suppl Operative):3-15. https://doi.org/10.1227/NEU.0b013e31827fca8c
9. Constanzo F, Coelho Neto M, Nogueira GF, Ramina R (2020) Microsurgical Anatomy of the Jugular Foramen Applied to Surgery of Glomus Jugulare via Craniocervical Approach. Front Surg 7 27. https://doi.org/10.3389/fsurg.2020.00027
10. Constanzo F, Gerhardt J, Ramina R (2019) How I do it: retrosigmoid suprajugular approach to the jugular foramen. Acta Neurochir (Wien) 161 (11):2271-2274. https://doi.org/10.1007/s00701-019-04030-z
11. David CA (2005) Preoperative planning and surgical approaches to tumors of the jugular foramen. Operative Techniques in Neurosurgery 8 (1):19-24. https://doi.org/10.1053/j.otns.2005.08.003
12. Fisch U (1982) Infratemporal fossa approach for glomus tumors of the temporal bone. Ann Otol Rhinol Laryngol 91 (5 Pt 1):474-479. https://doi.org/10.1177/000348948209100502
13. Fisch U (1984) Infratemporal fossa approach for lesions in the temporal bone and base of the skull. Adv Otorhinolaryngol 34: 254-266. https://doi.org/10.1159/000409856
14. Fukuda M, Oishi M, Saito A, Fujii Y (2009) Long-term outcomes after surgical treatment of jugular foramen schwannoma. Skull Base 19 (6):401-408. https://doi.org/10.1055/s-0029-1220197
15. George B, Tran PB (2000) Surgical resection of jugulare foramen tumors by juxtacondylar approach without facial nerve transposition. Acta Neurochir (Wien) 142 (6):613-620. https://doi.org/10.1007/s007010070103
16. Griessenauer CJ, McGrew B, Matusz P, De Caro R, Loukas M, Tubbs RS (2016) Surgical Approaches to the Jugular Foramen: A Comprehensive Review. J Neurol Surg B Skull Base 77 (3):260-264. https://doi.org/10.1055/s-0035-1567863
17. Guinto G, Kageyama M, Trujillo-Luarca VH, Abdo M, Ruiz-Than A, Romero-Rangel A (2014) Nonglomic tumors of the jugular foramen: differential diagnosis and prognostic implications. World Neurosurg 82 (6):1283-1290. https://doi.org/10.1016/j.wneu.2014.07.013
18. Hermann EJ, Petrakakis I, Polemikos M, Raab P, Cinibulak Z, Nakamura M et al. (2015) Electromagnetic navigation-guided surgery in the semi-sitting position for posterior fossa tumours: a safety and feasibility study. Acta Neurochir (Wien) 157 (7):1229-1237. https://doi.org/10.1007/s00701-015-2452-2
19. House WF, De la Cruz A, Hitselberger WE (1978) Surgery of the skull base: transcochlear approach to the petrous apex and clivus. Otolaryngology 86 (5):770-799. https://doi.org/10.1177/019459987808600522
20. House WF, Hitselberger WE (1976) The transcochlear approach to the skull base. Arch Otolaryngol 102 (6):334-342. https://doi.org/10.1001/archotol.1976.00780110046004

21. Ito S, Saegusa T, Ozawa Y, Higuchi Y, Iwadate Y, Serizawa T et al. (2019) Function-Preserving Multimodal Treatment for Jugular Foramen Meningiomas. J Neurol Surg B Skull Base 80 (3):239-243. https://doi.org/10.1055/s-0038-1668137
22. Jackson CG, Glasscock ME, Harris PF (1982) Glomus Tumors. Diagnosis, classification, and management of large lesions. Arch Otolaryngol 108 (7):401-410. https://doi.org/10.1001/archotol.1982.00790550005002
23. Kamitani H, Masuzawa H, Kanazawa I, Kubo T, Tokuyama Y (1994) A combined extradural-posterior petrous and suboccipital approach to the jugular foramen tumours. Acta Neurochir (Wien) 126 (2-4):179-184. https://doi.org/10.1007/BF01476430
24. Katsuta T, Rhoton AL, Matsushima T (1997) The jugular foramen: microsurgical anatomy and operative approaches. Neurosurgery 41 (1):149-201; discussion 201. https://doi.org/10.1097/00006123-199707000-00030
25. Kaye AH, Hahn JF, Kinney SE, Hardy RW, Bay JW (1984) Jugular foramen schwannomas. J Neurosurg 60 (5):1045-1053. https://doi.org/10.3171/jns.1984.60.5.1045
26. Komune N, Matsushima K, Matsushima T, Komune S, Rhoton AL (2016) Surgical approaches to jugular foramen schwannomas: An anatomic study. Head Neck 38 Suppl 1:1041-1053. https://doi.org/10.1002/hed.24156
27. Li D, Zeng XJ, Hao SY, Wang L, Tang J, Xiao XR et al. (2016) Less-aggressive surgical management and long-term outcomes of jugular foramen paragangliomas: a neurosurgical perspective. J Neurosurg 125 (5):1143-1154. https://doi.org/10.3171/2015.10.JNS151875
28. Liu JK, Sameshima T, Gottfried ON, Couldwell WT, Fukushima T (2006) The combined transmastoid retro- and infralabyrinthine transjugular transcondylar transtubercular high cervical approach for resection of glomus jugulare tumors. Neurosurgery 59 (1 Suppl 1):115-125; discussion 125. https://doi.org/10.1227/01.NEU.0000220025.81500.8D
29. Matsushima K, Kohno M, Komune N, Miki K, Matsushima T, Rhoton AL (2014) Suprajugular extension of the retrosigmoid approach: microsurgical anatomy. J Neurosurg 121 (2):397-407. https://doi.org/10.3171/2014.3.JNS132419
30. Matsushima K, Kohno M, Nakajima N, Izawa H, Ichimasu N, Tanaka Y et al. (2019) Retrosigmoid Intradural Suprajugular Approach to Jugular Foramen Tumors with Intraforaminal Extension: Surgical Series of 19 Cases. World Neurosurg 125 :984-991. https://doi.org/10.1016/j.wneu.2019.01.223
31. Matsushima T (2015) Microsurgical anatomy of and surgical approaches to the jugular foramen. In: Microsurgical Anatomy and Surgery of the Posterior Cranial Fossa. Springer, Tokyo. pp 277-297.
32. Mazzoni A (2009) The petro-occipital trans-sigmoid approach for lesions of the jugular foramen. Skull Base 19 (1):48-56. https://doi.org/10.1055/s-0028-1103127
33. Nakamura M, Krauss JK (2010) Image-guided resection of small lesions in the cavernous sinus and Meckel's cave. Eur J Surg Oncol 36 (2):208-213. https://doi.org/10.1016/j.ejso.2009.07.004
34. Nakamura M, Stöver T, Rodt T, Majdani O, Lorenz M, Lenarz T et al. (2009) Neuronavigational guidance in craniofacial approaches for large (para)nasal tumors involving the anterior skull base and upper clival lesions. Eur J Surg Oncol 35 (6):666-672. https://doi.org/10.1016/j.ejso.2008.10.011
35. Oldring D, Fisch U (1979) Glomus tumors of the temporal region: surgical therapy. Am J Otol 1 7-18.
36. Park ES, Lee EJ, Park JB, Cho YH, Hong SH, Kim JH et al. (2016) A Single-Institution Retrospective Study of Jugular Foramen Schwannoma Management: Radical Resection Versus Subtotal Intracranial Resection Through a Retrosigmoid Suboccipital Approach Followed by Radiosurgery. World Neurosurg 88 :552-562. https://doi.org/10.1016/j.wneu.2015.10.042

37. Patel SJ, Sekhar LN, Cass SP, Hirsch BE (1994) Combined approaches for resection of extensive glomus jugulare tumors. A review of 12 cases. J Neurosurg 80 (6):1026-1038. https://doi.org/10.3171/jns.1994.80.6.1026
38. Rhoton AL, Buza R (1975) Microsurgical anatomy of the jugular foramen. J Neurosurg 42 (5):541-550. https://doi.org/10.3171/jns.1975.42.5.0541
39. Samii M, Alimohamadi M, Gerganov V (2015) Surgical Treatment of Jugular Foramen Schwannoma: Surgical Treatment Based on a New Classification. Neurosurgery 77 (3):424-432; discussion 432. https://doi.org/10.1227/NEU.0000000000000831
40. Samii M, Alimohamadi M, Gerganov V (2016) Endoscope-assisted retrosigmoid infralabyrinthine approach to jugular foramen tumors. J Neurosurg 124 (4):1061-1067. https://doi.org/10.3171/2015.3.JNS142904
41. Samii M, Babu RP, Tatagiba M, Sepehrnia A (1995) Surgical treatment of jugular foramen schwannomas. J Neurosurg 82 (6):924-932. https://doi.org/10.3171/jns.1995.82.6.0924
42. Sanna M, De Donato G, Di Lella F, Falcioni M, Aggrawal N, Romano G (2009) Nonvascular lesions of the jugular foramen: the gruppo otologico experience. Skull Base 19 (1):57-74. https://doi.org/10.1055/s-0028-1103124
43. Sanna M, Flanagan S (2007) Surgical management of lesions of the internal carotid artery using a modified Fisch Type A infratemporal approach. Otol Neurotol 28 (7):994. https://doi.org/10.1097/01.MAO.0000271715.92886.9e
44. Sarma S, Sekhar LN, Schessel DA (2002) Nonvestibular schwannomas of the brain: a 7-year experience. Neurosurgery 50 (3):437-448; discussion 438. https://doi.org/10.1097/00006123-200203000-00002
45. Sarris CE, Stevens SM, Almefty KK (2021) Transtemporal Suprajugular Approach with Neck Dissection for Jugular Foramen Tumor Resection: Operative Video. J Neurol Surg B Skull Base 82 (Suppl 1):S55-S56. https://doi.org/10.1055/s-0040-1701680
46. Schipper J, Spetzger U, Tatagiba M, Rosahl S, Neumann HP, Boedeker CC et al. (2009) Juxtacondylar approach in temporal paraganglioma surgery: when and why. Skull Base 19 (1):43-47. https://doi.org/10.1055/s-0028-1103129
47. Shin SH, Sivalingam S, De Donato G, Falcioni M, Piazza P, Sanna M (2012) Vertebral artery involvement by tympanojugular paragangliomas: management and outcomes with a proposed addition to the fisch classification. Audiol Neurootol 17 (2):92-104. https://doi.org/10.1159/000330724
48. Silva D, Belsuzarri T, Barnett GH (2020) Image-guided surgery for meningioma. Handb Clin Neurol 170: 201-207. https://doi.org/10.1016/B978-0-12-822198-3.00040-9
49. Wan JH, Wu YH, Li ZJ, Li XJ, Qian HP, Meng XL et al. (2012) Triple dumbbell-shaped jugular foramen schwannomas. J Craniomaxillofac Surg 40 (4):354-361. https://doi.org/10.1016/j.jcms.2011.05.012

OP-III/74

The application of endonasal endoscopic approach for non-tumor inflammatory and infectious disease

Wei-Hsin Wang[1], Yu-Wen Huang[2], Chien-Fu Yeh[2], Li-Ting Hung[2], Yun-Ting Chao[2], Ming-Ying Lan[2]

[1]Department of Neurosurgery, Taipei Veterans General Hospital
[2]Department of Otolaryngology-Head and Neck Surgery, Taipei Veterans General Hospital

Objectives: To review the application and limitation of endonasal endoscopic approach (EEA) for skull base inflammatory and infectious disease

Background: Diagnosis and treatment of the inflammatory and infectious disease located in central skull base is challenging due to its mimic tumor behavior. EEA has been accepted as the efficient surgical corridor for deep central skull base lesions. The role of surgery may provide the advantage of accurate diagnosis and adequate decompression.

Method: EEA series from 2015 to 2022 in Taipei Veterans General Hospital were reviewed. Non-tumor inflammatory pathologies were selected for analysis. Surgical anatomy and literatures were also reviewed according to a variety of the pathologies.

Results: In this series, 18 cases were enrolled. The pathologies included 3 necrotizing granulomatous inflammation, 4 invasive fungal sinusitis, 3 chronic sinusitis and 8 osteoradionecrosis. The common symptoms included headache, neck pain and cranial nerves compression such as trigeminal neuralgia, ptosis, diplopia, hearing loss and facial palsy. The specimens for pathological diagnosis were available in all cases and there was no surgical morbidity and mortality.

Conclusions: EEA has privileges for midline skull lesions and relevant surgical landmarks and techniques have been widely practiced. For non-tumor inflammatory and infectious disease, it provides minimal invasive solutions to gain tissues for accurate diagnosis and efficient decompression, which may shorten the clinical course.

Keywords: skull base inflammatory disease, skull base osteomyelitis, skull base inflammatory pseudotumor, endonasal endoscopic approach

References

1. Anand, P., Chwalisz, B.K. Inflammatory Disorders of the Skull Base: a Review. *Curr Neurol Neurosci Rep* 19, 96 (2019)
2. Sokołowski, J., Lachowska, M., Karchier, E. *et al.* Skull base osteomyelitis: factors implicating clinical outcome. *Acta Neurol Belg* **119**, 431–437 (2019)
3. Garg V, Temin N, Hildenbrand P, Silverman M, Catalano PJ. Inflammatory Pseudotumor of the Skull Base. *Otolaryngology–Head and Neck Surgery*. 2010;142(1):129-131
4. Wang, W., Lieber, S., Mathias, R. N., Sun, X., Gardner, P. A., Snyderman, C. H., Wang, E. W., & Fernandez-Miranda, J. C. (2019). The foramen lacerum: surgical anatomy and relevance for endoscopic endonasal approaches, *Journal of Neurosurgery JNS*, *131*(5), 1571-1582.
5. Zwagerman, N.T., Zenonos, G., Lieber, S. *et al.* Endoscopic transnasal skull base surgery: pushing the boundaries. *J Neurooncol* **130**, 319–330 (2016)
6. Wang, Wei-Hsin, et al. "Endoscopic endonasal transclival transcondylar approach for foramen magnum meningiomas: surgical anatomy and technical note." *Operative Neurosurgery* 12.2 (2016): 153-162.

OP-II/75

Anatomical Variations of Atlantoaxial Region and Ideal C1 Lateral Mass, C2 Pedicle Screw Insertion: A Cadaveric Study

Derya Karatas[1], Ömer Ruşen Koyuncu[2], Saygı Uygur[1], Irmak Tekeli Barut[1], Ahmet Dağtekin[1], Emel Avcı[1]

[1]Mersin University, School of Medicine
[2]Doktor Yaşar Eryılmaz State Hospital

Objectives: To learn medial and cranial screw angles for C1 lateral mass and C2 pedicle instrumentation along with a novel entry point for C2. Also emphasizing the incidence of anatomical variations of C1 and C2 vertebrae.

Background: Various posterior screw trajectories have been proposed for C1 (atlas) lateral mass and C2 (axis) pedicle screws in atlantoaxial instability. There is still no consensus on ideal and safe trajectory. We aimed to analyze the feasibility of ideal and safe C1 lateral mass and C2 pedicle screw methods along a tight and long trajectory in spite of anatomical variations (1, 2, 3).

Method: We dissected craniovertebral junction of 17 cadavers (34 sides) after performing thin-cut computed tomography. The screw entry points, targets, angles, and lengths of the trajectories were performed for C1 lateral mass and C2 pedicle. A new inferior entry point of the C2 pedicle screw has been determined. We particularly focused on the morphometric features and the safety of trajectory in cadavers with vascular and bony variations (Figure 1 A-H).

Figure 1

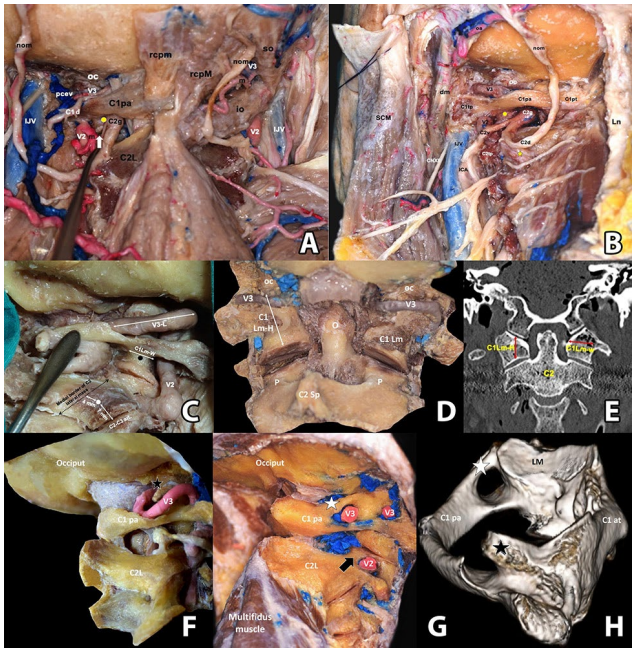

Posterior view, on the right side the muscles forming the suboccipital triangle are visible, to the left of the midline these muscles were removed and the hypoplastic vertebral artery is visible (A). Posterolateral view of deep muscular and neurovascular structures in the upper cervical region (B). Demonstration of several anatomical measurements after posterior dissection of the right upper cervical region (C). Posterior cadaveric dissection demonstrate C2 pedicle curve and C1-C2 articulation (D). Coronal section through the middle of both C1 lateral masses, thin-cut computed tomography (E). Complete and incomplete arcuate foramens as an atlas bone variation at right sided upper cervical region cadaveric dissections (F, G) and 3D reconstructive atlas tomography (H) from right side. H demonstrates the coexistence of complete and incomplete arcuate foramen and G demonstrates the specimen which have both high riding vertebral artery, narrow pedicle and complete arcuate foramen. Ln: Ligamentum nuchae, SCM: Sternocleidomastoideus muscle, nom: Nervus occipitalis major, yellow asterix: C2-C3 articulation, white arrow: C1-C2 articulation, yellow point: C1 screw entry point, C1tp: C1 transverse process, C2tp: C2 transvers process, so: Superior oblique muscle, io: Inferior oblique muscle, rcpM: Rectus capitis posterior major muscle, rcpm: Rectus capitis posterior minor, dm: digastric muscle, IJV: Internal jugular vein, ICA: Internal carotid artery, CNXII: Hypoglossal nerve , CNXI: Accessory nerve, C1d: C1 dorsal root, C2g: C2 ganglion, C2d: C2 dorsal root, C2v: C2 ventral root, C1pa: C1 posterior arcus, C1pt: C1 posterior tubercle, C2L: C2 lamina, oc: Occipital condyle, V2: Second segment of vertebral artery, V3: Third segment of vertebral artery, m: Muscular branch of vertebral artery, pcev: posterior deep cervical vein or posterior vertebral vein, LM: lateral mass, P: Pedicle, O: Odontoid process, C1Lm-H: C1 lateral mass height, C1 Lm-W: C1 lateral mass width, C1 Lm: C1 lateral mass, C2: Corpus of C2, C2 Sp: C2 spinous process, black point: C1 lateral mass screw entry point, white point: C2 pedicle screw entry point, C2-C3 art.: C2-C3 articulation, V3-L: The length of V3 segment, White asterix: Complete arcuate foramen, black asterix: Incomplete arcuate foramen, black arrow: Narrow pedicle.

Results: For the C1 lateral mass ideal medial and cranial angles were 13.4° ± 1.0° and 14.7° ± 1.1°, respectively. For the C2 pedicle screw, the cranial and medial angles were 27.7° ± 1.4° and 20.4° ± 1.5°, respectively. Rate of the high-riding vertebral artery (HRVA) was seen in 23% of all sides (Figure 2 A-N). The prevalence of arcuate foramen was 52.9% and its coexistence with HRVA was 35.3%. Narrow pedicle prevalence was 23.5%.

Figure 2

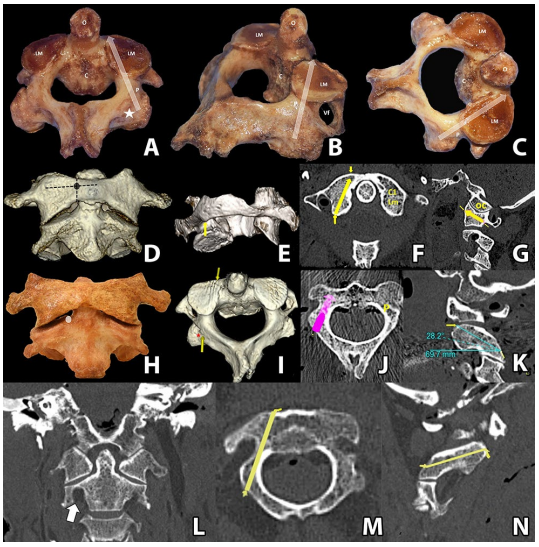

Posterior (A), lateral oblique (B) and superior (C) view of axis bone. D. 3D-CT atlantoaxial bone image shows the target point (black point) of C1 lateral mass screw trajectory from the anterior view. E. 3D-CT C1 bone image shows the entry point of left C1 lateral mass screw trajectory from the posterior view. F. Axial section through the trajectory that is oriented entry and target points of right C1 lateral mass, thin-cut computed tomography. G. Sagittal section through the trajectory that is oriented entry and target points of right C1 lateral mass. H. Anterior atlantoaxial cadaveric demonstration shows the target point (white point) of left C2 pedicle screw trajectory. I. 3D-CT of C2 bone shows the entry and target point of C2 pedicle screw trajectory from the superior view. J. Axial section through the trajectory that is oriented entry and target points of right C2 pedicle screw. K. Sagittal section through the trajectory that is oriented entry and target points of right C2 pedicle screw. The image shows the measurement of cranial angle (blue line) of C2 pedicle screw on workstation. L. Coronal section shows HRVA on right side (white arrow). M. Axial section through the trajectory that is oriented entry and target points of right C2 pedicle show the our safe trajectory on HRVA side. N. Sagittal section through the trajectory (yellow line) that is oriented entry and target points of right C2 pedicle screw. LM: C2 lateral mass, P: Pedicle, C: C2 corpus, O: Odontoid process, vf: vertebral foramene, white asterix: The C2 groove from the superior articular surface. Long white arrow demonstrates the novel C2 pedicle screw trajectory. black point: C1 lateral mass screw entry point, C1Lm: C1 lateral mass, oc: occipital condyle, white point: C2 transpedicular screw entry point, red asterix: Groove

Conclusions: Preoperative pedicle-oriented radiological evalution is crucial before C1 lateral mass and C2 pedicle screw placement because of the high incidence of bony variations. Using our novel C2 pedicle trajectory, a longer safe screw course to preserve vertebral artery can be achieved with a more feasible cranial angle even in HRVA, except narrow pedicle.

Keywords: C2 pedicle, C1 lateral mass, Arcuate foramen, High riding vertebral artery

References

1. Rea GL, Kumar VGR: Posterior suboccipital and upper servical exposure of the occipitocervical junction. Fessler RG, Laligam S (ed), Atlas of Neurosurgical Techniques Spine and Peripheral Nerve. New York: Thieme, 2006:110-114.
2. Atlantoaxial fixation: overview of all techniques. *Mummaneni PV, Haid RW Neurol India. 2005 Dec; 53(4):408-15*
3. Moon B:j, Choi K.H, Shin D.A, et al. Anatomical variations of vertebral artery and C2 isthmus in atlanto-axial fusion: Consecutive surgical 100 cases. Journal of Clinical Neuroscience 2018;53: 147–152.

OP- V/76

The Role of Artificial Intelligence in Analyzing Neuroanatomy for Teaching, Learning and Surgical Planning

Noor ul Huda Maria[1]

[1]PINS

Objectives: To assess the role of AI in analyzing Neuroanatomy for teaching,learning and surgical planning

Background: Neurosurgeons receive extensive and lengthy training to equip themselves with various technical skills, and neurosurgery requires a great deal of pre-, intra- and postoperative clinical data collection, decision making, care and recovery.With an increasing development in AI there seems to be great promise in neurosurgery by complementing neurosurgeons' skills by better learning and training through AI as well as AI assistance in surgical planning

Method: Literature Review

Results: Convolutional neural network has been shown to analyze accurately segment gross neuroanatomy images.AI has also shown to be useful in analyzing brain structure abnormalities. Preoperative MR images of patients with deeply located brain tumors were used for planning. Intracranial arteries, veins, and neural tracts were listed and numbered. Voxel values of these selected regions in cranial MR sequences were extracted and labeled. Tumor tissue was segmented as the target. Q-learning algorithm which is a model-free reinforcement learning algorithm was run on labeled voxel values (on optimal paths extracted from the new heuristic-based path planning algorithm), then the algorithm was assigned to list the cortico-tumoral pathways that aim to remove the maximum tumor tissue and in the meantime that functional anatomical tissues will be least affected.The most suitable cranial entry areas were found with the artificial intelligence algorithm.Complementing the 3d maps generated by AI with 3d printing, a patient specific model can be generated

Conclusions: The future of AI in neurosurgery is promising and it can help in better education, training and surgical planning with it's analytical skills.

Keywords: AI, Neurosurgery, Neuroanatomy

References

1.Yoon S, Mooney MA, Garcia RM, Lawton MT. Price transparency in neurosurgery: key challenges and proposed solutions. *World Neurosurg.* (2018) 119:444–5. doi: 10.1016/j.wneu.2018.09.019

PubMed Abstract | CrossRef Full Text | Google Scholar

2.Türe U, Harput MV, Kaya AH, Baimedi P, Firat Z, Türe H, et al. The paramedian supracerebellar-transtentorial approach to the entire length of the mediobasal temporal region: an anatomical and clinical study. Laboratory investigation. *J Neurosurg.* (2012) 116:773–91. doi: 10.3171/2011.12.JNS11791

OP-II/77

Robotics in Microneurosurgery

Akio Morita[1], Kanako Harada[2], Mamoru Mitsuishi[2]

[1]Teraoka Memorial Hospital
[2]Department of Engineering, University of Tokyo

Objectives: To establish robotic System to enhance Microneurosurgery

Background: Robotics and medical engineering can convert traditional surgery into digital and scientific procedures. Here, we review robotics in neurosurgery and describe our work to develop microneurosurgical robotic systems and to apply engineering technology to advance neurosurgery.

Method: With the collaboration of neurosurgeons and an engineering team, we have been developing two types of microsurgical robotic systems. The first, the deep surgical systems, enable delicate surgical procedures such as vessel suturing in a deep and narrow space. The second type allows for super-fine surgical procedures such as anastomosing 0.3-mm vessels. Both systems are constructed with master and slave manipulator robots connected to local area networks.

Results: Robotic systems allowed for secure and accurate procedures in a deep surgical field. In surgical models, these systems showed a good possibility of being useful in live human surgeries, but mechanical refinements and durability are necessary to be established as clinically applicable systems. Another trial included the digitalization of surgical technique and scientific analysis of surgical skills. Robotic and human hand motions were analyzed in numerical fashion as we tried to define surgical skillfulness in a digital format. Engineered skill assessment is also feasible and should be useful for microsurgical training.

Conclusions: Robotics and medical engineering should bring science into the surgical field and training of surgeons. Active collaboration between medical and engineering teams and academic and industry groups is mandatory to establish such medical systems to improve patient care.

Keywords: Robotics, Microneurosurgery, Engineering, Security

References

1. Morita A, Sora S, Mitsuishi M, Warisawa S, Surman K, Asai D, Baba S. Mochizuki R, Kirino T: Microsurgery robotic system for the deep surgical field. Development and feasibility study in animal and cadaveric models. **J Neurosurg** 103:320-327, 2005

OP-II/78

Association between Size of Residual Non-functioning pituitary adenoma with Regrowth Non-functioning pituitary adenoma after surgery

Todsapon Praphanuwat[1], Songkiet Suwansirikul[2], Tanat Vaniyapong[1]

[1]Department of Surgery , Neurosurgery unit,Faculty of Medicine ,Chiang Mai University, Chiang Mai ,Thailand
[2]Department of Pathology ,Faculty of Medicine, Chiang Mai University , Chiang Mai ,Thailand

Objectives: The aim of this study is to investigate whether the residual tumor size after surgery for non-functioning pituitary adenoma can predict tumor regrowth, and to identify other predictors that could also be used to predict tumor regrowth/recurrence.

Background: Incomplete resection of non-functioning pituitary adenomas is associated with high rates of recurrence, which present management challenges for neurosurgeons, often requiring revision surgery or radiotherapy. Several studies have identified predictors of tumor recurrence such as postoperative residual tumor, invasion of the cavernous sinus, and absence of postoperative radiotherapy, but there is still a lack of consensus on whether residual tumor size after surgery can accurately predict tumor regrowth.

Method: This retrospective study analyzed data from 123 newly diagnosed cases of non-functioning pituitary adenoma that underwent surgery at Maharaj Nakorn Chiang Man Hospital between January 2009 and December 2020. Follow-up assessments of residual tumor size were performed using CT scan or 1.5 Tesla MRI, interpreted by neurosurgeons. Multivariate analysis was used to identify predictors of tumor regrowth, and Kaplan-Meier analysis was used to determine regrowth-free survival.

Results: Of the 123 patients included in the study, 22 experienced tumor regrowth/recurrence and 101 had no progression. Univariate analysis revealed that residual tumor size was the most significant factor, particularly when the size was over 1 cm (HR 4.00; 95% CI 1.16-13.83; P=0.03). Multivariate analysis, adjusted for radiotherapy, hormonal deficit, age, and gender, showed that tumor regrowth or recurrence was dependent on size, particularly when the size was over 1 cm (HR 6.52; 95% CI 1.37-31.07; P=0.02).

Kaplan-Meier survival 1

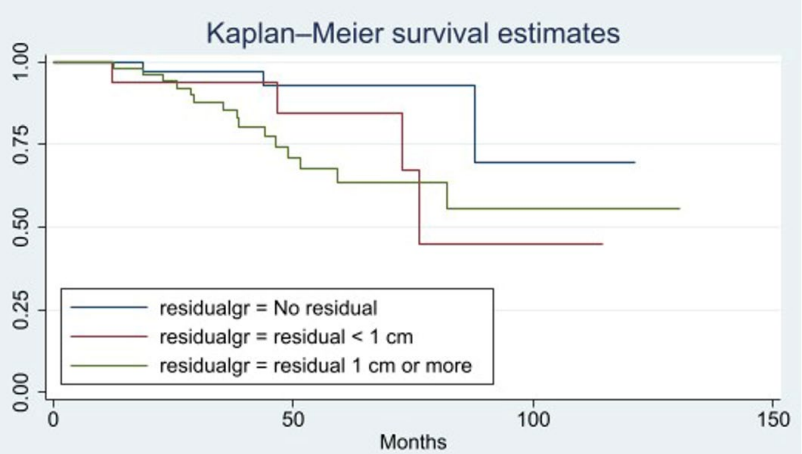

Kaplan-Meier curves for NFPA patients post surgical removal that : no residual tumor , residual tumor < 1 cm and residual tumor > 1 cm patients

Kaplan-Meier survival 2

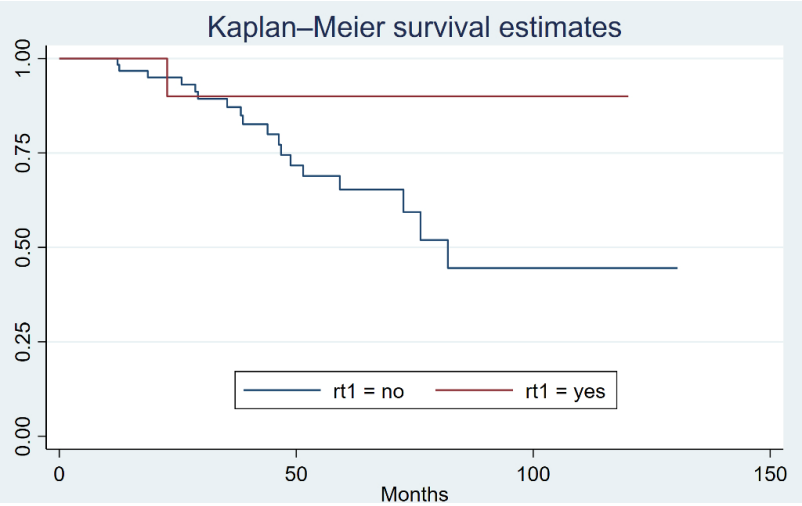

Kaplan-Meier curves for Residual tumor patients that under go radiotherapy and did not go radiotherapy

Demographic data

		Regrowth and Recurrent tumor	
	No (N=101)	Yes (N=22)	p-value
Age	53.4 (42.0-60.4)	49.9 (42.7-58.3)	0.45
Gender			
- Male	47 (46.5%)	9 (40.9%)	
- Female	54 (53.5%)	13 (59.1%)	0.81

Time follow up (months)	41.9 (27.4-67.8)	70.1 (58.5-100.4)	<0.001
Main Symptoms			
- Visual problem	69 (69%)	15 (68.2%)	
- Headache	16 (16%)	5 (22.7%)	
- Incidental	11 (11%)	1 (4.5%)	
- Hormonal	4 (4%)	1 (4.5%)	
Presence of Cyst			
Yes	71 (70.3%)	14 (63.6%)	
No	30 (29.7%)	8 (36.4%)	0.61
Presence of Hemorrhage			
Yes	77 (76.2%)	19 (86.4%)	
No	24 (23.8%)	3 (13.6%)	0.40
Knosp Classification			
- Grade 0	45 (44.6%)	5 (22.7%)	
- Grade I	18 (17.8%)	4 (18.2%)	
- Grade II	15 (14.9%)	2 (9.1%)	
- Grade III	10 (9.9%)	4 (18.2%)	
- Grade IV	13 (12.9%)	7 (31.8%)	0.10
Preoperative Maximal Diameter (cm)	2.8 (2.3-3.5)	3.2 (2.5-3.6)	0.22
Extension			
- Suprasellar	64 (63.4%)	12 (54.5%)	
- Parasellar	32 (31.7%)	9 (40.9%)	0.72
Residual Tumor			
No	45 (44.6%)	3 (13.6%)	
Yes	56 (55.4%)	19 (86.4%)	0.008
Hormonal deficit at least 1 axis			
No	41 (42%)	7 (39%)	
Yes	57 (58%)	11 (61%)	0.82
Ki-67 Li > 1			
No	31 (78%)	7 (88%)	
Yes	9 (23%)	11(13%)	1.00
Radiotherapy			
No	91 (90.1%)	21 (95.5%)	
Yes	10 (9.9%)	1 (4.5%)	0.69

Demographic data of Regrowth and Recurrent tumor compare with non-progression group

Univariate analysis

Outcome predictor	HR	95%CI	p-value
Age	1.00	0.96-1.04	0.94
Gender	1.20	0.51-2.81	0.68
Preoperative tumor diameter > 4 cm	1.74	0.59-5.16	0.32
Extension			
- Suprasellar	1.21	0.16-9.46	0.85
- Parasellar	1.70	0.21-13.58	0.62
Knosp Classification			
- Grade I	1.93	0.52-7.21	0.33
- Grade II	1.06	0.20-5.45	0.95
- Grade III	2.73	0.73-10.19	0.13
- Grade IV	4.60	1.45-14.57	0.01
Hormone deficit at least 1 axis	1.05	0.41-2.72	0.91
Residual tumor size			
- Residual < 1 cm	3.03	0.68-13.57	0.15
- Residual 1 cm or more	4.00	1.16-13.83	0.03
Radiotherapy	0.38	0.05-2.80	0.34

Multivariate analysis

Outcome predictor	HR	95%CI	p-value
Residual < 1 cm	5.29	0.94-29.90	0.06
Residual 1 cm or more	6.52	1.37-31.07	0.02

adjust by radiotherapy, hormonal deficit ,age ,gender

Conclusions: Residual non-functioning pituitary adenoma after surgical removal can predict future progression, especially if the size is over 1 cm. Physicians should pay close attention to patients in this group.

Keywords: Non-functioning pituitary adenoma, Predictor regrowth tumor, Residual Non-functioning pituitary adenoma size, Pituitary adenoma

References

1. Chen, Y., Wang, C. D., Su, Z. P., Chen, Y. X., Cai, L., Zhuge, Q. C., & Wu, Z. B. Natural History of Postoperative Nonfunctioning Pituitary Adenomas: A Systematic Review and Meta-Analysis. Neuroendocrinology.2012 ; 96(4), 333–342.
2. Hayhurst C, Taylor PN, Lansdown AJ, Palaniappan N, Rees DA, Davies JS. Current perspectives on recurrent pituitary adenoma: the role and timing of surgery vs adjuvant treatment. Clinical endocrinology. 2020;92(2):89–97.
3. Chai Hong Rim, Dae Sik Yang, Young Je Park, Won Sup Yoon, Jung Ae Lee, Chul Yong Kim . Radiotherapy for pituitary adenomas: long-term outcome and complications. Radiat Oncol J. 2011 ;29(3):156-63.
4. Jelena Maletkovic, Asmaa Dabbagh, Dongyun Zhang, Abdul Zahid, Marvin Bergsneider, Marilene B. Wang,Michael Linetsky, Noriko Salamon, William H. Yong, Harry V. Vinters, and Anthony P. Heaney . Residual Tumor Confers a 10-Fold Increased Risk of Regrowth in Clinically Nonfunctioning Pituitary Tumors . J Endocr Soc. 2019 Jul 23;3(10):1931-1941.
5. Sophie Brochier , Françoise Galland, Michèle Kujas, Fabrice Parker, Stephan Gaillard, Christian Raftopoulos, Jacques Young, Orsalia Alexopoulou, Dominique Maiter, Philippe Chanson . Factors predicting relapse of nonfunctioning pituitary macroadenomas after neurosurgery: a study of 142 patients . Eur J Endocrinol. 2010 Aug;163(2):193-200.
6. Jee Soon Kim ., Youn Soo Lee., Min Jung Jung., Yong Kil Hong., The Predictive Value of Pathologic Features in Pituitary Adenoma and Correlation with Pituitary Adenoma Recurrence. Journal of Pathology and Translational Medicine. 2016; 50: 419-425.
7. Georg Widhalm, Stefan Wolfsberger, Matthias Preusser, Ingeborg Fischer, Adelheid Woehrer, Joerg Wunderer, Johannes A. hainfellner, Engelbert Knosp . Residual nonfunctioning pituitary adenomas: prognostic value of MIB-1 labeling index for tumor progression. J Neurosurg .2009; 111:563–571.
8. Roger Gejman, Brooke Swearingen, E. Tessa Hedley-Whyte. Role of Ki-67 proliferation index and p53 expression in predicting progression of pituitary adenomas. Human Pathology .2008; 39, 758–766; 2007.
9. Jason Sheehan, Cheng-Chia Lee, Mary E. Bodach et al. Congress Of Neurologıcal Surgeons Systematıc Revıew And Evıdence-Based Guıdelıne For The Management Of Patıents Wıth Resıdual Or Recurrent Nonfunctıonıng Pıtuıtary Adenomas . Congress of Neurological Surgeons 2016.
10. Marco Losa, Pietro Mortini, Raffaella Barzaghi, Paolo Ribotto, Maria Rosa Terreni, Stefania Bianchi Marzoli et al . Early results of surgery in patients with nonfunctioning pituitary adenoma and analysis of the risk of tumor recurrence. J Neurosurg. 2008;108:525–532.
11. K. Seejore, S. A. Alavi, S. M. Pearson, J. M. W. Robins, B. Alromhain, A. Sheikh et al . Post-operative volumes following endoscopic surgery for non-functioning pituitary macroadenomas are predictive of further intervention, but not endocrine outcomes. BMC Endocrine Disorders .2021; 21:116.
12. Petr Matoušek, Petr Buzrla, Štefan Reguli, Jan KrajIa, Jana DvoláIková, Radim Lipina. Factors That Predict the Growth of Residual Nonfunctional Pituitary Adenomas: Correlations between Relapse and Cell Cycle Markers . Biomed Res Int . 2018 .
13. Lloyd RV, Osamura RY, Klöppel G, Rosai J . WHO classification of tumours of endocrine organs, 4th edn. 2017.
14. Yao X, Gao H, Li C, Wu L, Bai J, Wang J, et al. Analysis of Ki67, HMGA1, MDM2, and RB expression in nonfunctioning pituitary adenomas. Journal of Neuro-Oncology. 2017;132(2):199–206.
15. Sadeghipour A, Mahouzi L, Salem MM, Ebrahim-Nejad S, Asadi-Lari M, Radfar A, et al. Ki67 labeling correlated with invasion but not with recurrence. Applied Immunohistochemistry & Molecular Morphology. 2017;25(5):341–5.

OP- V/79

Presigmoidal Suprabulbar Infralabyrinthine Approach with Neuronavigational Assistance to the Jugular Foramen Region: Quantitative Analysis of Exposed Area and Surgical Freedom

Zafer Cinibulak[1]

[1]Department of Neurosurgery, Merheim Hospital/University of Witten/Herdecke, Cologne, Germany

Objectives: The navigated presigmoidal suprabulbar infralabyrinthine approach without rerouting of the fallopian canal is described as a suitable approach for tumors located at the intra -and supraforaminal region of the jugular foramen. The aim of the anatomical study is to evaluate the surgical freedom, angle of attack, and approach depth to the exposed area with particular focus on defined target points.

Background: Quantitative analysis of the infralabyrinthine approach.

Method: The infralabyrinthine approach was performed on ten adult human cadaver heads (20 total sides). To calculate the values, the vector coordinates were registered image-guided.

Anatomical demonstration of the approach

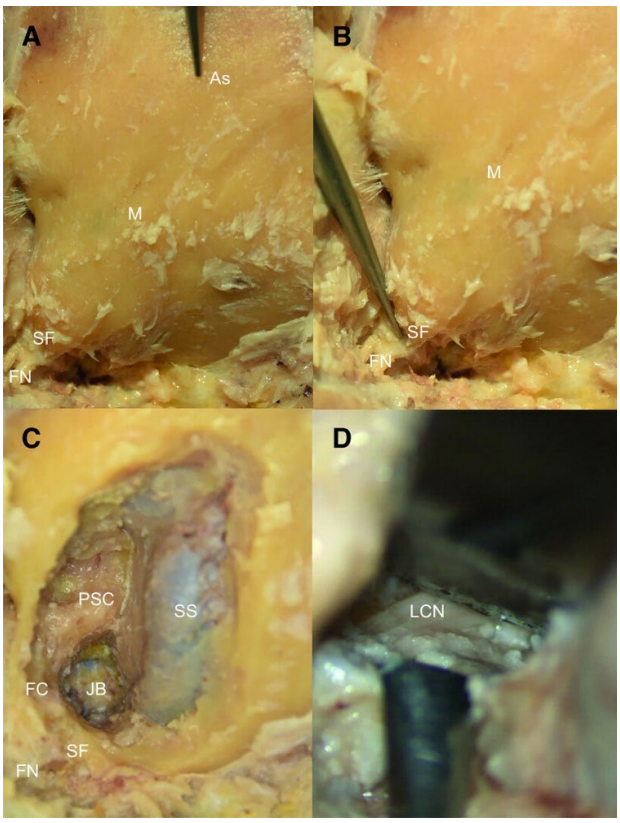

Anatomical exposure of the neuronavigational guided presigmoidal suprabulbar infralabyrinthine approach without rerouting of the facial nerve on the left side

Results: The exposed area was calculated at 51.1 ± SD 1.3 mm2, and the surgical freedom of exposed area at 18383.1 ± SD 567.8 mm2. The surgical freedom and angle of attack at the lateral and superolateral target points of the jugular foramen are significantly larger than at the medial and superomedial border.

Conclusions: The neuronavigated presigmoidal suprabulbar infralabyrinthine approach without rerouting of the facial nerve allows sufficient surgical freedom and angle of attack to intra -and supraforaminally situated jugular foramen tumors. Compared with medial and superomedially located target points at the jugular foramen, the surgical freedom, the horizontal viewing angle and the vertical viewing angle of the surgeon are significantly larger at the laterally and superolaterally located target points. Especially, jugular foramen tumors with lateral extension intra -and supraforaminally should be combined with the neuronavigated infralabyrinthine approach.

Keywords: Neuronavigation, Suprabulbar Approach, Sigmoid Sinus, Facial Nerve

References

1. Abe D, Aoyagi M: Microsurgical Resection of a Large Dumbbell-Shaped Jugular Foramen Schwannoma via Infralabyrinthine, Retrofacial, and Transjugular Approach. J Neurol Surg B Skull Base 82 (Suppl 1):S57-S58, 2021
2. Ayeni SA, Ohata K, Tanaka K, Hakuba A: The microsurgical anatomy of the jugular foramen. J Neurosurg 83 (5):903-909, 1995
3. Bulsara KR, Sameshima T, Friedman AH, Fukushima T: Microsurgical management of 53 jugular foramen schwannomas: lessons learned incorporated into a modified grading system. J Neurosurg 109 (5):794-803, 2008
4. Cavalcanti DD, Martirosyan NL, Verma K, Safavi-Abbasi S, Porter RW, Theodore N et al.: Surgical management and outcome of schwannomas in the craniocervical region. J Neurosurg 114 (5):1257-1267, 2011
5. Chibbaro S, Mirone G, Makiese O, Bresson D, George B: Dumbbell-shaped jugular foramen schwannomas: surgical management, outcome and complications on a series of 16 patients. Neurosurg Rev 32 (2):151-9; discussion 159, 2009
6. Cinibulak Z, Krauss JK, Nakamura M: Navigated minimally invasive presigmoidal suprabulbar infralabyrinthine approach to the jugular foramen without rerouting of the facial nerve. Neurosurgery 73 (1 Suppl Operative):ons3-15, 2013
7. Constanzo F, Coelho Neto M, Nogueira GF, Ramina R: Microsurgical Anatomy of the Jugular Foramen Applied to Surgery of Glomus Jugulare via Craniocervical Approach. Front Surg. Published online May 15, 2020. doi:10.3389/fsurg.2020.00027
8. Das SS, Saluja S, Vasudeva N: Complete morphometric analysis of jugular foramen and its clinical implications. J Craniovertebr Junction Spine 7 (4):257-264, 2016
9. Fayad JN, Keles B, Brackmann DE: Jugular foramen tumors: clinical characteristics and treatment outcomes. Otol Neurotol 31 (2):299-305, 2010
10. Gardner G, Cocke EW, Robertson JT, Trumbull ML, Palmer RE: Combined approach surgery for removal of glomus jugulare tumors. Laryngoscope 87 (5 Pt 1):665-688, 1977
11. Lieber S, Nunez M, Tatagiba M: Lateral Suboccipital Approach in Semisitting Position for Resection of Vagal Schwannoma: 2-Dimensional Operative Video. J Neurol Surg B Skull Base 82 (Suppl 1):S51-S52, 2021
12. Matsushima K, Kohno M: Transjugular transsigmoid approach for triple dumbbell-shaped jugular foramen schwannomas. Acta Neurochir (Wien) 161 (4):739-743, 2019
13. Matsushima K, Kohno M, Komune N, Miki K, Matsushima T, Rhoton AL: Suprajugular extension of the retrosigmoid approach: microsurgical anatomy. J Neurosurg 121 (2):397-407, 2014
14. Mattos JP, Ramina R, Borges W, Ghizoni E, Fernandes YB, Paschoal JR et al.: Intradural jugular foramen tumors. Arq Neuropsiquiatr 62 (4):997-1003, 2004
15. Rhoton AL, Buza R: Microsurgical anatomy of the jugular foramen. J Neurosurg 42 (5):541-550, 1975
16. Sanna M, Mazzoni A, Saleh EA, Taibah AK, Russo A: Lateral approaches to the median skull base through the petrous bone: the system of the modified transcochlear approach. J Laryngol Otol 108 (12):1036-1044, 1994

OP-II/80

Intra-Operative Cerebral Panangiography Through The Superior Thyroid Artery In Paraclinoid Aneurysms. Case Series And Results.

Kevin Eder Garcia Rodriguez[1], Osvaldo Manuel San Martin Garcia[1], Mateus Reghin Neto[1], Andrés Jaime Aguirre[2], Sergio Azcona[1]

[1]Beneficência Portuguesa de São Paulo
[2]Centro Médico Nacional "20 de Noviembre" ISSSTE

Objectives: To describe the results and the surgical technique for performing intraoperative cerebral angiography during the microsurgical management of paraclinoid aneurysms, using the superior thyroid artery as the access route.

Background: The cervical approach for proximal vascular control of aneurysms during microsurgery remains important during the procedure. We propose using the same approach to perform an intraoperative angiography that offers DSA images for post-clipping control. Cerebral angiography is usually performed using the femoral puncture technique or radial, which are carried out before or after performing the surgical procedure, not at the OR, and only in hospitals with neurological endovascular therapy. To date, we haven't found record of procedures carried out through this vascular access, so we report our results obtained in six patients with a diagnosis of paraclinoid aneurysm as well as the advantages and disadvantages that we were able to observe.

Patient positioning



Surgical position and marking of both the cranial approach and the vascular access for angiography

Method: The cervical control procedure was performed in six patients with paraclinoid aneurysm. A cervical approach was performed in the neck with the usual technique and in front

of the anterior border of the sternocleidomastoid, visualizing the common carotid artery and its bifurcation as well as the superior thyroid artery.

carotid bifurcation and superior thyroid artery

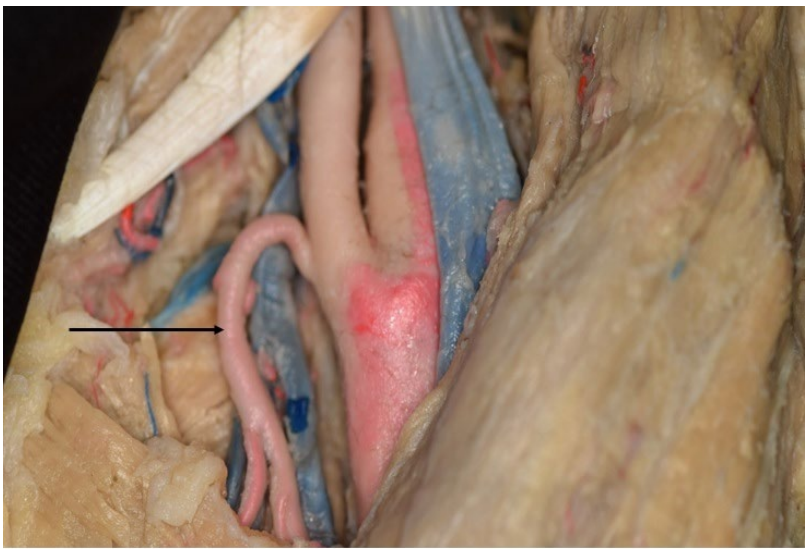

Disection of the carotid bifurcation, superior thyroid artery, and internal jugular vein, on cadaver at the lab.

Results: In each of the six cases, AP and Lat intraoperative DSA images were obtained by portable fluoroscopy before and after placement of the definitive clip to close the neck of the aneurysm, corroborating its exclusion. None of the cases showed intraoperative radiological or postoperative clinical vasospasm, and in no case was it necessary to reposition the definitive clip. There were no complications during the cervical approach, vascular damage or low cranial nerves, hematoma on surgical site or postoperative bleeding.

Angiography post op

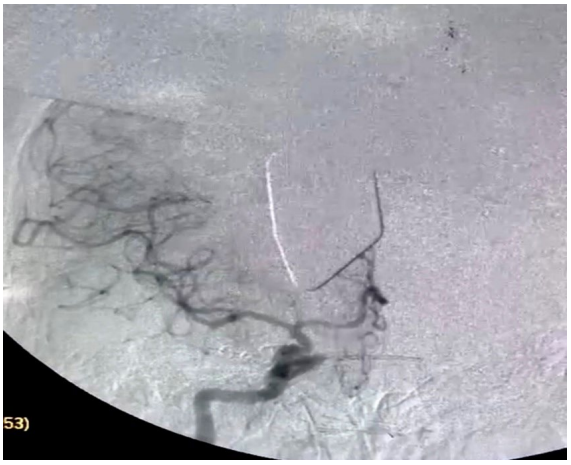

Intraoperative AP view after definitive clip placement

Conclusions: Intraoperative cerebral panangiography through access in the superior thyroid artery for the microsurgical management of paraclinoid aneurysms offers different specific advantages, reducing costs and the number of procedures performed on the patient.

Keywords: Paraclinoid, Aneurysm, Panangiography, Thyroid

References

1. Rhoton AL. The Supratentorial Cranial Space: Microsurgical Anatomy and Surgical Approaches. Lippincott Williams & Wilkins; 2002.
2. Lawton MT. Seven aneurysms: tenets und techniques for clipping. New York, NY: Thieme; 2011. 224 p.
3. Kamide T, Burkhardt JK, Tabani H, Safaee M, Lawton MT. Microsurgical Clipping Techniques and Outcomes for Paraclinoid Internal Carotid Artery Aneurysms. Oper Neurosurg. september 12th 2019; 157p.

OP-III/81

The Trochlear Nerve 2.0: 3-D Immersive Photorealistic photogrammetric Anatomical Model

Amedeo Piazza[1], Sergio Corvino[3], Francesco Corrivetti[2], Lili Laleva[4], Toma Spiriev[4], Matteo De Notaris[5]

[1]Department of Neurosurgery, Sapienza University, Rome, Italy
[2]Laboratory of Neuroscience, EBRIS Foundation, Salerno, Italy
[3]Department of Neuroscience, Reproductive and odontosmatological, division of Neurosurgery Federico II, Napoli, Italy
[4]Neurosurgery Unit, Acibadem CityClinic University Hospital, Sofia, Bulgaria 5 Neurosurgery Unit
[5]Department of Neuroscience, "San Pio" Hospital, Benevento, Italy

Objectives: The purpose of this paper is to present a photogrammetric method to process of multiple surface scanning to generate a complex volumetric 3D model from standard 2-D images. This reconstruction provides a more intuitive and interactive way to explore and describe the entire course of trochlear nerve in complex 3-D environment via photogrammetry.

Background: The 3-D photorealistic model of cranial nerves provides surgeons with a detailed and immersive representation of the anatomy, enabling to improve surgical planning and advance surgical research and training. In particular, there are several factors that contribute to the complexity of the anatomy of the trochlear nerve, including its small diameter, the complex and longest intracranial course within the posterior and middle cranial fossae to reach the orbit, a deep location and several anatomical relationships.

Method: Two injected-fixed head human specimens (4 side) were examined. The dissection protocol was divided in: step 1) brain hemisphere exposure, step 2) hemispherectomy dissecting all cranial nerves and partial removal of the free edge of the tentorium, step 3) middle fossa and lateral wall of cavernous sinus exposure, step 4) orbit exposure. Furthermore, a 3-D photogrammetric model was generated for each dissection step.

Results: Four main volumetric models were generated during a step by step layered dissection of the entire nerve pathway highlighting its different segments. Finally, a full and integrated model of the entire course of the nerve was created ready to be visualized on any computer or smart device well as in AR and VR mode.

Details of the Trochlear nerve in the photorealistic model

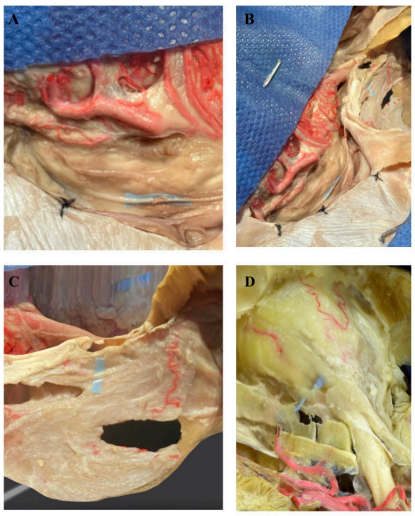

A,B: Cisternal portion C: Cavernous portion D: Orbital portion

Conclusions: The present photogrammetric model offer several advantages: provide a more comprehensive understanding of the nerve's anatomy, allow for customizable views thus simultating different approach's perspectives, provide a valuable alternative to traditional dissections and an advanced tool for surgical planning and surgical simulation well as virtual reality representation of the anatomy.

Keywords: photogrammetry, Trochlear nerve, Educational, 3D model

References

1. Rhoton AL, Jr. Tentorial incisura. *Neurosurgery*. Sep 2000;47(3 Suppl):S131-53. doi:10.1097/00006123-200009001-00015
2. Rhoton AL, Jr. The anterior and middle cranial base. *Neurosurgery*. Oct 2002;51(4 Suppl):S273-302.
3. Rhoton AL, Jr. The cavernous sinus, the cavernous venous plexus, and the carotid collar. *Neurosurgery*. Oct 2002;51(4 Suppl):S375-410.
4. Tubbs RS, Oakes WJ. Relationships of the cisternal segment of the trochlear nerve. *J Neurosurg*. Dec 1998;89(6):1015-9. doi:10.3171/jns.1998.89.6.1015
5. Tanriover N, Sanus GZ, Ulu MO, et al. Middle fossa approach: microsurgical anatomy and surgical technique from the neurosurgical perspective. *Surg Neurol*. May 2009;71(5):586-96; discussion 596. doi:10.1016/j.surneu.2008.04.009
6. Iaconetta G, de Notaris M, Benet A, et al. The trochlear nerve: microanatomic and endoscopic study. *Neurosurgical review*. 2013;36:227-238.
7. Bisaria KK. Cavernous portion of the trochlear nerve with special reference to its site of entrance. *J Anat*. Aug 1988;159:29-35.
8. Standring S, Ellis H, Healy J, et al. Gray's anatomy: the anatomical basis of clinical practice. *American journal of neuroradiology*. 2005;26(10):2703.
9. Rubio RR, Shehata J, Kournoutas I, et al. Construction of Neuroanatomical Volumetric Models Using 3-Dimensional Scanning Techniques: Technical Note and Applications. *World Neurosurg*. Jun 2019;126:359-368. doi:10.1016/j.wneu.2019.03.099

OP-II/82

Three-Dimensional Modeling and Augmented and Virtual Reality Simulations of the White Matter Anatomy of the Cerebrum

Muhammet Enes Gurses[1], Abuzer Gungor[3], Elif Gökalp[4], Sahin Hanalioglu[1], Seda Yagmur Karatas Okumus[2], Ilkan Tatar[5], Mustafa Berker[1], Aaron A. Cohen-Gadol[6], Uğur Türe[2]

[1]Department of Neurosurgery, Hacettepe University, Ankara, Turkey
[2]Department of Neurosurgery, Microsurgical Neuroanatomy Laboratory, Yeditepe University School of Medicine, Istanbul, Turkey
[3]Department of Neurosurgery, University of Health Sciences, Bakirkoy Prof. Dr. Mazhar Osman Training and Research Hospital for Neurology, Neurosurgery and Psychiatry, Istanbul, Turkey
[4]Department of Neurosurgery, Ankara University, Ankara, Turkey
[5]Department of Anatomy, Hacettepe University, Ankara, Turkey
[6]Department of Neurological Surgery, Indiana University School of Medicine, Indianapolis, Indiana, USA

Objectives: To define the white matter tracts of cadaveric human brains through fiber dissection and to make 2-dimensional and 3- dimensional (3D) images of the white matter tracts and create 3D models and augmented and virtual reality simulations.

Background: An understanding of the anatomy of white matter tracts and their 3D relationship with each other is important for neurosurgical practice. The fiber dissection technique contributes to this understanding because it involves removing the brain's white matter tracts to reveal their anatomic organization. Using this technique, we built freely accessible 3D models and augmented and virtual reality simulations of white matter tracts.

Method: Twenty cadaveric brain specimens were prepared in accordance with the Klingler method. Brain hemispheres were dissected step-by-step from lateral-to-medial and medial-to-lateral directions. Three-dimensional models and augmented reality and virtual reality simulations were built with photogrammetry.

Results: High-resolution 3D models and augmented reality and virtual reality simu- lations of the white matter anatomy of the cerebrum were obtained. These models can be freely shifted and rotated on different planes, projected on any real surface, visualized from both front and back, and viewed from various angles at various magnifications.

Figure 1

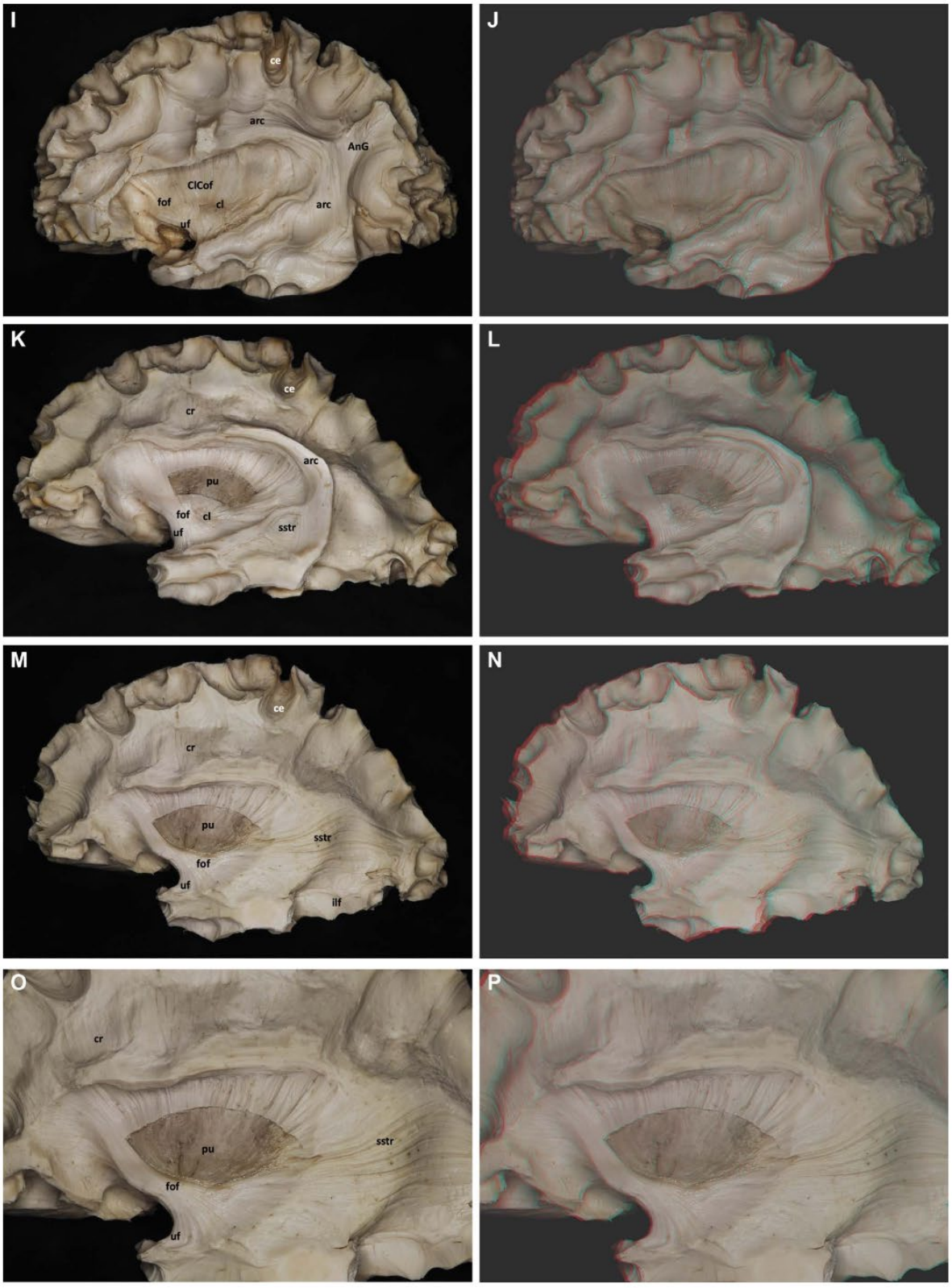
I
ce
arc
AnG
ClCof
fof
cl
arc
uf
J
K
ce
cr
arc
pu
fof
cl
sstr
uf
L
M
ce
cr
pu
sstr
fof
uf
ilf
N
O
cr
pu
sstr
fof
uf
P

Figure 2

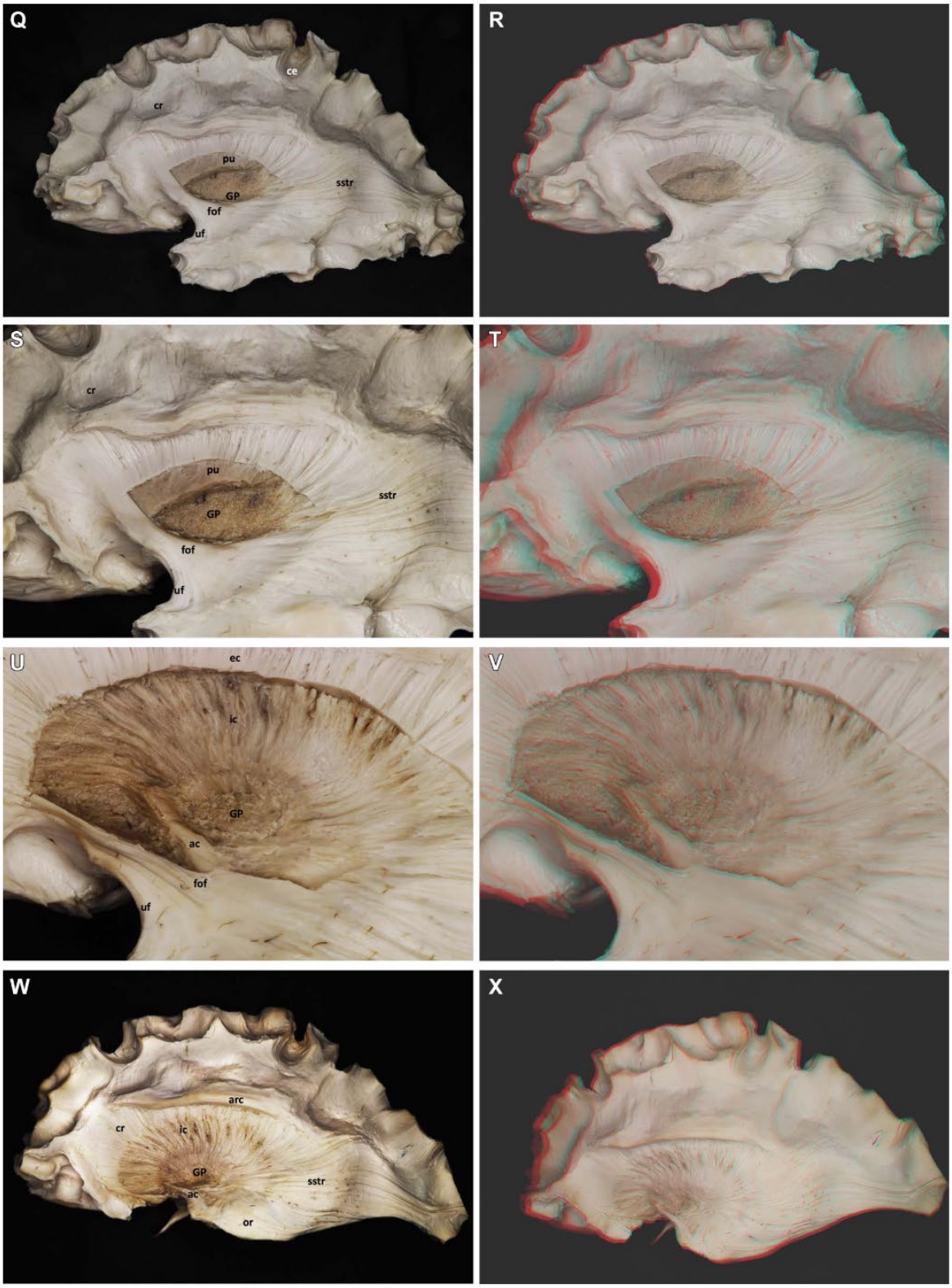
Q
ce
cr
pu
sstr
GP
fof
uf
R
S
cr
pu
sstr
GP
fof
uf
T
U
ec
ic
GP
ac
fof
uf
V
W
arc
cr
ic
GP
sstr
ac
or
X

figure 3

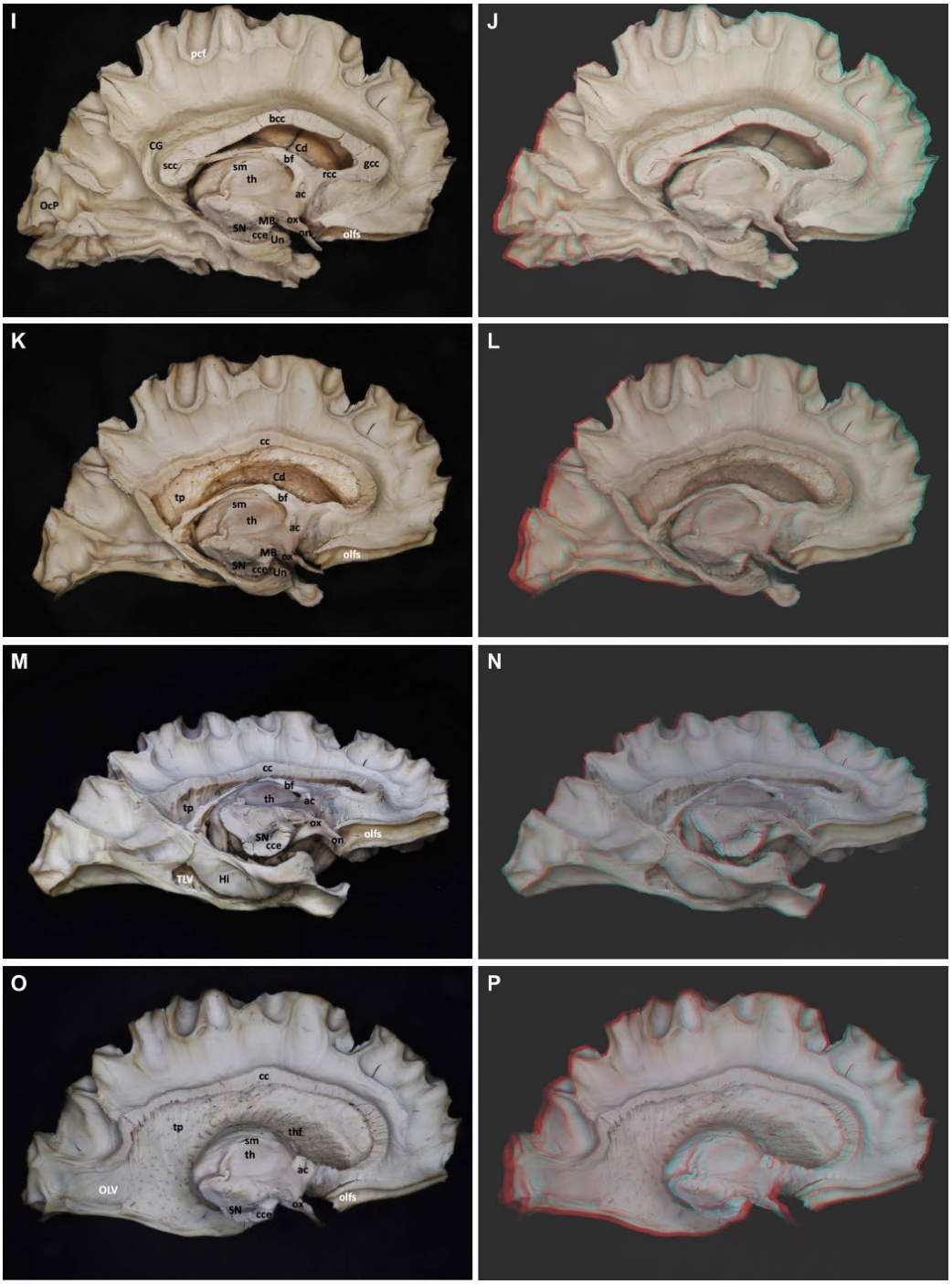

Conclusions: To our knowledge, this is the first detailed study integrating various technologies (3D modeling, augmented reality, and virtual reality) for high-resolution 3D visualization of dissected white matter fibers of the entire human cerebrum.

Keywords: 3D modeling, Virtual reality, Neuroanatomy, Augmented reality

References

1. Türe U, Yaşargil MG, Friedman AH, Al-Mefty O. Fiber dissection technique: lateral aspect of the brain. Neurosurgery. 2000;47(2):417-426; discussion 426-427.
2. Silva SM, Andrade JP. Neuroanatomy: the added value of the Klingler method. Ann Anat. 2016;208:187-193.
3. Agrawal A, Kapfhammer JP, Kress A, et al. Josef Klingler's models of white matter tracts: influences on neuroanatomy, neurosurgery, and neuroimaging. Neurosurgery. 2011;69(2):238-252; discussion 252-254.
4. Türe U, Yaşargil DC, Al-Mefty O, Yaşargil MG. Topographic anatomy of the insular region. J Neurosurg. 1999;90(4):720-733.
5. Kucukyuruk B, Yagmurlu K, Tanriover N, Uzan M, Rhoton AL Jr. Microsurgical anatomy of the white matter tracts in hemispherotomy. Neurosurgery. 2014;10(suppl 2):305-324; discussion 324.
6. Ribas EC, Yagmurlu K, Wen HT, Rhoton AL Jr. Microsurgical anatomy of the inferior limiting insular sulcus and the temporal stem. J Neurosurg. 2015;122(6):1263-1273.
7. Yagmurlu K, Vlasak AL, Rhoton AL Jr. Three-dimensional topographic fiber tract anatomy of the cerebrum. Neurosurgery. 2015;11(suppl 2):274-305; discussion 305.
8. Güngör A, Baydin S, Middlebrooks EH, Tanriover N, Isler C, Rhoton AL Jr. The white matter tracts of the cerebrum in ventricular surgery and hydrocephalus. J Neurosurg. 2017;126(3):945-971.
9. Ribas EC, Yağmurlu K, de Oliveira E, Ribas GC, Rhoton A. Microsurgical anatomy of the central core of the brain. J Neurosurg. 2018;129(3):752-769.
10. Párraga RG, Possatti LL, Alves RV, Ribas GC, Türe U, de Oliveira E. Microsurgical anatomy and internal architecture of the brainstem in 3D images: surgical considerations. J Neurosurg. 2016;124(5):1377-1395.
11. Serra C, Türe U, Krayenbühl N, Şengül G, Yaşargil DC, Yaşargil MG. Topographic classification of the thalamus surfaces related to microneurosurgery: a White matter fiber microdissection study. World Neurosurg. 2017;97:438-452.
12. Johnson EO, Charchanti AV, Troupis TG. Modernization of an anatomy class: from conceptualization to implementation. A case for integrated multimodal-multidisciplinary teaching. Anat Sci Educ. 2012;5(6):354-366.
13. Meakin JR, Shepherd DE, Hukins DW. Short communication: fused deposition models from CT scans. Br J Radiol. 2004;77(918):504-507.
14. Müller A, Krishnan KG, Uhl E, Mast G. The application of rapid prototyping techniques in cranial reconstruction and preoperative planning in neurosurgery. J Craniofac Surg. 2003;14(6):899-914.
15. Harput MV, Gonzalez-Lopez P, Türe U. Three-dimensional reconstruction of the topographical cerebral surface anatomy for presurgical planning with free OsiriX Software. Neurosurgery. 2014;10(suppl 3):426-435; discussion 435.
16. Kelley DJ, Farhoud M, Meyerand ME, et al. Creating physical 3D stereolithograph models of brain and skull. PLoS One. 2007;2(10):e1119.
17. Fernandez-Miranda JC, Rhoton AL Jr, Alvarez-Linera J, Kakizawa Y, Choi C, de Oliveira EP. Three-dimensional microsurgical and tractographic anatomy of the white matter of the human brain. Neurosurgery. 2008;62(6 suppl 3):989-1026. discussion 1026-1028.
18. Lukic IK, Gluncic V, Ivkic G, Hubenstorf M, Marusic A. Virtual dissection: a lesson from the 18th century. Lancet. 2003;362(9401):2110-2113.
19. Chen JC, Amar AP, Levy ML, Apuzzo ML. The development of anatomic art and sciences: the ceroplastica anatomic models of La Specola. Neurosurgery. 1999;45(4):883-891; discussion 891-892.
20. Akbaş A, Tuğcu B, Ekşi MŞ, et al. Robotic surgical approach to the mesial temporal region: a preliminary three-dimensional cadaveric study of technical feasibility. World Neurosurg. 2020;144:e40-e52.
21. Petriceks AH, Peterson AS, Angeles M, Brown WP, Srivastava S. Photogrammetry of human specimens: an innovation in anatomy education. J Med Educ Curric Dev. 2018;5:2382120518799356.

22. Huang KT, Ball C, Francis J, Ratan R, Boumis J, Fordham J. Augmented versus virtual reality in education: an exploratory study examining science knowledge retention when using augmented reality/virtual reality mobile applications. Cyberpsychol Behav Soc Netw. 2019;22(2):105-110.
23. Gurses ME, Gungor A, Hanalioglu S, et al. Qlone®: a simple method to create 360-degree photogrammetry-based 3-dimensional model of cadaveric specimens. Oper Neurosurg. 2021;21(6):E488-E493.
24. The Neurosurgical Atlas. https://www.neurosurgicalatlas.com/. Accessed Web. January 30, 2022.
25. Martino J, Hamer PC, Berger MS, et al. Analysis of the subcomponents and cortical terminations of the perisylvian superior longitudinal fasciculus: a fiber dissection and DTI tractography study. Brain Struct Funct. 2013;218(1):105-121.26. Uddin LQ, Nomi JS, Hebert-Seropian B, Ghaziri J, Boucher O. Structure and function of the human insula. J Clin Neurophysiol. 2017;34(4):300-306.
26. Peltier J, Verclytte S, Delmaire C, Pruvo JP, Havet E, Le Gars D. Microsurgical anatomy of the anterior commissure: correlations with diffusion tensor imaging fiber tracking and clinical relevance. Neurosurgery. 2011;69(2 suppl operative):ONS241-ONS246; discussion ons241-ons247.
27. Di Carlo DT, Benedetto N, Duffau H, et al. Microsurgical anatomy of the sagittal stratum. Acta Neurochir. 2019;161(11):2319-2327.
28. Bubb EJ, Metzler-Baddeley C, Aggleton JP. The cingulum bundle: anatomy, function, and dysfunction. Neurosci Biobehav Rev. 2018;92:104-127.
29. Teyler TJ, DiScenna P. The topological anatomy of the hippocampus: a clue to its function. Brain Res Bull. 1984;12(6):711-719.
30. Giap BT, Jong CN, Ricker JH, Cullen NK, Zafonte RD. The hippocampus: anatomy, pathophysiology, and regenerative capacity. J Head Trauma Rehabil. 2000;15(3):875-894.
31. Ozer MA, Kayalioglu G, Erturk M. Topographic anatomy of the fornix as a guide for the transcallosal-interforniceal approach with a special emphasis on sex differences. Neurol Med Chir (Tokyo). 2005;45(12):607-612; discussion 12-13.
32. Estevez ME, Lindgren KA, Bergethon PR. A novel three-dimensional tool for teaching human neuroanatomy. Anat Sci Educ. 2010;3(6):309-317.
33. Wysiadecki G, Clarke E, Polguj M, Haladaj R, Zytkowski A, Topol M. Klingler's method of brain dissection: review of the technique including its usefulness in practical neuroanatomy teaching, neurosurgery and neuroimaging. Folia Morphol (Warsz). 2019;78(3):455-466.
34. Drake RL, McBride JM, Lachman N, Pawlina W. Medical education in the anatomical sciences: the winds of change continue to blow. Anat Sci Educ. 2009;2(6):253-259.
35. Kockro RA, Amaxopoulou C, Killeen T, et al. Stereoscopic neuroanatomy lectures using a three-dimensional virtual reality environment. Ann Anat. 2015;201:91-98.
36. McMenamin PG, Quayle MR, McHenry CR, Adams JW. The production of anatomical teaching resources using three-dimensional (3D) printing technology. Anat Sci Educ. 2014;7(6):479-486.
37. Riva G, Wiederhold BK. The New Dawn of virtual reality in health care: medical simulation and experiential interface. Stud Health Technol Inform. 2015;219:3-6.
38. Rizzolo LJ, Rando WC, O'Brien MK, Haims AH, Abrahams JJ, Stewart WB. Design, implementation, and evaluation of an innovative anatomy course. Anat Sci Educ. 2010;3(3):109-120.
39. The Rhoton Collection. http://rhoton.ineurodb.org/mobile. Accessed Web. March, 10 2021.

OP-III/83

Treatment strategy and surgical technique for tumor resection in and around the cavernous sinus

Taketoshi Maehara[1], Takashi Sugawara[1]

[1]Department of Neurosurgery, Tokyo Medical and Dental University

Objectives: We show the surgical strategies and techniques with intraoperative video, also clinical outcome.

Background: Radical resection of tumor in and around cavernous sins is still challenging due to risk of cranial nerves injury. In this presentation.

Method: Surgical resection is indicated for patients with neurological symptoms. The lesion in cavernous sinus is removed as much as possible while preserving cranial nerves. The tumor in the cavernous sinus is left if the tumor is deemed too firm to be removed without damaging the cranial nerves. When the patient has neurological symptoms of diplopia, ptosis, and visual field disturbance, the optic sheath and oculomotor cave are opened wide, and the lesions there are removed aggressively to restore its function. Preoperative symptoms and their postoperative course (especially oculomotor, abducens, optic nerve function) were evaluated in 23 surgically resected cases (14 meningiomas, 4 schwannomas, 2 chondrosarcomas, 3 others).

Results: Tumor resection was performed with the aim of restoring the function of oculomotor, abducens, and optic nerve in 9, 8, and 7 patients respectively. And this functional recovery was achieved completely in 7(78%), 5(63%), and 1(14%) patients and partially in 1(11%), 1(13%), and 6(86%) patients respectively. Postoperative complications were brief transient hemiparesis by IC dissection or vasospasm in 2 cases. Gross total removal was achieved in 8 case and 15 cases were partially removed with remnant mainly in cavernous sinus. Four residual WHO grade II meningiomas in cavernous sinus underwent IMRT. Three meningiomas recurred or regrew and underwent IMRT or γknife radiosurgery and these lesions have been well controlled.

cavernous sinus lateral wall exposure

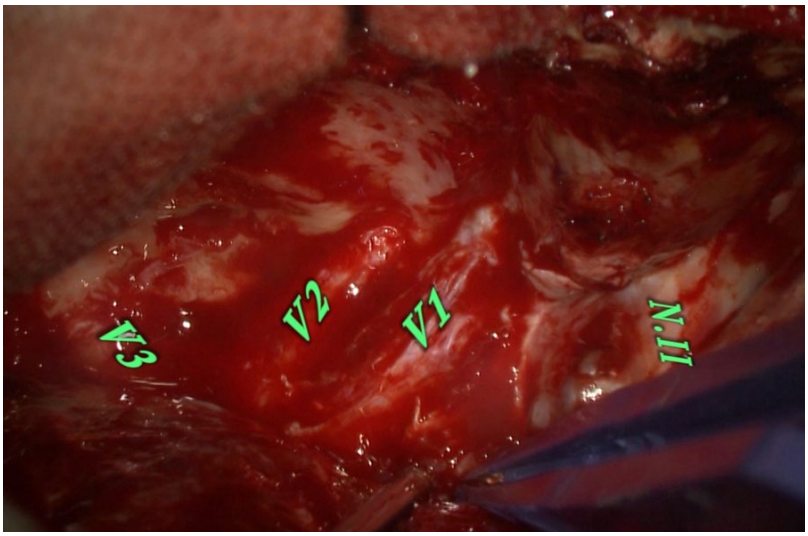

Oculomotor cave opening and oculomotor nerve decompression

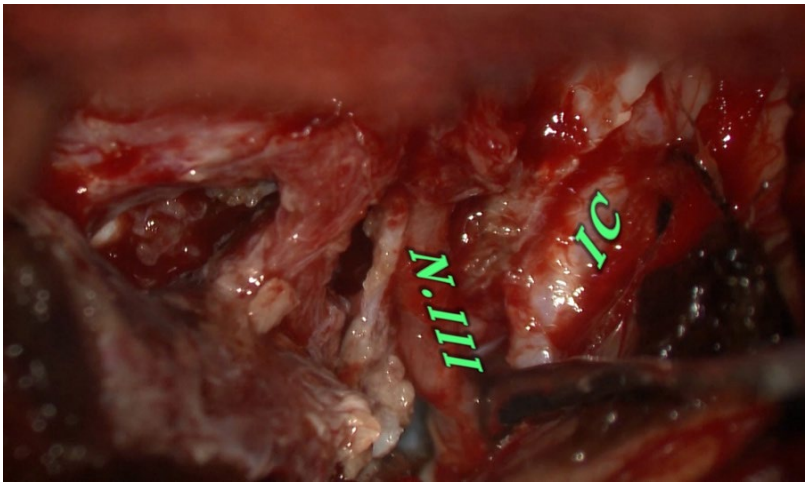

Conclusions: In surgical resection of tumor around the cavernous sinus to restore the cranial nerve function, functional recovery was accomplished at a higher rate, especially for the oculomotor and optic nerves. And most of these tumors can be well controlled with only acceptable transient insult by careful and delicate procedure.

Keywords: skull base surgery, cavernous sinus lesion, tumor resection, oculomotor nerve

References

AF K (2005) Transcavernous Approach to Diseases of the Anterior Upper Third of the Posterior Fossa. Neurosurg Focus 19 JA H, O A-M (2003) Cavernous Sinus Meningiomas. Neurosurg Focus 14.

OP-I/84

A 3D Exploration of Ventricles and Adjacent Structures

Umut Tan Sevgi[1], Gökberk Erol[3], Osman Fikret Sönmez[1], Serdar Rahmanov[2], Yücel Doğruel[2], Abuzer Güngör[4]

[1]Department of Neurosurgery, University of Health Sciences, Tepecik Training and Research Hospital, Izmir, Turkey
[2]Department of Neurosurgery, Yeditepe University Microsurgical Neuroanatomy Laboratory, Istanbul, Turkey
[3]Department of Neurosurgery, Faculty of Medicine, Gazi University, Ankara, Turkey
[4]Department of Neurosurgery, University of Health Sciences, Bakirkoy Research and Training Hospital for Neurology, Neurosurgery and Psychiatry, Istanbul, Turkey

Objectives: To provide a comprehensive three-dimensional representation of the ventricular system and its relationship with surrounding structures using 3D models.To investigate the implications of this detailed anatomical model for neurosurgical planning and training

Background: Given the complexity of intracranial anatomy, a thorough understanding of the spatial relationships between the ventricular system and surrounding structures is critical for neurosurgeons. Traditional two-dimensional models are limited in their ability to accurately depict these relationships and require the development of a more comprehensive three-dimensional model.

Method: 5 cerebral hemispheres were fixed with the Klingler method. The ventricles were scanned and 3D models were created by photogrammetry to show the ventricles and the structures within and adjacent to them, as well as to increase the three-dimensional orientation.

Results: The resulting 3D model offers a detailed view of the ventricular system, including the lateral, third, and fourth ventricles, as well as their connections via the interventricular foramen and cerebral aqueduct. The model also distinctly portrays adjacent structures such as the corpus callosum, thalamus, hypothalamus, and basal ganglia.The model's high level of detail and accuracy illuminates the intimate relationships between these structures and the ventricular system. For instance, the proximity of the ventricles to the internal capsule and basal ganglia underscores the potential risks during surgical interventions, especially those targeting deep-seated brain lesions or performing ventricular drainage.

Posterosuperior View of Lateral Ventricles and Related Structures using a 3D model



Posterosuperolateral View of Atrium and Related Structures using a 3D model



View of one of the specimens in the program interface

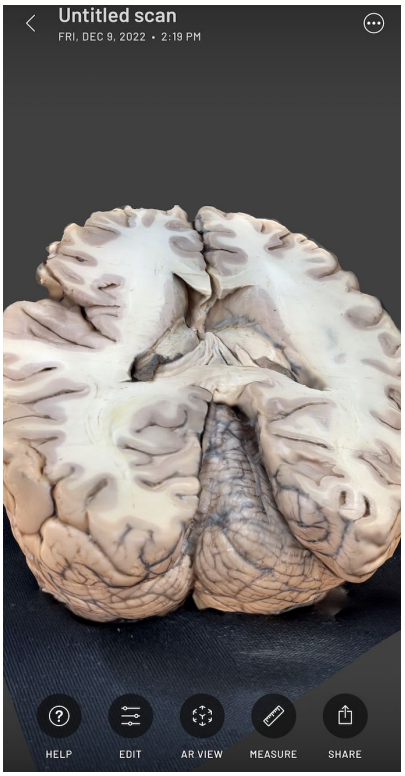

Conclusions: Our 3D model of the ventricular system and surrounding anatomy, constructed using photogrammetry and white matter dissection techniques, offers an unprecedented tool for neurosurgical planning and education. The model's depiction of intricate anatomical relationships can assist neurosurgeons in minimizing risks during surgical interventions. Future work will incorporate the model into surgical simulators and adjust it for anatomical variations.

Keywords: 3D Modeling, Neuroanatomy, Ventricles, White Matter

References

1) Gurses, M. E., Gungor, A., Hanalioglu, S., Yaltirik, C. K., Postuk, H. C., Berker, M., & Türe, U. (2021). Qlone®: A Simple Method to Create 360-Degree Photogrammetry-Based 3-Dimensional Model of Cadaveric Specimens. *Operative neurosurgery (Hagerstown, Md.)*, *21*(6), E488–E493. https://doi.org/10.1093/ons/opab355
2) Gurses, M. E., Gungor, A., Rahmanov, S., Gökalp, E., Hanalioglu, S., Berker, M., Cohen-Gadol, A. A., & Türe, U. (2022). Three-Dimensional Modeling and Augmented Reality and Virtual Reality Simulation of Fiber Dissection of the Cerebellum and Brainstem. *Operative neurosurgery (Hagerstown, Md.)*, *23*(5), 345–354. https://doi.org/10.1227/ons.0000000000000358
3) Baran, O., Baydin, S., Gungor, A., Balak, N., Middlebrooks, E., Saygi, T., Aydin, I., & Tanriover, N. (2019). Surgical Approaches to the Thalamus in Relation to the White Matter Tracts of the Cerebrum. *World neurosurgery*, *128*, e1048–e1086. https://doi.org/10.1016/j.wneu.2019.05.068
4) Güngör, A., Baydin, S., Middlebrooks, E. H., Tanriover, N., Isler, C., & Rhoton, A. L., Jr (2017). The white matter tracts of the cerebrum in ventricular surgery and hydrocephalus. *Journal of neurosurgery*, *126*(3), 945–971. https://doi.org/10.3171/2016.1.JNS152082

OP-II/85

Adding Cavernous-Petrous Drilling to Approach the Interpeduncular Cistern

Alhusain Nagm[1]

[1]Department of Neurosurgery University of Maryland School of Medicine, Baltimore, MD, United States

Objectives: To emphasize the importance of adding cavernous-petrous drilling to reach the interpeduncular cistern (IPC).

Background: Cadaveric simulation for IPC surgery is an indispensable prerequisite.

Method: Following completion of preparatory surgical steps (orbitozygomatic craniotomies, extradural anterior-clinoidectomies, cavernous sinus unlocking, releasing the oculomotor and trochlear nerves via opening the porous oculomotorius and detaching tentorial ligaments, respectively" and sylvian fissure dissections), 6 colored-injected formalin-fixed heads (12 sides) were dissected to review the benefit of adding cavernous-petrous (cavernous part of the petrous apex) drilling with intradural posterior clinoidectomy to expose to the IPC. Anatomical IPC-targets (n=10) were elected to understand the accessibility and maneuverability from the open microscopic surgical perspective. We did not cut the PcomA to reduce miscalculation errors. The data were collected and analyzed.

Results: Adding cavernous-petrous drilling to expose to the IPC allows reasonable visual validation and maneuverability for all (n=60 (10 x 6 heads)) targets (Basilar apex/trunk, 2 (ipsilateral/contralateral) posterior communicating arteries (PcomA), 2 posterior cerebral arteries, 2 superior cerebellar arteries, 2 oculomotor nerves, and mamillary bodies). It gives better proximal control for both low-seated/high riding basilar apices and overcomes the tunnel-like corridor for such deep targets. However, inevitable trigeminal nerve controlled-retraction was done to ensure safe drilling for the cavernous-petrous apex (ophthalmic division at risk). Besides, for right-handed surgeons, the right sided posterior clinoidectomy and temporary aneurysm clipping to the basilar trunk were done without handshaking (contrary, specific maneuvers with the non-dominant hands caries potential risk). Trochlear nerve injuries (n=3) were encountered during our initial IPC manipulations on the left side [25% (3/12) of all trochlear nerves = 5% of all targets (3/60)]. All other targets were anatomically preserved.

Figure 1

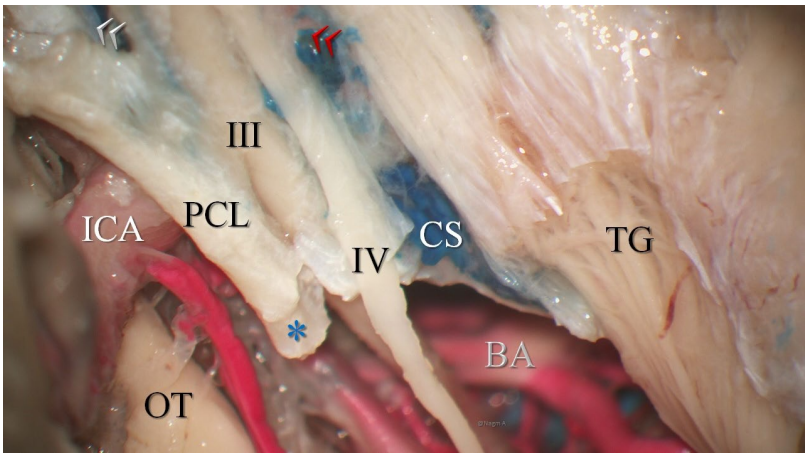

Figure 2

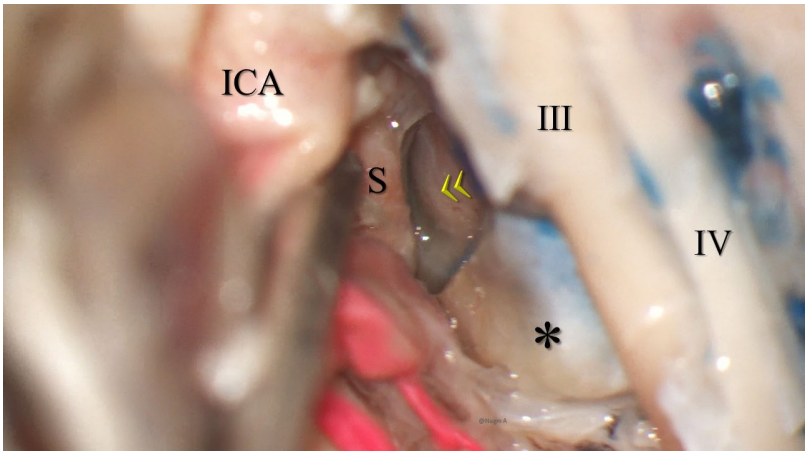

Figure 3

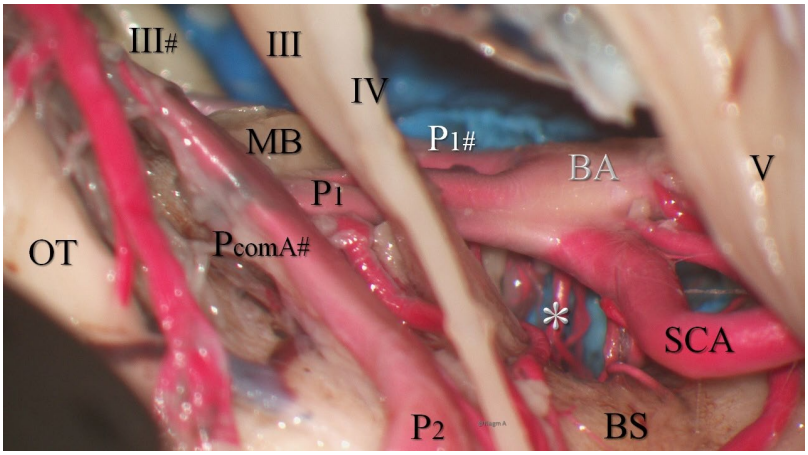

Conclusions: Adding cavernous-petrous drilling for IPC approaches is promising. It provides additional workspace. Clarifying the surgical targets and structures-at-risk benefits to the realization of limitations and providing prospective feedback for operative theatres.

Keywords: Cavernous Sinus, Petrous Apex, cadaveric dissection, Basila artery

References

1. Seoane E, Tedeschi H, de Oliveira E, Wen HT, Rhoton AL Jr. The pretemporal transcavernous approach to the interpeduncular and prepontine cisterns: microsurgical anatomy and technique application. Neurosurgery. 2000 Apr;46(4):891-8; discussion 898-9.

OP- V/86

Transfalx approach for removal of the brain tumors

Agadadash Kasymov[1], Anton Kalinovskiy[1], Sergeev Michael[1], Zotov Alexander[1], Ekaterina Gormolysova[1], Jamil Rzaev[1]

[1]FSBI "Federal Neurosurgical Center" Novosibirsk, Russia

Objectives: to evaluate the removal of tumors of the interhemispheric fissure through the contralateral interhemispheric approach in terms of efficiency, safety and preservation of brain structures around tumors

Background: Minimally invasive techniques in brain tumor surgery are the priority tasks for preserving the function of the structures of the central nervous system adjacent to tumors. The approaches through the natural arachnoid spaces avoiding additional trauma to the intact brain with dissection of the falx, can be an alternative to conventional direct approaches to the interhemispheric fissure tumors

Method: In the Department of Neurooncology of the Federal Center of Neurosurgery (Novosibirsk), 18 patients with tumors located in the interhemispheric fissure were operated. Surgical interventions using collateral transfalx approach were performed

fig. 1.

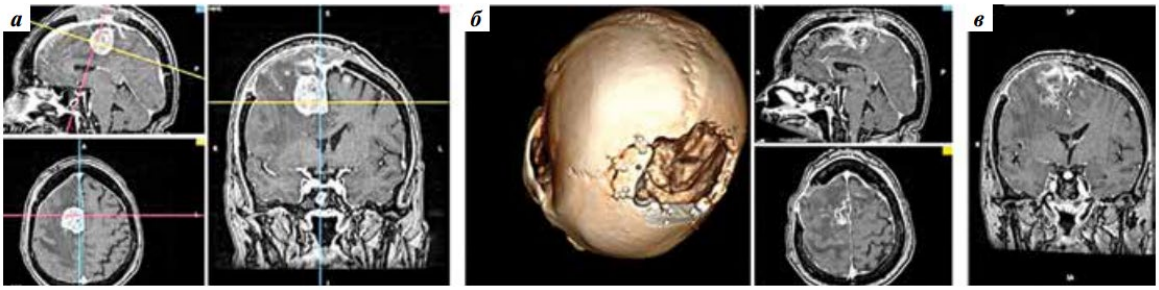

Brain Study: a – MRI (T1-weighted with contrast images) after an attempt to remove the tumor of the interhemispheric fissure from the side of the tumor complicated by severe cerebral edema; б – 3D-reconstruction of a CT-scan showing the dimensions of the primary resection trepanation and additional craniotomy performed during the 2nd operation when the tumor was removed through the contralateral transfalx approach; в – MRI (T1-weighted with contrast images) after removal of the tumor of the interhemispheric fissure through the transfalk contralateral approach

Fig. 2.

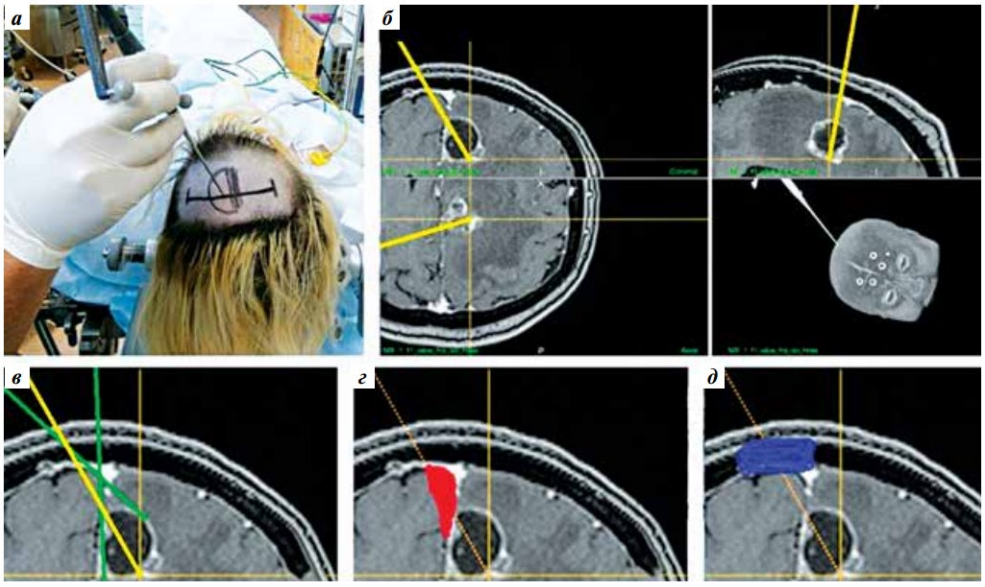

The position of the patient on the operating table, the projection of the approach and skin incision, planned using intraoperative navigation (а); the trajectory of the direction of the navigation pointer (yellow line) to the deepest part of the tumor (б); projection of lines of sight of the medial and lateral walls of the tumor (green lines) (в); the area of necessary brain traction (red) for an adequate view of the tumor (г); dimensions of the craniotomy (blue) to ensure adequate visibility and manipulation in the surgical field (д)

Main characteristics of patients operated through the contralateral transfalx approach

Patient number	Sex	Age, years	Location of tumor to falx	Pathology	Average size, mm	Clinical manifestations
1	m	71	1/3	mts of adenocarcinoma	25	epilepsy
2	f	65	2/3	meningioma	46	hemiparesis
3	f	49	1/3	meningioma	30	epilepsy
4	f	70	1/3	meningioma	41	-
5	f	44	1/3	meningioma	19	epilepsy
6	f	65	2/3	glioblastoma	35	hemiparesis
7	m	60	2/3	mts of clearcell carcinoma	12	epilepsy
8	f	66	1/3	meningioma	23	-
9	f	57	3/3	glioblastoma	27	hemiparesis
10	f	35	1/3	glioblastoma	40	hemiparesis
11	m	61	1/3	glioblastoma	41	-
12	f	50	2/3	mts of adenocarcinoma	29	hemiparesis

13	m	59	1/3	meningioma	43	epilepsy
14	f	64	1/3	mts of adenocarcinoma	23	hemiparesis
15	f	55	2/3	mts of adenocarcinoma	26	hemiparesis
16	m	56	2/3	glioblastoma	24	hemiparesis
17	f	59	1/3	mts of clearcell carcinoma	16	-
18	f	53	2/3	glioblastoma	42	hemiparesis
		average age: 57.7 ± 9.1			average size: 30.1 ± 10.2	

Location of tumor to falx: 1/3 – anterior third of falx; 2/3 – middle third of falx; 3/3 – posterior third of falx. Mts – tumor metastases.

Results: This paper presents the results of surgical treatment of 18 patients with tumors of the interhemispheric fissure of various histological structures, which underwent removal of the lesions through the contralateral transfalx approach. Radicality was achieved in 100 %. there was no increase in neurological deficit in the postoperative period, and the regression of neurological symptoms was noted in 67 % of cases.

Fig .3.

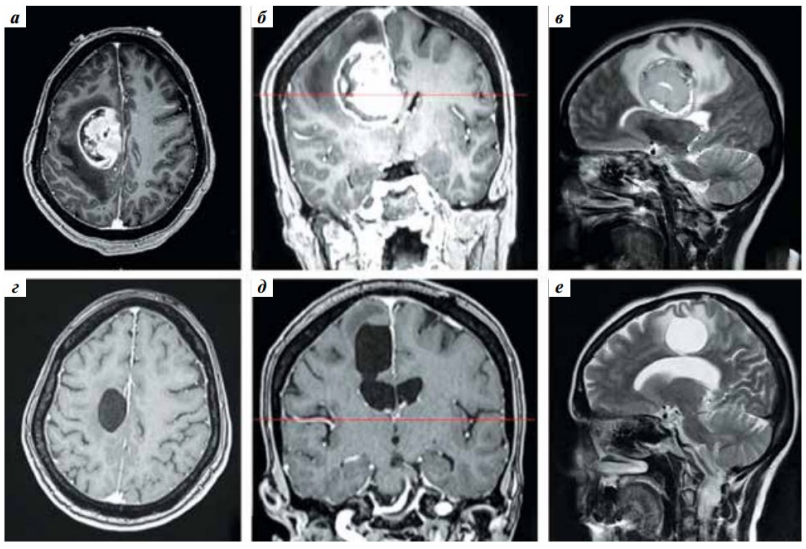

Preoperative T1-weighted axial and coronal contrast-enhanced MRI (а, б) and T2-weighted sagittal MRI (в) demonstrate an intracerebral tumor located in the posterior right frontal lobe adjacent to the falx, with severe perifocal edema around the tumor; postoperative T1-weighted MRI-examination 1 year after surgery with contrast enhancement in axial and coronal projections (г, д), and T2-weighted MRI-examination in sagittal projection (е) show no signs of tumor recurrence and additional damage along the perimeter of the postoperative cystic cavity and in the area of surgical approach

Results of surgical treatment

Patient number	Time of operation, min	Bloodloss, ml	Radical resection rate	Local symptooms pre-op	Local symptooms post-op
1	65	50	total	-	-
2	125	50	total	hemiparesis	regression
3	90	50	total	-	-
4	75	50	total	-	-
5	85	50	total	-	-
6	80	50	total	hemiparesis	regression
7	120	100	total	-	-
8	95	50	total	-	-
9	15	150	total	hemiparesis	the same
10	160	200	total	hemiparesis	the same
11	190	50	total	-	-
12	95	50	total	hemiparesis	regression
13	180	250	total	-	-
14	60	50	total	hemiparesis	regression
15	100	250	total	hemiparesis	the same
16	180	300	total	hemiparesis	regression
17	100	50	total	-	-
18	70	100	total	hemiparesis	regression
average	112 ± 42	105 ± 85 мл	100%	46%	13%

Conclusions: The contralateral transfalx approach can be recommended as an alternative option for the treatment of a number of patients with tumors of the interhemispheric fissure, as minimally invasive, less traumatic and effective.

Keywords: transfalx contralateral approach, minimally invasive removal of brain tumors, tumor of the interhemispheric fissure

References

1. Ellenbogen R.G., Scott R.M. Transfalcine approach to a callosomarginal artery aneurysm. Neurosurgery 1991;29(1): 140–3. DOI: 10.1097/00006123- 199107000-00028.
2. Goel A. Transfalcine approach to a contralateral hemispheric tumour. Acta Neurochir 1995;135:210–2. DOI: 10.1007/BF02187772.
3. Davies J., Tawk R.G., Lawton M.T. The contralateral transcingulate approach: Operative technique and results with vascular lesions. Operative Neurosurg 2012;71(Suppl 1):ons4–14. DOI: 10.1227/NEU.0b013e318246a7f8.
4. Lawton M.T., Golfinos J.G., Spetzler R.F. The contralateral transcallosal approach: experience with 32 patients. Neurosurgery 1996;39(4):729–34; DOI: 10.1097/ 00006123-199610000-00016.
5. Krylov V.V., Tkachev V.V., Dobrovolskiy G.F. Contralateral surgery of aneurysms. Moscow: Meditsina, 2002. 192 p. (In Russ.).
6. Rodríguez-Hernández A., Gabarrós A., Lawton M.T. Contralateral clipping of middle cerebral artery aneurysms: rationale, indications, and surgical technique. Neurosurgery 2012; 71(1 Suppl operative):116-24. DOI: 10.1227/NEU.0b013e31824d8f66.
7. Andrade-Barazarte H., Kivelev Yu., Goehre F. et al. Contralateral approach to internal carotid artery ophthalmic segment aneurysms: Angiographic analysis and surgical results for 30 Patients. Neurosurgery 2015;77(1):104–2. DOI: 10.1227/NEU.0000000000000742.
8. de Almeida G.M., Shibata M.K., Nakagawa E.J. Contralateral parafalcine approach for parasagittal and callosal arteriovenous malformations. Neurosurgery 1984;14(6):744–6. DOI: 10.1227/00006123-198406000- 00018.
9. García-García S., Gonzalez-Sanchez J.J., Gandhi S. et al Contralateral Transfalcine Versus Ipsilateral Anterior Interhemispheric Approach for Midline Arteriovenous Malformations: Surgical and Anatomical Assessment. World Neurosurg 2018;119:e1041–51. DOI: 10.1016/j.wneu.2018.08.074. 10. Stone J.L., Cybulsky G.R., Crowell R.M., Moody R.A. The lateral position – dependant occipital approach to pineal and medial occipitoparietal lesions. Technical note. Acta Neurochir (Wien) 1990;102(3–4):133–6. DOI:
10. 1007/BF01405427. 11. Xie T., Sun C., Zhang X. et al. The contralateral transfalcine transprecuneus approach to the atrium of the lateral ventricle: operative technique and surgical results. Neurosurgery 2015;11(Suppl 2):110–7; DOI: 10.1227/NEU.0000000000000643.

OP-I/87

Supraflocculer Transhorizontal Fissure Approach to the Cerebellopontine Angle: an Anatomical Study With Case Series

Pelin Kuzucu[1], Tolga Türkmen[1], Oğuz Kağan Demirtaş[2], Abuzer Güngör[3], Mesut Emre Yaman[1], Şükrü Aykol[1]

[1]Gazi University Faculty of Medicine
[2]Sincan Dr. Nafiz Körez State Hospital
[3]Yeditepe University Faculty of Medicine
[4]Bakırköy Research and Training Hospital for Psyhiatry, Neurology and Neurosurgery

Objectives: In this study, we aimed to demonstrate a previously described but not widely used method, the supraflocculer transshorizontal fissure approach with anatomical dissection on the cadaver, accompanied by a case presentation with the largest clinical series in the literature.

Figüre 1

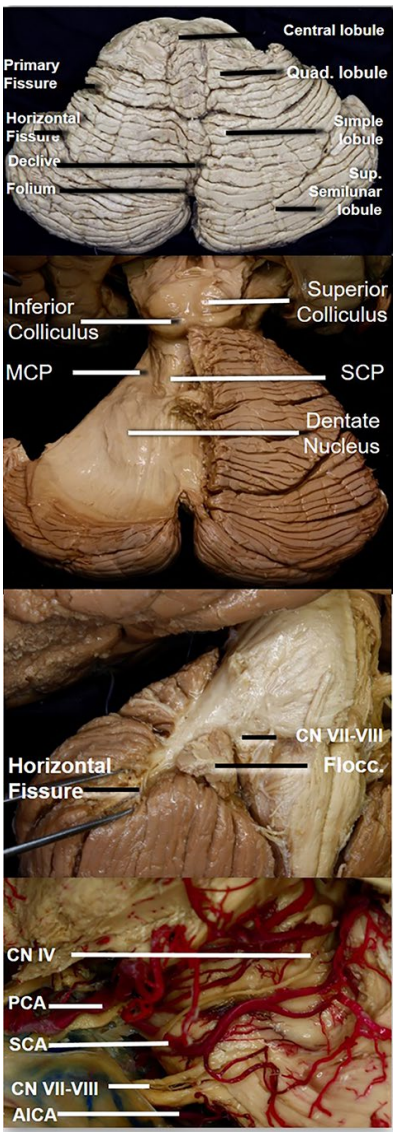

Cerebellum dissection steps performed from the cerebellar surface A: Anteroinferior view of the cerebrum, cerebellum, and brain stem. Here, the relationship between the supraflocculer lobule, brain stem, and cerebellum is seen. The middle cerebellar peduncle with major connections between the brain stem and the cerebellum is seen. Cranial nerve pairs originating around the supraflocculer lobe are also seen. B: Postero-superior view of the cerebellum. Horizontal fissure and primary fissure are seen between cerebellar lobules. The horizontal fissure forms the border between the superior semilunar lobule and the inferior semilunar lobule. It is divided into the following three lobes: the anterior lobe, the posterior lobe, and the flocculonodular lobe. It is separated by a primary and posterolateral fissure. The central core of the white matter is arranged in the form of the branching pattern of a tree, which is called arborvitae cerebelli (arborvitae = tree of life). C:The horizontal fissure was retracted with the help of forceps and its junction with the brain stem was shown. This fissure separates the superior surface from the inferior surface. D: Dissection images of SCA, AICA, PICA, and branches and related anatomical structures while continuing dissections.

Background: The horizontal fissure is the deepest and biggest V-shaped fissure of the cerebellum. With the supraflocculer transhorizontal fissure approach, which can be called a variant of classical retrosigmoid surgery, the complex skull base techniques and sacrifice of the cerebellar vascular structures to obtain sufficient exposure are unnecessary. It is possible to perform safe surgery with fissure dissections at the CPA just as the Sylvian fissure, which is a cerebral fissure, is routinely opened in the supratentorial region to access deep-seated pathology without dividing any nerve tissue.

Method: Klingler's protocol was used to prepare 8 silicone injected and 8 non silicone injected human hemispheres. A total of 210 patients who underwent surgery in the cerebellopontine angle between 2019 and 2022 were evaluated in our clinic. Of these, the supraflocculer transhorizontal fissure approach was applied in 33 patient, and it was successful in 26 patient, but this approach could not be achived in 7 patients.

Results: The transhorizontal fissure is a fissure in the cerebellum located between the superior semilunar lobule and the inferior semilunar lobule. In the 26 patients we operated with the supraflocculer trans horizontal fissure approach, there was no need for retraction and no complications developed. However, in 7 patients, this fissure could not be dissected due to adhesions.

Figüre 2

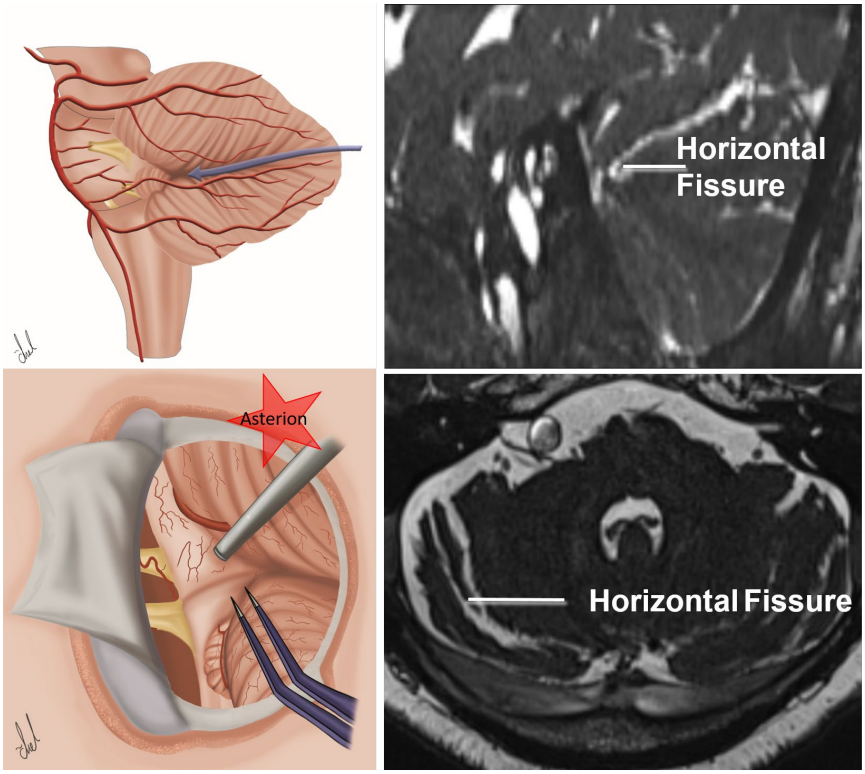

A: Illustration images of classical retrosigmoid approach with supraflocculer trans horizontal fissure approach B: The image of the large subarachnoid space of the horizontal fissure on the sagittal T2 MRI. The image of the axial T2 MRI, the subarachnoid space is wide and the fissure is easily visible is an indication that the supraflocculer trans horizontal fissure approach can be used surgically.

Figüre 3

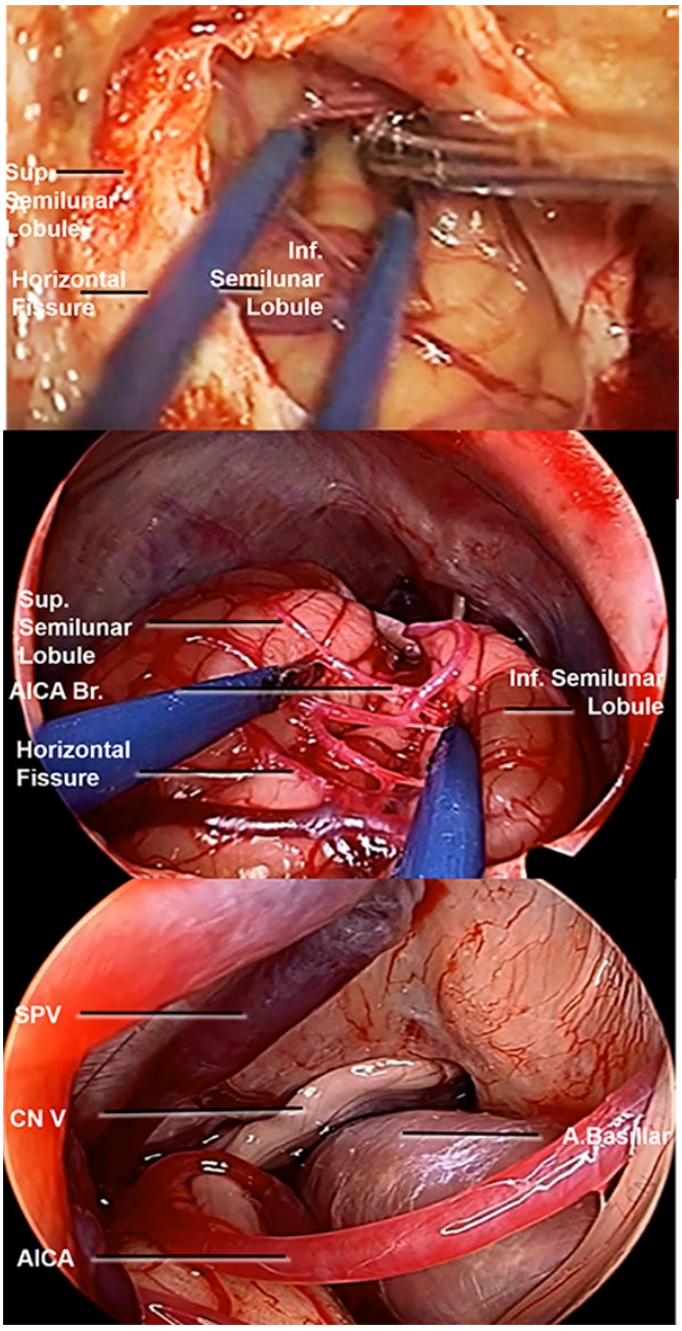

A: Intraoperative horizontal fissure dissection image with a microscope B: Reaching the cranial nerves after intraoperative horizontal fissure dissection with a microscope C: Intraoperative horizontal fissure dissection image with an endoscope-assisted technique S: Visualization of the relationship of cranial nerves and vascular structures after intraoperative, horizontal fissure dissection with the endoscope-assisted technique

Conclusions: Supraflocculer approach is an alternative to the classical retrosigmoid approach in tumors smaller than 2 cm, medially localized with little cerebellar edema and NVCS. Because in this approach; no cerebellum retraction is required, vascular structures are better preserved and the surgical time is shortened.

Keywords: Supraflocculer Transshorizontal Fissure, Retrosigmoid Approaches, Petrosal Fissure, Neurovascular Compression Syndrome

References

1. Akkaya E, Gokcil Z, Erbas C, Pusat S, Kazak Bengisun Z, Erdogan E (2019) A clinical analysis of microvascular decompression surgery with sacrification of the superior petrosal venous complex for trigeminal neuralgia: a single-surgeon experience. Turkish Neurosurgery. doi: 10.5137/1019-5149.JTN.26555-19.3
2. Ansari SF, Terry C, Cohen-Gadol AA (2012) Surgery for vestibular schwannomas: a systematic review of complications by approach. Neurosurg Focus 33:E14. doi: 10.3171/2012.6.FOCUS12163
3. Blue R, Li C, Spadola M, Saylany A, McShane B, Lee JYK (2020) Complication Rates During Endoscopic Microvascular Decompression Surgery Are Low With or Without Petrosal Vein Sacrifice. World Neurosurg 138:e420–e425. doi: 10.1016/j.wneu.2020.02.142
4. Distelmaier P (1976) [Complications of the operative neurosurgical treatment of trigeminal neuralgia]. Zentralbl Neurochir 37:119–125
5. Dumot C, Sindou M (2015) Trigeminal neuralgia due to neurovascular conflicts from venous origin: an anatomical-surgical study (consecutive series of 124 operated cases). Acta Neurochir (Wien) 157:455–466. doi: 10.1007/s00701-014-2330-3
6. Elhammady MS, Telischi FF, Morcos JJ (2012) Retrosigmoid approach: indications, techniques, and results. Otolaryngol Clin North Am 45:375–397, ix. doi: 10.1016/j.otc.2012.02.001
7. Fujimaki T, Kirino T (2000) Combined transhorizontal-supracerebellar approach for microvascular decompression of trigeminal neuralgia. Br J Neurosurg 14:531–534. doi: 10.1080/02688690020005536
8. Kalani MYS, Yagmurlu K, Martirosyan NL, Spetzler RF (2016) The Retrosigmoid Petrosal Fissure Transpeduncular Approach to Central Pontine Lesions. World Neurosurg 87:235–241. doi: 10.1016/j.wneu.2015.11.025
9. Liebelt BD, Barber SM, Desai VR, Harper R, Zhang J, Parrish R, Baskin DS, Trask T, Britz GW (2017) Superior Petrosal Vein Sacrifice During Microvascular Decompression: Perioperative Complication Rates and Comparison with Venous Preservation. World Neurosurg 104:788–794. doi: 10.1016/j.wneu.2017.05.098
10. Matsushima K, Yagmurlu K, Kohno M, Rhoton AL (2016) Anatomy and approaches along the cerebellar-brainstem fissures. J Neurosurg 124:248–263. doi: 10.3171/2015.2.JNS142707
11. Ohue S, Fukushima T, Friedman AH, Kumon Y, Ohnishi T (2010) Retrosigmoid supraflocculer transhorizontal fissure approach for resection of brainstem cavernous malformation. Neurosurgery 66:306–312; discussion 312-313. doi: 10.1227/01.NEU.0000369703.67562.BB
12. Sattari SA, Shahbandi A, Xu R, Hung A, Feghali J, Yang W, Lee RP, Bettegowda C, Huang J (2022) Sacrifice or preserve the superior petrosal vein in microvascular decompression surgery: a systematic review and meta-analysis. Journal of Neurosurgery 1:1–9. doi: 10.3171/2022.5.JNS22143
13. Schneider JR, Chiluwal AK, Nouri M, Prashant GN, Dehdashti AR (2022) Retrosigmoid transhorizontal fissure approach to lateral pontine cavernous malformation: comparison to transpetrosal presigmoid retrolabyrinthine approach. Journal of Neurosurgery 136:205–214. doi: 10.3171/2020.12.JNS203608
14. Sindou M, Howeidy T, Acevedo G (2002) Anatomical observations during microvascular decompression for idiopathic trigeminal neuralgia (with correlations between topography of pain and site of the neurovascular conflict). Prospective study in a series of 579 patients. Acta Neurochir (Wien) 144:1–12; discussion 12-13. doi: 10.1007/s701-002-8269-4

15. Strauss C, Naraghi R, Bischoff B, Huk WJ, Romstöck J (2000) Contralateral hearing loss as an effect of venous congestion at the ipsilateral inferior colliculus after microvascular decompression: report of a case. J Neurol Neurosurg Psychiatry 69:679–682. doi: 10.1136/jnnp.69.5.679
16. Sultan F, Hamodeh S, Baizer JS (2010) The human dentate nucleus: a complex shape untangled. Neuroscience 167:965–968. doi: 10.1016/j.neuroscience.2010.03.007
17. Tamura R, Katayama M, Yamamoto K, Horiguchi T (2021) Suboccipital Transhorizontal Fissure Approach for Posterior Cranial Fossa Lesions: A Cadaveric Study and First Clinical Experience. Operative Neurosurgery 21:E479–E487. doi: 10.1093/ons/opab345
18. Tsukamoto H, Matsushima T, Fujiwara S, Fukui M (1993) Peduncular hallucinosis following microvascular decompression for trigeminal neuralgia: case report. Surg Neurol 40:31–34. doi: 10.1016/0090-3019(93)90166-x
19. Watanabe T, Katayama Y, Fukushima T, Kawamata T (2011) Lateral supracerebellar transtentorial approach for petroclival meningiomas: operative technique and outcome. J Neurosurg 115:49–54. doi: 10.3171/2011.2.JNS101759
20. Xia Y, Kim TY, Mashouf LA, Patel KK, Xu R, Casaos J, Choi J, Kim ES, Hung AL, Wu A, Garzon-Muvdi T, Bender MT, Jackson CM, Bettegowda C, Lim M (2020) Absence of Ischemic Injury after Sacrificing the Superior Petrosal Vein during Microvascular Decompression. Oper Neurosurg (Hagerstown) 18:316–320. doi: 10.1093/ons/opz163
21. Zhu J, Zhong J, Jiao W, Zhou Q-M, Guan H-X, Dou N-N, Wang Y-N, Xia L, Li S-T (2014) Via-cerebellar-fissures approach for microvascular decompression of trigeminal nerve. J Craniofac Surg 25:1438–1440. doi: 10.1097/SCS.0000000000000780

OP-III/88

Management Outcomes for Ruptured Middle Cerebral Artery Aneurysms: A Single-Center Analysis of Clipping and Coiling Techniques

Iroda Mammadinova[1], Chingiz Nurimanov[1], Yerbol Makhambetov[1]

[1]National Centre For Neurosurgery

Objectives: We studied the outcomes of patients with ruptured middle cerebral artery aneurysms, specifically comparing the effectiveness of clipping and coiling techniques in a single-center study.

Background: The middle cerebral artery is a common site for ruptured intracranial aneurysms, ranking third in frequency. The Subarachnoid Aneurysm Trial study showed improved outcomes after one year for patients with small, good-grade ruptured aneurysms in the anterior circulation who underwent endovascular coiling. However, the Barrow Ruptured Aneurysm Trial focused on acutely ruptured aneurysms and suggested that microsurgical clipping of MCA aneurysms may have better long-term anatomical outcomes. Despite the lack of conclusive evidence, the optimal management of MCA aneurysms remains uncertain, leading to continued use of surgical approaches in their treatment.

Method: We analyzed patients with ruptured MCA aneurysms at our institution from 2010 to 2020. The choice between clipping or coiling was determined through personalized evaluations by our team of neurosurgeons.

Results: The study included 288 patients with ruptured MCA aneurysms. Among them, 51.39% underwent clipping and 48.61% underwent coiling. The average age was 50.00±11.42, with a majority of female patients (61.11%). In the endovascular treatment group, 68.91% of patients achieved a Raymond-Roy occlusion grade of 1. Post-treatment complications were observed in 8.78% of the clipping group and 10% of the coiling group. During the 1-year follow-up, recanalization rates were 1.3% in the clipping group and 10% in the coiling group. In the subsequent follow-up period (2 to 10 years), the death rate was 6.75% in the clipping group and 12.85% in the coiling group.

Conclusions: In our study on patients with ruptured middle cerebral artery aneurysms, both clipping and coiling techniques were used equally. Our findings suggest that clipping is a more favorable treatment option for ruptured middle cerebral artery (MCA) aneurysms, showing lower rates of recanalization and mortality compared to coiling.

Keywords: ruptured aneurysm, MCA aneurysm, clipping, endovascular treatment

OP-I/89

Posterior midline transaxial odontoidectomy: a morphometric study

İhsan Doğan[1], Macit Terzi[1], Yusuf Cem Kuzukıran[1], Halit Anıl Eray[1], Murat Büyüktepe[2], Eyüp Bayatlı[1]

[1]Ankara University Department of Neurosurgery
[2]Ünye State Hospital, Department of Neurosurgery

Objectives: To present the anatomical details related to the posterior midline transaxial odontoidectomy

Background: The anatomy of the craniovertebral junction, the atlas and axis hold immense importance in terms of their unique morphology and complex relationships with the vertebral artery. Odontoid process resections techniques provide effective anterior cervicomedullary decompression in craniocervical junction pathologies seen in various diseases.(1,5)

Method: The anatomy of the craniovertebral junction and axis was studied on 42 cadaveric axis bones and morphometric data was evaluated.

Results: Posteromedial point of the lateral atlantoaxial joint (PMEP) was defined, which reached by advancing an average of 20.56 mm on the lamina from the spinous process of the axis, which is an important anatomical point for surgery. After reaching this point, the base of the odontoid process reached by turning medially and advancing subligamentously. Foramen transversium is located 7.45 cm from the PMEP point, at 76 degrees anterolaterally, therefore, its relationship with the vertebral artery should be known while advancing. From the PMEP point, advancing at an angle of the 55 degree either side of the axis bone; however the right side 14 mm, on the left side 13 mm considered sufficient to reach posterior odontoid base . The distance of the PMEP point to odontoid tip measured as 26.74 mm on the right and 26.58 mm on the left. On coranel plane, angle of the PMEP point with odontoid tip measured as 55.61 degrees on the right and 55.33 degrees on the left.

Measurments

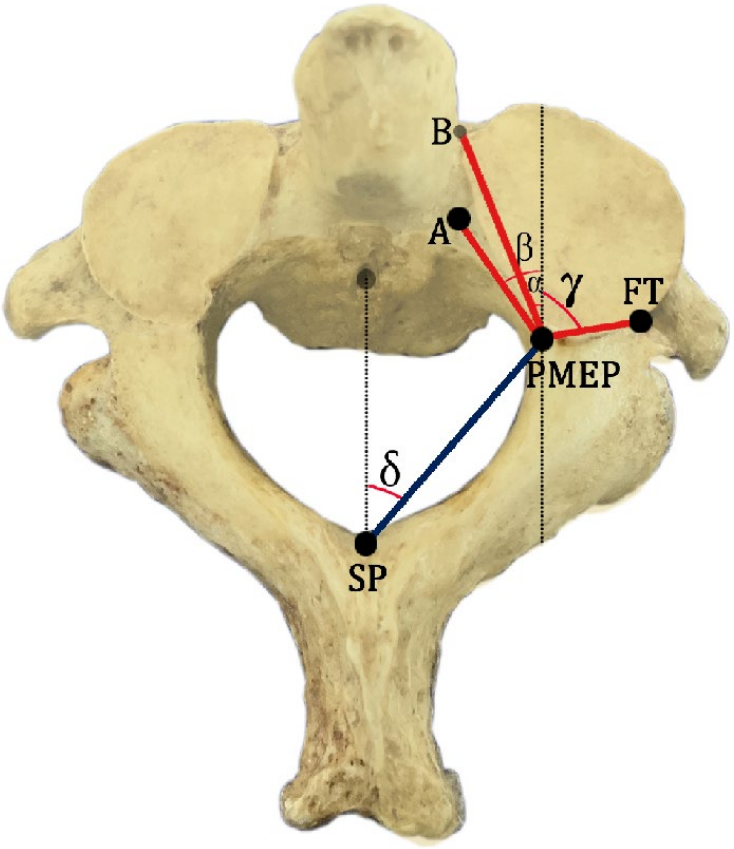

Measurements 2

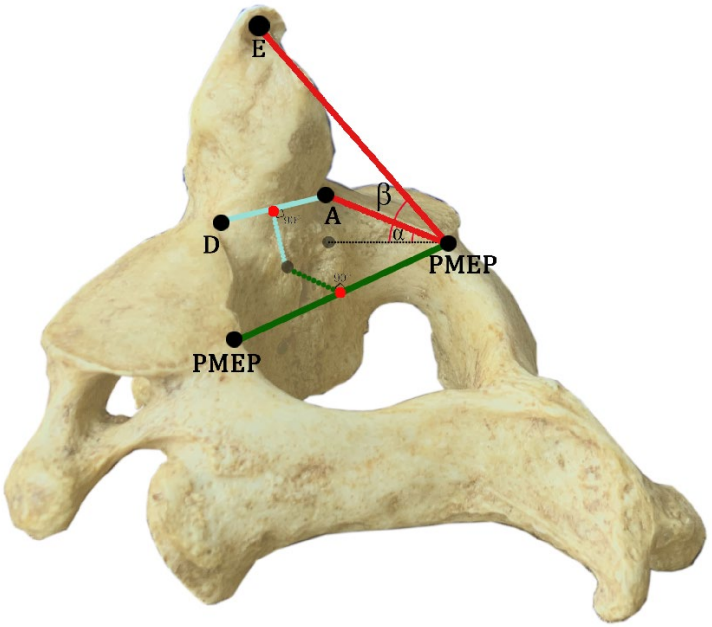

Conclusions: The posterior transaxis approach is defined as a new surgical technique that reduces the high complication rates of surgeries performed with anterior and posterolateral approaches.(2,3,4) In addition, this approach allows occipitocervical stabilization without requiring a change of position.(5)

Keywords: Neuroanatomy, Odontoidectomy, Craniovertebral, Axis

References

1. Dickman CA, Locantro J, Fessler RG. The influence of transoral odontoid resection on stability of the craniovertebral junction. *J Neurosurg*. 1992;77(4):525-530.
2. Kanavel AB. Bullet located between the atlas and the base of the skull: Technic of removal through the mouth. *Surg Clin Chic*. 1917;1:361-366.
3. Tubbs RS, Demerdash A, Rizk E, Chapman JR, Oskouian RJ. Complications of transoral and transnasal odontoidectomy: a comprehensive review. *Childs Nerv Syst*. 2016;32:55-59.
4. Türe U, Pamir MN. Extreme lateral—transatlas approach for resection of the dens of the axis. *J Neurosurg Spine*. 2002;96(1):73-82.
5. Erdogan K, Solmaz S, Abbasoglu B, Caglar YS, Dogan I. Posterior midline approach to odontoidectomy: A novel method to treat basilar invagination. *J Craniovertebral Junction Spine*. 2022;13(2):146.

OP-II/90

Microneurosurgical Treatment of a Small Perimesencephalic Pure Pial Arterial Malformation: An Under-Recognized Etiology of Angiographically-Occult Subarachnoid Hemorrhage

Robert C. Sterner[1], Garret P. Greeneway[1], Ufuk Erginoglu[1], Jaime L. Martínez Santos[1], Mustafa K. Baskaya[1]

[1]University of Wisconsin-Madison

Objectives: To present a unique case of a deceitfully dynamic pial arterial malformation that caused episodes of hemorrhage, complete thrombosis, recanalization, and re-hemorrhage.

Background: Pial arterial malformations (PAM) are rare vascular lesions consisting of dilated tortuous arteries without venous drainage. Current PAM understanding is limited by their rarity, limited anatomopathological studies, and frequent misclassifications.

Method: Case report and systematic review of reported cases of pial arterial malformations including an operative video, intraoperative photographs, and diagnostic and follow-up magnetic resonance imaging and cerebral angiograms.

Results: A 23-year-old male experienced two spontaneous subarachnoid hemorrhages (SAH) over six-months with initially unremarkable diagnostic cerebral angiograms. Magnetic resonance imaging (MRI) and angiography following the second SAH revealed a small perimesencephalic ovoid lesion within the left crural cistern, between the left superior and posterior cerebral arteries, appearing to be an exophytic cavernoma, a thrombosed aneurysm, or a hemorrhagic tumor. Microsurgical resection was achieved with a pterional craniotomy and anterior clinoidectomy. The resected lesion was characteristic of a pure pial arterial malformation arising from superior cerebellar arterial branches.

Conclusions: Small pure pial arterial malformations can be deceitfully dynamic lesions causing episodes of hemorrhage, complete thrombosis (angiographically occult), recanalization, and re-hemorrhage. Small thrombosed vascular malformations or aneurysms should be included in differential diagnoses of angiographically occult SAH. MRI can be diagnostic, but the true angioarchitecture can only be elucidated with microneurosurgery. The only definitive cure is removal. The microneurosurgical strategy should account for worst-case scenarios, provide adequate skull base exposures, and include bypass revascularization options when thrombosed aneurysms are encountered.

Keywords: Pure arterial malformation, PAM, Pure pial PAM, Superior cerebellar artery

OP-III/91

Photogrammetry for Reconstruction of High-Quality 3D Models to Aid Residents Education and Intraoperative Surgical Field Documentation and Measuring

Daniel Ballesteros Herrera[1], José Alfonso Alvarez Castro[1]

[1]National Institute of Neurology and Neurosurgery "Manuel Velasco Suarez"

Objectives: Assess residents ability to apply photogrammetric techniques to real-world scenarios in residents' education and intraoperative surgical field documentation and measuring.

Background: Photogrammetry is a powerful tool for creating high-quality 3D models that can be used in medical education and intraoperative surgical field documentation and measuring. In the last years the advancements have been develop in medical fields. The accuracy and resolution of photogrammetry models can vary depending on the quality of the photographs, the number of images taken, and the processing software used. Unfortunately, the infrastructure needed for it is expensive and needs the aid of professionals involved in photography, and 3D modeling.

Method: Materials used were a cellphone with LiDAR technology and the software 3DScanner for image acquisition, and iMac with M1 processor, 8GB RAM memory for 3D processing. The most important step is image acquisition, performed with good illumination and at least 60-100 pictures taken in an ordered fashion. Posterior 3DScanner software is opened and image processing option is clicked. After some minutes depending on the complexity of the model, the model will appear, and some post processing could be performed in Sketchfab a program made to display 3D objects that is free and accessible.

Photogrammetry of the Skull



Using the photogrammetry tecnique a 3-D model of the skull was built.

Results: 56 models have been produced during the development of this technique. 31 intraoperatively (55%) and the rest inside the laboratory (45%) with several specimens. All models have VR and AR capabilities. Measurements were made in several models to compare with the real models with high precision. 25 students were challenged using the model with better understanding of 3D conception.

Conclusions: Overall, photogrammetry is a valuable technique that can enhance medical education and improve patient outcomes. By providing detailed 3D models that can be used for education and surgical planning, photogrammetry can help to improve the skills and knowledge of medical professionals, ultimately leading to better outcomes.

Keywords: Education, Neurosurgery, 3-D models. Photogrammetry, Reconstruction.

OP-II/93

Anterior Cerebral Artery: Anatomical Variations, Associated Vascular Lesions, and Their Neurosurgical Implications.

Juan Cruz Rodriguez Ferrero[1], Joaquín Ignacio Marini[1], Osvaldo San Martin García[1], Mateus Reghin[1], Vanessa Milanese[1]

[1]Beneficência Portuguesa Hospital

Objectives: To investigate anatomical variations of the anterior cerebral artery (ACA) and their relationships with predisposition to aneurysm formation in the anterior circulation. To highlight the importance of understanding these anatomical variations for precise and safe surgical management of vascular lesions in the anterior circulation.

Background: Since the ACA is a crucial vascular structure in the anterior circulation of the brain, it is essential to understand how these variations can affect the predisposition to aneurysm formation and, therefore, adapt surgical techniques on an individualized basis. The aim of this study is to understand the anatomical variations of the ACA and their implication in aneurysmal pathology.

Method: Microsurgical dissections of anatomical specimens were perfomed and a thorough review of specialized scientific literature to examine the anatomical variations of the ACA. The dissected anatomical specimens were compared to the findings of the reviewed scientific literature to identify common patterns and individual variations.

Anterior cerebral artery



A rare variation is observed where the left ACA is unpaired, and a single one branches out to supply both hemispheres.

Anterior cerebral artery (2)

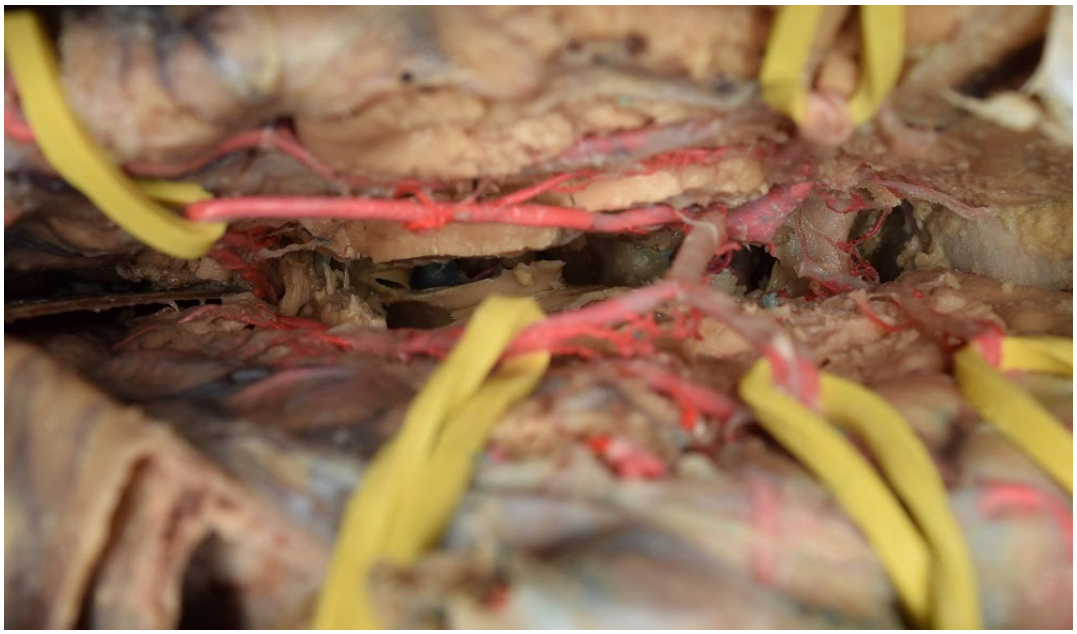

Anterior cerebral artery(3)



Results: The anatomical variations of the anterior cerebral artery (ACA) showed a significant relationship with the predisposition to the formation of aneurysms in the anterior circulation. It was observed that hypoplasia of the A1 segment of the ACA is associated with a higher risk of aneurysm development. These findings have important clinical and neurosurgical implications for the appropriate management of vascular lesions in the anterior circulation.

Conclusions: This study highlights the relevance of understanding the anatomical variations of the ACA and their relationship with predisposition to aneurysmal pathology. Precise knowledge of these variations is fundamental for performing precise and safe neurosurgical practice, adapting surgical techniques to the individual anatomical characteristics of each patient, thereby allowing a reduction in associated risks and more precise surgical planning.

Keywords: anterior cerebral artery, anatomical variations, aneurysmal pathology, surgical management

References

1. Zamora-Chavarría, A., Herrera-Guerra, C., Quesada Navarro, F., & Ballesteros Herrera, D. (2023). Variantes anatómicas del segmento anterior del polígono de Willis: relación con aneurismas cerebrales [Anatomical variants of the anterior segment of the circle of Willis: association with cerebral aneurysms]. Revista Médica Sinergia, 8(6), e1063. https://doi.org/10.31434/rms.v8i6.1063
2. Jiménez-Sosa, M. S., Cantu-González, J. R., Morales-Avalos, R., de la Garza-Castro, O., Quiroga-Garza, A., Pinales-Razo, R., Elizondo-Riojas, G., Elizondo-Omaña, R. E., & Guzmán-López, S. (2017). Anatomical Variants of Anterior Cerebral Arterial Circle: A Study by Multidetector Computerized 3D Tomographic Angiography. International Journal of Morphology, 35(3), 1121-1128. https://doi.org/10.4067/S0717-95022017000300049
3. Chiarullo, M. D., Gatto, L. A., Baccanelli, M., & Yampolsky, C. (2019). Clipado de aneurismas de la arteria cerebral anterior distal: revisión anatómica y presentación de casos [Clipping of distal anterior cerebral artery aneurysms: anatomical review and case presentation]. Revista Argentina de Neurocirugía. Recuperado el 14 de junio de 2023 de https://aanc.org.ar/ranc/items/show/220
4. Pacheco Mayedo, M., Estrella Durán Matos, M., Cuba Yordi, O. L., Serrano González, L., Rosales Almeida, Y., & Loret de Mola Nicolau, J. (2017). Patrón común y variantes anatómicas de la porción anterior del círculo arterial del cerebro. Revista Archivo Médico de Camagüey, 21(6).
5. Guillemí-Álvarez, N. M., Alberti-Vázquez, L., & Bacallao-Cabrera, I. S. (2020). Características anatómicas del origen de las arterias cerebelares. Archivo Médico de Camagüey, 24, a6700.
6. Colodette, A. L., Castheloge Coutinho, B. P. N., da Silva, F. S. R., Pratti, L. M., Zottele, M. Z., Costa Junior, O. S., Rocha, V. V., & de Batista, P. R. (2022). Variações anatômicas do círculo arterial do cérebro e suas implicações fisiológicas e clínicas: uma revisão integrativa da literatura. In VARIAÇÕES ANATÔMICAS (Vol. 1). Editora Científica Digital.
7. Quijano Blanco, Y., & García Orjuela, D. (2020). Variantes anatómicas del círculo arterial cerebral en un anfiteatro universitario en Bogotá (Colombia). Revista Ciencias de la Salud, 18(3), 1-12. https://doi.org/10.12804/revistas.urosario.edu.co/revsalud/a.9688
8. Rhoton Jr., A. L. (2021). Anatomía craneal y abordajes quirúrgicos. Amolca.
9. García, J. (2014). Polígono de Willis: anatomía y variantes. Revista Virtual Sociedad Iberoamericana de Información Científica (SIC), 11(1), 1-10.
10. Martín García, M. (2016). Anatomía del polígono de Willis [Trabajo de fin de grado, Universidad de Valladolid]. https://uvadoc.uva.es/bitstream/handle/10324/19131/TFG-M-M630.pdf?sequence=1&isAllowed=y

OP-II/94

Evaluation of Access to the Pontomedullar Area With Modifications of the Combined Supratentorial And Infratentorial Presigmoid Approach

Ayberk KARAMAN[1], Zeynep DAĞLAR[1], Tufan Agah KARTUM[2], Ahmet Deniz BELEN[1], Necmettin TANRIÖVER[2]

[1]Department of Neurosurgery, Ankara City Hospital, Ankara, Türkiye
[2]Cerrahpaşa Faculty of Medicine, Department of Neurosurgery, Istanbul University-Cerrahpaşa, Istanbul, Turkey.

Objectives: Our aim was to reveal the three-dimensional microsurgical anatomy of the Combined supra-infratentorial presigmoid approach(CSITPA) in relation to its different modifications and to compare the surgical corridors and the petroclival areas of access.

Background: The alternatives for a single surgical approach that provide access to all parts of the petroclival region are very few. CSITPA – with its modifications – is the first line surgical treatment modality for this purpose.

Method: This study was carried in colored silicone injected cadaver heads. Surgical corridors for surgical approaches and structures encountered during different stages of surgery were determined step by step and documented in three dimensions.

Results: Access to the upper petroclival region was achieved without any resection of the semicircular canals (SCC) during the RL modification. With the addition of one or two SCC resections during the PL modification, the operative field increased moderately. Resection of the posterior SCC increased the angle of view towards cerebellopontine and cerebellomedullary cisterns, and superior SCC resection enhanced the angle of operative view to the petrous apex in the middle fossa. In the TL modification provided direct access to the internal acoustic meatus (IAM). The resection of the cochlea and transposition of the facial nerve during the TK modification ensured the maximum angle of view to the entire petroclival region, specifically the prepontine and premedullary cisterns.

Photo 1

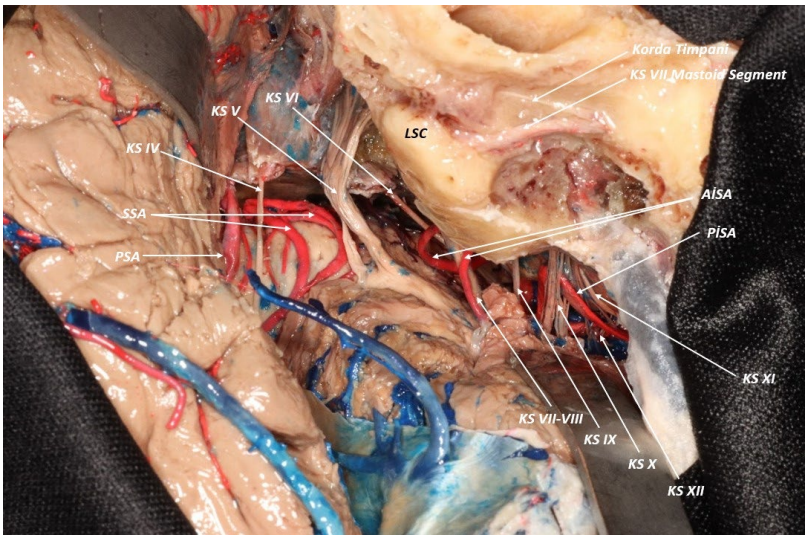

Surgical field of view with partial labyrinthectomy after resection of SSC and PSC.

Photo 2

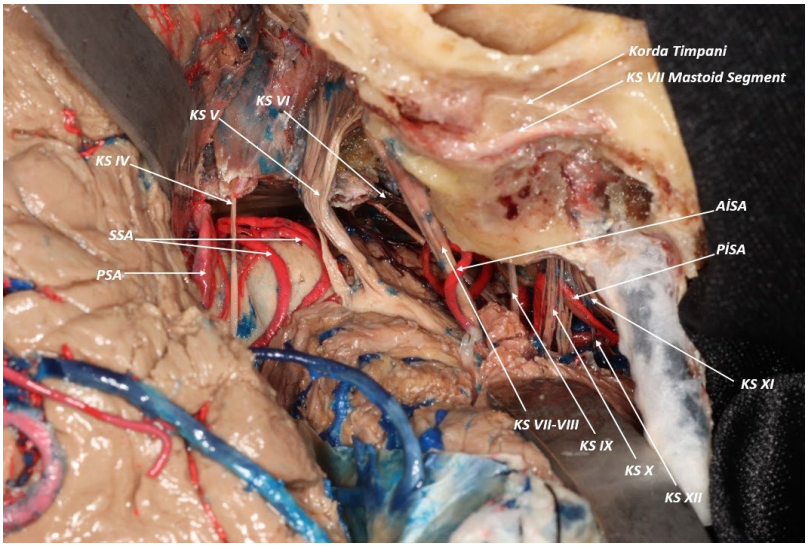

Translabyrinthine approach is seen in which LSC and vestibule are removed in addition to Partial Labyrinthectomy.

Photo 3

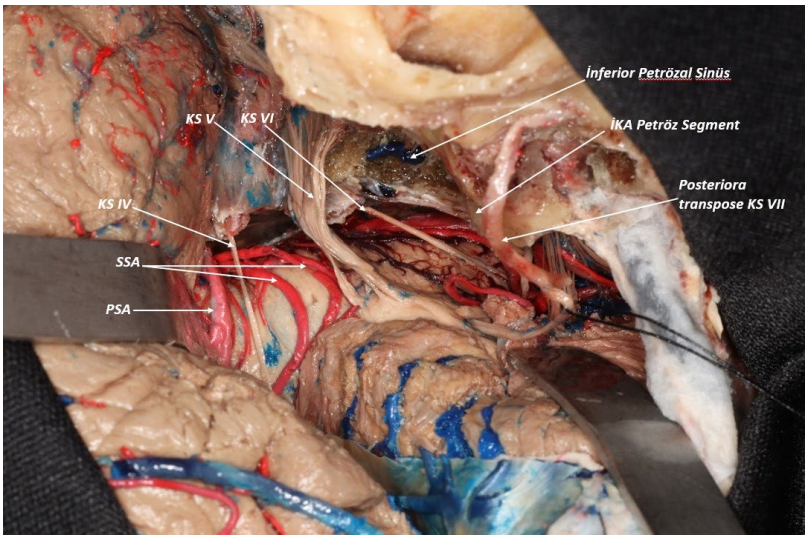

The final modification of the CSITP approach is seen, in which the cochlea is removed and transposed to the posterior KS VII.

Conclusions: The RL provides access to a significantly restricted area compared to other modifications and PL is the approach that can provide the most benefit on the accessed operative field with the least morbidity. TL provides direct angle of attack to the IAM, as expected. Considering the origin, location, and size of the petroclival pathology and the morbidity on the patient, different combinations of the CSITP may be planned and even combined with additional skull base approaches.

Table 1

Retrolabyrinthine	**Partial Labyrinthine**	**Translabyrinthine**	**Trans Cochlear/Facial nerve transposition**
KS III-IV	KS III-IV	KS III-IV	KS III-IV
KS V (cisternal + Meckel Cave Segments)	KS V (cisternal + Meckel Cave Segments)	KS V (cisternal + Meckel Cave Segments)	KS V (cisternal + Meckel Cave Segments)
KS VI (Cisternal Segment)	KS VI (Cisternal + Petroclival Segment)	KS VI (Cisternal + Petroclival Segment)	KS VI (Cisternal + Petroclival Segment)
	Dorello's canal	Dorello's canal	Dorello's canal
KS VII (Cisternal Part)	KS VII (Cisternal Part)	KS VII (Cisternal + Meatal + Labyrinthine + Tympanic Parts)	KS VII (Cisternal + Meatal + Labyrinthine + Tympanic Parts)
KS VIII (Cisternal Part)	KS VIII (Cisternal Part)	KS VIII (Cisternal Part + All part in İAM)	KS VIII (Cisternal Part + All part in İAM)
KS IX-X-XI	KS IX-X-XI	KS IX-X-XI	KS IX-X-XI
PCA	PCA	PCA	PCA

PCOM	PCOM	PCOM	PCOM
SCA	SCA	SCA	SCA
AİCA (lateral pontine, flocculonodular parts)	AİCA (anterior pontine, lateral pontine, flocculonodular parts)	AİCA (anterior pontine, lateral pontine, flocculonodular parts)	AİCA (anterior pontine, lateral pontine, flocculonodular parts)
PİCA (lateral medullary segment)	PİCA (lateral medullary segment)	PİCA (lateral medullary segment)	PİCA (lateral medullary segment)
			İCA Petrous Segment
			Vertebrobasilar Junction
			İnferior Petrosal Sinus
Cavernous sinus posterior	Cavernous sinus posterior	Cavernous sinus posterior	Cavernous sinus posterior
Superior Petrosal Vein	Superior Petrosal Vein	Superior Petrosal Vein	Superior Petrosal Vein
	Basilar artery	Basilar artery	Basilar artery
Flocculus	Flocculus	Flocculus	Flocculus
Foramen Lusckha	Foramen Lusckha	Foramen Lusckha	Foramen Lusckha
Cerebral pedicle	Cerebral pedicle	Cerebral pedicle	Cerebral pedicle
Lateral part of the pontomesencephalic junction	Lateral part of the pontomesencephalic junction	Lateral part of the pontomesencephalic junction	Lateral part of the pontomesencephalic junction
Cerebellomesencephalic fissur	Pons anterior 2/3 upper part	Pons anterior 2/3 upper part	Pons anterior and lateral surface
	Cerebellopontine Fissur Sup + İnf Limb	Cerebellopontine Fissur Sup + İnf Limb	Cerebellopontine Fissur Sup + İnf Limb
			Pontomedullary Fissur
Tentorial and petrous surface of the cerebellum	Tentorial and petrous surface of the cerebellum	Tentorial and petrous surface of the cerebellum	Tentorial and petrous surface of the cerebellum

Table of comparison of structures within the reach of RL, PL, TL and TC/Facial nerve transposition.

Keywords: cerebellopontine angle, brainstem, microsurgical anatomy, petroclival

References

1. Rhoton AL. The Temporal Bone and Transtemporal Approaches. *Neurosurgery*. 2000;47(suppl_3):S211-S265. doi:10.1097/00006123-200009001-00023.
2. Tedeschi H, Rhoton AL. Lateral approaches to the petroclival region. *Surg Neurol*. 1994;41(3):180-216. doi:10.1016/0090-3019(94)90123-6.
3. Rhoton AL. The Cerebellopontine Angle and Posterior Fossa Cranial Nerves by the Retrosigmoid Approach. *Neurosurgery*. 2000;47(suppl_3):S93-S129. doi:10.1097/00006123-200009001-00013.
4. Tanriover N, Sanus GZ, Ulu MO, et al. Middle fossa approach: microsurgical anatomy and surgical technique from the neurosurgical perspective. *Surg Neurol*. 2009;71(5):586-596. doi:10.1016/j.surneu.2008.04.009.
5. Tanriover N, Abe H, Rhoton AL, Kawashima M, Sanus GZ, Akar Z. Microsurgical anatomy of the superior petrosal venous complex: new classifications and implications for subtemporal transtentorial and retrosigmoid suprameatal approaches. *J Neurosurg*. 2007;106(6):1041-1050. doi:10.3171/jns.2007.106.6.1041.
6. McElveen JT, Wilkins RH, Molter DW, Erwin AC, Wolford RD. Hearing Preservation Using the Modified Translabyrinthine Approach. *Otolaryngol Neck Surg*. 1993;108(6):671-679. doi:10.1177/019459989310800608.
7. Horgan MA, Delashaw JB, Schwartz MS, Kellogg JX, Spektor S, McMenomey SO. Transcrusal approach to the petroclival region with hearing preservation: Technical note and illustrative cases. *J Neurosurg*. 2001;94(4):660-666. doi:10.3171/jns.2001.94.4.0660.
8. Kaylie DM, Horgan MA, Delashaw JB, McMenomey SO. Hearing Preservation With the Transcrusal Approach to the Petroclival Region: *Otol Neurotol*. 2004;25(4):594-598. doi:10.1097/00129492-200407000-00029.

OP- V/95

The Supracerebellar Transtentorial Approach in the Prone Position

murat kocaoğlu[1]

[1]hatay training and research hospital

Objectives: The mediobasal temporal region (MTR) is a deep part of the brain covered by eloquent structures. In certain cases, accessing this region is challenging. According to the literature, the supracerebellar transtentorial (SCTT) approach provides safe access to the MTR. Since this approach was introduced by Voigt and Yasargil, many researchers used SCTT in different positions.

Background: The SCTT approach can be conducted in sitting, semisitting, park bench, or prone position. However, sitting/semisitting position is generally chosen due to gravity- aided cerebellar retraction. All these positions have some benefits and/or drawbacks.In particular, the sitting position was the most preferred as it allows the cerebellum to fall away from the tentorium. However, this position has disadvantages such as venous air embolism (VAE), paradoxical air embolism (PAE), and some non ergonomic conditions during surgery.

fig1

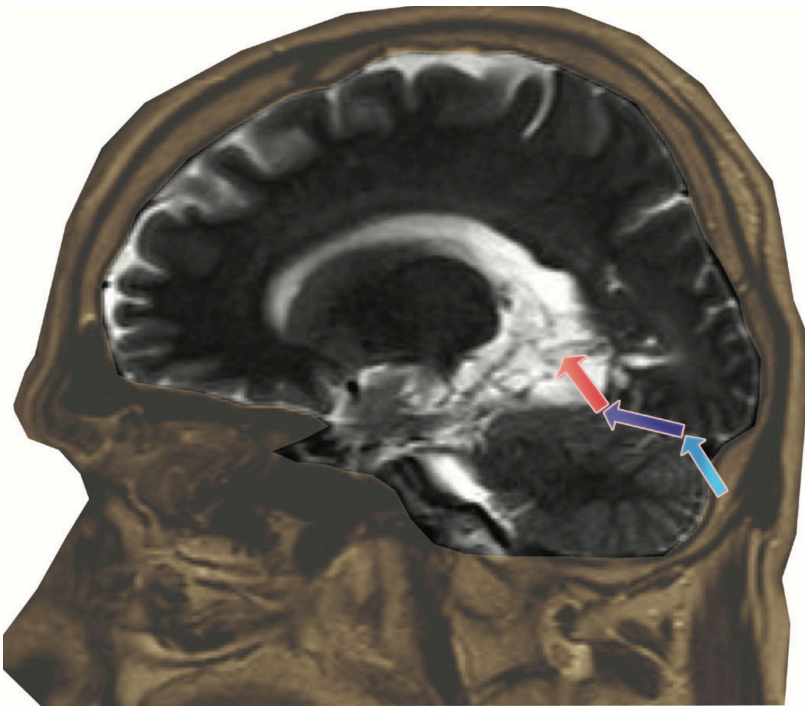

The supracerebellar transtentorial approach for accessing the mediobasal temporal region.

Method: We report two cases with tumors affecting the middle and posterior medial temporal regions. Both patients underwent surgeries in the prone position using the SCTT approach. There were no procedure-related complications. Histopathological results were as follows: psammomatous meningioma in the first case; adenocarcinoma metastasis in the second case.

Results: The results of performing the SCTT approach in the prone position in two patients were reported. There were no procedure-related complications.Thus, in this study, the efficacy, feasibility, and safety of accessing the MTR using the SCTT approach in the prone position were demonstrated.

fig2

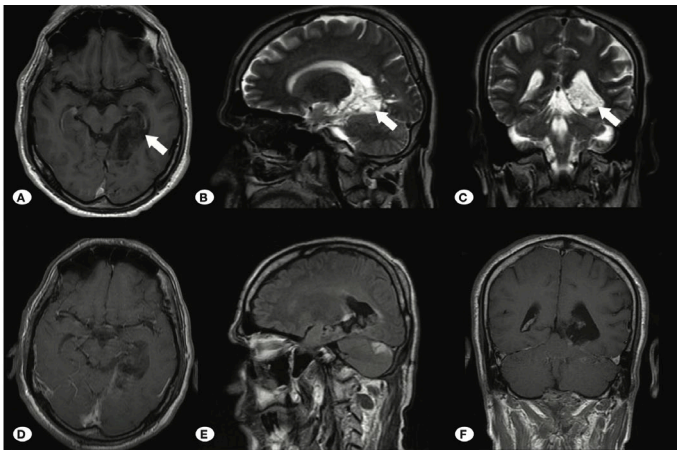

Case 1; preoperative (upper) and early postoperative (lower) images were obtained. A) T1+C axial MRI shows lesion (white arrow); B) T2w MRI shows lesion and trigone (white arrow); C) T2w MRI shows lesion and tentorium cerebelli (white arrow); D) T1+C axial MRI; E) T1+C sagittal MRI; F) T1+C coronal MRI.

fig3

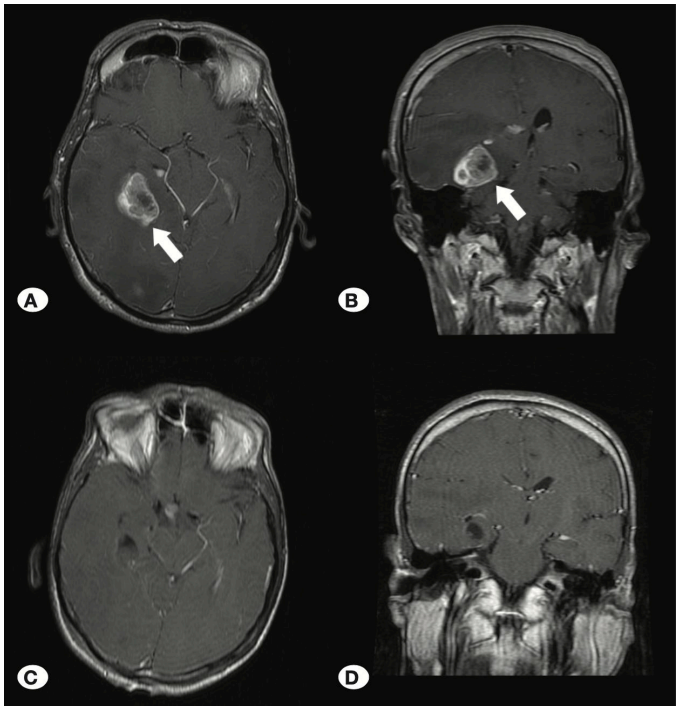

Case 2; preoperative (upper) and early postoperative (lower) images were obtained. A) T1+C axial MRI shows lesion (white arrow); B) T1+C coronal MRI shows lesion (white arrow); C) T1+C axial MRI; D) T1+C coronal MRI.

Conclusions: Therefore, it can be concluded that the SCTT approach in the prone position is safe, effective, and feasible. This technique will be more applied for larger areas of the brain's deep part with developing technologies such as neuronavigation and maybe robotic surgery in the future. Finally, more cases and long-term follow-up are warranted to endorse the advantages of the prone position for the SCTT approach, especially in the anterior part of the MTR.

Keywords: Mediobasal temporal region, Prone position, Supracerebellar transtentorial approach

References

1. Ansari SF, Young RL, Bohnstedt BN, Gadol AAC: The extend- ed supracerebellar transtentorial approach for resection of medial tentorial meningiomas. Surg Neurol Int 5:35, 2014
2. Bandt SK, Werner N, Dines J, Rashid S, Eisenmen LN, Hogan RE, Leuthardt EC, Dowling J: Trans-middle temporal gyrus selective amygdalohippocampectomy for medically intractable mesial temporal lobe epilepsy in adults: Seizure response rates, complications, and neuropsychological outcomes. Epilepsy Behav 28:17-21, 2013
3. Chang EF, Englot DJ, Vadera S: Minimally invasive surgical approaches for temporal lobe epilepsy. Epilepsy Behav 47: 24-33, 2015
4. de Oliveira JG, Párraga RG, Chaddad-Neto F, Ribas GC, de Oliveira EPL: Supracerebellar transtentorial approach- resection of the tentorium instead of an opening-to provide broad exposure of the mediobasal temporal lobe: Anatomical aspects and surgical applications. J Neurosurg 116:764-772, 2012
5. Dilmen OK, Akcil EF, Tureci E, Tunali Y, Bahar M, Tanriverdi T, Aydin S, Yentur E: Neurosurgery in the sitting position: Retrospective analysis of 692 adult and pediatric cases. Turk Neurosurg 21:634-640, 2011
6. Ganslandt O, Merkel A, Schmitt H, Tzabazis A, Buchfelder M, Eyupoğlu I, Muenster T: The sitting position in neurosurgery: Indications, complications and results. A single institution experience of 600 cases. Acta Neurochir (Wien) 155:1887- 1893, 2013
7. Goel A, Shah A: Lateral supracerebellar transtentorial approach to a middle fossa epidermoid tumor. J Clin Neurosci 17:372-373, 2010
8. Grigoryan YUA, Sitnikov AR, Timoshenkov AV, Grigoryan GYU: The paramedian supracerebellar transtentorial approach to the mediobasal temporal region. J Neurosurg 80:43-56, 2016
9. Konovalov AN, Pitskhelauri DI, Melikyan AG, Shishina LV, Serova NK, Pronin IN, Eliseeva NM, Shkatova AM, Samborskiy DYA, Bykanov AE, Golovteev AL, Grinenko OA, Kopachev DN: Supracerebellar transtentorial approach to tumors of the posterior portions of the medial temporal region. Zh Vopr Neirokhir Im N N Burdenko 79(4):38-47, 2015
10. Manilha R, Harput VM, Ture U: The paramedian supracerebellar- transtentorial approach for a tentorial incisura meningioma: 3-dimensional operative video. Oper Neurosurg 15(1):102, 2018
11. Marcus HJ, Sarkar H, Mindermann T, Reisch R: Keyhole supracerebellar transtentorial transcollateral sulcus approach to the lateral ventricle. Neurosurgery 73:295- 301, 2013

12. Moftakhar R, Izci Y, Başkaya MK: Microsurgical anatomy of the supracerebellar transtentorial approach to the posterior mediobasal temporal region. Oper Neurosurg 62:1-8, 2008
13. Porter JM, Pidgeon C, Cunningham AJ: The sitting position in neurosurgery: A critical appraisal. Br J Anaesth 82:117-128, 1999
14. Smith KA, Spetzler RF: Supratentorial-infraoccipital approach for posteromedial temporal lobe lesions. J Neurosurg 82:940- 944, 1995
15. Ture U, Harput MV, Kaya AH, Baimedi P, Firat Z, Ture H, Bingol CA: The paramedian supracerebellar- transtentorial approach to the entire length of the mediobasal temporal region: An anatomical and clinical study. J Neurosurg 116:773-791, 2012
16. Uchiyama N, Hasegawa M, Kita D, Yamashita J: Paramedian supracerebellar transtentorial approach for a medial tentorial meningioma with supratentorial extension: Technical case report. Neurosurgery 49:1470- 1474, 2001
17. Voigt K, Yasargil MG: Cerebral cavernous haemangiomas or cavernomas. Incidence, pathology, localization, diagnosis, clinical features and treatment. Review of the literature and report of an unusual case. Neurochirurgia (Stuttg) 19:59-68, 1976
18. Watanabe T, Katayama Y, Fukushima T, Kawamata T: Lateral supracerebellar transtentorial approach for petroclival meningiomas: Operative technique and outcome. J Neurosurg 115:49-54, 2011
19. Weil AG, Middleton AL, Niazi TN, Ragheb J, Bhatia S:
The supracerebellar-transtentorial approach to posteromedial temporal lsions in children with refractory epilepsy. J Neurosurg Pediatr 15:45-54, 2015
20. Yonekawa Y, Imhof HG, Taub E, Curcic M, Kaku Y, Roth P, Wieser HG, Groscurth P: Supracerebellar transtentorial approach to posterior temporomedial structures. J Neurosurg 94:339-345, 2001

OP-I/96

Cingulate sulcus morphology and paracingulate sulcus variations: Anatomical and radiological studies

Ozge Selahi[1], Pınar Kuru Bektasoglu[2], Tayfun Hakan[1], Zeynep Firat[3], Abuzer Gungor[4], Erhan Celikoglu[1]

[1]Department of Neurosurgery, University of Health Sciences, Fatih Sultan Mehmet Research and Training Hospital, Istanbul, Turkey
[2]Department of Neurosurgery, Sivas Numune Hospital, Sivas, Turkey
[3]Department of Radiology, Yeditepe University School of Medicine, Istanbul, Turkey
[4]Department of Neurosurgery, University of Health Sciences, Bakirkoy Research and Training Hospital for Psychiatry, Neurology and Neurosurgery, Istanbul, Turkey

Objectives: This study aims to demonstrate the anatomical variations of the paracingulate sulcus in cadaver and healthy human brains and the difference between the left and right hemisphere asymmetry and sex differences.

Background: The cingulate sulcus is an important landmark for deciding the surgical approach for neighboring pathological lesions. Identifying the anatomical variations of anterior cingulate cortex morphology would help to determine the safe-entry route through neighboring lesions.

Method: In this study, magnetic resonance imaging data acquired from 149 healthy volunteers were investigated retrospectively for anatomical variations of the paracingulate sulcus. Also, human cadaveric brain hemispheres were investigated for cingulate and paracingulate sulcus anatomy.

Results: Three types of paracingulate sulcus patterns were identified: "prominent," "present," and "absent." Hemispheric comparisons indicated that the paracingulate sulcus is commonly "prominent" in the left hemisphere (n = 48, 32.21%) and more commonly "absent" in the right hemisphere (n = 73, 48.99%). Ten (6.71%) people had a prominent paracingulate sulcus in both the right and left hemispheres. Seven (4.70%) of them were male, and 3 (2.01%) of them were female. Paracingulate sulci were present in both hemispheres in 19 people (12.75%), of which 9 (6.04%) were male and 10 (6.71%) were female. There were 35 (23.49%) participants without paracingulate sulci in both hemispheres. Eleven (7.38%) were male and 24 (16.11%) were female. There were 73 (48.99%) participants without right paracingulate sulcus and 57 (38.26%) participants without left paracingulate sulcus (p = 0.019). It has been observed that the paracingulate sulcus is more prominent in the normal male brain compared to females.

Conclusions: This study shows that there are both hemispheric and sex differences in the anatomy of the paracingulate sulcus. Understanding the cingulate sulcus anatomy and considering the variations in the anterior cingulate cortex morphology during surgery will help surgeons to orient this elegant and complex area.

Keywords: anterior cingulate cortex, Brodmann's area 32, gyrus cinguli, cingulate sulcus

References

1. Paus, T., Tomaiuolo, F., Otaky, N., MacDonald, D., Petrides, M., Atlas, J., Morris, R., & Evans, A. C. (1996). Human cingulate and paracingulate sulci: Pattern, variability, asymmetry, and probabilistic map. Cerebral Cortex, 6(2), 207–214.
2. Vogt, B. A., Nimchinsky, E. A., Vogt, L. J., & Hof, P. R. (1995). Human cingulate cortex: Surface features, flat maps, and cytoarchitecture. The Journal of Comparative Neurology, 359(3), 490–506.
3. Yücel, M., Stuart, G. W., Maruff, P., Velakoulis, D., Crowe, S. F., Savage, G., & Pantelis, C. (2001). Hemispheric and gender-related differences in the gross morphology of the anterior cingulate/paracingulate cortex in normal volunteers: An MRI morphometric study. Cerebral Cortex, 11(1), 17–25.

OP-I/97

Management of a Challenging Dural-Embedded Anterior Inferior Cerebellar Artery Loop During a Retrosigmoid Hearing Preservation Vestibular Schwannoma Resection: Microsurgical Technique and Operative Video

Robert C. Sterner[1], Jaime L. Martínez Santos[1], Mustafa K. Baskaya[1]

[1]University of Wisconsin-Madison

Objectives: To present the management and microsurgical technique of a unique case of a dural-embedded and osseous-penetrating AICA loop encountered during a hearing-preserving retrosigmoid approach.

Background: Anatomic variants of the anterior inferior cerebellar artery (AICA) such as an anomalous "AICA loop" embedded in the dura and bone of the subarcuate fossa increase the complexity and risk of vestibular schwannoma (VS) resections. Classically, osseous penetrating AICA loops are the most challenging to mobilize as the dura must be dissected and the surrounding petrous bone must be drilled to mobilize the AICA away from the surgical corridor and out of harm.

Method: Case report and review of the literature including an operative video, intraoperative photographs and both preoperative and postoperative audiograms and magnetic resonance imaging.

Results: This report and operative video depict the microsurgical mobilization of an AICA loop embedded in the dura and bone during a retrosigmoid hearing-preserving VS resection not requiring drilling of the surrounding petrous bone. Although mostly recognized intraoperatively, thin-sliced petrous bone CTs and high-quality MRIs could aid in the preoperative recognition of these potentially dangerous AICA loops.

Conclusions: We demonstrate the safe and efficient microdissection and mobilization of a rare dural-embdedded and osseous-penetrating AICA loop without having to drill the surrounding bone. A retrosigmoid approach is superior for its early intradural recognition, and proximal vascular control, and offers more versatility for mobilizing AICA loops and developing microsurgical corridors to cisternal and intracanalicular tumors by simply drilling the IAC intradurally.

Keywords: anatomy, anterior inferior cerebellar artery, subarcuate fossa, vestibular schwannoma

OP-III/98

The role of extracranial-intracranial microvascular anastomosis surgery in patients with the acute occlusive intracranial vascular disease following an unsuccessful endovascular approach

Chingiz Nurimanov[1], Özde Şenol[1], Yerbol Makhambetov[1]

[1]National Centre for Neurosurgery

Objectives: This retrospective study aimed to evaluate the treatment outcomes of patients with acute occlusive intracranial vascular disease who underwent microvascular anastomosis surgery after unsuccessful attempts at endovascular revascularization interventions.

Background: Ischemic stroke is a significant societal burden, and although intra-arterial thrombolysis and mechanical thrombectomy are effective treatments, they are not always successful, with failure rates of 10-30% [1, 2]. The use of microsurgical interventions for cerebrovascular pathology has decreased, including revascularization operations for steno-occlusive diseases that have gained widespread use after the COSS1 and COSS2 studies [3]. However, emergency bypass vascular anastomoses between extra-intracranial vessels remain a viable option for patients when endovascular treatments are not possible. The first reported use of these operations was by G. Yasargil in 1968 [4].

Method: The study involved 9 patients (age range: 34-61 years, average age: 44.2 years) with acute occlusion of intracranial vessels. Microsurgical revascularization was performed within 6 hours from the start of symptoms, and within 2-6 hours in the occluded territory. Clinical signs included: hemiparesis, dysarthria, hemihypesthesia. The STA-MCA end-to-side bypass technique was used in all 9 patients for microsurgical revascularization. Intraoperatively, the patency of the anastomosis was confirmed by ultrasound duplex scanning.

Results: All 9 patients demonstrated functional anastomosis on control angiography. 7 patients (78%) exhibited complete regression of initial neurological symptoms and a mRS of 1 at discharge. The remaining 2 patients (22%) had minor neurological deficits, corresponding to a mRS of 2 at discharge. No complications related to the operation were observed during or after the procedure.

illustrative case # 1.

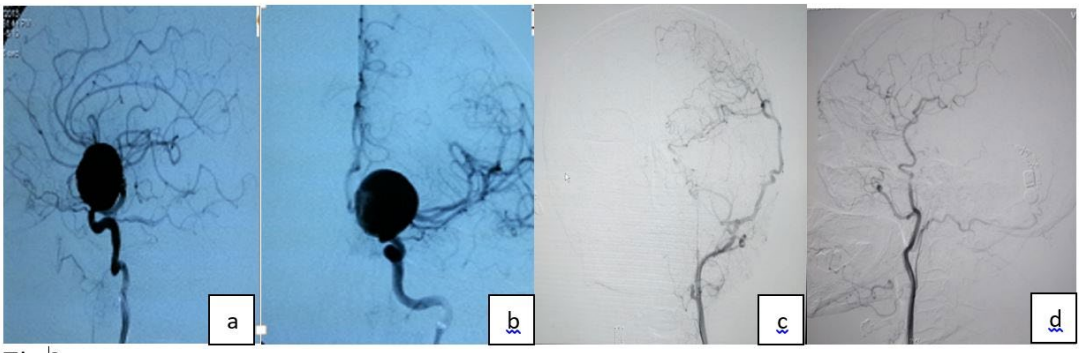

Fig 2.

A 51-year-old woman with a diagnosis of pituitary adenoma (see Figure 1a) underwent a transnasal endoscopic removal of the adenoma. On the 5th day after the operation, the patient developed symptoms of left-sided hemiparesis. Angiography showed occlusion of the right ICA, and after unsuccessful attempts at endovascular revascularization methods (see Figures 1b, c), an STA-MCA bypass surgery was performed 4.5 hours after the index event (see Figure 1d). Follow-up angiography on the 2nd day (see Figures 1e, f) was performed. Complete regression of neurological symptoms. Discharged on the 8th day with a Rankin score of 1.

Illustrative case # 2

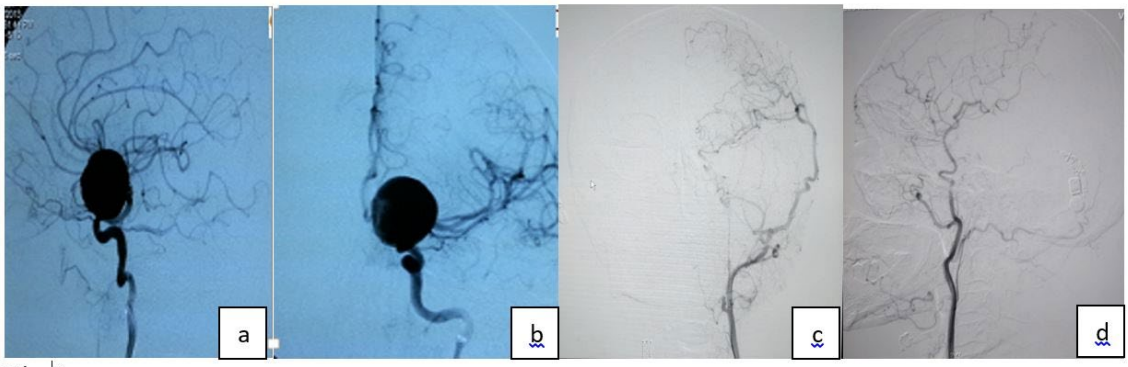

Fig 2.

Patient, 46 years old, female with a diagnosis of giant aneurysm of the left internal carotid artery. (see Fig. 2, a, b). A flow-diverting stent was installed. On the second day after the operation, the patient developed hemiparesis and aphasia. Control angiography revealed stent thrombosis, and after unsuccessful attempts at endovascular revascularization, a bypass STA-MCA was performed, followed by control angiography (see Fig. 2, c, d). Neurological symptoms regressed. Discharged on the 6th day with a Rankin score of 1.

Illustrative case # 3.

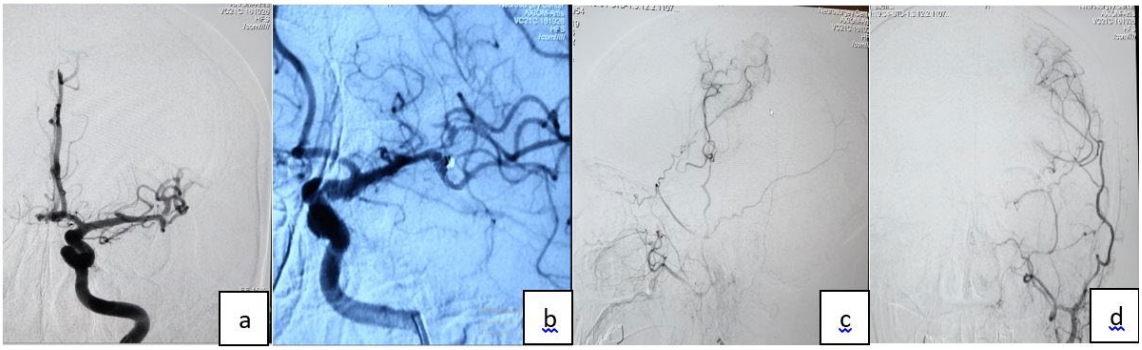

Fig 3.

Patient, 37 years old, female with a diagnosis of an aneurysm of the left middle cerebral artery. (see Fig. 3, a, b), Embolization of the aneurysm with microcoils with stent assistance was performed. Three hours after the operation, the patient developed hemiparesis and aphasia. Control angiography revealed occlusion of the superior branch of the MCA, and after unsuccessful attempts at endovascular revascularization, a bypass STA-MCA was performed, followed by control angiography on the second day (see Fig. 3, c, d).

Conclusions: This study emphasizes the importance of microvascular anastomoses in the context of endovascular treatment for acute occlusion of cerebral vessels. It is essential for neurosurgeons to possess proficiency in the technique of microvascular anastomosis, which can prevent ischemic complications and improve outcomes in patients who experience thromboembolic complications during neurosurgical procedures.

Keywords: ischemic stroke, revascularization, STA-MCA anastomosis

References

1. Nogueira RG, Jadhav AP, Haussen DC, Bonafe A, Budzik RF, Bhuva P, et al. Thrombectomy 6 to 24 hours after stroke with a mismatch between deficit and infarct. N Engl J Med. 2018 Jan 4;378(1):11–21.
2. R. Bhatia, M.D. Hill, N. Shobha, B. Menon, S. Bal, P. Kochar, T. Watson, M. Goyal, A.M. Demchuk, Low rates of acute recanalization with intravenous recombinant tissue plasminogen activator in ischemic stroke: real-world experience and a call for action, Stroke 41 (10) (2010) 2254–2258.
3. Grubb RL Jr, Powers WJ, Clarke WR, Videen TO, Adams HP Jr, Derdeyn CP, Carotic Occlusion Study Investigators. Surgical results of the Carotic Occlusion Surgery Study. Journal of Neurosurgery. 2012 October 26; 118 (1) 25-3
4. Yaşargil MG. Anastomosis between the superficial temporal artery and a branch of the middle cerebral artery. In: Yaşargil MG, editor. *Microsurgery Applied to Neurosurgery.* George Thieme Verlag; Stuttgart: 1969. pp. 105–115

OP-III/99

Ipsilateral Supracerebellar-Transtentorial Approach for Parahipocampal Gyrus Ganglioglioma Resection in Park Bench Position

Evren Sandal[1], Halil Güllüoğlu[2], Ali Akay[1]

[1]Izmir Economy University, Medical Faculty, Neurosurgery
[2]Izmir Economy University, Medical Faculty, Neurology

Objectives: Park-bench position (PBP) could offer the advantages of both sitting and pron positions for posterior fossa surgery. A pediatric case with temporal lobe epilepsy due to parahippocampal gyrus ganglioglioma, who underwent selective lesion excision with SCTT in PBP, is presented. The aim of this presentation is to discuss surgical technique, indication, advantages and difficulties of SCTT in PBP, with video images.

Background: Medial temporal lobe is challenging area for surgical approaches. Supracerebellar transtentorial approach (SCTT) is an ideal method to reach directly. Surgical position options for SCTT have always been discussed over sitting, semi-sitting and pron positions. Each position option has some advantages and disadvantages.

Method: A 16-year-old patient with the diagnosis of temporal lobe epilepsy had received treatment and followed-up for 9 years. She was referred for epilepsy that became resistant to triple drup treatment and a lesion involving the parahippocampal gyrus on cranial MRI.Epileptic focus was PMTL due to EEG. Neurocognitive evaluations were normal. Selective lesion excision preserving hippocampus was decided. Ipsilateral paramedian SCTT approach in park-bench position was performed. Surgical technique and position, advantages and difficulties presented with video visuals.

MR-navigational

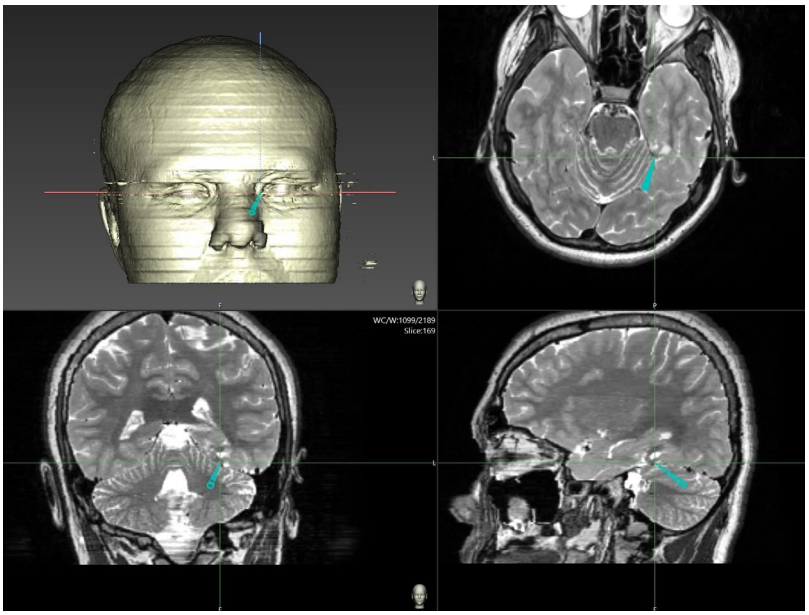

position



Results: No serebellum retraction were required. Tentorium was cut in paramedian line far away from the deep midline venous structures and PMTL was easily reached. Neuronavigation-guided selective lesion excision was performed while preserving the hippocampus. PBP was as good at providing clean surgical field as the sitting position. The target gyrus/lesion was reached through the shortest anatomical corridor.

intraoperative view

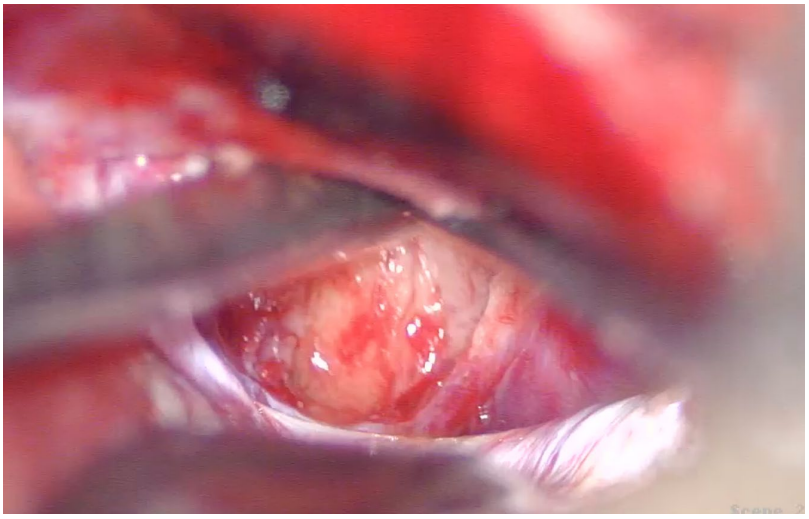

Conclusions: SCTT could be superior to other alternatives as it provides a safe and direct access to PMTL. Also, since it can provide the advantages of both sitting and pron positions, PBP could be preferred for this approach. Craniofacial landmarks of the patient are more visible than when the patient is in the pron position, and this facilitates the registration phase of neuronavigation.

Keywords: supracerebellar transtentorial, parahippocampal, medial temporal

References

1. Türe U, Harput MV, Kaya AH, Baimedi P, Firat Z, Türe H, Bingöl CA. The paramedian supracerebellar-transtentorial approach to the entire length of the mediobasal temporal region: an anatomical and clinical study. Laboratory investigation. J Neurosurg. 2012 Apr;116(4):773-91. doi: 10.3171/2011.12.JNS11791. Epub 2012 Jan 20. PMID: 22264179.
2. Moftakhar R, Izci Y, Başkaya MK. Microsurgical anatomy of the supracerebellar transtentorial approach to the posterior mediobasal temporal region: technical considerations with a case illustration. Neurosurgery. 2008 Mar;62(3 Suppl 1):1-7; discussion 7-8. doi: 10.1227/01.neu.0000317367.61899.65. PMID: 18424961.
3. Frisoli FA, Baranoski JF, Catapano JS, Lang MJ, Lawton MT. Contralateral Supracerebellar-Transtentorial Approach for Posterior Mediobasal Temporal Cavernous Malformation Resection. World Neurosurg. 2022 Feb;158:166. doi: 10.1016/j.wneu.2021.11.052. Epub 2021 Nov 24. PMID: 34826633.
4. Weil AG, Middleton AL, Niazi TN, Ragheb J, Bhatia S. The supracerebellar-transtentorial approach to posteromedial temporal lesions in children with refractory epilepsy. J Neurosurg Pediatr. 2015 Jan;15(1):45-54. doi: 10.3171/2014.10.PEDS14162. PMID: 25396700.

OP-III/101

Results of Treatment of Medulloblastoma of the Brain

Dilshod Khodjimetov[1]

[1]Republican specialized scientific practical medical center of neurosurgery, Tashkent, Uzbekistan

Objectives: identification and assessment of the validity of the morphometric definition of hydrocephalus

Background: Widespread and easy methods of grading hydrocephalus is Evans index (EI) [1]. There is consensus that an Evans index > 0.3 is indicative of hydrocephalus [2]. We suggest using mamillo-pontine distance (MPD) on grading preoperative severity of hydrocephalus.

Method: Retrospective analyze of 43 patient with triventricular non-communicating hydrocephalus (pineal region and posterior cranial fossa tumors) treated in RSSPCN Tashkent, were performed. Control group- 30 people without any brain pathology (healthy). Pre operative and postoperative MRI images were observed. We performed measurement of mammillo-pontine distance, the shortest distance between the center of the mammillary bodies and the upper surface of the pons , and Evans index in all patient for performing comparative analyze. For defining grades of hydrocephalus we also measured collosal angle , degree of periventricular edema and assess state of eye fundus, quality of life by Karnofsky performance scale

Results: We assess Sensitivity and Specificity of MPD and EI for comparative analyse . We find that MPD has high Sensitivity and Specificity while Evans index (EI) has low Sensitivity and high Specificity (Graph. 1). For classify hydrocephalus into groups of severity we compared it with several signs of HC as we mention before. We divide hydrocephalus (HC) by severity into 3 grades. We suggest our classification of hydrocephalus severity according to mamillopontine distance (MPD):I – mild: MPD from 5,1 to 8,9 mm;II –moderate: MPD from 2,1 to 5,0 mm;III –severe: MPD from 0 to 2,0 mm;

Distribution of patients

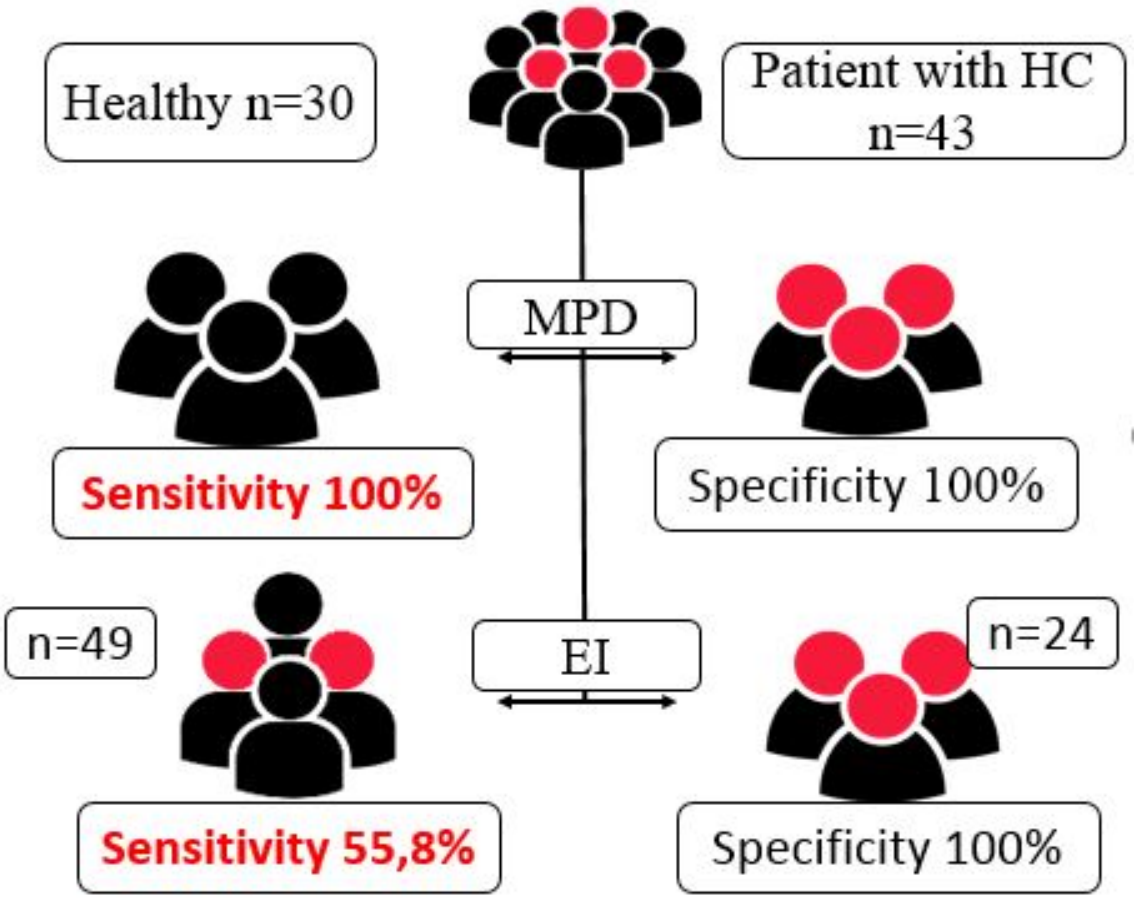

Graph. 1. Comparative analysing capability of MPD and EI on revealing non communicative HC.

Conclusions: 1. MPD one of the more accurate and powerful method for defining presence of hydrocephalus in-patient even in early stage of occlusion. It has high specificity and sensitivity. 2. MPD capable classify hydrocephalus into grades according to severity. This allows assessing severity of illness more preciously and choosing appropriate means of treatment

Keywords: mammillo-pontine distance, hydrocephalus, Evans index, pineal region and posterior cranial fossa tumors)

References

1.Gopalakrishnan C.V et al. Factors Predicting the Need for Cerebrospinal Fluid Diversion following Posterior Fossa Tumor Surgery in Children. Pediatr Neurosurg 2012;48:93–101

2.Evans WA. An encephalographic ratio for estimating ventricular enlargement and cerebral atrophy. Arch Neurol Psychiatry 1942; 47: 931–937

OP-III/103

Retrosigmoid Supracerebellar Infratentorial Approach to Mediobasal Temporal Region Anatomy: A Cadaver Study

Mehmet Hakan ŞAHİN[1], Mehmet Emin AKYÜZ[1], Muhammet ELVEREN[1], Caner Fahrettin KARA[1], Mehmet Kürşat KARADAĞ[1], Hakan Hadi KADIOĞLU[1]

[1]Atatürk University, Faculty of Medicine, Department of Neurosurgery

Objectives: 1.Determine a potential surgical corridor that can be reached with the retrosigmoid supracerebellar infratentorial approach (RSIT) to the entire mediobasal temporal region (MTR) 2.Preoperatively predict the difficulty in reaching the entire area

Background: Several methods have been described to approach the MTR, but each method has its advantages/disadvantages. We aimed to demonstrate that the RSIT approach may be a suitable surgical corridor to approach the region by anatomical study and comparison with other methods.

Method: Brain MRIs of 100 randomly selected healthy individuals were examined, and MRIs of 8 head specimens prepared according to the Klinger method were taken and navigated. Cephalic index and angle measurements were analyzed on MRIs. Surgical distance measurements were made on the specimens (Figure 1). The specimens were dissected using a RSIT approach, preserving anatomical landmarks, until the medial temporal area was reached and each stage was photographed (Figure 2).

Figure 1

MEASUREMENTS		PLANE	DESCRIPTION	IMAGE
*CEPHALIC INDEX (CI) MEASUREMENT	Cephalic length	Axial	Length between the nasion and the maximum occipital point (a)	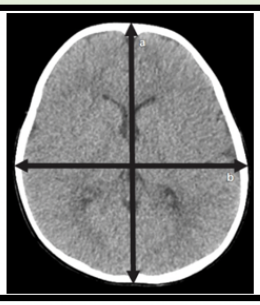
	Biparietal width	Axial	Biparietal width in the same cross-section (b)	
ANGLE MEASUREMENT	Tentorial angle (TA)	Sagittal	Tentorial angle (a) between tentorium cerebelli and the line drawn from the tuberculum sella (tus) to the internal occipital protuberance (iop) (Twining line) (a)	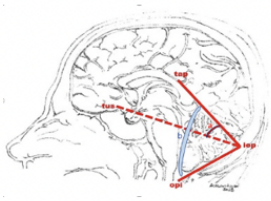
	Occipital angle (OA)	Sagittal	Occipital angle (b) between tentorium cerebelli and the line connecting iop to opistion (opi) (b)	
SURGICAL DISTANCE MEASUREMENT	**Distance from REP to IchP	Axial	Distance between the REP and the inferior choroidal point (IchP), which is the entry point of the inferior choroidal artery into the temporal horn	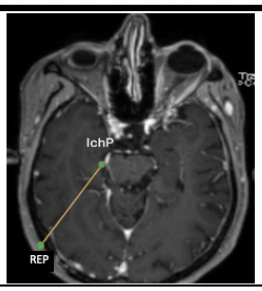
	Distance from REP to Th	Axial	Distance between REP and the most anterior visible part of the temporal horn (Th)	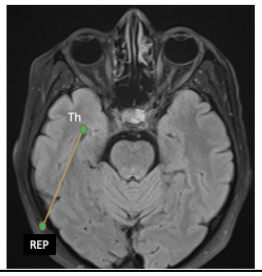
	Distance from RGN to TmP	Axial	Distance from REP to temporal pole (TmP)	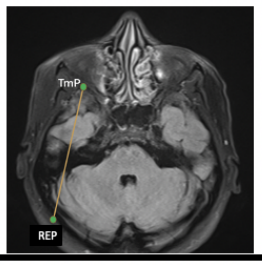

Figure 1; Measurements and Definitions in Radiological Images *Cephalic index: b/a x 100. An index ≥ 80 was considered brachycephalic, 75-80 was considered mesocephalic and ≤75 was considered dolichocephalic. **Retrosigmoid entry point (REP): the intersection of the lower edge of the transverse sinus and two cm medial to the transverse sinus sigmoid sinus junction.

Figure 2

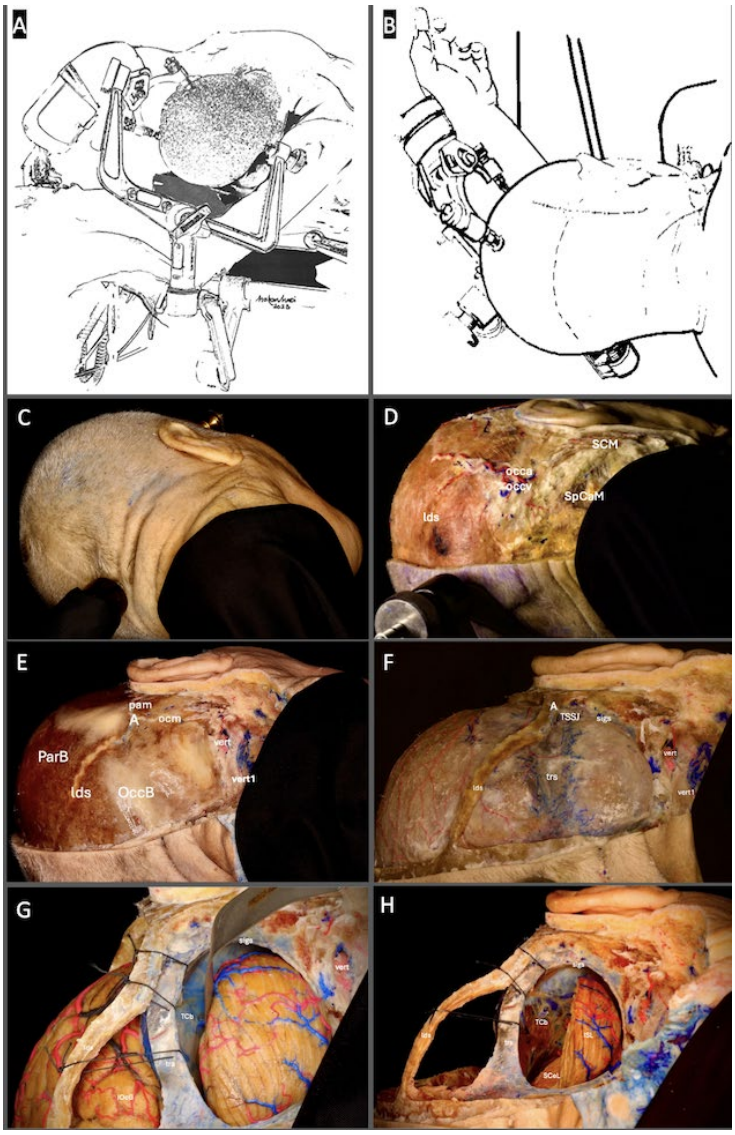

Figure 2.A, B; Fukushima position under 3-pin head fixator and REP display in this position, 2.C; Demonstration of fixation of the head specimen with a 3-pin fixator and positioning according to Fukusima, 2.D; Image after removing the scalp with the sagittal suture on the medial side and the auricle border on the lateral side, 2.E; view of the cranium after muscle and periosteum removal, 2.F; removal of the bone with preservation of the lamdoid suture and exposure of the dura, 2.G; removal of the dura with preservation of the transverse and sigmoid sinus and exposure of the cerebellum, 2.H; cutting the upper 1/3 of the cerebellum and the right hemisphere for a wider view and exposure of anatomical landmarks (A; asterion, ISL; inferior cerebellar lobule, lds; lambdoid suture, occa; occipital artery, ocm; occipito-mastoid suture, OccB; occipital bone, occv; occipital vein, SCM; sternocleidomastoid muscle, pam; parieto-mastoid suture, ParB; parietal bone, SCel; superior semilunar lobule, sigs; sigmoid sinus, SpCaM; splenius capitis muscle, Tcb; tentorium cerebelli, TSSJ; transvers sinus-sigmoid sinus junction, trs; transverse sinus, vert; vertebral artery)

Results: The measurements made in MRI imaging are shown in Table 1. There was a statistically significant correlation between angles and resection target distances (Table 2). With retrosigmoid incision, half of the cerebellum were removed, and the tentorium was incised from the posterior portion of the mediotemporal region. P2-P3 bifurcation, fusiform and lingual gyri were identified. Anterio-medial resection was performed by estimating the parahippocampal gyrus superior to P2-P3 in the neighborhood of the fusiform gyrus, and the medial border was determined by entering the ventricle. The amygdalohippocampus was resected by going anteriorly along this way. These stages were photographed.

Figure 3

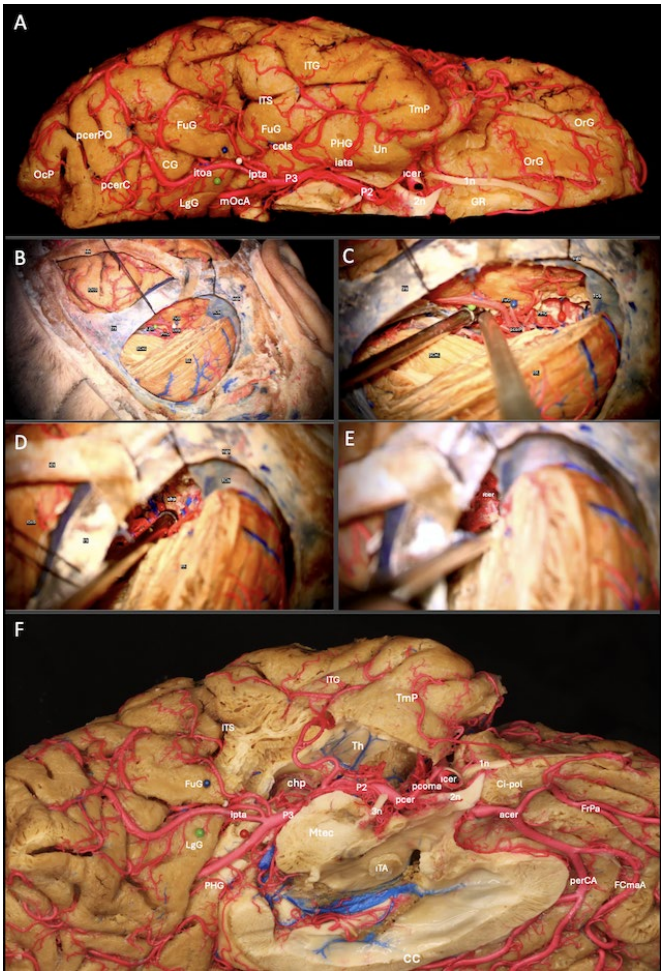

Figure 3.A; image of the inferior surface of the right hemisphere removed from the cranium to provide topographic dominance, with pins marking the cortical areas associated with the surgical approach, blue pin; fusiform gyrus, green pin; lingual gyrus, white pin; colleral sulcus, red pin; parahippocampal gyrus 3.B; The image obtained from the tentorium incision after the replacement of the hemisphere with cortical markers, 3.C; Subpial resection with the help of CUSA, starting from the PCER P3 branch point, 3.D; Resection of the hippocampus tail anteriorly, leaving the PCer P3 and P2 branches medially and the cols laterally. After approximately 2.5 cm, resected the hippocampal body and head by moving superiorly and medially until reaching Th, and visualization of chp with Th lateral wall resection. During this procedure, approximately 2 cm3 of the fusiform gyrus was resected to provide sufficient visual angle. 3.E; Resection of the amygdala and the remainder of the hippocampus head,

continuing the dissection from the Th lateral wall lateral and inferiorly until ICER and 2.n are seen. 3.F; After resection, the image of the inferior surface of the right hemisphere is removed (CC; corpus callosum, chp; choroid plexus, CG; cingulat gyrus, cols; colleteral sulcus, Ci-pol; cingulat pole, fug; fusiform gyrus, FCmaA; fronto callosomarginal artery, FrPa; frontopolar artery, GR; gyrus rectus, IOcG; inferior occipital gyrus, ITA; interthalamic adhesion, ITG; inferior temporal gyrus, ITS; inferior temporal sulcus, iata; inferior anterior temporal artery, icer; internal cerebral artery, ipta; inferior parieto-temporal artery, lgg; lingual gyrus, moca; medial occipital artery, Mtec; mesencephalic tectum, ocp; occipital pole, Org; orbital gyrus, perCA; pericallosal artery, PHG; parahippocampal gyrus, pcerc; posterior cerebral artery calcerine branche, pcerpo; posterior cerebral artery parieto-occipital branche, sigs; sigmoid sinus, TCb; tentorium cerebelli, Tmp; temporal pole, artery, trs; transvers sinus, Un, uncus, 1n; oculomotor nerve)

Table 1

MEASUREMENTS		Individuals (mean±SD)	Cadavares (mean±SD)
*CEPHALIC INDEX (CI) MEASUREMENT	Cephalic length (mm)	183,86±6,3	181,27±5,3
	Biparietal width (mm)	149,87±7,2	150,71±9,7
ANGLE MEASUREMENT	Tentorial angle (TA)	41,76±6,8	36,88±4,2
	Occipital angle (OA)	114,7±8,4	108,86±4,1
SURGICAL DISTANCE MEASUREMENT	**Distance from REP to IchP (mm)	64,67±6,08	68,93±6,8
	Distance from REP to Th (mm)	63,84±6,1	68,29±6,6
	Distance from RGN to TmP (mm)	88,22±9,6	85,21±5,8

Table 1; Results of measurements obtained from rayological images

Table 2

MEASUREMENTS	OA	REP-IchP	REP-Th	REP-TmP
TA	r 0,973 p<0,05	r 0,305 p<0,05	r 0,301 p<0,05	r 0,358 p<0,05
OA	-	r 0,294 p<0,05	r 0,292 p<0,05	r 0,346 p<0,05
REP-IchP	-	-	r 0,996 p<0,05	r 0,798 p<0,05
REP-Th	-	-	-	r 0,790, p<0,05

Table 2; Results showing a statistical correlation between occipital angle (OA) and tentorial angle (TA) and the amount of resection

Conclusions: The entire MTR can be reached with RSIT, but access to the anterior part will become more difficult as the tentorial and occipital angle increases. The advantages of RSIT over current surgical approaches are thought to be: shorter surgical distance and an alternative anatomical corridor. Case series are needed to better understand the feasibility of this surgical approach.

Keywords: Cadaver, Mediobasal temporal region, retrosigmoid, transtentorial

References

1. Yaşargil M, Wieser H, Valavanis A, et al. Surgery and results of selective amygdala-hippocampectomy in one hundred patients with nonlesional limbic epilepsy. Neurosurg Clin N Am. 1993; 4 (2): 243-61.
2. Yaşargil MG, Teddy PJ, Roth P. Selective amygdalo-hippocampectomy. Operative anatomy and surgical technique. Adv Tech Stand Neurosurg. 1985; 12: 93-123.
3. Türe U, Harput MV, Kaya AH, et al. The paramedian supracerebellar-transtentorial approach to the entire length of the mediobasal temporal region: an anatomical and clinical study. Laboratory investigation. J Neurosurg. 2012; 116 (4): 773-91.
4. Lafazanos S, Türe U, Harput MV, et al. Evaluating the importance of the tentorial angle in the paramedian supracerebellar-transtentorial approach for selective amygdalohippocampectomy. World Neurosurg. 2015; 83 (5): 836-41.
5. Campero A, Tróccoli G, Martins C, et al. Microsurgical approaches to the medial temporal region: an anatomical study. Neurosurgery. 2006; 59 (4 Suppl 2): ONS 279-307; discussion ONS 307-8.
6. Erdem A, Yaşargil MG, Roth P. Microsurgical anatomy of the hippocampal arteries. J Neurosurg. 1993; 79 (2): 256-65.
7. Nieuwenhuys R, Voogd J, van Huijzen C. The Human Central Nervous System: Springer-Verlag. New York; 2008. pp: 361-86
8. Türe U, Pamir M. Small petrosal approach to the middle portion of the mediobasal temporal region: technical case report. Surg Neurol. 2004; 61: 60-7.
9. Yaşargil M. Anatomy. Microneurosurgery, vol. IVA. Thieme, New York 1994. pp: 16-69.
10. Yaşargil M. Surgical Approachs. Microneurosurgery, vol. IVB. Thieme, New York 1996. pp: 252-285.
11. Türe U, Harput MV, Kaya AH, , et al. The paramedian supracerebellar-transtentorial approach to the entire length of the mediobasal temporal region: an anatomical and clinical study: Laboratory investigation. J Neurosurg. 2012; 116 (4): 773-91.
12. Wieser H, Yaşargil M. Selective amygdalohippocampectomy as a surgical treatment of mesiobasal limbic epilepsy. Surg Neurol. 1982; 17: 445-57.
13. Yaşargil M, Krayenbühl N, Roth P, et al. The selective amygdalohippocampectomy for intractable temporal limbic seizures. Historical vignette. J Neurosurg. 2010; 112: 168-85.
14. Olivier A. Temporal resections in the surgical treatment of epilepsy. Epilepsy Res Suppl. 1992; 5: 175-88.
15. Rhoton AL, Jr. The cerebellopontine angle and posterior fossa cranial nerves by the retrosigmoid approach. Neurosurgery. 2000; 47 (3 Suppl): 93-129.
16. Velho V, Naik H, Bhide A, et al. Lateral Semi-sitting Position: A Novel Method of Patient's Head Positioning in Suboccipital Retrosigmoid Approaches. Asian J Neurosurg. 2019; 14 (1): 82-6.

OP-III/104

Transmastoid Infralabyrinthine Posterior Petrosal Approach to the Ventral Skull Base: limitations, advantages and anatomical tricks

Onur SARIKAYA[1], Mustafa Eren YUNCU[1], Berra BILGIN[2], Ali KARADAG[3], Mustafa GUVENCER[4]

[1]University of Health Sciences, Tepecik Research and Training Hospital, Department of Neurosurgery, Izmir, Turkey
[2]Tokat State Hospital, Department of Neurosurgery, Tokat, Turkey
[3]University of Health Sciences, Izmir Faculty of Medicine, Department of Neurosurgery, Izmir, Turkey
[4]Izmir Tınaztepe University, Faculty of Medicine, Department of Anatomy, Izmir, Turkey

Objectives: Transmastoid infralabirintine posterior petrosal approach (TIPPA) is an alternative approach to the ventral brainstem and petroclival region extended lesions with hearing preserving. The petroclival region, the middle and lower neurovascular complex structures around the cerebellopontine angle (CPA) could be reached. Endoscope assistance provides a maximum exposure with minimal brain retraction. Our aim is to describe the limitations of TIPPA, advantages and disadvantages.

Background: Anatomical dissection of the ventral brain stem and petroclival region needs to prevent the hearing loss, is a challenging and includes some.

Method: Colored silicone injected four (4) adult cadaver heads (8 sides) with lateral park bench position were used. TIPPA were evaluated with using neuroendoscope and microsurgical dissection.

Results: Asterion, suprameatal crest, spine of henle and mastoid air cells were revealed (Fig. 1A-B). Next, transverse, sigmoid sinuses and mastoid antrum were observed (Fig. 1C). After exposing the semicircular canals, the facial nerve was shown between the digastric ridge and the lateral semicircular canal. Between the sigmoid sinus and the superior petrosal sinus, the posterior fossa dura including the sinodural angle and the trautman's triangle were defined (Fig. 1D). The dura was opened and the ventral brainstem, petroclival region and CPA were reached (Fig. 1E-F). It was shown that the surgical view was expanded with using endoscope, especially in the middle and lower neurovascular structures of the CPA (Fig. 2A-D). The tympanic and labyrinthine segments of the facial nerve are not exposed in TIPPA and access to the middle cranial fossa.

Figure 1

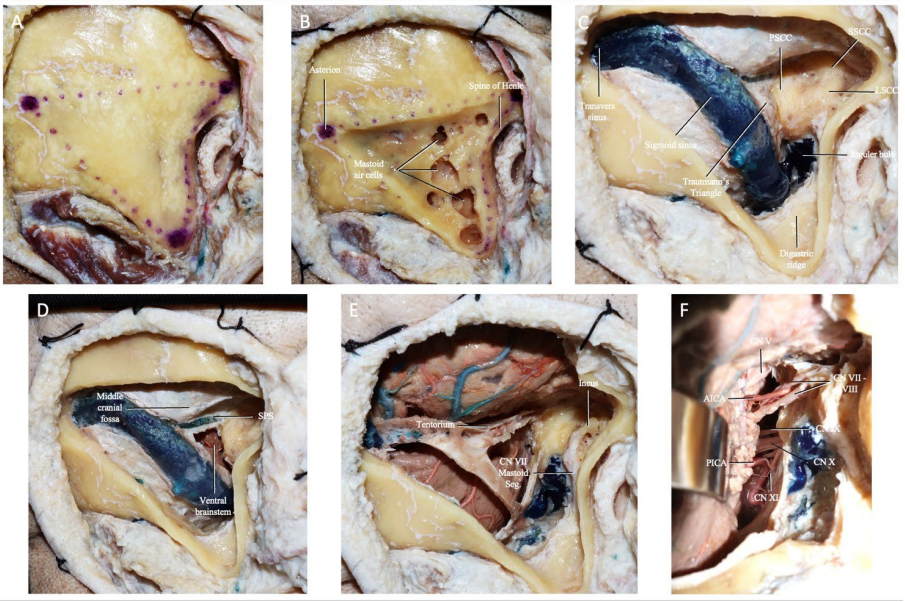

Showing the postauricular skin incision, mastoidectomy was performed at the borders of Fukushima's outer mastoid triangle (A). Mastoid air cells were shown by drilling the cortical bone of the mastoid bone (B). They were drilled to expose transverse sinus, sigmoid sinus, jugular bulb and semicircular canals (C). The dura was opened near the borders of Trautmann's triangle, the posterior cranial fossa and the ventral brain stem were shown (D). With the extended approach, the semicircular canals were removed, the tympanic segment of the facial nerve was shown, and the middle cranial fossa dura was opened (E). The IAM was opened and the labyrinthine and canalicular segment of the facial nerve were shown, the cerebellum was excluded and the CPA middle and lower neurovascular complex was revealed (F). Abbreviations: AICA = anterior inferior cerebellar artery; CN = cranial nerve; CPA = cerebellopontine angle; IAM = Internal acoustic meatus; LSCC = lateral semicircular canal; PICA = Posterior inferior cerebellar artery; PSCC = posterior semicircular canal; SPS = superior petrosal sinüs; SSCC = superior semicircular canal

Figure 2

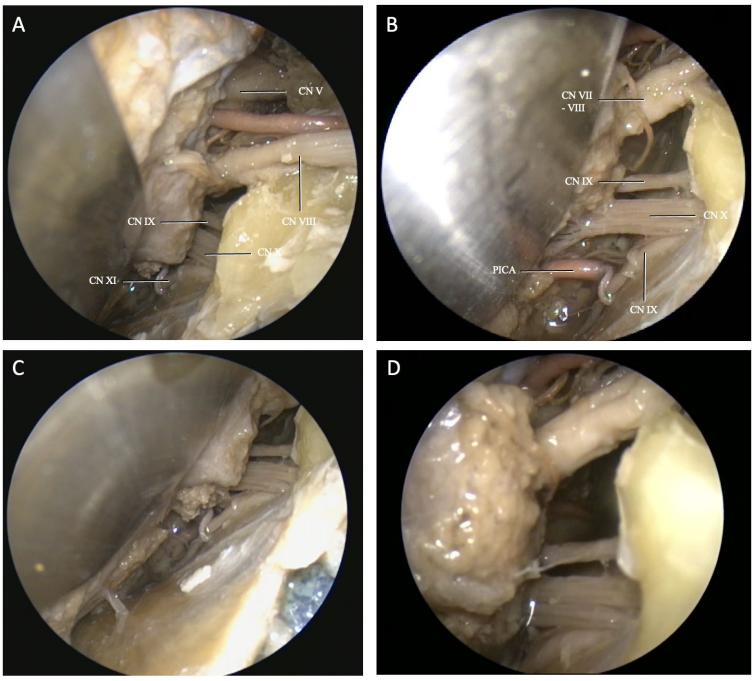

Endoscopic focus on the CN VII – VIII and CMB with wider surgical exposure (A). A close view at the CMB middle and lower neurovascular complex with an endoscope. The origin of the CN IX - X - XI and PICA are seen (B). Endoscopic detailed view of Fig. B (C-D). Abbreviations: CN = cranial nerve; CPA = cerebellopontine angle; PICA = Posterior inferior cerebellar artery

Conclusions: TIPPA is less invasive approach than the lateral and posterolateral approaches. Endoscopic systems provide wider surgical exposure with less retraction. It can be preferred in selected cases presented with ventral brain stem and petroclival region lesions. We believe that this techniques will be more preferred in near future with more experience.

Keywords: infralabyrinthine, mastoidectomy, neuroendoscopy, presigmoid

References

1. Tummala, Ramachandra P., Ernesto Coscarella, and Jacques J. Morcos. "Transpetrosal approaches to the posterior fossa." *Neurosurgical focus* 19.2 (2005): 1-9.
2. Acioly, Marcus André, et al. "The Infralabyrinthine Route to the Petrous Apex: A Comparison of the Extradural Infralabyrinthine and Retrosigmoid Intradural Inframeatal Approaches." *Journal of Neurological Surgery Part B: Skull Base* 77.S 02 (2016): FP-17.
3. Cömert, Ela, et al. "Surgical anatomy of the infralabyrinthine approach." *Otolaryngology--Head and Neck Surgery* 151.2 (2014): 301-307.
4. Rhoton Jr, Albert L. "The temporal bone and transtemporal approaches." *Neurosurgery* 47.3 (2000): S211-S265.

OP- V/105

Madison Objective Self-Assessment Tool for Microvascular Laboratory Training

Abdullah Keles[1], Chloe Dumot[1], Gokce Hatipoglu Majernik[1], Roy Chebel[1], Ahmed Elbayomy[1], Mehmet Sabri Gurbuz[1], Turab Gasimov[1], Guillermo Garcia Oriola[1], Derin Tuna[1], Cagdas Ataoglu[1], Ufuk Erginoglu[1], Burak Ozaydin[1], Mustafa Kemal Baskaya[1]

[1]Department of Neurological Surgery, University of Wisconsin, School of Medicine and Public Health, Madison, Wisconsin, US

Objectives: The objective of the study is to establish an objective and reliable training-specific self-assessment tool for trainees of different skill levels.

Background: Detailed objective assessment and feedback are of utmost importance for microvascular bypass skills training. An ideal assessment tool should be objective, reliable, well-defined, and easy to use.

Method: The Baskaya microvascular bypass training curriculum was completed by eight trainees using stereo microscopes. Each trainee scored each of their 31 microvascular bypass end-products twice using the new Madison Objective Self-Assessment Tool. The trainees' end products were then scored independently by one expert. The scoring was then compared using intraclass correlation coefficients to assess the inter-rater and intra-rater reliability of the self-assessment tool.

Madison Objective Self-Assessment Tool Metrics



Madison Objective Self-Assessment Tool Assessment for continuous Penrose suturing exercise

Madison Objective Self-Assessment Tool Metrics

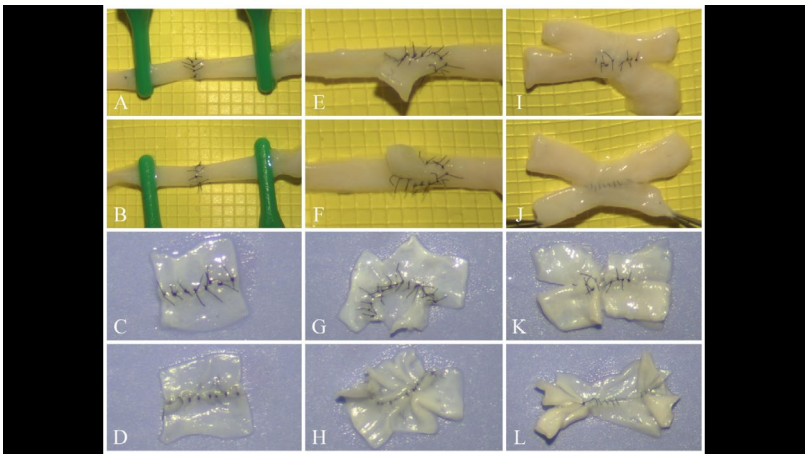

Assessment for Chicken vessel anastomosis exercises

Results: The results showed that the inter-rater and intra-rater agreement ranged from excellent (ICC > 0.90) to acceptable (ICC = 0.61–0.80) for all but two exercises. Two inter-rater ICC showed no significance, 0.32 [-0.10-0.63], for 2 mm Silicone Tube End-to-end Anastomosis and moderate agreement 0.52 [0.16-0.76], for Chicken Vessels Side-to-side Anastomosis with 10-0 respectively. This demonstrated that the Madison Objective Self-Assessment Tool (MOST) is reliable. The MOST was easy to apply and required only a few minutes per microsurgical exercise according to the participants.

Results for the Intra-Rater and Inter-Rater coefficient correlation (ICC)

Table 3: Results for the intra-rater and inter-rater coefficient correlation (ICC).

	ICC INTRA-RATER [95%]	ICC INTER-RATER [95%]
6 cm Continuous Penrose Suturing with 6-0	0.95 [0.91-0.97]	0.82 [0.68-0.90]
6 cm Continuous Penrose Suturing with 7-0	0.93 [0.88-0.97]	0.83 [0.70-0.91]
3 mm Silicone Tube End-to-end Anastomosis with 9-0	0.72 [0.45-0.87]	0.66 [0.36-0.84]
2 mm Silicone Tube End-to-end Anastomosis with 9-0	0.85[0.69-0.93]	0.32 [-0.10-0.63]
3/2 mm Silicone Tube End-to-side Anastomosis with 9-0	0.79 [0.57-0.90]	0.76 [0.52-0.89]
3/3 mm Silicone Tube side-to-side Anastomosis with 9-0	0.86 [0.70-0.94]	0.83 [0.64-0.92]
Chicken Vessels End-to-end Anastomosis with 10-0	0.68 [0.38-0.85]	0.83 [0.65-0.92]
Chicken Vessels End-to-side Anastomosis with 10-0	0.84 [0.66-0.93]	0.64 [0.32-0.82]
Chicken Vessels Side-to-side Anastomosis with 10-0	0.97 [0.93-0.99]	0.52 [0.16-0.76]

Results for the Intra-Rater and Inter-Rater coefficient correlation (ICC). The results are presented as number and [95% confidence interval].

Conclusions: The MOST is an objective, reliable, and easy-to-use self-assessment test that can be easily utilized by different levels of trainee.

Keywords: bypass training, microanastomosis training, microvascular surgery, self-assessment tool

References

1. Niveditha M, Sharma R, Suri A. Microsurgical suturing assessment scores: a systematic review. *Neurosurg Rev*. 2021:1-6.

OP-VI/106

Microvascular Anastomosis Courses for All: A New Approach for LMICs

Abdullah Keles[1], Turab Gasimov[2], Mehmet Sabri Gurbuz[3], Zviad Malazonia[4], Burak Ozaydin[5], Mustafa K. Baskaya[1]

[1]Department of Neurological Surgery, University of Wisconsin, School of Medicine and Public Health, Madison, Wisconsin, US
[2]Department of Neurosurgery, Respublika Diaqnostika Mərkəzi, Baku, Azerbaijan
[3]Department of Neurosurgery, Istanbul Medeniyet University, Istanbul, Türkiye
[4]Department of Neurological Surgery, Caucasus Medical Center, Tbilisi, Georgia
[5]Department of Neurological Surgery, University of Oklahoma College of Medicine, Oklahoma City, Oklahoma, US

Objectives: To organize free, accessible microanastomosis courses all over the world wherever needed.

Background: Despite over five decades since the introduction of microsurgical techniques in neurosurgery, these fundamental methods remain inaccessible in many countries, particularly in Low- and Middle-Income Countries (LMICs). In these countries, neurosurgeons are compelled to travel overseas in order to receive such training. This process is time-consuming, costly, and involves lengthy procedures such as obtaining visas.

Method: At Madison Microneurosurgery Initiative(MMI), we came up with a new approach to address this issue. In our headquarter(Mustafa K. Baskaya Laboratory), we prepared a microvascular anastomosis course setup including 10 trainee tabletop stereo microscopes, one tabletop demonstration stereo microscope with two observer tubes, an optional camera, instruments, light sources, and practice materials.After setting up the course setup, we reached out to our connections from LMICs and organized free hands-on courses in their home countries.

MMI microvascular anastomosis course setup



Our microvascular anastomosis course setup includes 10 trainee tabletop stereo microscopes, one tabletop demonstration stereo microscope with two observer tubes, an optional camera, instruments, light sources, and practice materials.

Results: To date, we have organized seven hands-on microvascular anastomosis courses, held in seven institutions across four countries; Türkiye, Georgia, Azerbaijan, and Paraguay. In six of these locations, our courses marked the inaugural occurrence of microvascular anastomosis training in those cities, while in three of the locations, it served as the first-ever course of its kind in the entire country. In six of these locations, we organized a comprehensive one-day hands-on course that spanned from 9 am to 6 pm. These courses encompassed various lectures, demonstration sessions, and practical training opportunities. Likewise, in Paraguay, we conducted a two-day course with a greater focus on hands-on practice, providing participants with ample opportunities for practical training.Across the seven centers, we provided training to a total of 115 trainees.

MMI hands-on microvascular anastomosis courses



To date, we have organized seven hands-on microvascular anastomosis courses, held in seven institutions across four countries; Türkiye, Georgia, Azerbaijan, and Paraguay.

Conclusions: The organization of free and accessible microanastomosis courses is viable and can be implemented worldwide, wherever the need arises.

Keywords: global neurosurgery, microanastomosis course, microvascular surgery, training

References

1. Yasargil MG. Microsurgery: applied to neurosurgery. Elsevier; 1969.

2. Dempsey RJ. Neurosurgery in the Developing World: Specialty Service and Global Health. Editorial Material. World Neurosurg. Apr 2018;112:325-327. doi:10.1016/j.wneu.2018.02.099

OP-III/108

Comprehensive Review of the Microsurgical Anatomy of the Middle Longitudinal Fasciculus

Cise Sahin[1], Aysegul Esen Aydin[2]

[1]Department of Neurosurgery, Prof. Dr. Cemil Tascioglu City Hospital, University of Health Sciences, Istanbul, Turkey
[2]Department of Neurosurgery, Arnavutkoy State Hospital, Istanbul, Turkey

Objectives: This study aims to elucidate the microsurgical anatomy of the Middle Longitudinal Fasciculus (MdLF) and its adjacent structures through the application of the white matter dissection method. By employing the fiber dissection technique, our primary objective is to provide a detailed description and visualization of the microsurgical anatomy of the MdLF.

Background: Middle longitudinal fasciculus (MdLF) is one of the association fibers, and originates from the temporal pole, then extends across the superior temporal gyrus (STG) and reaches the inferior parietal lobe (IPL) (1). In recent years, some authors have been suggested that this fiber bundle is related to language, auditory, visual and cognitive functions (2-4).

Method: Four formalin-fixed cadaveric human brains were dissected by Klingler method. A step-by-step dissection was utilized to expose white matter pathways, including MdLF.

Results: MdLF consists of three parts: anterior, middle and posterior. The anterior part of MdLF originates from the temporal pole and extends to posterior along the STG (Figure 1). After removing the frontal, parietal and temporal operculums, insula was exposed in the aperture of the Sylvian fissure. The anterior and middle portions of the STG were removed and the rest of the anterior part of MdLF was visualized (Figure 2). Heschl gyrus was dissected and shortened. Thus, the middle part of MdLF, which extended from the posterior of the Heschl gyrus to the medial of the AF, was observed (Figure 3).

Figure 1

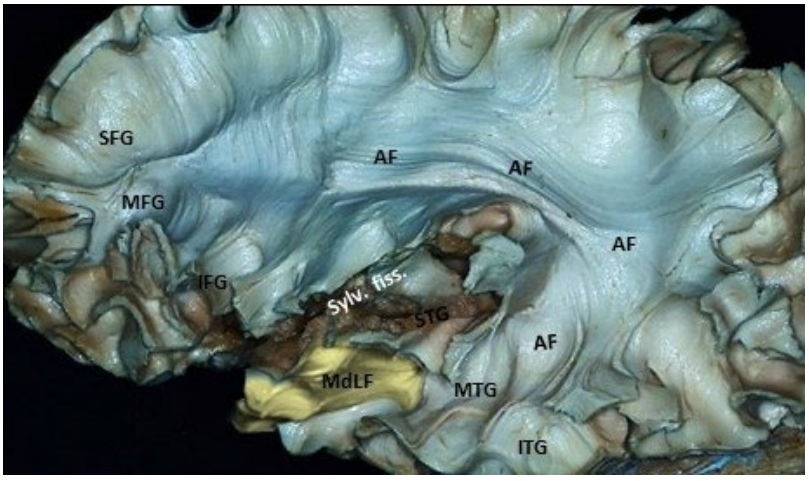

Dissections are made from lateral to medial direction in the left hemisphere. Arcuate fasciculus with frontal and temporal extension is exposed with the removal of superior longitudinal fasciculus 2 and 3 fibers. The anterior part of middle longitudinal fasciculus originating from temporal pole is shown with the dissection of superior temporal gyrus. The anterior part of middle longitudinal fasciculus is shown in yellow colour. AF: Arcuate fasciculus. IFG: Inferior frontal gyrus, ITG: Inferior temporal gyrus, MdLF: Middle longitudinal fasciculus, MFG: Middle frontal gyrus, MTG: Middle temporal gyrus, Sylv fiss: Sylvian fissure, SFG: Superior frontal gyrus, STG: Superior temporal gyrus.

Figure 2

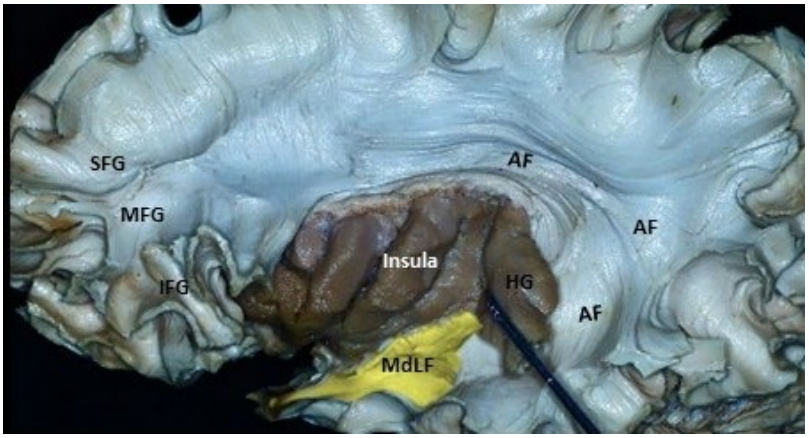

After removing the frontal and temporal opercula around the Sylvian fissure, the insula is exposed. Superior temporal gyrus is removed by preserving the Heschl gyrus, and middle longitudinal fasciculus extending from the temporal pole to the Heschl gyrus are shown. The anterior part of middle longitudinal fasciculus is shown in yellow colour with the rest part. AF: Arcuate fasciculus. HG: Heschl gyrus, IFG: Inferior frontal gyrus, ITG: Inferior temporal gyrus, MdLF: Middle longitudinal fasciculus, MFG: Middle frontal gyrus, MTG: Middle temporal gyrus, SFG: Superior frontal gyrus

Figure 3

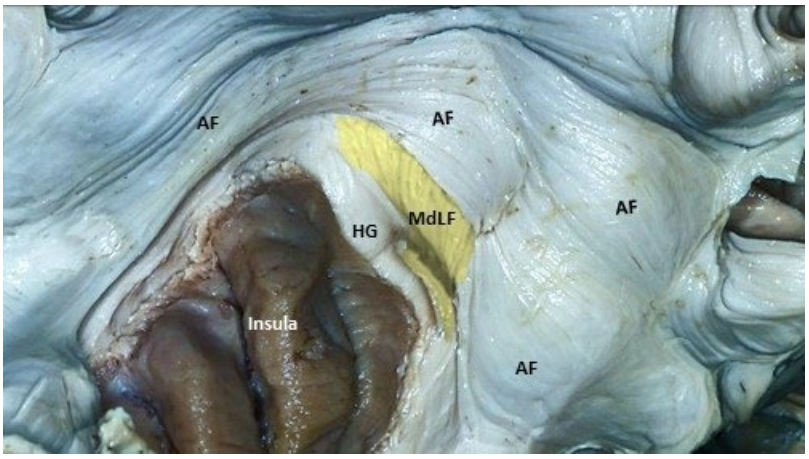

A close view focusing on the posterior insular region. Heschl gyrus is decorticated. The middle part of middle longitudinal fasciculus located at the posterior of Heschl gyrus is

shown in yellow colour. AF: Arcuate fasciculus, HG: Heschl gyrus, MdLF: Middle longitudinal fasciculus

Conclusions: MdLF is a cortico-cortical association pathway located in the temporoparietal region of the brain, and associated with language, auditory, visual and cognitive functions. Because MdLF was defined later than other white matter fibers, a limited number of anatomical studies on MdLF have been conducted in the literature so far. Although anatomical dissection studies provide detailed information for approaches to structures adjacent to this pathway, collaborating the further tractography studies are needed.

Keywords: Dissection, middle longitudinal fasciculus, neuroanatomy, white matter

References

1. Makris N, Papadimitriou GM, Kaiser JR, Sorg S, Kennedy DN, Pandya DN. Delineation of the middle longitudinal fascicle in humans: a quantitative, in vivo, DT-MRI study. Cereb Cortex. 2009 Apr;19(4):777-85.
2. Menjot de Champfleur N, Lima Maldonado I, Moritz-Gasser S, Machi P, Le Bars E, Bonafé A, Duffau H. Middle longitudinal fasciculus delineation within language pathways: a diffusion tensor imaging study in human. Eur J Radiol. 2013 Jan;82(1):151-7.
3. Conner AK, Briggs RG, Rahimi M, Sali G, Baker CM, Burks JD, Glenn CA, Battiste JD, Sughrue ME. A Connectomic Atlas of the Human Cerebrum-Chapter 12: Tractographic Description of the Middle Longitudinal Fasciculus. Oper Neurosurg (Hagerstown). 2018 Dec 1;15(suppl_1):S429-S435.
4. Kalyvas A, Koutsarnakis C, Komaitis S, Karavasilis E, Christidi F, Skandalakis GP, Liouta E, Papakonstantinou O, Kelekis N, Duffau H, Stranjalis G. Mapping the human middle longitudinal fasciculus through a focused anatomo-imaging study: shifting the paradigm of its segmentation and connectivity pattern. Brain Struct Funct. 2020 Jan;225(1):85-119.

OP-VI/109

Photo-Stacking Technique for Neuroanatomical Education

Daniel Ballesteros Herrera[1], Jose Alfonso Alvarez Castro[1]

[1]National Institute of Neurology and Neurosurgery "Manuel Velasco Suarez"

Objectives: Assess the ability to identify and label key neuroanatomical structures using photo-stacking technique.

Background: Photo-stacking can be used in a variety of medical fields, and can be applied to various types of medical imaging, including radiography, CT scans, MRI, and ultrasound. Detailed three-dimensional neuroanatomical knowledge is of paramount importance in neurosurgical training. However, these tools are usually expensive and not widely available. A simple and inexpensive method for producing high-quality images and 3D models is proposed.

Method: We describe in a stepwise approach the photo-stacking method used to produce those mentioned above. Time for picture acquisition, file conversion, processing, and final production was measured using two processing methods. We also report the total number and file size of pictures. Measures of central tendency and dispersion report the measurements.

Results: Ten models were used in both methods for 20 models and high-definition photographs. The mean number of acquired pictures was 40.6 (14-67), picture acquisition time 51.50 ± 18.8s, time of file conversion 250 ± 134.6s, processing time 50.46 ± 21.46 s and 41.97 ± 20.84s, and 3D reconstruction time was 4.29 ± .74 s and 3.89 ± 0.60s for methods B and C, respectively. The mean file size of RAW files is 1010 ± 452 MB and 101.06 ± 38.09 MB for JPG files after conversion. The final image means size is 71.9 ± 0.126 MB, and the 3D model means file size 37.4 ± 0.516 MB using both methods. The equipment used was cheaper than other systems reported.

Photography with Photo-Stacking Technique



Highly detailed photography of the brain

Photography with Photo-Stacking Technique



Highly detailed photography of the brain

Photography with Photo-Stacking Technique

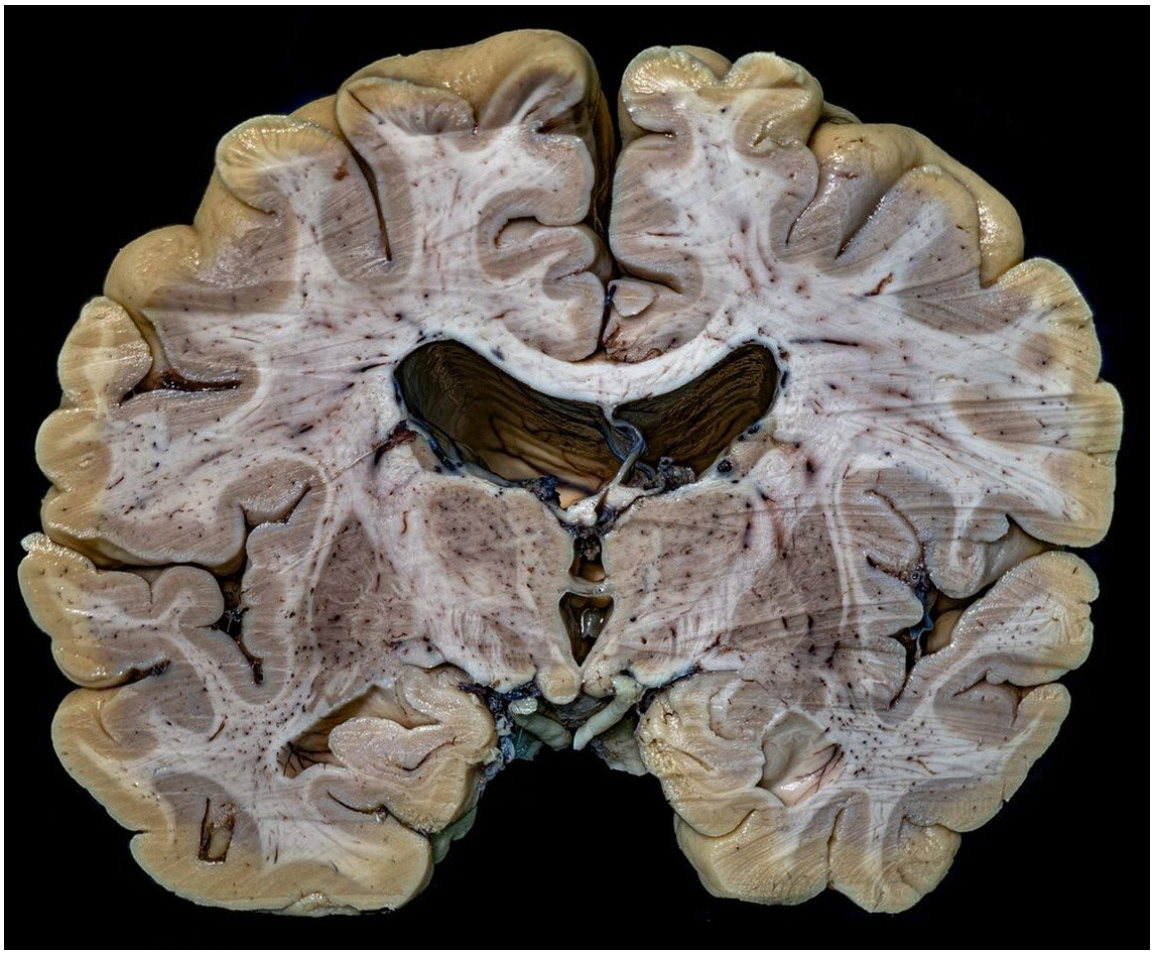

Highly detailed phtography of the brain

Conclusions: Overall, photo-stacking is a powerful tool that can enhance medical education. By providing a detailed visualizations of medical conditions and procedures, it help medical professionals make better-informed decisions and improve outcomes. Thus, the reported technique is a simple and inexpensive method to create 3D models and high-definition pictures that could prove valuable in neuroanatomy training.

Keywords: Neuroanatomy, Education, Neurosurgery, Virtual dissection.

OP-IV/110

Technical and Cosmetic Improvement of Craniotomy

Sebastião Gusmão[1], Roberto Leal[3], Arthur Nicolato[2]

[1]Universidade Federal do Vale do Jequitinhonha e Mucuri
[2]Universidade Federal de Minas Gerais
[3]Instituto da Pequenas Missionárias de Maria Imaculada - Hospital Madre Teresa

Objectives: To describe a technical and cosmetic improvement of the craniotomy

Background: Craniotomy is usually performed through burr holes which are connected to one another using the craniotome. Reconstruction of the skull is performed by fixation of the bone flap using titanium plates. A major disadvantage of this procedure is that the burr holes cause an aesthetic defect, especially in the frontal region of the skull. Furthermore, electric saw use is associated with a high risk of dural injury.

Method: The boundaries of the craniotomy are marked by drilling a groove through the outer lamina and diploe using a high-speed electric drill. An area of this bone groove is chosen, and a bevelled cut towards the centre of the opening, which reaches the inner lamina, is made to the extent of 15 mm. The lamina is fractured using a lever inserted into this bevelled cut. Burr holes were not made and reconstruction of the bone flap with plates and screws was not performed. Seventy-five patients were operated on using this technique and the cosmetic results were evaluated postoperatively using computed tomography (CT) and clinical evaluation.

Drilling

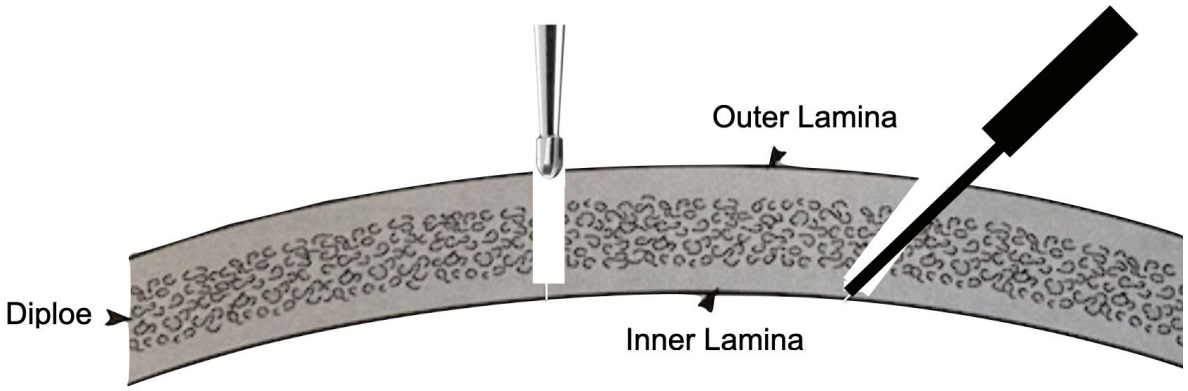

bone groove in the outer lamina and diploe; bevelled groove in the outer lamina, diploe and inner lamina for application of the lever; and fracture of the inner lamina

Lever



Lever

Fronto-temporo-parietal craniotomy.

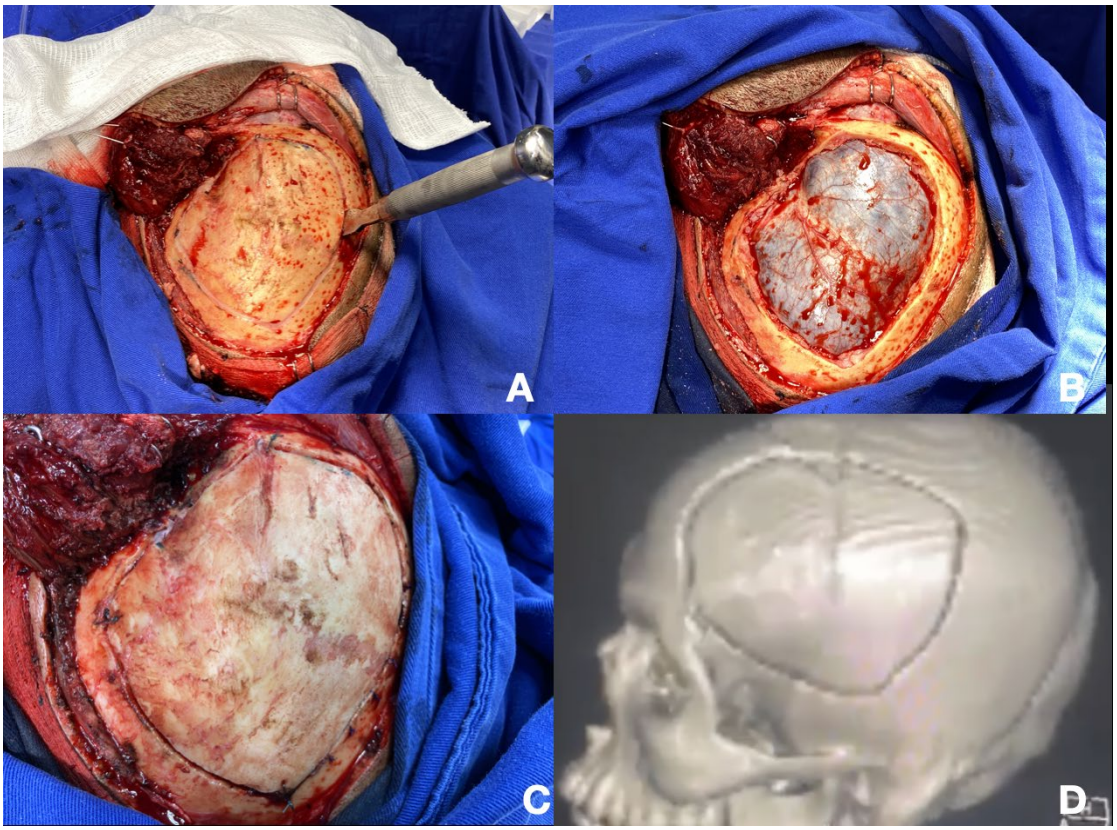

a)Bone groove defining the contour of the craniotomy and lever applied to the slit; b) craniotomy; c) replacement of the bone flap and fixation with three sutures; d) post-op CT Scan.

Results: In all cases, the procedure was performed without adverse events, except for dura mater lesion in three cases. The time spent performing the procedure was approximately equal to that spent in a usual craniotomy. Excellent bone fitting and osseous fusion were observed on postoperative CT scans. The clinical evaluation demonstrated excellent cosmetic results.

Conclusions: The proposed technical modification for removing the bone flap (craniotomy) is safe, aesthetic and economical.

Keywords: Craniotomy, Osteoplastic craniotomy, Surgical technique

References

1. González-Darder, J M. Trepanation, Trephining and Craniotomy. Switzerland: Springer International Publishing; 2019.
2. Badie B. Cosmetic reconstruction of temporal defect following pterional craniotomy. Surg Neurol. 1996;45: 383–384.
3. Engelhardt M, Uhlenbruch S, Christmann A, Miede C, Eufinger H, Scholz M, Harders A, Schmieder K. Accidental dural tears occurring during supratentorial craniotomy - a prospective analysis of predisposing factors in 100 patients. Zentralbl Neurochir. 2005;66(2):70-4.
4. Colohan AR, Jane JA, Newman AS, Maggio WW. Frontal sinus approach to the orbit: technical note. J. Neurosurg. 1985; 63:811-3,.
5. Colohan AR, Jane JA, Park TS, Persing JA. Bifrontal osteoblastic craniotomy utilizing the anterior wall of the frontal sinus: technical note. Neurosurgery. 1985;16(6):822-4.
6. Wagner W. Die temporäre Resektion des Schädeldaches an Stelle der Trepanation. Zentralbl Chir. 1889;16:833–8.
7. Jill Peterson, Paul C. Dechow. Material properties of the inner and outer cortical tables of the human parietal bone. Anat Rec. 2002;268:7–15

OP-I/111

The extreme anterior interhemispheric transcallosal approach for pure aqueduct tumors: an anatomical study

Alberth Patricio Munoz-Gualan[1], Pinar Kuru Bektasoglu[2], Emin Oğuzcan Yamaner[1], Abuzer Gungor[3], Uğur Türe[1]

[1]Yeditepe University School of Medicine, Department of Neurosurgery, Istanbul
[2]Sivas Numune Hospital, Department of Neurosurgery, Sivas
[3]Bakirkoy Research and Training Hospital for Psychiatry, Neurology and Neurosurgery, Department of Neurosurgery, Istanbul

Objectives: We aimed to show the normal anatomy of the cerebral aqueduct and the feasibility of the approach to remove tumors within the aqueduct.

Background: The cerebral aqueduct is a deep structure located in the diencephalon. It is part of the ventricular system and connects the third and fourth ventricles. The aqueduct has three portions: superior, medial, and inferior. Pure aqueduct tumors occur in the superior portion, and lesions located within the aqueduct are difficult to remove through conventional approaches. Most aqueduct tumors are biopsied and accompanying hydrocephalus is addressed through an endoscopic third ventriculostomy (ETV). The extreme anterior interhemispheric transcallosal approach makes use of a natural corridor to remove aqueduct lesions. Herein, we describe the detailed anatomy of this approach for resecting pure aqueduct tumors in the superior portion of the aqueduct.

Method: Ten human brain hemispheres and one cadaveric head were dissected under an operative microscope with 6x to 40x magnification. The cerebral aqueduct anatomy was delineated along with the relationship to nearby structures in the extreme anterior interhemispheric transcallosal approach.

Results: We described the anatomy of the cerebral aqueduct within the brain and showed that, with the proper angle for the extreme anterior interhemispheric transcallosal approach, lesions in the cerebral aqueduct can be reached in a single session without damaging periventricular structures.

Conclusions: The extreme anterior interhemispheric transcallosal approach provides a direct corridor to the cerebral aqueduct and, thus, is feasible for resecting pure aqueduct tumors in an already dilated intraventricular foramen.

Keywords: Cerebral aqueduct, Fiber dissection, Microsurgical anatomy, Transcallosal approach

References

1. Serra C, Ture U: The extreme anterior interhemispheric transcallosal approach for pure aqueduct tumors: Surgical technique and case series. Neurosurg Rev 45(1):499-505, 2022.
2. Goga C, Ture U: The anterior transcallosal approach to a cerebral aqueduct tumor: A 3-dimensional operative video. Neurosurgery 10 Suppl 3:492, 2014.
3. Ture U, Yasargil MG, Al-Mefty O: The transcallosaltransforaminal approach to the third ventricle with regard to the venous variations in this region. J Neurosurg 87(5):706–715, 1997.
4. Ture U, Yasargil MG, Friedman AH, Al-Mefty O: Fiber dissection technique: Lateral aspect of the brain. Neurosurgery 47(2):417- 426; discussion 426-427, 2000.

OP-VI/112

Ct-Mri Image Fusion Based AR Assisted Neuronavigation for Extradural Anterior Clinoidectomy

Melih Bozkurt[2], Koral Erdoğan[1], Mahmut Özden[1]

[1]Bahcelievler Memorial Hospital
[2]Arel University

Objectives: Safe drilling of anterior clinoid process, superiority of CT-MRI fusion with AR assisted neuronavigation.

Background: Treatment of anterior clinoid process lesions adjacent to critical neurovascular structures requires accurate route planning and secure and reliable image guidance to provide intraoperative guidance with the highest precision. In this study, we illustrate the ability to confirm the anterior clinoid lesion with the combination of CT and MR images, and we demonstrate the results of CT and MR image data fusion for augmented reality (AR) assisted extradural anterior clinoidectomy with the help of a navigation system.

Method: Patient with ACP lesion underwent multi detector computed tomography (MDCT) and magnetic resonance imaging (MRI). The fusion images were used for surgical planning and intraoperative image guidance.

Results: Targeting the ACP with CT provides rapid and precise coordinates for stereotactic localization. However, the anatomic identification and discrimination of neural structures adjacent to the ACP are poor compared to MRI. MRI much more precisely defines anatomical details.

Conclusions: CT and MRI are crucial for preoperative evaluation of the anterior clinoidectomy procedure (extra and intradural). The use of CT-MR image fusion provides a more precise method for planning the procedure and gives an advantage for the surgical results in AR assisted navigated neurosurgery of ACP lesions.

Keywords: Augmented reality, Navigation, CT-MRI fusion

References

1- Nemec SF, Donat MA, Mehrain S, Friedrich K, Krestan C, Matula C, Imhof H, Czerny C. CT-MR image data fusion for computer assisted navigated neurosurgery of temporal bone tumors. Eur J Radiol. 2007 May;62(2):192-8. doi:10.1016/j.ejrad.2006.11.029.
2- Savas A, Bozkurt M, Akbostanci C. A comparison between stereotactic targeting methods of the subthalamic nucleus in cases with Parkinson's disease. Acta Neurochir Suppl. 2013;117:35-41. doi:10.1007/978-3-7091-1482-7_6.

OP-VI/113

Impact of Mixed Reality On The Planning Of Complex Neuro-Oncological Cases

Elisa Colombo[1], Carlo Serra[1], Menno Germans[1], Luca Regli[1], Giuseppe Esposito[1], Alexander Küffer[1], Tristan van Doormaal[1]

[1]University Hospital Zurich

Objectives: To document the use of a novel mixed reality system for preoperative neurosurgical planning and endorse its implementation for a more precise anatomical understanding and approach customization.

Background: Precise pre-operative surgical planning of complex intracranial lesions requires an excellent appreciation of the three-dimensional (3D) anatomy. 3D interactive patient-specific holograms could be more advantageous than standard imaging to optimize the intraoperative trajectory minimizing brain retraction and avoiding injury to important structures.

Method: Patients diagnosed with surgically complex neuro-oncologic lesions who underwent elective surgery in our Institution were prospectively selected. The preoperative magnetic resonance imaging (MRI) was utilized to segment the lesions and the surrounding anatomical structures, which was partially performed with AI trained algorithms (Lumi, Augmedit, The Netherlands). Hologram preparation time (HPT) was documented. Surgical planning and matching of the hologram's with the patient's head in the intraoperative non-sterile phase were achieved with the use of mixed reality glasses, and time of intraoperative MxR use was documented for 10 cases. Modifications of the surgical approach after 3D visualization were noted.

Mixed Reality Implementation

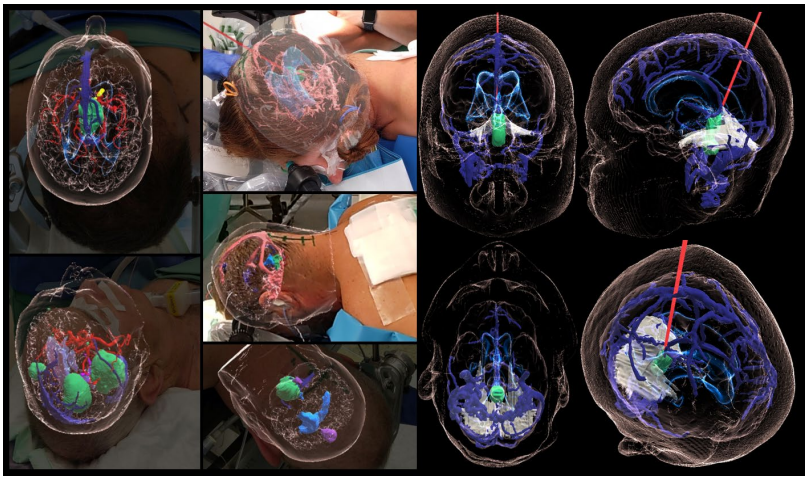

Overview of the preoperative implementation strategies of patient-specific 3D interactive holograms.

Results: Twenty patients were included. 14 patients (14/20, 70%) presented an infratentorial lesion. Mean HPT was 51 +/- 22 minutes, and mean total time of MxR use in the operating room was 8 +/4 minutes. After examination of the 3D hologram, the surgical approach was re-evaluated in two cases (2/20, 10%) for the sake of a more direct operative trajectory. Patient positioning was optimized in 2 cases (2/10, 20%) after interactive 3D visualization. Improved anatomical understanding was endorsed by all operating neurosurgeons.

Conclusions: Pre-operative study and surgical planning using 3D visualization of patient-specific anatomy provided a valuable adjunct for patient positioning and the identification of the best surgical trajectory. Faster, fully automatic segmentation and intraoperative guidance are the 2 most important next steps in Mixed Reality research.

Keywords: Neurosurgical oncology, Mixed Reality, 3D visualization, Pre-operative planning

References

1- Zawy Alsofy S, Sakellaropoulou I, Stroop R. Evaluation of Surgical Approaches for Tumor Resection in the Deep Infratentorial Region and Impact of Virtual Reality Technique for the Surgical Planning and Strategy. J Craniofac Surg. 2020 Oct;31(7):1865-1869. doi: 10.1097/SCS.0000000000006525.
2- van Doormaal JAM, Fick T, Ali M, Köllen M, van der Kuijp V, van Doormaal TPC. Fully Automatic Adaptive Meshing Based Segmentation of the Ventricular System for Augmented Reality Visualization and Navigation. *World Neurosurg*. 2021;156:e9-e24. doi:10.1016/j.wneu.2021.07.099.
3- Fick T, Doormaal JAM van, Tosic L, et al. Fully automatic brain tumor segmentation for 3D evaluation in augmented reality. *Neurosurgical Focus*. 2021;51(2):E14. doi:10.3171/2021.5.FOCUS21200.

OP- VI/114

Ventricular Tap-Parenchymal Damage Relationship: Anatomical and Radiological Study

Mehmet Emin Akyüz[1], Mehmet Hakan Şahin[1], Caner Fahrettin Kara[1], Muhammet Elveren[1], Mete Zeynal[1], Hakan Hadi Kadıoğlu[1]

[1]Atatürk University, Faculty of Medicine

Objectives: To show the damage occurred in the cerebral parenchyma during ventricular catheter placement. Finding the least damaging and shortest path for practical application.

Background: Parenchymal damage is theoretically expected in all cases of catheter placement in the ventricle. We aimed to find the most optimal intervention point by anatomically and radiologically examining 5 commonly used intervention points.

Method: Six human cadaveric heads were prepared using the Klingler method. A ventricular catheter was inserted at the usual points with a neuronavigator. Dissection was performed microsurgically with preservation of catheters. The relationships of catheters sent from these points with white matter fibers were revealed. In the second phase of our study; MRI of 50 adult patients with hydrocephalus were analyzed. The distances of the catheters from the skin to the ventricle were measured, and the angles were calculated according to the Frankfurt line (FH), posterior ear line (PKH) and median sagittal plane (MSP). The data were statistically analyzed. The data were statistically analyzed.

Figure 1

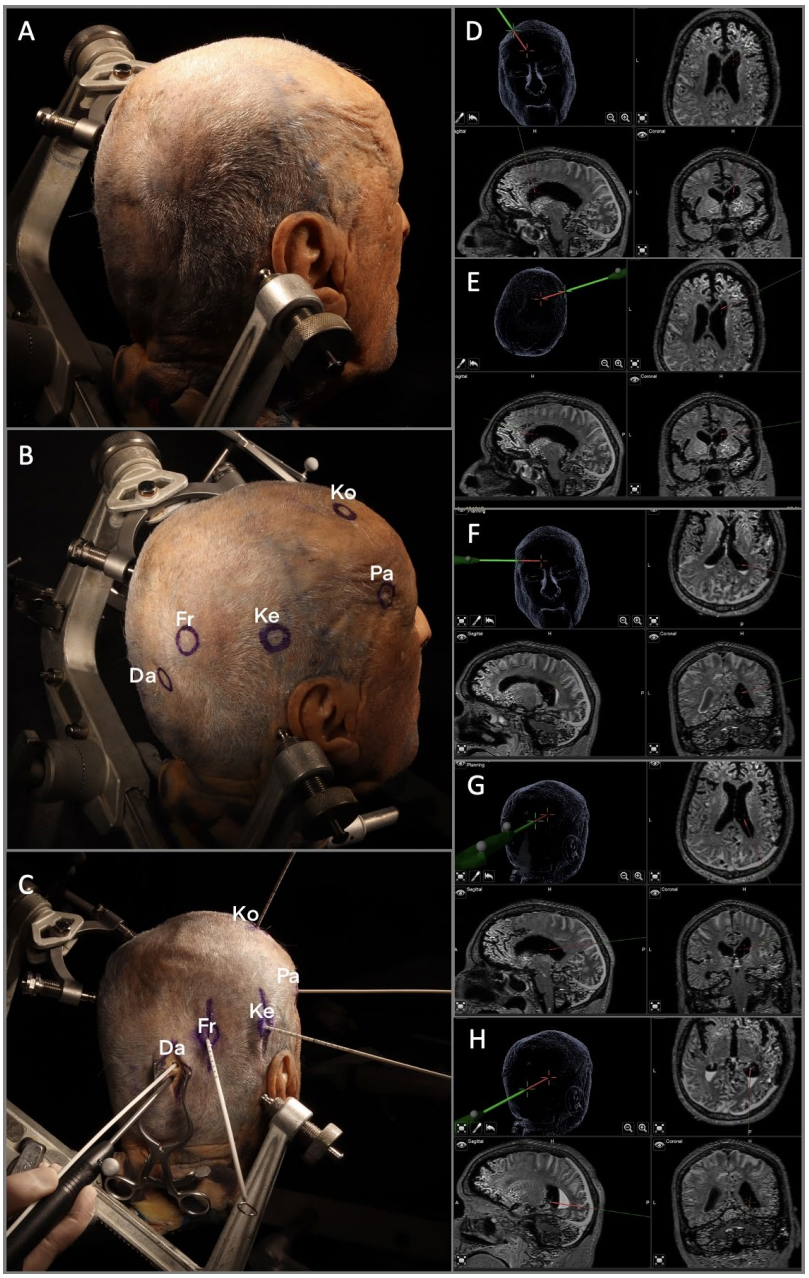

Common practice sites for ventricular tap include delivery of catheters, fixation of the head with 3-pin and registration with neuronavigator.

Results: The relationship of the catheters with U fibers, SLF2, SLF3, AF, MdLF, clastrum, claustrocortilal fibers, UF, corona radiata, internal capsule, IFOF, tapetum fibers, optic radiation, and VOF fibers was shown according to the route of delivery until reaching the ventricle. The least fiber group was observed in the catheter pathway sent from the Koher point. In the second group of data, the shortest pathway in the parenchyma was 12° from FL and 13° from MSP at the Dandy point, and the longest pathway was 28° from FL and 18° from PEL at the Paine point.

Figure 2

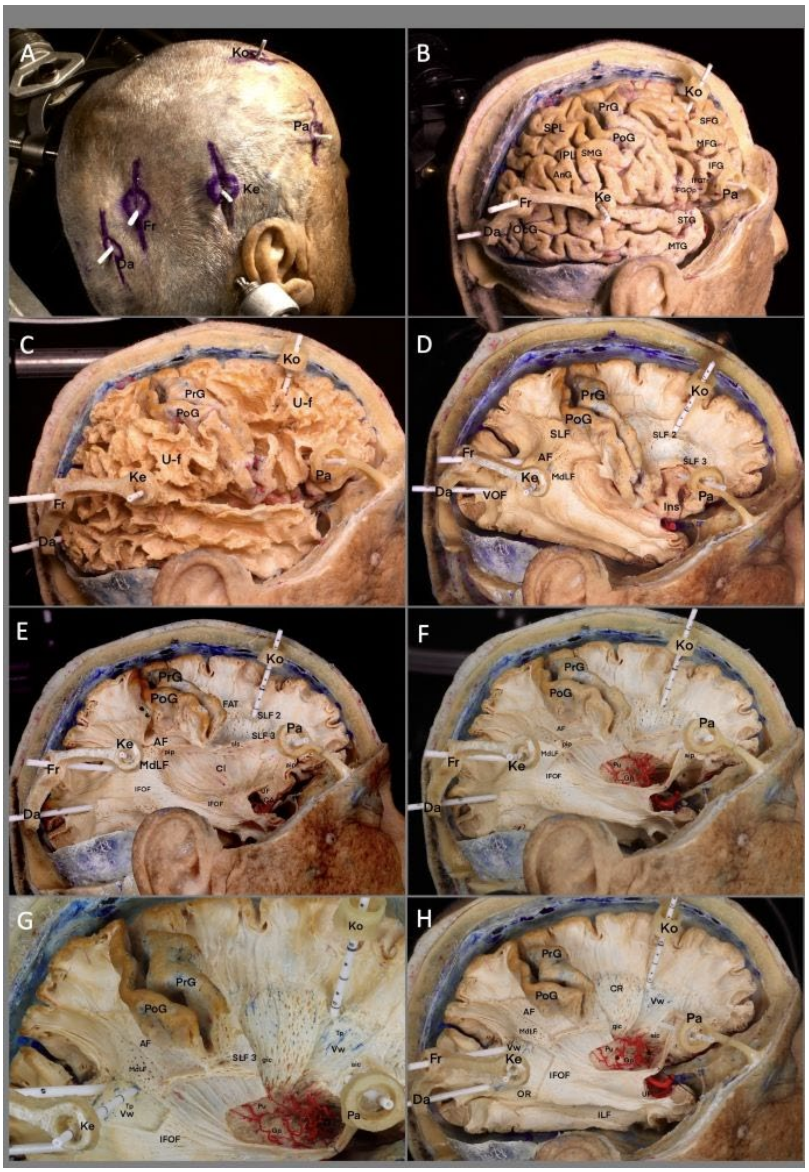

Figure 2.A; Demonstration of the insertion sites of catheters through the skin under 3-pin head fixator (Ko, Kocher; Pa, Paine; Ke, Keen; Fr, Fraizer; Da, Dandy) Figure 2. B; Lateral view of the cerebral cortex after removal of skin, bone, dura, arteries, veins and arachnoids while preserving the catheter access sites (SFG, superior frontal gyrus; MFG, middle frontal gyrus; IFG, inferior frontal gyrus; IFGTr, inferior frontal gyrus triangularis part; IFGOp, inferior frontal gyrus operculum part; STG, superior temporal gyrus; MTG, middle temporal gyrus; SPL, superior parietal lobule; IPL, inferior parietal lobule; OcG, occipital gyrus; AnG, angular gyrus; SMG, supramarginal gyrus; PrG, precentral gyrus; PoG, postcentral gyrus) Figure 2.C; Demonstration of U fibers after decortication of the lateral surface cerebral cortex preserving the presentral gyrus and postcentral gyrus (U-f, U fiber) Figure 2.D; SLF, AF, MdLF, SLF 2, SLF 3, VOF and Ins after removal of U-fibers and decorticated gyrus walls (SLF, superior longitudinal fascicle; AF, arcuate fascicle; Mdlf, middle longitudinal fascicle; SLF 2, superior longitudinal fascicle 2; SLF 3, superior longitudinal fascicle 3; VOF, ventral occipital fascicle; Ins, insula) Figure 2.E; Display of Cl after decortication of Ins, display of FAT with removal of SLF 2, display of combination of AF and MdLF, combination of MdLF

and IFOF, display of UF, display of aip, pip and sls (Cl, clastrum; FAT, frontal lion tract; IFOF, inferior fronto-occipital fascicle; UF, uncinate fasciculus; aip, anterior insular point; pip, posterior insular point; sls, superior limitan sulcus) Figure 2.F; Display of Pu and Gp after removal of clastrum (Pu, putamen; Gp, globus pallidus) Figure 2.G; Appearance of corona radiata fibers after removal of SLF 2 and FAT, appearance of aic, gic after removal of corona radiata fibers, appearance of Tp fibers in the ventricular wall after removal of CR, appearance of Tp fibers on the ventricular atrium after removal of IFOF (CR, corona radiata; Tp , tapetum fibers) Figure 2.H; Appearance of OR fibers extending to the ventricle after removal of IFOF, showing ILF fibers under MTG (OR, optical radiation; ILF, inferior longitudian fascicle)

Figure 3

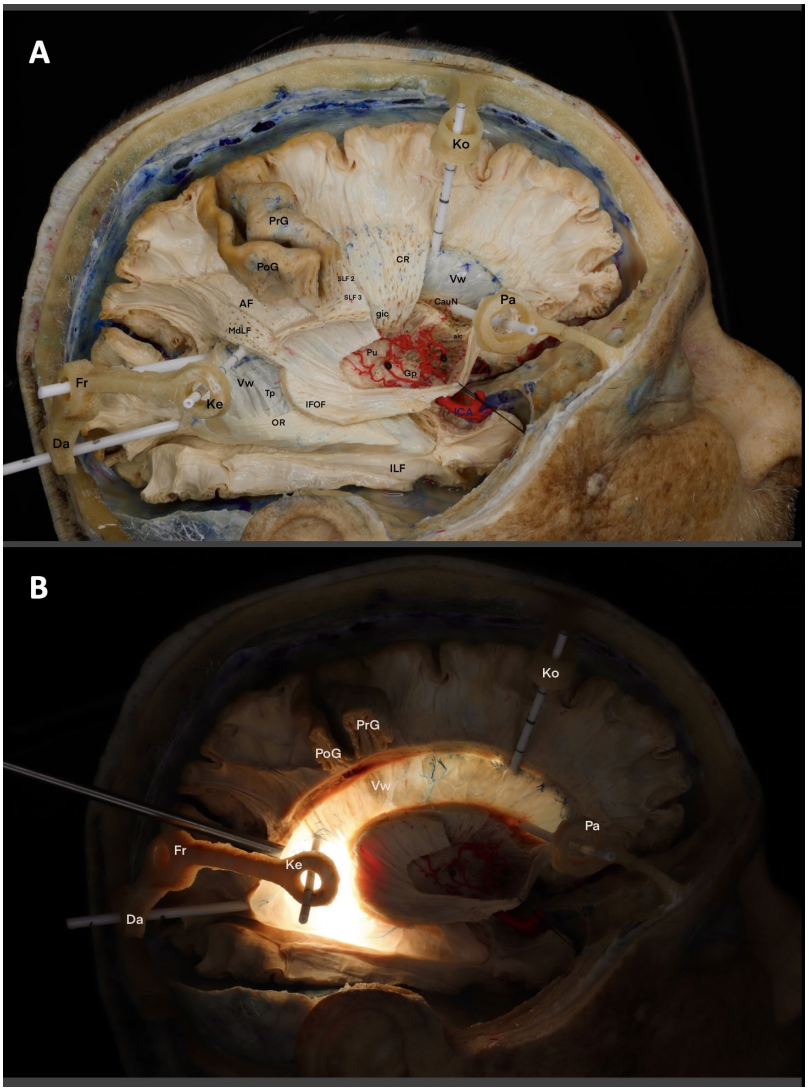

Demonstration of the relationship between the catheters and the ventricle through intraventricular lumination

1

TAP Points	Measures	Hydrocephalus Grades Grade 1 (%30-%40)	Grade 2 (%40-%50)	Grade 3 (>%50)	*p*
	PL	25,74±2,59	23,42±3,06	20,23±2,66	*p<0.001*
KOCHER	CVL	57,53±5,17	61,38±6,66	62,95±6,65	*p<0.05*
	VCI (%)	38	45	52	-
	PL	32,62±3,43	32,18±4,04	30,02±3,38	*p>0.05*
PAINE	CVL	51,99±3,61	54,91±6,67	55,97±5,05	*p<0.05*
	VCI(%)	23	28	33	-
	PL	24,82±3,82	23,94±4,73	21,48±2,70	*p<0.05*
KEEN	CVL	50,28±6,17	55,21±9,90	58,79±11,31	*p<0.05*
	VCI (%)	37	45	52	-
	PL	33,44±5,30	28,93±6,26	26,33±5,30	*p<0.001*
FRAZIER	CVL	76,92±9,40	79,54±7,82	81,84±7,78	*p>0.05*
	VCI (%)	44	51	56	-
	PL	24,43±6,33	22,86±5,90	21,03±3,42	*p>0.05*
DANDY	CVL	60,24±5,47	63,17±12,48	71,23±11,00	*p<0.05*
	VCI (%)	44	49	57	-

Catheter Measurement Values According to Degree of Hydrocephalus and Ventricular Tap Locations in Patients (Ventricle-to-Catheter Percentage: (KVU-PU-Bone Thickness) / KVU x 100 PL: Parenchyma Length, CVL: Cranium-Ventricle Length, VCI: Ventricle-Catheter Index According to Pearson Correlation test; p>0.05: insignificant relationship, p<0.05: significant relationship, p<0.001: strong significant relationship)

Conclusions: The distance to the parenchyma, white matter damage caused by the catheter and its relationship with periventricular fiber structures were taken into consideration. It was concluded that interventions at Kocher and Frazier points may be more reliable, but histologic studies are needed for more optimal results.

Keywords: Cadaver, Fiber dissection, White matter tracts, Ventricular Tap

References

1- Catani M, Dell'Acqua F, Bizzi A, Forkel SJ, Williams SC, Simmons A, et al. Beyond cortical localization in clinico-anatomical correlation. cortex. 2012;48(10):1262-87.
2- Agrawal A, Kapfhammer JP, Kress A, Wichers H, Deep A, Feindel W, et al. Josef Klingler's models of white matter tracts: influences on neuroanatomy, neurosurgery, and neuroimaging. Neurosurgery. 2011;69(2):238-52; discussion 52-4.
3- Erdener T, Albert Jr LR, Margaret B. Microsurgical anatomy and operative approaches to the lateral ventricles. Neurosurgery. 1986;19(5):685-723.
4- Rhoton Jr AL. The lateral and third ventricles. Neurosurgery. 2002;51(suppl_4):S1-207-S1-71.
5- Yasargil MG. CNS Tumors: Surgical Anatomy, Neuropathology, Neuroradiology, Neurophysiology: Clinical Considerations, Operability: Thieme Medical Publishers; 1994.
6- Türe U, Yaşargil MG, Friedman AH, Al-Mefty O. Fiber dissection technique: lateral aspect of the brain. Neurosurgery. 2000;47(2):417-27.
7- Klingler J, Ludwig E. Atlas cerebri humani: Karger Publishers; 1956
8- Yagmurlu K, Vlasak AL, Rhoton AL, Jr. Three-dimensional topographic fiber tract anatomy of the cerebrum. Neurosurgery. 2015;11 Suppl 2:274-305; discussion
9- Morone PJ, Dewan MC, Zuckerman SL, Tubbs RS, Singer RJ. Craniometrics and Ventricular Access: A Review of Kocher's, Kaufman's, Paine's, Menovksy's, Tubbs', Keen's, Frazier's, Dandy's, and Sanchez's Points. Oper Neurosurg (Hagerstown). 2020;18(5):461-9.

OP-II/115

Endoscopic Endovascular Anatomy of the Dorello's Canal (Abducens Nerve Canal) And Its Surgical Implications.

J.Kunicki (1), A.Dąbkowska (3), B.Ciszek (2)
1.Department of Neurosurgery, M.Sklodowska-Curie National Research Institute of Oncology Warsaw , Poland

2. Department of Descriptive and Clinical Anatomy , Warsaw Medical University
3. Department of Forensic Medicine , Warsaw Medical University

The advances in imaging techniques, the surgical and endovascular approaches for pathologies of the petroclival area continue the interest in the anatomy of this complex area. The anatomy of the cavernous sinus (CS) and the Dorello canal (DC) has been extensively described with standard anatomical dissections. Endoscopic techniques attract clinicians and anatomists to visualize complex and hard-to-reach topographical areas.

This study aimed to assess the feasibility and image quality of rigid endovascular endoscopy for anatomical examination of the internal structure of Dorello's canal (DC).

Methods: The fresh specimens consisting of the skull base tissue block (body of sphenoid bone, clivus, and both cavernous sinuses) from 91 cadavers were dissected and examined using the rigid endoscopes (Hopkins II, 2.7 mm diameter) with 0° and 30° optics with physiological like flow of saline solution.

The DC was inspected through 2 ports: the inferior - lumen of the inferior petrosal sinus (IPS) and the superior port, the 3 mm incision in the superior wall of the CS

Results: We successfully explored 169 (92 %) out of 182 examined sides using the inferior port (IPS) and 94 (51.6%) sides using the superior port. The main obstacle for the superior port was lack or hypoplasia of the inferior petrosal sinus 10/182 (5.5 %), and for the superior port: the ectatic course of the cavernous ICA, obliterating passage of endoscope in 41/182 (22.5 %).We distinguished four main course types of the abducens nerve within DC (medial, intermediate, lateral, and low lateral), which pose different surgical implications. The most common type was the lateral type (64%).

Conclusions This new technique for anatomical dissection allows visualization of intact Dorello's canal and CS for anatomic descriptions and more accurately reveals its internal relations. The results hopefully will help in better understanding its surgical anatomy and relevance.

Disclosure of conflict of interest: no conflict of interest

Keywords: Dorello canal, abducens nerve, endoscopy, cavernous sinus

OP-II/116

Analysis of the Superior Hypophyseal Artery Visualization and Preservation and Outcames in Endoscopic Endonasal Surgery For Tuberculum Sellae Meningioma

Jacek Kunicki , Jiyun Hur

Department of Neurosurgery, M.Sklodowska-Curie National Research Institute of Oncology, Warsaw , Poland

Backgrounds : Tuberculum sellae meningioma (TSM) surgery is challenging due to proximity of the optic chiasm and its vessels. An endoscopic endonasal approach (EEA) has been used increasingly for selected TSM as it offers advantages in comparison to craniotomy. The superior hypophyseal arteries (SHA) are the main vessels supplying the optic chiasm; their preservation is essential to prevent postoperative visual worsening.

Objectives : The study's objective was to analyze the relationship between SHA, tumor and critical anatomical structures during EEA and correlate with early surgical results..

Methods : The study is a retrospective analysis of complete data with surgical records and videos of 34 TSM patients (28 women/ 6 men) operated with EEA in our center between 2012-2022. The mean maximal tumor diameter was 18mm (12-35mm). All patients were treated with an extended transplanum/transtuberculum approach to remove their tumors.

Results : The superior hypophyseal arteries were visualized on bothsides in 30/34 cases (88.2%). In case of no bilateral SHA visualization, the tumor was asymmetrical and intact meningeal margins hid one SHA. In 25/34 cases, SHA were covered by preserved arachnoid membranes. The locations of SHA according to tumor circumference were : inferolateral (at the optic nerve level) 41/60, inferior (over the diaphragma sellae) 12/60, and superior (above the optic nerve) 4/60. The tumor encased SHA in 5 cases (14.7%). There were 2 cases of unintentional SHA closure or avulsion from the chiasm, with one visual worsening and the other stable presurgical visual deficit.

Conclusions : The localization and preservation of the SHA during TSM surgery with EEA is necessary for visual improvement. Our results show the actual surgical anatomy of a superior hypophyseal artery from the perspective of extended endonasal appraches for tuberculum selle meningiomas.

Disclosure of conflict of interest: no conflict of interest

Key words: meningioma, endoscopy, hypophyseal artery



3rd International Rhoton Society Meeting

22 - 24 August 2023 - Istanbul

E-POSTERS

P-01

A Method of Posterior Fossa Vertical Dural Opening: Technical Note and Case Series

Neslihan Cavusoglu[1], Gokberk Erol[2], Umut Tan Sevgi[3], Sabino Luzzi[4], Yucel Dogruel[5], Abuzer Gungor[5], Feride Bulgur[1], Barıs Kaval[1]

[1]Department of Neurosurgery, University of Health Sciences, Bakirkoy Research and Training Hospital for Neurology, Neurosurgery and Psychiatry, Istanbul, Turkey
[2]Department of Neurosurgery, Faculty of Medicine, Gazi University, Ankara, Turkey
[3]Department of Neurosurgery, University of Health Sciences, Tepecik Training and Research Hospital, Izmir, Turkey
[4]Neurosurgery Unit, Department of Clinical-Surgical, Diagnostic and Pediatric Sciences, University of Pavia, Italy.
[5]Department of Neurosurgery, Yeditepe University Microsurgical Neuroanatomy Laboratory, Istanbul, Turkey

Objectives: The present technical note describes the Occipital Sinus(OS)-Sparing linear paramedian dural incision, which lead to a decrease in the risk of complications during the median suboccipital approach in our case series.

Background: Durotomies, traditionally used during the midline suboccipital approach, involve sacrificing the occipital sinus(OS) with consequent shrinking of the dura, risk of venous complications, difficulty performing watertight closure, and a higher rate of postoperative CSF(cerebrospinal fluid) leaks.

Method: After the midline suboccipital craniotomy, a linear dural incision is placed 1 cm lateral to the OS. No coagulation is used. The angle of view of the microscope is frequently changed to overcome the slightly narrowed exposure of the linear durotomy. Copious irrigation with saline prevents drying of the dura. A running watertight closure of the dura is used with resorbable Vicryl 4/0 stitches. The overall results of five cases are herein reviewed.

Figure 1: Occipital sinus-sparing linear paramedian dural incision technique.

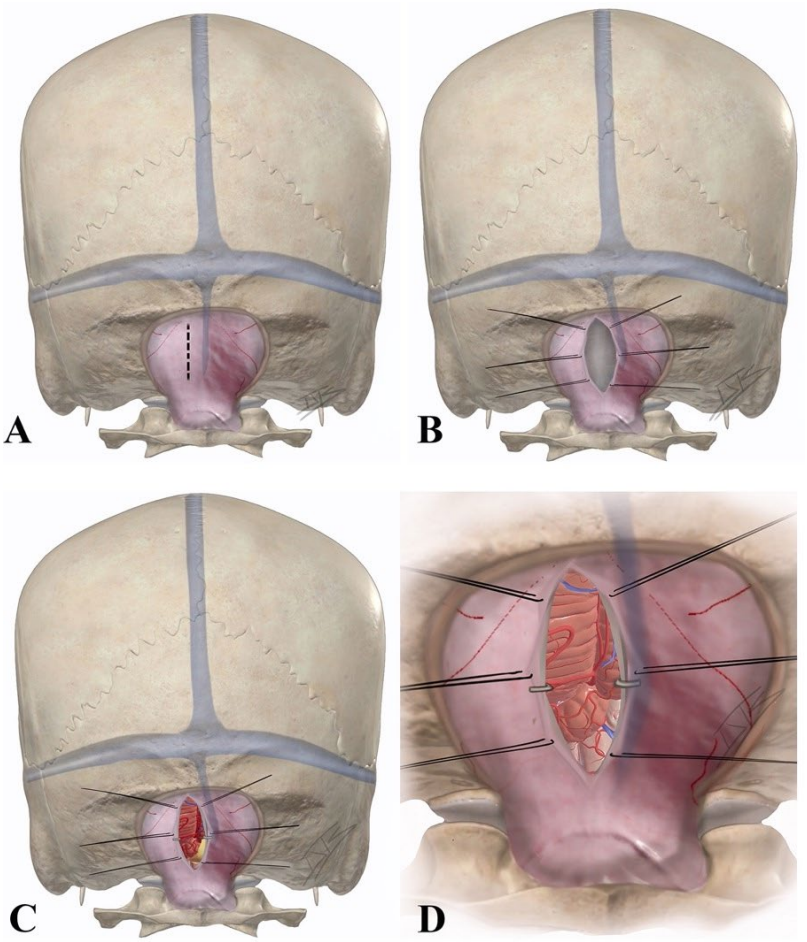

A: paramedian linear dural incision, B: tenting of the dura edges, C: opening of the cisterna magna; D: opening of the arachnoid.

Results: Between 2021-2023, we reviewed the medical records of 5 patients. Three patients were male. Their average age was 43.2 years (range 20-75 years). The cases were three tumors and two cavernomas. The histology of the lesions was as follows: two cavernomas, one midline H3K27 mutant glioma, one choroid plexus papilloma, and one metastasis. The OS was preserved in all five, and no duraplasty was needed. The average dura closure time was 16.8 minutes. No CSF leak occurred, and no wound complications were observed. A gross total resection of the lesion was achieved in all the patients. The mean follow-up was 4.6 months, and there were no late complications related to the dura closure.

Figure 2: Pre- and post-operative MRI images of the treated cases.

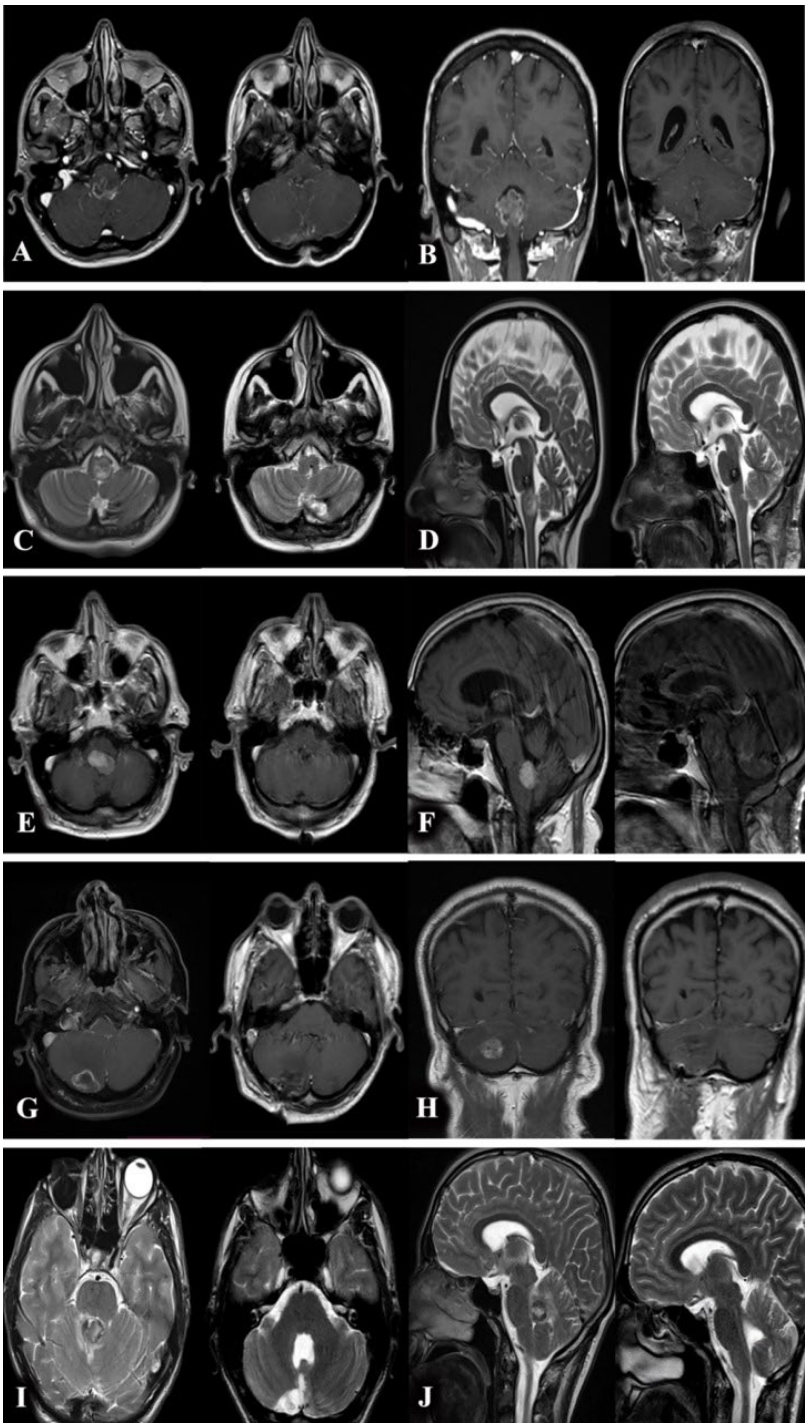

A&B:midline H3K27 mutant glioma of the medulla oblongata. C&D: medulla oblongata cavernoma. E&F: fourth ventricle papilloma. G&H: metastasis of the cerebellar hemisphere. I&J: fourth ventricle cavernoma.

Figure 3: Intraoperative pictures of the fourth ventricle choroid plexus papilloma.

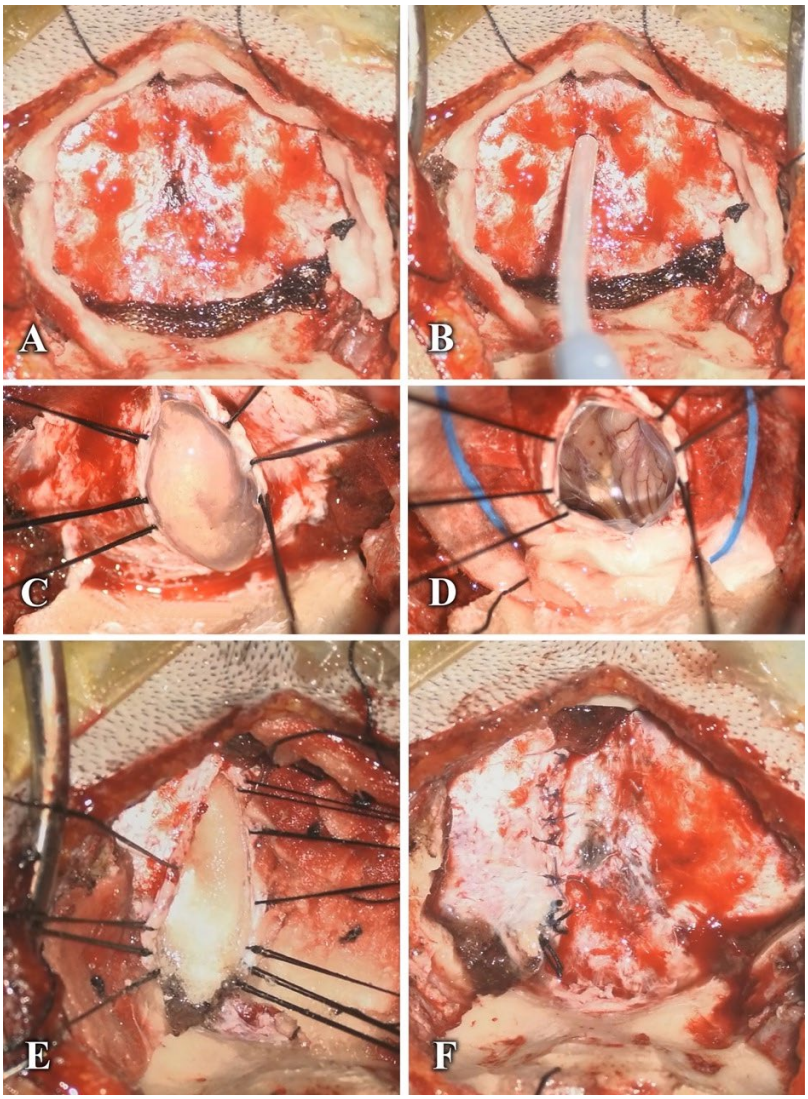

A: exposure of the dura of the suboccipital region. B: ultrasound check of the occipital sinus. C: Occipital sinus-sparing linear paramedian dural incision. D: Opening of the arachnoid of the cisterna magna and release of the CSF. E: Release of the gelatin sponge in the subdural space before closure of the dura. F: running watertight suture.

Conclusions: In comparison to the types of durotomies conventionally used for the midline suboccipital approach, the OS-sparing linear paramedian dural incision entails lower risks of bleeding, venous complications, CSF leaks, and infections by avoiding duraplasty. Validation of this technical note on a larger patient cohort is needed.

Keywords: Occipital Sinus, CSF leak, Suboccipital Approach, Duraplasty

References

1. Rhoton AL. *Rhoton's Cranial Anatomy and Surgical Approaches*: Oxford University Press; 2019.
2. Matsushima T. Midline Suboccipital Approach and Its Variations for Fourth Ventricular or Cerebellar Hemispheric Lesions. In: Matsushima T, ed. *Microsurgical Anatomy and Surgery of the Posterior Cranial Fossa: Surgical Approaches and Procedures Based on Anatomical Study.* Tokyo: Springer Japan; 2015:57-71.
3. Dobrowolski S, Ebner F, Lepski G, Tatagiba M. Foramen magnum meningioma: The midline suboccipital sub tonsillar approach. *Clin Neurol Neurosurg.* 2016;145: 28-34. https://doi.org/10.1016/j.clineuro.2016.02.027.
4. Tatagiba M, Koerbel A, Roser F. The midline suboccipital subtonsillar approach to the hypoglossal canal: surgical anatomy and clinical application. *Acta Neurochir (Wien).* 2006;148(9): 965-969. https://doi.org/10.1007/s00701-006-0816-3.
5. Hollinshead WH. *Anatomy for Surgeons*: Hoeber-Harper; 1954.
6. Dubey A, Sung WS, Shaya M, et al. Complications of posterior cranial fossa surgery--an institutional experience of 500 patients. *Surg Neurol.* 2009;72(4): 369-375. https://doi.org/10.1016/j.surneu.2009.04.001.
7. Kourbeti IS, Vakis AF, Ziakas P, et al. Infections in patients undergoing craniotomy: risk factors associated with post-craniotomy meningitis. *J Neurosurg.* 2015;122(5): 1113-1119. https://doi.org/10.3171/2014.8.Jns132557.
8. Larson AS, Lanzino G, Brinjikji W. Variations of Intracranial Dural Venous Sinus Diameters from Birth to 20 Years of Age: An MRV-Based Study. *AJNR Am J Neuroradiol.* 2020;41(12): 2351-2357. https://doi.org/10.3174/ajnr.A6816.
9. Ayanzen RH, Bird CR, Keller PJ, McCully FJ, Theobald MR, Heiserman JE. Cerebral MR venography: normal anatomy and potential diagnostic pitfalls. *AJNR Am J Neuroradiol.* 2000;21(1): 74-78.
10. Lang J. *Clinical anatomy of the posterior cranial fossa and its foramina*. New York: Thieme; 1991
11. Lang J. *Skull Base and Related Structures: Atlas of Clinical Anatomy*: Schattauer; 2001.
12. D'Costa S, Krishnamurthy A, Nayak SR, et al. Duplication of falx cerebelli, occipital sinus, and internal occipital crest. *Rom J Morphol Embryol.* 2009;50(1): 107-110.
13. Das S, Abd Latiff A, Suhaimi FH, et al. An anatomico-radiological study of the grooves for occipital sinus in the posterior cranial fossa. *Bratisl Lek Listy.* 2008;109(11): 520-524.
14. Kobayashi K, Suzuki M, Ueda F, Matsui O. Anatomical study of the occipital sinus using contrast-enhanced magnetic resonance venography. *Neuroradiology.* 2006;48(6): 373-379. https://doi.org/10.1007/s00234-006-0087-y.
15. Tubbs RS, Ammar K, Liechty P, et al. The marginal sinus. *J Neurosurg.* 2006;104(3): 429-431. https://doi.org/10.3171/jns.2006.104.3.429.
16. Das AC, Hasan M. The occipital sinus. *J Neurosurg.* 1970;33(3): 307-311. https://doi.org/10.3171/jns.1970.33.3.0307.
17. Balak N, Ersoy G, Uslu U, et al. Microsurgical and histomorphometric study of the occipital sinus: quantitative measurements using a novel approach of stereology. *Clin Anat.* 2010;23(4): 386-393. https://doi.org/10.1002/ca.20947.
18. Kalbag RM, Woolf AL. *Cerebral venal thrombosis*. London, New York, Toronto: Oxford University Press; 1967.
19. Tubbs RS, Bosmia AN, Shoja MM, Loukas M, Curé JK, Cohen-Gadol AA. The oblique occipital sinus: a review of anatomy and imaging characteristics. *Surg Radiol Anat.* 2011;33(9): 747-749. https://doi.org/10.1007/s00276-011-0831-9.
20. Tochigi S, Isoshima A, Ohashi H, et al. Preoperative assessment of dominant occipital sinus in patients with Chiari malformation type I: anatomical variations and implications for preventing

potentially life-threatening surgical complications. *Journal of Neurosurgery.* 2023;138(2): 540-549. https://doi.org/10.3171/2022.5.Jns212973.

21. Dora F, Zileli T. Common variations of the lateral and occipital sinuses at the confluens sinuum. *Neuroradiology.*1980;20(1): 23-27. https://doi.org/10.1007/bf00346857.
22. Streeter GL. The development of the venous sinuses of the dura mater in the human embryo. *American Journal of Anatomy.* 1915;18(2): 145-178. https://doi.org/https://doi.org/10.1002/aja.1000180202.
23. Padget DH. The cranial venous system in man in reference to development, adult configuration, and relation to the arteries. *Am J Anat.* 1956;98(3): 307-355. https://doi.org/10.1002/aja.1000980302.
24. Woodhall B. Anatomy of cranial blood sinuses with particular reference to the lateral sinuses. *Laryngoscope.* 1939;49: 966-1010.
25. Yaşargil MG. *Microneurosurgery: In 4 Volumes*: Georg Thieme; 1984.
26. Panigrahi M, Krishnan SS, Varma DR. Crescent posterior fossa durotomy for occipito-marginal venous sinus preservation: a pilot study. *Acta Neurochir (Wien).* 2012;154(11): 2115-2121. https://doi.org/10.1007/s00701-012-1457-3.
27. Graupman P, Defillo A, Nussbaum L, Nussbaum ES. Limited vertical dural opening for lesions of the vermis, 4(th) ventricle, and distal PICA segments. *Surg Neurol Int.* 2012;3: 141. https://doi.org/10.4103/2152-7806.103881.
28. Shin HS, Choi DS, Baek HJ, et al. The oblique occipital sinus: anatomical study using bone subtraction 3D CT venography. *Surg Radiol Anat.* 2017;39(6): 619-6 https://doi.org/10.1007/s00276-016-1767-x.
29. Fukusumi A, Okudera T, Takahashi S, et al. Anatomical evaluation of the dural sinuses in the region of the torcular herophili using three dimensional CT venography. *Acad Radiol.* 2010;17(9): 1103-1111. https://doi.org/10.1016/j.acra.2010.04.020.
30. Seo H, Choi DS, Shin HS, Cho JM, Koh EH, Son S. Bone subtraction 3D CT venography for the evaluation of cerebral veins and venous sinuses: imaging techniques, normal variations, and pathologic findings. *AJR Am J Roentgenol.*2014;202(2): W169-175. https://doi.org/10.2214/ajr.13.10985.
31. Chotai S, Medhkour A. Surgical outcomes after posterior fossa decompression with and without duraplasty in Chiari malformation-I. *Clin Neurol Neurosurg.* 2014;125: 182-188. https://doi.org/10.1016/j.clineuro.2014.07.027.
32. Moskowitz SI, Liu J, Krishnaney AA. Postoperative complications associated with dural substitutes in suboccipital craniotomies. *Neurosurgery.* 2009;64(3 Suppl): ons28-33; discussion ons33-24. https://doi.org/10.1227/01.Neu.0000334414.79963.59.

P-03

Role of Intraoperative Ultrasound in Surgery of Pediatric Posterior Fossa Tumors

Mohamed Mohsen Amen[1], Mohamed Hashem[1], Ashraf Abd El - Moneim Ezz -Eldeen[1]

[1]Mansoura university, Neurosurgery department

Objectives: We try to highlight the important effect of Intraoperative Ultrasound application in pediatric brain tumor surgery especially posterior fossa tumors and report how this device can affect the volume of tumor excision ,safety of the patient and time of surgery in such critical anatomical and pathological lesions.

Background: Maximal safe resection represents the gold standard for surgery of posterior fossa tumors. In recent years, new methods, such as the IOMR have become relevant in neuro-oncological surgery, allowing for more radical and safer tumor resection. But they are expensive and not available in every neurosurgical center. Therefore, in the last few years, great attention has been paid to the possible intraoperative use of ultrasound (IOUS) guidance for brain tumor surgery

Method: A prospective descriptive study was conducted in Mansoura University Hospitals, Department of Neurosurgery for 1 year. Our study included 30 child patients who underwent surgical excision of posterior fossa tumor using Intraoperative ultrasound (IOUS) guidance.

Figure 3: pre-excision ultrasound image, axial view showing a) both cerebellar hemispheres, b) hyperechoic mass, c) 4th ventricle.

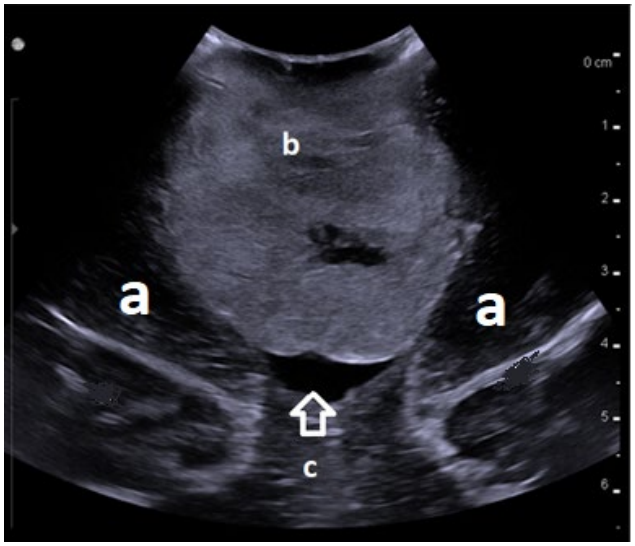

Results: A total of 30 patients met the inclusion criteria during the specified study period, including 13 males and 17 females. The mean age of the study patients was 7.67 years (range 1 months to 17 years). In our study, we achieved total resection among studied cases in 22(73.33 %) cases, near-total resection was achieved in 3 (10 %) cases, subtotal resection was in 4 cases (13.3) and partial resection was in one case (3.33%).

: post-excision ultrasound image, axial view, showing a) a hypoechoic cavity filled with normal saline after tumor excision.

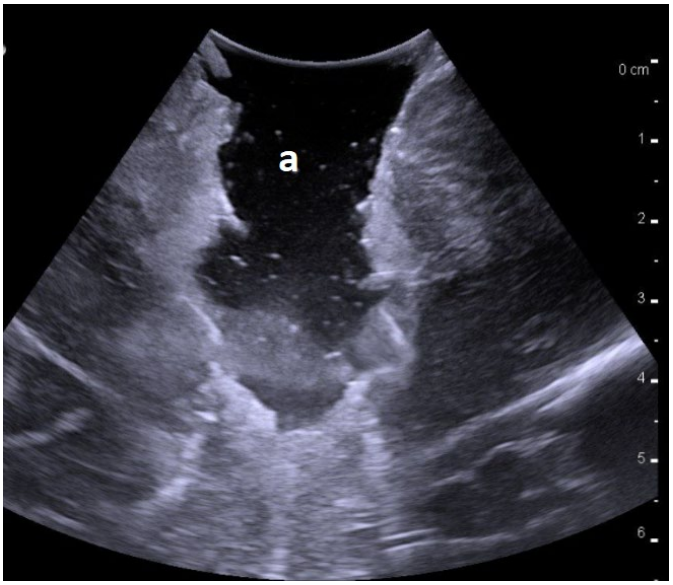

post-operative MRI brain with contrast, axial cuts, showing signs of craniectomy and no residual detected

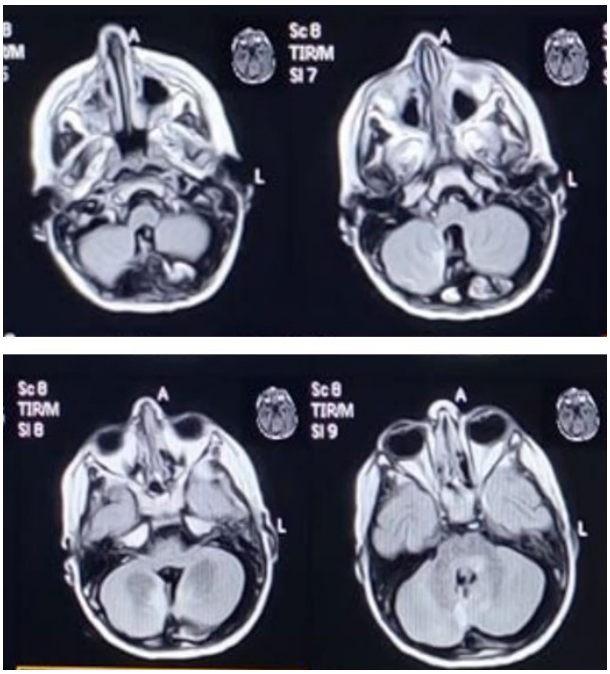

Conclusions: Intraoperative ultrasound was found in our study to be of excellent value in resection of posterior fossa lesions with more accurate localization of the lesion, detection of lesion borders, character of the tumor, and differentiation of solid parts from cystic parts of the lesion. The rate of intraoperative and postoperative morbidities and mortalities was much more decreased after introduction of ultrasound in the operating room .

Keywords: Intraoperative Ultrasound – Pediatric - Posterior fossa tumors -Residual, Intraoperative Ultrasound – Pediatric - Posterior fossa tumors, Intraoperative -Ultrasound – Pediatric - Posterior fossa

References

1. Rickert CH, Paulus W. Epidemiology of central nervous system tumors in childhood and adolescence based on the new WHO classification. Childs Nerv Syst. 2001;17(9):503–11.
2. Prasad, Kadali Satya Vara, et al. "Clinicopathological study of pediatric posterior fossa tumors." Journal of pediatric neurosciences 12.3 (2017): 245.
3. Di Rocco, Concezio, Dachling Pang, and James T. Rutka, eds. Textbook of Pediatric Neurosurgery. Springer International Publishing, 2020.
4. Chen D, Wei X, Yin Q, Guan J, Pan W, Wang C, Liu Y (2009) The microscopic surgical treatment for tumor of posterior cranial fossa in children. Clin Oncol Cancer Res 6:95–99
5. Pino, Maria Angela, et al. "New hope in brain glioma surgery: the role of intraoperative ultrasound. A review." Brain Sciences 8.11 (2018): 202.
6. Gerard, Ian J., et al. "Brain shift in neuronavigation of brain tumors: a review." Medical image analysis 35 (2017): 403-420.
7. Maugeri, Rosario, et al. "With a little help from my friends: The role of intraoperative fluorescent dyes in the surgical management of high-grade gliomas." Brain sciences 8.2 (2018): 31.
8. Bajwa, Mohammad Hamza, Saqib Kamran Bakhshi, and Muhammad Shahzad Shamim. "Role of intra-operative ultrasound in brain tumour surgeries." *JPMA. The Journal of the Pakistan Medical Association* 71.5 (2021): 1508.
9. Hammoud, Maarouf A., et al. "Use of intraoperative ultrasound for localizing tumors and determining the extent of resection: a comparative study with magnetic resonance imaging." Journal of neurosurgery 84.5 (1996): 737-741.
10. Smith, Heather, et al. "Correlation between intraoperative ultrasound and postoperative MRI in pediatric tumor surgery." Journal of Neurosurgery: Pediatrics 18.5 (2016): 578-584.
11. Prakash, Tiwari Divye, Patil Deepak, and Sharma Vivek. "Intraoperative Ultrasound in Intracranial Space Occupying Lesions." World Journal of Surgical Medical and Radiation Oncology 2.11 (2013).
12. Šteňo, Andrej, et al. "Current limitations of intraoperative ultrasound in brain tumor surgery." Frontiers in Oncology (2021): 851.
13. Erdoğan, N., et al. "Ultrasound guidance in intracranial tumor resection: correlation with postoperative magnetic resonance findings." Acta Radiologica 46.7 (2005): 743-749.
14. Wang, J., et al. "The relationship between intra-operative ultrasonography and pathological grade in cerebral glioma." Journal of International Medical Research 36.6 (2008): 1426-1434.
15. Nagaty, Ahmed, Ahmad Elsabaa, and Hisham Anwer. "Efficacy of Intraoperative Ultrasound in Resection of Posterior Fossa Lesions." Int. J. Neurosurg 3 (2019): 13-20.

P-05

The Party Wall: Redefining the Indications of Transcranial Approaches for Giant Pituitary Adenomas in Endoscopic Era

Sabino Luzzi[1], Alice Giotta Lucifero[1], Jessica Rabski[2], Paulo Kadri[3], Ossama Al-Mefty[2]

[1]Department of Clinical-Surgical, Diagnostic and Pediatric Sciences, University of Pavia, Pavia, Italy
[2]Brigham and Women's Hospital, Harvard Medical School, Boston, Massachusetts, USA
[3]Medical School, Federal University of Mato Grosso do Sul, Campo Grande, Mato Grosso do Sul, Brazil

Objectives: To redefine the current indications for the transcranial approaches for giant pituitary adenomas in the endoscopic era.

Background: The evolution of endoscopic transsphenoidal surgery raises the question of the role of transcranial surgery for pituitary tumors, particularly with the effectiveness of adjunct irradiation.

Method: A critical appraisal of the personal series of the senior author (O.A.) was performed to characterize the patient factors and the tumor's pathological anatomy features that endorse a cranial approach.

Results: Traditional indications for transcranial approach include absent pneumatization of the sphenoid sinus, kissing/ectatic internal carotid arteries, reduced dimensions of the sella, lateral invasion to the cavernous sinus lateral to the carotid artery, dumbbell-shaped tumors caused by severe diaphragm constriction, fibrous/calcified tumor consistency, wide supra, para-, and retro-sellar extension, arterial encasement, brain invasion, coexisting cerebral aneurysms, and coexisting separate pathologies of the sphenoid sinus, especially infections. Residual/recurrent tumors and postoperative pituitary apoplexy after transsphenoidal surgery require individualized considerations.

Conclusions: Transcranial approaches still have a critical role in giant and complex pituitary adenomas with wide intracranial extension, brain parenchymal involvement, and encasement of the neurovascular structures.

Keywords: Cavernous sinus, Parasellar tumors, Pituitary adenoma, Transsphenoidal approach

References

1. Luzzi S, Giotta Lucifero A, Rabski J, Kadri PAS, Al-Mefty O. The Party Wall: Redefining the Indications of Transcranial Approaches for Giant Pituitary Adenomas in Endoscopic Era. Cancers (Basel). 2023 Apr 10;15(8):2235. doi: 10.3390/cancers15082235.

P-06

Management of Sigmoid and Transverse Sinus Injury: A Case Report

Erkin Özgiray[1], Nevhis Akıntürk[1], Erhan Şimşek[1], Mirnaim Kıyan[1], Özgün Anadolu[2]

[1]Ege University, Department of Neurosurgery
[2]Ege University, Department of Anesthesiology

Objectives: 1. Sinus injury can range from minor to major lacerations and the risk of blood loss and air embolism could be lethal.2. Follow-up is crucial to prevent long-term complications.

Background: The sinus laceration is a disastrous complication in craniotomies involving venous sinuses. Blood loss and venous air embolism can lead to mortality and morbidity. Therefore, achieving hemostasis and repairing the sinus is crucial. In this study, we will present a case of retrosigmoid craniotomy that was complicated by transverse and sigmoid sinus lacerations.

Method: A 46 years-old female with trigeminal neuralgia, that is resistant to drugs and radiofrequency ablation therapy. Microvascular decompression of the left trigeminal nerve with a retrosigmoid approach in a prone position was performed.

Results: The transverse sinus was injured after placing the first burr hole to the inferomedial of the asterion, but hemostasis was obtained with gel foam and cottonoids. Later while turning the craniotomy, there was abundant bleeding from the sigmoid sinus. Bone wax was applied with gel foam and large cottonoids, followed by the elevation of the head of the bed. The bleeding slowed down, and there was no sign of air embolus so the craniotomy could be completed. Although the sigmoid sinus could not be sutured, hemostasis was obtained using Hemopatch and gel foam. Ultrasonic Doppler was used to confirm the flow of the sinus. The operation proceeded without any other significant complications and the patient was discharged without any neurological deficits.

Conclusions: Sinus injury can range from minor to major lacerations and should be taken seriously since the risk of blood loss and air embolism could be lethal. Proper follow-up is crucial to prevent long-term complications such as sinus thrombosis and dural arteriovenous malformations.

Keywords: sinus laceration, air embolism, craniotomy, blood loss

References

1. Matsushima K, Kohno M, Tanaka Y, Nakajima N, Ichimasu N. Management of Sigmoid Sinus Injury: Retrospective Study of 450 Consecutive Surgeries in the Cerebellopontine Angle and Intrapetrous Region. Oper Neurosurg (Hagerstown). 2020 Nov 16;19(6):721-729. doi: 10.1093/ons/opaa225. PMID: 32687573.

P-07

The Pre-Pontine and Tentorial Block and Their Relevance in Development and Treatment of Hydrocephalus

Carla Richetta[1], Shelly Shiran[1], Shlomi Constantini[1], Jonathan Roth[1]

[1]Tel Aviv Medical Center

Objectives: The objective of the study is to describe the anatomical and clinical importance of a prepontine CSF block.

Background: Classic CSF flow patterns describe flow through the ventricles to the subarachnoid space and cisterns. Anatomical studies of the ambient and crural cisterns have highlighted the presence of arachnoid membranes separating the infratentorial from the supratentorial spaces, making the prepontine subarachnoid space the main CSF outlet for bulky flow, from the fourth ventricle to the supratentorial subarachnoid space. An obstruction at the prepontine space may cause an obstructive hydrocephalus pattern with specific radiological characteristics. We describe a short cases series of patients with hydrocephalus secondary to a pre-pontine block and their anatomical characteristics.

Method: We retrospectively collected data of four patients who were diagnosed with hydrocephalus secondary to a prepontine block between August 2021 and June 2023.

Results: Four patients were included. Two children presented with hydrocephalus on imaging without any other underlying pathology and one child had a suprasellar cyst too. One adult patient was incidentally diagnosed. All cases had an open aqueduct on T2 sagittal sequences and all presented with an infra-cerebellar CSF collection. In all pre-operative images, there was a suspected membrane in the prepontine region. In the three operated cases, a thick membrane obstructing the prepontine cistern was observed during surgery. Two patients improved following an ETV, and one underwent a ventriculoperitoneal shunt.

Conclusions: We highlight the anatomical-physiological of a prepontine CSF block as a potential cause of obstructive hydrocephalus. We believe this anatomical nuance adds to better understanding of CSF pathways, and the role of ETV treating hydrocephalus in a small subgroup of patients without a clear obstruction.

Keywords: prepontine block, tentorial block, hydrocephalus, endoscopic third ventriculostomy

References

1. Al-Hakim S, Schaumann A, Tietze A, Schulz M, Thomale UW. Endoscopic third ventriculostomy in children with third ventricular pressure gradient and open ventricular outlets on MRI. Childs Nerv Syst. 2019 Dec;35(12):2319-2326. doi: 10.1007/s00381-019-04383-x. Epub 2019 Oct 25. PMID: 31654263. 2: Zhang XA, Qi ST, Fan J, Huang GL, Peng JX. Arachnoid membranes in the posterior half of the incisural space: an inverted Liliequist membrane-like arachnoid complex. J Neurosurg. 2014 Aug;121(2):390-6. doi: 10.3171/2014.3.JNS132206. Epub 2014 May
2. PMID: 24785320. 3: Qi ST, Fan J, Zhang XA, Pan J. Reinvestigation of the ambient cistern and its related arachnoid membranes: an anatomical study. J Neurosurg. 2011 Jul;115(1):171-8. doi: 10.3171/2011.2.JNS101365. Epub 2011 Mar 11. PMID: 21395390.

P-08

Posterior Fossa Arteriovenous Malformations: Determining the Path to Travel

Waseem Ahamed TP[1], Kamlesh Bhaisora[1], Abhishek Kumar[1]

[1]Sanjay Gandhi Postgraduate Institute, Lucknow

Objectives: Analyse data of our patients with Posterior Fossa Arteriovenous Malformations(AVM). Define the Management and need for supplementary classification for Posterior Fossa AVMs with special emphasis on Cerebellar AVMs

Background: Posterior fossa AVMs (pfavm) account for 7-15% of all intracranial AVMs, They rupture much more frequently than supratentorial AVMs. They are classified anatomically as involving cerebellum (hemispheres and vermis) and brainstem (midbrain, pons, medulla).

Method: Retrospective analysis of 29 patients admitted with pfAVM from June 2010 to June 2022. Clinical profile, radiological data & the lines of management modalities are analysed .AVMs are classified according to the Spetzler-Martin Scale and shortcomings noted. AVMs are considered eloquent if they are seen involving the deep cerebellar nuclei, the brainstem or the cerebellar peduncles. Venous drainage was defined as deep, when at least one vein drained into the deep venous system. Outcome was assessed using The Modified Rankin Scale (mRS).

Results: The mean age of our 29 patients was 34 years (range from 7 to 64 years). Feeders were seen to arise from SCA in 20, PICA in 12, AICA in 10, PCA in 3 and vertebral artery in 1patients, the AVMs were seen draining to transverse sinus in 16, straight sinus in 11, sigmoid sinus in 4, superior petrosal sinus in 2 and internal cerebral vein/vein of Galen in 1 patient. AVM Location with Spetzler-Martin Grade, presence of Associated aneurysm, Management and outcome were also studied. Mean follow-up was 5.4 years and mRS was used to assess patients.

Conclusions: pfAVMs deserve multimodality intervention in most cases because of their higher risk of rupture and higher potential for morbidity. Study sheds light on the characteristics of pfAVMs and help in management and surgical planning. Key components of the Spetzler-Martin system- venous drainage and eloquence, are distorted by cerebellar anatomy warranting need for additional classification.

Keywords: Posterior fossa, Arteriovenous malformations, Cerebellum, Brain Stem.

References

1. R. Al-Shahi, C. Warlow, A systematic review of the frequency and prognosis of arteriovenous malformations of the brain in adults, Brain. 124 (2001) 1900–1926. https://doi.org/10.1093/brain/124.10.1900.
2. L. da Costa, L. Thines, A.R. Dehdashti, M.C. Wallace, R.A. Willinsky, M. Tymianski, M.L. Schwartz, K.G. t. Brugge, Management and clinical outcome of posterior fossa arteriovenous malformations: report on a single-centre 15-year

experience, J Neurol Neurosurg Psychiatry. 80 (2008) 376–379. https://doi.org/10.1136/jnnp.2008.152710.
3. O.M. Arnaout, B.A. Gross, C.S. Eddleman, B.R. Bendok, C.C. Getch, H.H. Batjer, Posterior fossa arteriovenous malformations, Neurosurg Focus. 26 (2009) E12. https://doi.org/10.3171/2009.2.FOCUS0914.
4. R.D. Brown, K.D. Flemming, F.B. Meyer, H.J. Cloft, B.E. Pollock, M.J. Link, Natural History, Evaluation, and Management of Intracranial Vascular Malformations, Mayo Clin Proc. 80 (2005) 269–281. https://doi.org/https://doi.org/10.4065/80.2.269.
5. R.G. Monaco, H. Alvarez, A. Goulao, Ph. Pruvost, P. Lasjaunias, Posterior fossa arteriovenous malformations, Neuroradiology. 31 (1990) 471–475. https://doi.org/10.1007/BF00340124.
6. J. Piao, T. Luan, Y. Wang, J. Yu, Imaging characteristics and endovascular treatment strategy for cerebellar arteriovenous malformations, Medicine International. 1 (2021) 5. https://doi.org/10.3892/mi.2021.6.
7. L. SYMON, L. TACCONI, N. MENDOZA, P. NAKAJI, Arteriovenous malformations of the posterior fossa: a report on 28 cases and review of the literature, Br J Neurosurg. 9 (1995) 721–732. https://doi.org/10.1080/02688699550040675.
8. R.F. Spetzler, N.A. Martin, A proposed grading system for arteriovenous malformations, J Neurosurg. 65 (1986) 476–483. https://doi.org/10.3171/jns.1986.65.4.0476.
9. R.G. Monaco, H. Alvarez, A. Goulao, Ph. Pruvost, P. Lasjaunias, Posterior fossa arteriovenous malformations, Neuroradiology. 31 (1990) 471–475. https://doi.org/10.1007/BF00340124.
10. J. Choque-Velasquez, R. Colasanti, S. Muhammad, F. Chioffi, J. Hernesniemi, Vascular Lesions of the Pineal Region: A Comprehensive Review of the Therapeutic Options, World Neurosurg. 159 (2022) 298–313. https://doi.org/10.1016/j.wneu.2021.09.061.
11. M.E. Kelly, R. Guzman, J. Sinclair, T.E. Bell-Stephens, R. Bower, S. Hamilton, M.P. Marks, H.M. Do, S.D. Chang, J.R. Adler, R.P. Levy, G.K. Steinberg, Multimodality treatment of posterior fossa arteriovenous malformations, J Neurosurg. 108 (2008) 1152–1161. https://doi.org/10.3171/JNS/2008/108/6/1152.
12. K. Maruyama, T. Koga, A. Niranjan, D. Kondziolka, J.C. Flickinger, L.D. Lunsford, Radiosurgery for Brainstem Arteriovenous Malformation, in: 2013: pp. 67–72. https://doi.org/10.1159/000341639.
13. P.L. Nisson, S.A. Fard, C.M. Walter, C.M. Johnstone, M.A. Mooney, A. Tayebi Meybodi, M. Lang, H. Kim, H. Jahnke, D.J. Roe, T.M. Dumont, G.M. Lemole, R.F. Spetzler, M.T. Lawton, A novel proposed grading system for cerebellar arteriovenous malformations, J Neurosurg. 132 (2020) 1105–1115. https://doi.org/10.3171/2018.12.JNS181677.
14. A.A. Abla, J. Nelson, W.C. Rutledge, W.L. Young, H. Kim, M.T. Lawton, The natural history of AVM hemorrhage in the posterior fossa: comparison of hematoma volumes and neurological outcomes in patients with ruptured infra- and supratentorial AVMs, Neurosurg Focus. 37 (2014) E6. https://doi.org/10.3171/2014.7.FOCUS14211.
15. H.J. Meisel, U. Mansmann, H. Alvarez, G. Rodesch, M. Brock, P. Lasjaunias, Cerebral Arteriovenous Malformations and Associated Aneurysms: Analysis of 305 Cases from a Series of 662 Patients, Neurosurgery. 46 (2000) 793–802. https://doi.org/10.1097/00006123-200004000-00004.

P-09

Total resection of the tumor with a two-stage interhemispheric contralateral transcallosal horizontal approach in bilaterally extending lateral ventricular tumor

Bilal YEKELER[1], Murat ÇİFTÇİ[2]

[1]Bayburt State Hospital, Bayburt, TR
[2]Kayseri City Education and Research Hospital, Kayseri, TR

Objectives: To demonstrate the usefulness of the contralateral transcallosal horizontal approach for resecting lesions located bilaterally in or adjacent to the lateral ventricle. To compare treatment methods with alternative approaches.

Background: Modifications to the standard ipsilateral transcallosal technique, include positioning the head, with the midline oriented, horizontally, placing the lesion side up, and performing the craniotomy and interhemispheric dissection on the contralateral side. This approach avoids a transcortical incision, allows gravity to provide an open interhemispheric fissure, and enhances the lateral exposure toward the lesion.

Comparison of the contralateral and ipsilateral transcallosal approach

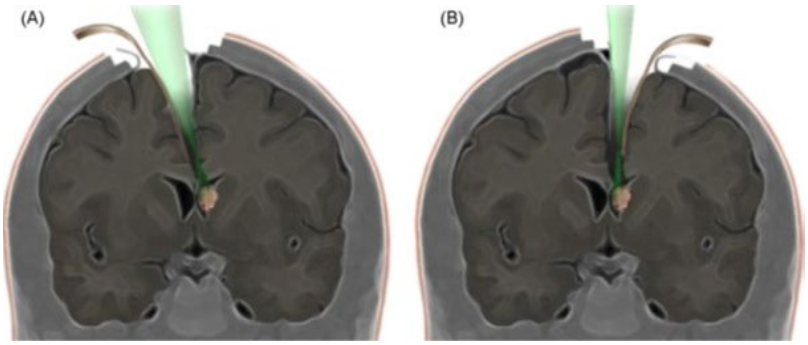

The contralateral approach (A) provides a more favorable angle to the lateral edge of the lesion than the ipsilateral approach (B). The medial part of the lesion can be seen adequately with either approach.

Method: 16-year-old girl who was operated for postreior fossa ependymoma 6 years ago, came to our clinic with increasing headache, gait and visual disturbance. İn the lateral ventricles, bilaterally located and diffuse contrast enhancing lesion was detected. Patient was operated in two stages via the contralateral horizontal interhemispheric approach to the lateral ventricles. Total tumor resection was successfully achieved without any neurological compromise.

Intraoperative images of the contralateral transcallosal approach with the head in the horizontal position

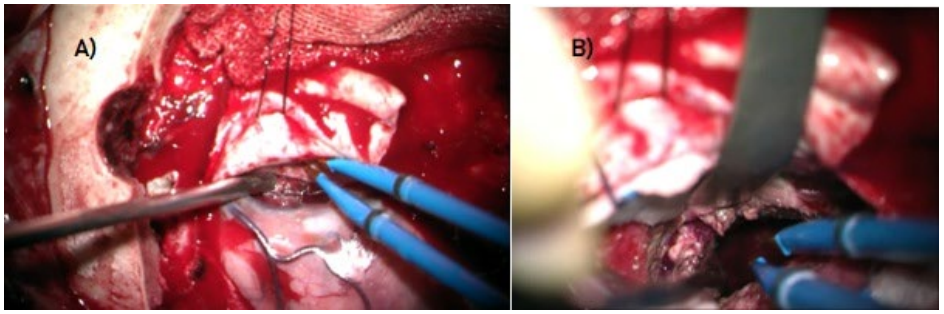

(A) The ipsilateral hemisphere fell down with the help of gravity and the interhemispheric corridor was opened. Contralateral tumor is seen. (B) The ipsilateral tumor was resected and the falx was retracted with the help of a retractor. The lateral part of the contralateral tumor is seen.

Results: Postoperative MRI confirmed that the tumor was completely resected bilaterally without any morbidity.

Preoperative and Postoperative MRI Findings

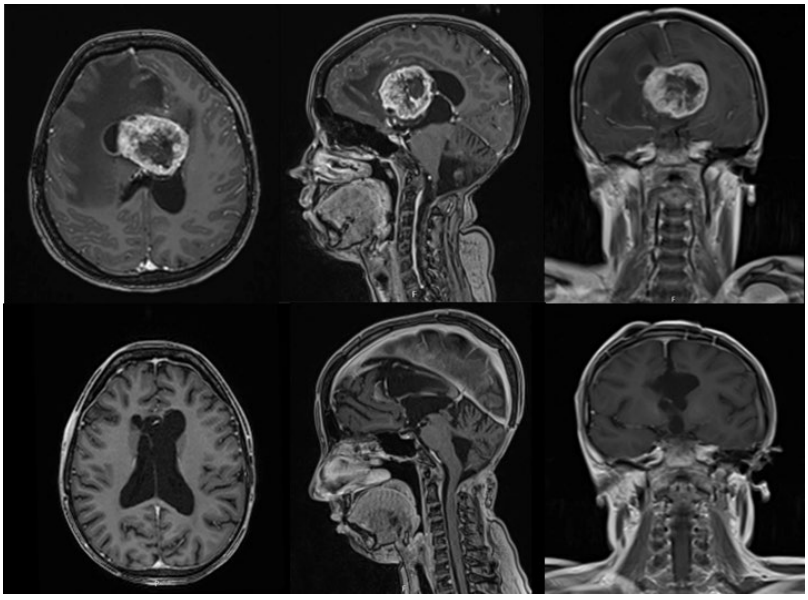

Total resection of bilateral lateral intraventricular tumor with the head in a horizontal position with a two-stage contralateral transcallosal approach

Conclusions: Bilateral contralateral transcallosal horizontal approach can be utilized for resection of bilateral frontal horn and genu of the lateral ventricle tumors that laterally extended safely and successfully.

Keywords: contralateral transcallosal approach, lateral ventricle tumors, ventricular surgery, brain tumor surgery

References

1. Cikla U, Swanson KI, Tumturk A, et al. Microsurgical resection of tumors of the lateral and third ventricles: operative corridors for difficult-to-reach lesions. *J Neurooncol*. 2016;130(2):331-340. doi:10.1007/s11060-016-2126-9
2. Yaşargil MG, Abdulrauf SI. SURGERY OF INTRAVENTRICULAR TUMORS. *Neurosurgery*. 2008;62(6):SHC1029-SHC1041. doi:10.1227/01.NEU.0000316427.57165.01
3. Lawton MT, Golfinos JG, Spetzler RF. The Contralateral Transcallosal Approach: Experience with 32 Patients. *Neurosurgery*. 1996;39(4):729-734. doi:10.1097/00006123-199610000-00016
4. Anderson RCE, Ghatan S, Feldstein NA. Surgical approaches to tumors of the lateral ventricle. *Neurosurg Clin N Am*. 2003;14(4):509-525. doi:10.1016/S1042-3680(03)00054-8

P-11

Composite Approach for Foramen Magnum Meningioma: Clinical Case

Rauan Aiteli[1]

[1]Asfendiyarov Kazakh Nathional Medical University

Objectives: This case illustrates issues surrounding a far-lateral approach for the resection of a foramen magnum meningioma.

Background: The management of foramen magnum meningiomas has been revolutionized by the techniques of cranial base surgery. However, these tumors are still among the most difficult cranial base lesions to treat. The particular challenge of the treatment of these tumors lies in the close proximity and involvement of highly sensible neurovascular structures such as the lower brainstem, the lower cranial nerves, the V3 and V4 segments of the vertebral arteries.

Method: We present a case of a foramen magnum meningioma that highlights the importance of the pre-planning of the method of surgical treatment the Neurosurgery Department of KazNMU with Neurosurgical Center at the City Clinical Hospital 7 Almaty (Kazakhstan). A 36 -year-old woman presented with an 8-month history of progressive headache,unsteadiness when walking. The patient underwent neurosurgical operated of the patient on the stomach position by use of a suboccipital approach with a midline incision and extension of the craniectomy laterally toward the side of the tumor and resection C1 vertebral arch with exposure of the vertebral artery. A wide matrix at the edge of the descended along the anterolateral surface the C1 vertebra. Achieved good decompression of the trunk.

Results: The results show that the tumor node was located to the right and in front of the brain stem, strongly squeezing and extremely solid. With technical difficulties in stages, with the help of an ultrasonic disintegrator, this node was partially removed. Very close fusion with the lateral surface of the trunk did not allow to separate and remove the tumor completely.

Conclusions: The lateral suboccipital approach, with or without laminectomy of C1 vertebra, is most frequently used as it offers access to the majority of these lesions. Occasionally, mechanical instability might ensue and thus render osteosynthesis necessary.

Keywords: Lateral approaches, meningioma foramen magnum, vertebral artery

P-13

Tailoring Fenestrated Aneurysm Clips Intraoperatively: Instant Solution for a Difficult Problem

Hanside Setenay Unal[1], Oguz Altunyuva[1], Ismail Seckin Kaya[1], Yagmur Tuncbilekli[1], Pinar Eser[1], Hasan Kocaeli[1], Hülya Bilgin[2]

[1]Uludag University School of Medicine Department of Neurosurgery
[2]Uludag University School of Medicine Department of Anesthesiology and Reanimation

Objectives: We aimed to underline the effectiveness of intraoperative clip modification (ClipMod) for anatomically challenging anterior communicating artery (ACoA) aneurysms.

Background: The ACoA complex is the most common site of ruptured intracranial aneurysms which are also the most complex aneurysms of the anterior circulation. Despite the advancing technology in aneurysm clips, at times, it is still hard to securely clip the ACoA complex aneurysms given their small sizes, adherence to adjacent neurovascular structures, thin walls, challenging projection angles that make dissection harder, and atypical fenestrations (1). Even so, particular cases may require imaginative solutions such as intraoperative ClipMod for safe clipping (2).

Method: We retrospectively analyzed clinical records of two patients who required ClipMod intraoperatively and presented them as video cases.

Results: Case #1 underwent microsurgical clipping of a ruptured, 4-mm AcoA aneurysm. Unfortunately, given the short distance between the two A2s, it was not possible to clip the aneurysm without a compromise to the contralateral A2 with the available shortest 3-mm fenestrated clip. We then used the clip modification technique intraoperatively by shortening the clip tips with mesh-plaque cutter and smoothening the remaining sharp ends using cautery sanding. Eventually, the aneurysm was clipped successfully with the modified-fenestrated clip. Post-clipping imagings confirmed complete occlusion of the aneurysm and patency of parent arteries. Case 2# underwent microsurgical clipping for a ruptured, 1-mm AcoA aneurysm. Like Case 1#, the initial clipping attempt with the available shortest 4-mm fenestrated clip failed given the excessive length of the tips. The patient, thus, required clip modification as described above. The aneurysm was then clipped successfully using the modified-fenestrated clip, protecting bilateral A2s. Post-clipping imagings demonstrated patency of parent arteries with no residual aneurysm filling.

Conclusions: ClipMod seems to be an effective option in clipping the AcoA aneurysms when available clips are too long to secure them safely.

Keywords: Anterior communicating artery, Clip modification, Fenestrated aneurysm clips, Microsurgical clipping

References

1. Hernesniemi J et al. Microneurosurgical management of anterior communicating artery aneurysms. Surg Neurol 70(1):8-28, 2008
2. Parmar V et al. Intraoperative Shortening of Aneurysm Clips: Revisiting an Old Technique in a New Era. World Neurosurg 139:361-369, 2020

P-15

An Uncommon Posterior Fossa Pathology in Elderly: Medulloblastoma

Erkin Özgiray[1], Nevhis Akıntürk[1], Bilal Bahadır Akbulut[1], Ömer Kitiş[2], Yeşim Ertan[3]

[1]Ege University, Department of Neurosurgery
[2]Ege University, Department of Radiology
[3]Ege University, Department of Pathology

Objectives: 1. Medulloblastoma is a rare pathology in the elderly, as it is most commonly seen in children. It is essential to be wary of such rare diagnoses. 2. There is limited knowledge about adult medulloblastomas' clinical and prognostic values.

Background: Medulloblastoma is a pathology primarily seen in children and accounts for less than1% of all adult intracranial tumors. Therefore, it is rare in the elderly (>65 years old).Although metastasis is a more common diagnosis for a posterior fossa tumor inadults, it is essential to consider less common pathologies. We present a case ofadult medulloblastoma with nausea-vomiting and gait abnormality.

Method: A 71-years old male patient was admitted to a primary care center for nausea andvomiting and tested for abdominal pathologies; he was discharged with symptomatictreatment. Meanwhile, slurred speech, gait abnormality, and vertigo were added tohis symptoms. MRI scan demonstrated a right cerebellar T2 hyperintense andheterogenic, T1 hypointense but contrast-enhancing lesion. The patient was awakeand had only right-sided dysmetria and dysdiadochokinesia.

Results: Gross total tumor excision was made using right-sided suboccipital craniotomy, andthe tumor had a cystic and necrotic appearance. The MRI scan revealed total tumorremoval, and the patient was discharged after 5 days of follow-up. Pathology resultscame as medulloblastoma, and he was referred to the Department of Oncology for further treatment.

Conclusions: While most commonly seen in children, medulloblastoma is a rare diagnosis that mayalso occur in elderly patients. The treatment regimen is still controversial and followsas the pediatric patients. Even though the medulloblastoma incidence is low inadults, it should be considered in the differential diagnosis.

Keywords: adult medulloblastoma, surgery

References

1. Majd N, Penas-Prado M. Updates on Management of Adult Medulloblastoma. Curr Treat Options Oncol. 2019 Jun 24;20(8):64. doi: 10.1007/s11864-019-0663-0. PMID: 31236711.

P-17

A Rare Case of a 16 Year Old Patient With Ventricular Tumor Who Avoided Permanent Shunt

Viktor Stoev[1], Ivica Kocevski[1], Robert Shumkovski[1], Elmedina Asani[1]

[1]1. University clinic of Neurosurgery - Skopje, North Macedonia, Faculty of Medicine, UniversitySt Cyril and Methodius Skopje

Objectives: To present that despite the presence of obstructive hydrocephalus due to the presence of a tumor, with its fast remove the patient can be spared from a shunt. Also not in all cases after the tumor is removed, the possibility of hydrocephalus reoccurrence is not excluded.

Background: An oligoastrocytoma is a type of mixed glioma that affects the oligodendrocytes and astrocytes, two different types of glial cells. Like other tumors, oligoastrocytomas are graded on a scale from 1 to 4, with grades 1 and 2 describing low-grade tumors. Cerebellar astrocytomas represent up to 10% of all primary brain tumours and up to 25% of posterior fossa tumors in children, with low grade gliomas forming the commonest of the cerebellar gliomas. They commonly present with symptoms and signs of raised intracranial pressure due to obstructive hydrocephalus.

Method: A 16 year old male presenting withacute development of headache, nausea, vomiting, drowsiness, orthostatic instability, tremor and clumsiness in coordination of arms and legs, cerebellar ataxia of the truncal type, Romberg's test is positive without a clear inclination, adiadochokinesiawith low-frequency intention tremor is noted.MRI shows a solid cystic lesion in the cerebellar region with involvement of the vermis. The fourth cerebral ventricle is compressed. Consecutive hydrocephalus is present due to compression of the 4th cerebral ventricle.

Figure 1

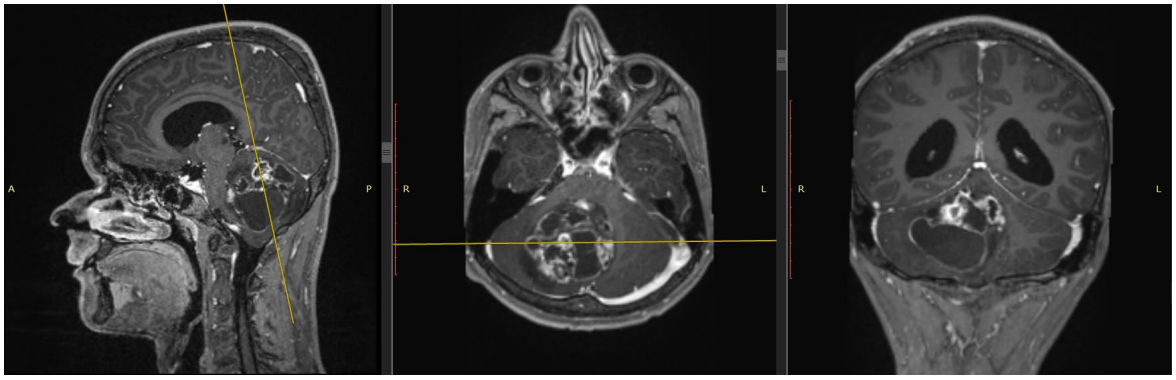

Sagittal, axial and coronal MR of the head with post-contrast series ,before the operative intervention. We see obstructive hydrocephalus as a result of compression on the 4th ventricle

Results: Postoperatively, patient had a significantly improved neurological clinical status, which improved significantly over a period of time. The patient was discharged to home treatment without the need for shunt placement.

Conclusions: Timely treatment and good surgical expertise in reducing the tumor leads to decompression in the posterior fossa and on the 4th cerebral ventricle. This raises the question of possible resolution of hydrocephalus without the need for a shunt.

Keywords: fossa posterior, ventricular tumor, shunt, hydrocephalus

References

1. Nasrallah MLP, Desai A, O'Rourke DM, Surrey LF, Stein JM. A dual-genotype oligoastrocytoma with histologic, molecular, radiological and time-course features. Acta Neuropathol Commun. 2020 Jul 20;8(1):115. doi: 10.1186/s40478-020-00998-3. PMID: 32690110; PMCID: PMC7372861.
2. Sridhar K, Sridhar R, Venkatprasanna G. Management of posterior fossa gliomas in children. J Pediatr Neurosci. 2011 Oct;6(Suppl 1):S72-7. doi: 10.4103/1817-1745.85714. PMID: 22069433; PMCID: PMC3208911.
3. Ahmed M. Moawad; Mohamed K.M. Abdallah; Medhat M. El-Sawy. "Childhood cerebellar astrocytoma, surgical management". *Minia Journal of Medical Research*, 33, 4, 2022, 74-84. doi: 10.21608/mjmr.2022.266325

P-18

Features of Endoscopic Visualization of the Parasellar Region During Subfrontal Access (an Anatomical Study)

Abdishukur Abdilatipov[1], Maksim Kutin[2], Pavel Kalinin[2], Jamil Rzaev[1]

[1]Federal Neurosurgical Center, Novosibirsk, Russia, Nemirovich-Danchenko str., 132\1, 630087.
[2]N.N. Burdenko National Medical Research Center of Neurosurgery, Moscow, Russia, 4th Tverskaya-Yamskaya str., 16, Moscow, Russian Federation, 125047.

Objectives: To study features of perception of parasellar anatomy using different 0° and 45° endoscopes.

Background: The introduction of endoscopic technologies in transcranial surgery of tumors of the parasellar region began relatively recently. The main advantage of using endoscopy is the expansion of the viewing angle and the visualization of areas that are inaccessible to examination under a microscope, for performing any surgical manipulations. The present work is devoted to the description of the features of visualization of the anatomy of the paracellar region under right and angular endoscopes when performing subfrontal access on anatomical preparations.

Method: To study the peculiarities of endoscopic anatomy we performed a study on 5 anatomical specimens with the injection of stained silicone into the ICA and jugular vein from both sides. A small size subfrontal microsurgical access was used with the anatomical specimens (Figure 1).

Figure 1 - Stages of subfrontal craniotomy.



A) Skeletonization of bony structures in the right frontotemporal region, exposure of the key point (indicated with an asterisk). B) Milling of the key point. C) Trepanation of the skull. Semicircular incision of the dura mater, facing the base to the roof of the orbit.

Results: Direct optics (0°) allows visualization of the following parasellar structures: olfactory nerve, optic nerves, chiasma, internal carotid artery. By moving the endoscope between the optic nerves and under the chiasma, the surgeon obtains a view of the pituitary stalk, the diaphragm of the sellar and the superior pituitary arteries (Figure 2). Visualization with a 45° endoscope. When replacing the direct vision endoscope with a 45° endoscope, "blind areas" that are difficult to see through the microscope during subfrontal access can be visualized. The "blind zones" in subfrontal access include: the area under the optic nerve on the access side,

the area under the chiasma, the area behind the back of the sellar, the posterior parts of the third ventricle cavity after perforation of the lamina terminalis.

Figure 2 - Visualization of the structures of the skull base with 0° an endoscope.

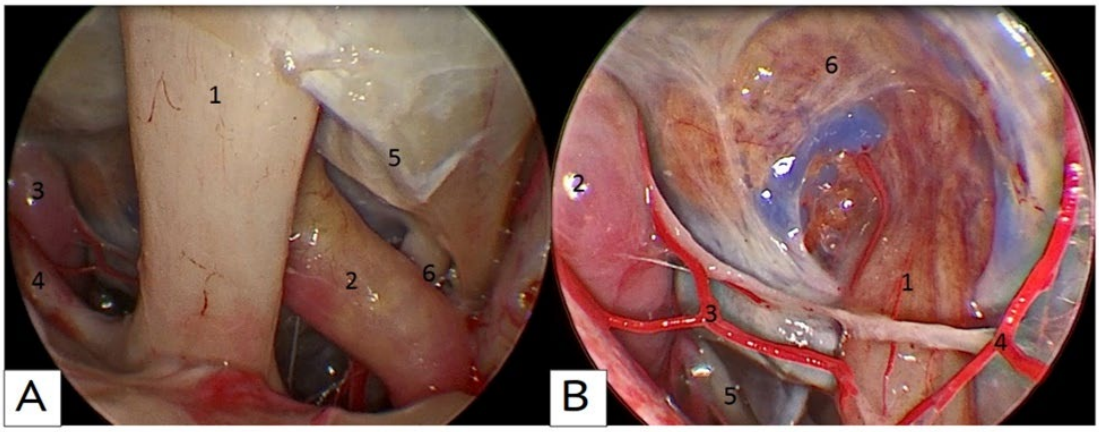

A) Examination over the chiasma: 1 - right optic nerve, 2 - right internal carotid artery, 3 - left VAS, 4 - left optic nerve, 5 - right anterior oblique process, 6 - right oculomotor nerve. B) Examination under the chiasma: 1 - pituitary stalk, 2 - left ICA, 3 and 4 - superior pituitary arteries, 5 - left oculomotor nerve, 6 - diaphragm of the sellar.

Conclusions: The use of endoscopic assistance significantly expands the possibilities of transcranial surgery of the sellar region, allowing improved visualization of anatomical structures during minimally invasive microsurgical accesses and providing control of the radicality of neoplasm removal.

Keywords: transcranial endoscopic anatomical study, parasellar region, subfrontal access, microanatomy

References

1. Spena G., Spena G, Fasel J, Tribolet Nd, Radovanovic I. Subfrontal endoscopic fenestration of lamina terminalis: An anatomical study // Minim. Invasive Neurosurg. Minim Invasive Neurosurg, 2008. Vol. 51, № 6. P. 319–323. doi: 10.1055/s-0028-1085423.
2. Komatsu, F., Komatsu, M., Inoue, T., Tschabitscher, M. Endoscopic supraorbital extradural approach to the cavernous sinus: a cadaver study. Journal of Neurosurgery. 2011. 114(5), 1331–1337. doi:10.3171/2010.10.jns101242
3. Tang C.T., Baidya N.B., Ammirati M. Endoscope-assisted supraorbital approach to the retroinfundibular area: A cadaveric study // Neurosurg. Rev. Springer Verlag, 2013. Vol. 36, № 2. P. 249–257. doi: 10.1007/s10143-012-0418-x
4. Akçakaya, M. O., Aras, Y., İzgi, N., Gayretli, Ö., Sabancı, P. A., Aydoseli, A., Hepgül, K. Fully endoscopic supraorbital keyhole approach to the anterior cranial base: A cadaveric study. Journal of Neurosciences in Rural Practice. 2015. 6(03), 361–368. doi:10.4103/0976-3147.154568

P-19

SMA Syndrome After Transcortical Approach for Intraventricular Tumor

Viktor Stoev[1], Ivica Kocevski[1], Robert Shumkovski[1], Elmedina Asani[1]

[1]1. University clinic of Neurosurgery - Skopje, North Macedonia, Faculty of Medicine, University St Cyril and Methodius Skopje

Objectives: Our main goal is to present that not always the occurrence of postoperative neurological deficit represents an irreversible condition. Due to the complicated location of the tumor, different approaches present different potential neurologic deficits that may occur in the patient.

Background: Intraventricular tumors are unique due to its diversity in the pathological spectrum. Intraventricular tumors are rare lesions representing 0,8%-1,6% of all intracranial tumors. However, because of the location of tumors, surgical management is accompanied by the risk of injury such as supplementary motor area syndrome.

Method: We are describing the clinical course of a 54 year old patient with an intraventricular pilocytic astrocytoma tumor who developed SMA syndrome after transcortical surgical approach. This patienthad a history of headaches that lasted several months and they were more frequent during the day. During the neurological examination she was without any other neurological deficits or signs of increased ICP or/and hydrocephalus. MRI showed an extensive lobulated expansive formation which markedly expands the right lateral ventricle, marked compression of the left lateral ventricle. After transcortical surgical approach the patient developed SMA syndrome.

Figure 1

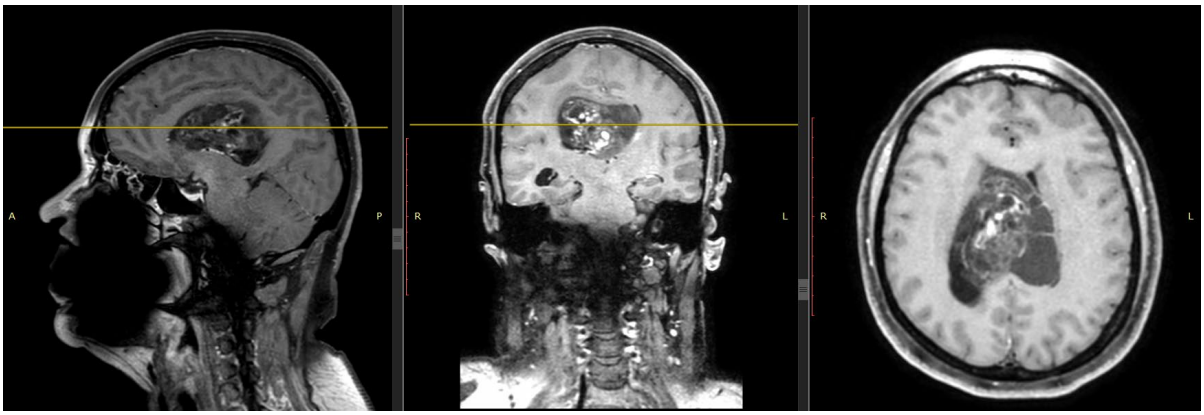

Sagittal MR of the head with T1W post-contrast series and coronal and axial post-contrast sequence ,before the operative intervention

Results: In our case, postoperatively, the patient developed SMA syndrome. The recovery trend improved dramatically over time. After completing one cycle of physical therapy thatwas realized 20 days after the intervention, the patient was with a significant improvement in left-sided weakness.

Conclusions: Intraventricular tumors such as pilocytic astrocytoma are quite rare and may be confused with other tumors in the same localization. The main objective of the surgeon is complete resection which is associated with great outcomes. Consequently, the neurosurgeon's experience and the selection of the surgical approach are essential for better clinical prognosis.

Keywords: intraventricular tumor, IVT, supplementary motor area syndrome, transcortical approach

References

1. Louis DN, Perry A, Reifenberger G, von Deimling A, Figarella-Branger D, Cavenee WK, et al. The 2016 World Health Organization classification of tumors of the central nervous system: a summary. Acta Neuropathol. 2016;131(6):803–20.
2. Agarwal A, Kanekar S. Intraventricular Tumors. Semin Ultrasound CT MR. 2016 Apr;37(2):150-8. doi: 10.1053/j.sult.2015.12.003. Epub 2015 Dec 10. PMID: 27063665.
3. Pinson H, Van Lerbeirghe J, Vanhauwaert D, Van Damme O, Hallaert G, Kalala JP. The supplementary motor area syndrome: a neurosurgical review. Neurosurg Rev. 2022 Feb;45(1):81-90. doi: 10.1007/s10143-021-01566-6. Epub 2021 May 15. PMID: 33993354.
4. Alam S, Uddin AN, Majumder MR, Hasan MM, Ahmed A. Intraventricular Tumor: An Analysis of 18 Cases. Nep J Neurosci [Internet]. 2016 Oct. 9 [cited 2023 May 31];13(1):23-9. Available from: https://www.nepjol.info/index.php/NJN/article/view/15908
5. Nakajima, R., Kinoshita, M., Yahata, T., & Nakada, M. (2020). Recovery time from supplementary motor area syndrome: relationship to postoperative day 7 paralysis and damage of the cingulum, *Journal of Neurosurgery JNS*, *132*(3), 865-874. Retrieved May 31, 2023, from https://doi.org/10.3171/2018.10.JNS182391
6. A. Agarwal *et al.* Intraventricular tumors Semin Ultrasound CT MR (2016)

P-20

Ventriculoperitoneal Shunt in Slit-like Ventricles- Role of Minimal Invasive Neurosurgical techniques.

Rajesh Kumar Meena[1], Ramesh S Doddamanı[1], Sarat P Chandra[1]

[1]Aiims, New-Delhi

Objectives: Background: Ventriculoperitoneal shunt (VPS) is the most common procedure used in the management of hydrocephalus. The standard free-hand technique is used for the placement of VPS in patients with enlarged ventricles. In patients with very small ventricles, CSF access through ventriculostomy becomes challenging and free-hand technique may be associated with high failure rates. In these situations, stereotactic-guided VPS becomes very useful.

Background: Background: Ventriculoperitoneal shunt (VPS) is the most common procedure used in the management of hydrocephalus. The standard free-hand technique is used for the placement of VPS in patients with enlarged ventricles. In patients with very small ventricles, CSF access through ventriculostomy becomes challenging and free-hand technique may be associated with high failure rates. In these situations, stereotactic-guided VPS becomes very useful.

Method: Methods: Seven patients underwent VPS with robotic guidance between 2016 and 2022. Plain CT brain with 1-mm slice thickness acquired prior to the surgery was uploaded into the ROSA machine (Zimmer Biomet Warsaw, Indiana). The trajectory for the VPS is created on the robotic software pre-surgery. The placement of the VPS is commenced with the robotic arm in the predetermined trajectory.

Results: Results: Ventricle was hit in a single attempt in all the cases. CSF leak stopped in the case with meningocele; headache, and visual acuity improved in four out of six cases of IIH.

Conclusions: Conclusion: Robotic-guidance provides a safe and accurate method of VPS placement even in the presence of slit-like ventricles.

Keywords: SLIT LIKE VENTRICLES, VP SHUNT, IIH, ROBOTIC

References

Badhiwala JH, Kulkami AV. Ventricular shunting procedures. In: Winn H, editor. Youmans and Winn Neurological Surgery. 4th ed. Elsevier; 2016. p. 1615-29.
McGirt MJ, Woodworth G, Thomas G, Miller N, Williams M, Rigamonti D. Cerebrospinal fluid shunt placement for pseudotumor cerebri-associated intractable headache: Predictors of treatment response and an analysis of long-term outcomes. J Neurosurg 2004;101:627-32.
Johnston I, Besser M, Morgan MK. Cerebrospinal fluid diversion in the treatment of benign intracranial hypertension. J Neurosurg 1988;69:195-202.
El-Saadany WF, Farhoud A, Zidan I. Lumboperitoneal shunt for idiopathic intracranial hypertension: Patients' selection and outcome. Neurosurg Rev 1996;35:239-44.

P-21

Epilepsy and Its Surgical Management in LMICs, Where are We Standing? The Scenario, Scope and Challenges

Noor ul Huda Maria[1]

[1]PINS

Objectives: Assess the current scenario of Epilepsy, Management and the availability of Surgical Management of Epilepsy and also training with special reference to Scope and Challenges

Background: While epilepsy surgery is a promising option for drug-resistant epilepsy, it is still an underrated and underutilized procedure worldwide. Its use is far worse in the low-middle income countries where the incidence and prevalence is relatively high

Method: We reviewed articles and performed a survey from neurosurgeons from LMIC

Results: 80% of the affected from LMICs in 2006 epilepsy surgery is available in only 13% 73.3- 75% of patients do not receive any treatment Study from Tanzania suggested association of adverse perinatal events with epilepsy In Pakistan one dedicated epilepsy surgery,no national guideline,there is no specialty training program for epilepsy surgery as well Cambodia has no epilepsy center, Level-3 epilepsy centers are available in Indonesia, Philippine, Thailand and Vietnam only. Indonesia and Thailand has at least one level-4 epilepsy care facility. India by 2017, 39 centers . Only 10% neurosurgeons admitted to have observed epilepsy surgery during their career, only 25% had epilepsy surgery performed in their country, 60% said that they find patients interested in epilepsy surgery,30% had at least 1 dedicated epilepsy management center in their country,60% neurosurgeons showed interest in epilepsy surgery 20% had national training program for epilepsy surgery.In question related with the challenges for epilepsy surgery, all agreed that it is because of lack of trained personnel who could train the other neurosurgeons 80 % lack of attention 60% cost of surgery

Conclusions: Epilepsy surgery is still an under rated management strategy in the LMIC for epileptic patients. The greatest challenge is a lack of trained personnel, national training program scarcity of dedicated epileptic centers and economical constraints in the LMIC

Keywords: Epilepsy, Epilepsy Surgery, LMICs

References

1. Watila MM, Xiao F, Keezer MR, Miserocchi A, Winkler AS, McEvoy AW, Sander JW. Epilepsy surgery in low- and middle-income countries: A scoping review. Epilepsy Behav. 2019 Mar;92:311-326. doi: 10.1016/j.yebeh.2019.01.001. Epub 2019 Feb 6. PMID: 30738248.
2. Williamson PD, Jobst BC. Epilepsy surgery in developing countries. Epilepsia. 2000;41 Suppl 4:S45-50. doi: 10.1111/j.1528-1157.2000.tb01546.x. PMID: 10963478.

P-22

Temporal Lobe Encephalocele in The Lateral Recess of the Sphenoid Sinus Complicated With Intracerebral Hemorrhage

Rasim Agaev[1], Ekaterina Gormolisova[1], Anton Kalinovskiy[1], Jamil Rzaev[1], Galina Moisak[1]

[1]FSBI "Federal Neurosurgical Center" Novosibirsk, Russia

Objectives: Investigation of clinical case

Background: Cranial encephaloceles, herniation of intracranial meninges and brain tissue through a defect in the cranium or skull base, are rare conditions with an incidence of approximately 1 in 35,000 people, and are more common in the anterior cranial fossa than in the middle one.

Method: A 34-year-old female presented with an 8-year history of rhinorrhea. She turned to doctors due to an increase in the amount of fluid secreted from the nose. Computed tomography (CT) imaging of the head revealed a sphenoid sinus bony defect on its posterior aspects about 5 mm,(fig. 1). An MRI study showed gliotic temporal brain parenchyma herniating through the sphenoid bone defect (fig. 2).

fig.2

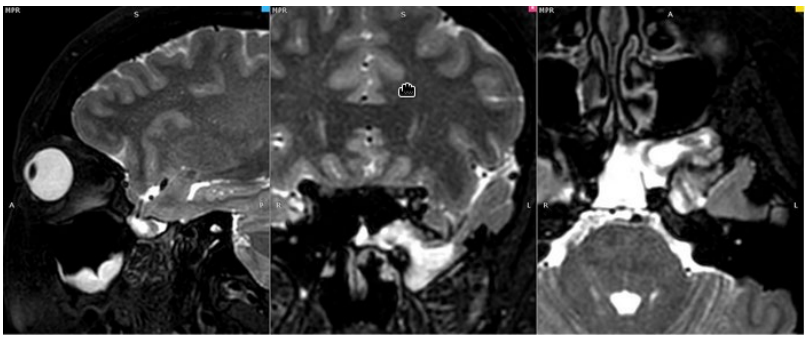

MRI scan of meningoencephalocele

fig. 1

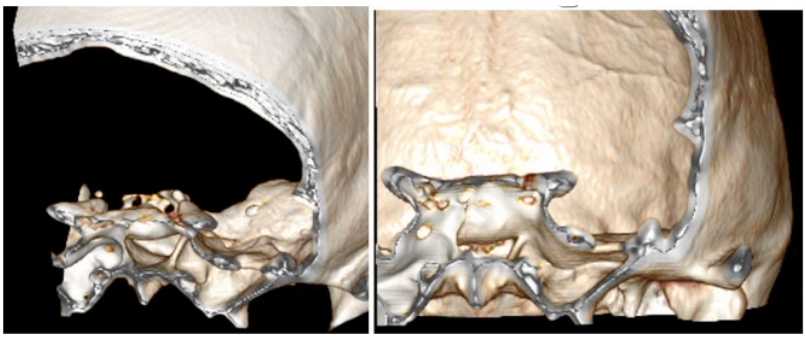

CT scan of bone defect

Results: Endoscope-assisted transnasal approach was performed for surgical repair of the defect. In the early postoperative period, decreased consciousness (12 Glasgow score), with no other neurologic deficit. On CT scan there were intracerebral hematoma of the left temporal lobe, up to 40 ml., with signs of SAH. (fig. 2A). There was a immediate surgical treatment - removal of an intracerebral hematoma. In the postoperative period, the general condition is stable, no consciousness deficit, there was an elements of motor aphasia. Control MRI of the brain revealed new small foci of ischemia in the left frontal lobe (fig. 3). After stabilisation, the patient was discharged in a satisfactory condition.

fig.3

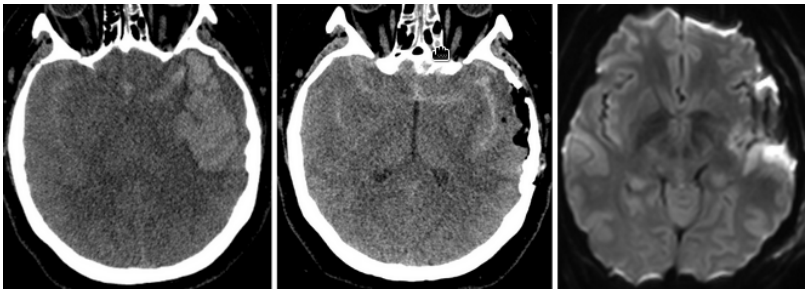

CT and MRI scan after surgery

Conclusions: Our literature review showed a lot of different type of complications, but without any hematoma or subarachnoid hemorrhage. We investigated our case and found, on MRI scans, that the encephalocele consisted branch of an MCA temporopolar artery, which we suppose was the cause of hemorrhage. The temporopolar artery (TPA) is the most proximal branch of the middle cerebral artery (MCA), feeding the pole and lateral aspect of the anterior temporal lobe.

Keywords: Rhinorrhoea, Encephalocele, Hematoma, temporopolar artery

References

1. Hanwate, R. , Thorawade, V. , Jagade, M. , Attakil, A. , Parelkar, K. , Pandare, M. , Natraj, R. and Kar, R. (2015) CSF Rhinorrhoea with Encephalocele through Sternberg's Canal: Our Experience. International Journal of Otolaryngology and Head & Neck Surgery, 4, 50-54. Volume 4, Issue 1 (January 2015)
2. Cruz E Silva V, Luís A, Mora Féria R, Marques L, Chorão M, Reizinho C, Graça J. Transsphenoidal meningoencephalocele protruding into the nasal cavity. BJR Case Rep. 2016 Nov 10;3(2):20160082.
3. Sharipov OI, Kutin MA, Polev GA, Kalinin PL. Lateral extended transsphenoidal endoscopic approach through the pterygopalatine fossa in surgery for meningoencephalocele of the lateral sphenoid recess. Zhurnal Voprosy Neirokhirurgii Imeni N.N. Burdenko. 2018;82(5):96-103.
4. Zoli M, Farneti P, Ghirelli M, Giulioni M, Frank G, Mazzatenta D, Pasquini E. Meningocele and Meningoencephalocele of the Lateral Wall of Sphenoidal Sinus: The Role of the Endoscopic Endonasal Surgery. World Neurosurg. 2016 Mar;87:91-7.
5. Somu L, Kumar P, Nivas PR (2015) Meningoencephelocele through the Lateral Craniopharyngeal Canal. J Otolaryngol ENT Res 3(3): 00069
6. Shelesko EV, Kapitanov DN, Kravchuk AD, Chernikova NA, Zinkevich DN, Tsukanova TV. Nash opyt lecheniia patsientov s nazal'noĭ likvoreeĭ iz lateral'nogo karmana klinovidnoĭ pazukhi [Experience of treating patients with lateral sphenoid sinus recess CSF leak]. Zh Vopr Neirokhir Im N N Burdenko. 2018;82(6):68-75.
7. Hanz SZ, Arko L 4th, Schmidt F, Kacker A, Tsiouris AJ, Anand VK, Schwartz TH. Low incidence of true Sternberg's canal defects among lateral sphenoid sinus encephaloceles. Acta Neurochir (Wien). 2020 Oct;162(10):2413-2420.
8. Tayebi Meybodi A, Benet A, Griswold D, Dones F, Preul MC, Lawton MT. Anatomical Assessment of the Temporopolar Artery for Revascularization of Deep Recipients. Oper Neurosurg (Hagerstown). 2019 Mar 1;16(3):335-344
9. De Long WB. Anatomy of the middle cerebral artery: the temporal branches. Stroke. 1973 May-Jun;4(3):412-8.
10. Moore, K. L., Dalley, A. F., & Agur, A. M. R. (2014). Clinically Oriented Anatomy (7th ed.). Philadelphia, PA: Lippincott Williams & Wilkins.
11. Netter, F. (2019). Atlas of Human Anatomy (7th ed.). Philadelphia, PA: Saunders.
12. Standring, S. (2016). Gray's Anatomy (41tst ed.). Edinburgh: Elsevier Churchill Livingstone.
13. Tubbs, R. S., Shoja, M. M., Loukas, M., & Bergman, R. A. (2016). Bergman's comprehensive encyclopedia of human anatomic variation. Hoboken: Wiley Blackwell.
14. Meybodi AT, Lawton MT, Griswold D, Mokhtari P, Payman A, Yousef S, Tabani H, Benet A. Anterior Temporal Artery-to-Anterior Cerebral Artery Bypass: Anatomic Feasibility of a Novel Intracranial-Intracranial Revascularization Technique. World Neurosurg. 2017 Mar;99:667-673.

P-24

Usage of Gentamicin and Vancomycin Versus Normal Saline lavage Intraoperatively to Treat Infected Depressed Skull Fractures

Dr. Tahreem Fatima Fatima[1], Dr. Umar Nadeem Nadeem[1], Dr. Umar Hassan Hassan[1], Dr. Ayesha Farooq Farooq[1]

[1]Mayo hospital Lahore, Pakistan

Objectives: To study the Use of Gentamicin and Vancomycin versus Normal Saline lavage intraoperatively to treat infected depressed skull fractures in traumatic brain injury patients

Background: Traumatic brain injury is a common presentation in emergency departments. Skull fractures can be classified into linear, depressed, and comminuted fractures or depressed. Antibiotics have also been linked with decreased infection rates in patients with depressed skull fractures. The purpose of this study is to compare the use of a dual preparation for wash i.e. containing both gentamicin and vancomycin with a control group [normal saline] wash in the treatment of infected depressed skull fractures intraoperatively.

Method: A Prospective Case-Control Study in the Neurosurgery Department, Mayo Hospital, Lahore for 6 months. The sample size included 62 cases and 31 patients both groups. The data analysis using SPSS version 28 was performed.

Methods

Figure 1

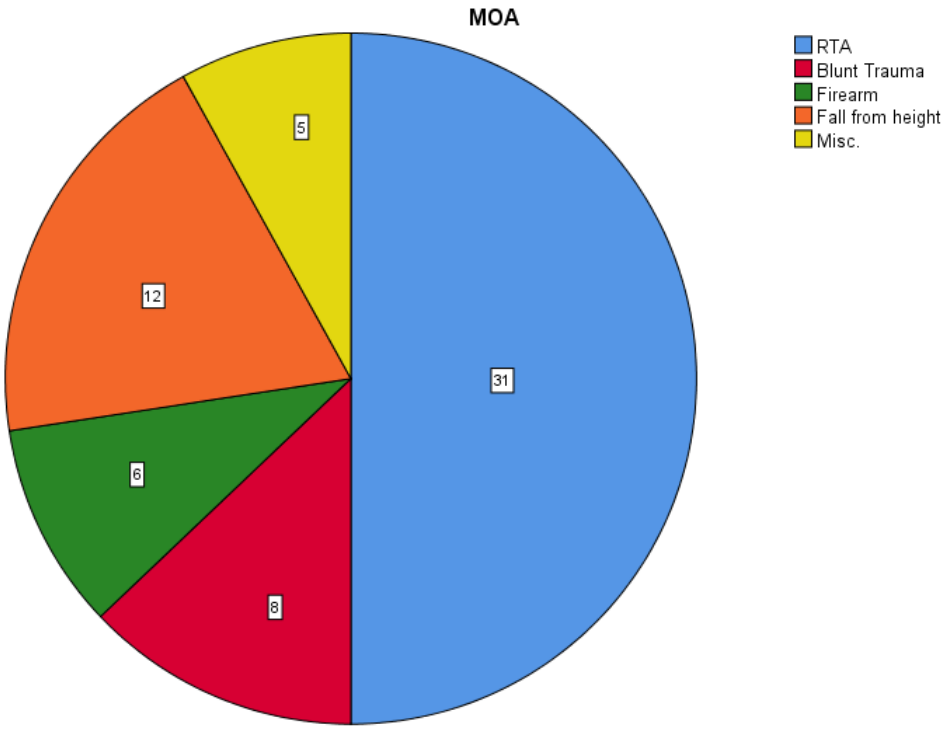

CSF leak

	Frequency	Percent	
Absent	30	48.4	
Present	32	51.6	
Total	62	100.0	

Depressed skull fractures

	Frequency	Percent
Open	48	77.4
Close	14	22.6
Total	62	100.0

Results: In control group (normal saline wash), mean duration of hospital stay was 15.81 ± 14.284 days, whereas in the case group (gentamycin and vancomycin wash), it was 4.32 ± 2.60. In the control group the mean GOS was 3.26 ± 1.413 whereas in the case group it was 4.81 ± 0.543. (Pearson's correlation for GOS co-efficient= -0.799, $p < 0.001$). There was a need for intervention after the primary intervention in only 4.3% cases in the case group as compared to 24.2% in the control group for which the chi-square test of independence shows a statistical significance (p=0.001).

results

Table 2.

Open/Close Wound

		Frequency	Percent
Valid	Open	48	77.4
	Close	14	22.6
	Total	62	100.0

CSF Leak

		Frequency	Percent
Valid	Absent	30	48.4
	Present	32	51.6
	Total	62	100.0

Foreign Body

		Frequency	Percent
Valid	Absent	44	71.0
	Present	18	29.0
	Total	62	100.0

Brain Matter

		Frequency	Percent
Valid	Absent	38	61.3
	Present	24	38.7
	Total	62	100.0

results

Figure 2

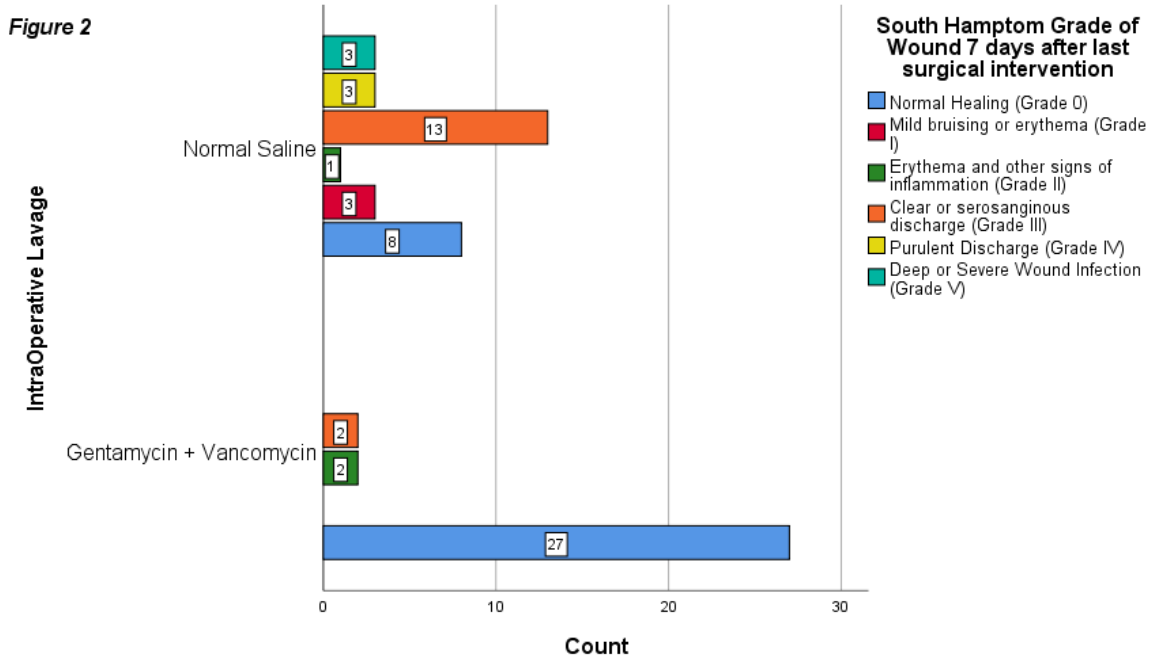

Conclusions: The case group (gentamycin and vancomycin wash) showed a significant decrease in duration of hospital stay, post-operative complications and better GOS as compared to the control group. Thus, the usage of intraoperative gentamycin and vancomycin lavage is effective in decreasing complications of infected depressed skull fractures in burdened trauma settings of developing countries.

Keywords: Gentamicin, Depressed skull fracture, vancomycin, normal saline

References

1. Georges A, M Das J. Traumatic Brain Injury. 2022 Jan 5. In: StatPearls [Internet]. Treasure Island (FL): StatPearls Publishing; 2022 Jan–. PMID: 29083790.
2. Hussein, A. A., Laeke, T., & Yohannes, D. (2022). Clinical Outcomes and Prognostic Determinants of Surgically Treated Depressed Skull Fracture in Addis Ababa University Neurosurgical Teaching Hospitals: A Prospective Multicenter Observational Study. *World Neurosurgery*, *158*, e55-e63. https://doi.org/10.1016/j.wneu.2021.10.089
3. Kelly, Adrian Kelly & Lekgwara, Patrick. (2018). Evaluating patient epidemiology and clinical practice on the outcome of patients admitted with skull fractures secondary to assault. Clinical Practice. 10.4172/clinical-practice.1000436.
4. Manoz-Sanchez MA, Murillo-Cabezas F, Cayuela-Dominguez A, Rincón-Ferrari MD, Amaya-Villar R, León-Carrión J. Skull fracture, with or without clinical signs, in mTBI, is an independent risk marker for neurosurgical relevant intracranial lesion: a cohort study. Brain Inj.2009;23:39.
5. Salia, S. M., Mersha, H. B., Aklilu, A. T., Baleh, A. S., & Lund-Johansen, M. (2018). Predicting Dural Tear in Compound Depressed Skull Fractures: A Prospective Multicenter Correlational Study. *World Neurosurgery*, *114*, e833-e839. https://doi.org/10.1016/j.wneu.2018.03.095
6. Irshad M, Manzoor CA, Aamir M. The frequency of infection in early versus late surgery of compound depressed skull fractures in adults. *International Surgery Journal*. 2018;5(2):538. doi:10.18203/2349-2902.isj20180347
7. Jennett B, Miller J. Infection after depressed fracture of the skull. Implications for management of nonmissile injuries. J Neurosurg. 1972;36:333-9.
8. Zapata, L., Wright, E. J., & Nakaji, P. (2018). Clinical and Neurosurgical Management of Cranial Machete Injuries: The Experience of a Tertiary Referral Center in Nicaragua. *World Neurosurgery*, *116*, 140-143. https://doi.org/10.1016/j.wneu.2018.05.020
9. Kolodziejczyk, D., & Hirsch, W. D. (1992). Epidurale "Sulmycin Implant"-Abdeckung zur lokathe len Infektionsprophylaxe bei der operativen Versorgung offener Schädel-Hirn-Verletzungen [Epidural "sulmycin implant" coverage for local prevention of infection in surgical management of open craniocerebral injuries]. *Aktuelle Traumatologie*, *22*(6), 272–275.
10. Uysal, E., Çal, M. A., & Cine, H. Advance 2). The use of vancomycin powder in the compound depressed skull fractures. *Clinical neurology and neurosurgery*, *225*, 107570. Advance online publication. https://doi.org/10.1016/j.clineuro.2022.107570

P-25

Ventriculosubgaleal Shunt as a Proposed Technique for Post-infectious Hydrocephalus

Mohamed Mohsen Amen[1], Ahmed Zaher[1], Hatem Ebraheem Badr[1], Mohamed fekry elsherbiny[1], Ahmed Elnaggar[1]

[1]Mansoura university hospitals

Objectives: We conducted the current study to elucidate the safety and efficacy of VSGS as a temporary CSF diversion procedure before VPS in patients with PIH, which is the most common cause of acquired hydrocephalus in our tertiary center.

Background: The management of post-infectious hydrocephalus (PIH) remains challenging for neurosurgeons. It requires a temporary diversion procedure till the normalization of CSF parameters prior to the permanent one. Ventriculosubgaleal shunt (VSGS) was widely used in pediatric cases with post-hemorrhagic hydrocephalus (PHH). However, its role in PIH is still lacking. This study was done to elucidate the safety and efficacy of VSGS as a temporary CSF diversion procedure before the permanent one in patients with PIH

Method: This retrospective investigation analyzed the data of 50 consecutive cases who underwent VSGS for PIH

operative steps

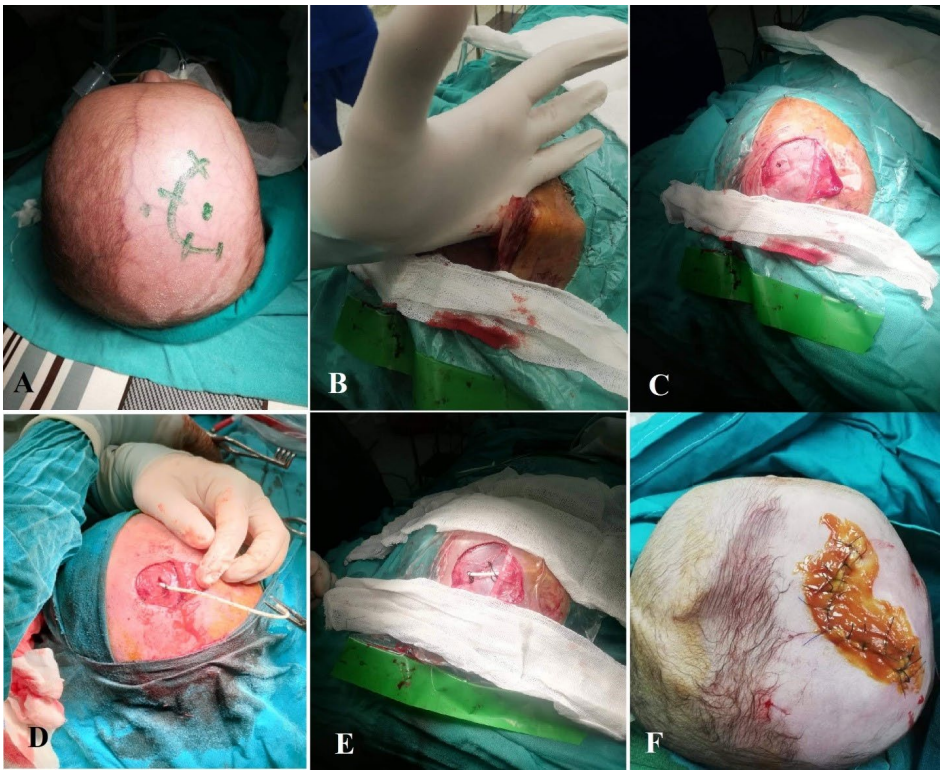

Results: The age of the included patients ranged between 1 and 10 months. Twenty-six cases had meningitis and or ventriculitis (52%), while the remaining had shunt infection. At follow-up, arresting of hydrocephalus was noted in ten patients (20%), while another 36 cases required the permanent diversion procedure within 35 days. Regarding the shunt complications, scalp infection, tissue breakdown, and shunt exposure were encountered in ten cases (20%), while CSF leakage was noted in 12 cases (24%). Shunt migration was noted in only two patients (4%). Shunt revision was needed in 16 cases (32%). Mortality was encountered in four cases (8%) because of sepsis. Risk factors for morbimortality included younger age, lower weight, male gender, and meningitis and or ventriculitis.

Conclusions: VSGS is a safe and effective procedure in infants awaiting definitive VPS for postinfectious hydrocephalus. It was proven that VSGS has shortened the hospital stay and the economic burden on the country.

Keywords: Post-infectious hydrocephalus · Ventriculosubgaleal shunt

References

1. Krishnan P, Raybaud C, Palasamudram S, Shroff M (2019) Neuroimaging in Pediatric hydrocephalus. Indian J Pediatr 86(10):952–960
2. Korinek AM, Fulla-Oller L, Boch AL, Golmard JL, Hadiji B, Puybasset L (2011) Morbidity of ventricular cerebrospinal fluid shunt surgery in adults: an 8-year study. Neurosurgery 68(4):985– 94; discussion 94–5
3. Weisenberg SH, TerMaath SC, Seaver CE, Killeffer JA (2016) Ventricular catheter development: past, present, and future. J Neuorosurg 125(6):1504–1512
4. Melo JRT, Passos RK, Carvalho M (2017) Cerebrospinal fluid drainage options for posthemorrhagic hydrocephalus in premature neonates. Arq Neuropsiquiatr 75(7):433–438
5. Rahman S, Teo C, Morris W, Lao D, Boop FA (1995) Ventriculosubgaleal shunt: a treatment option for progressive posthemorrhagic hydrocephalus. Childs Nerv Syst 11(11):
6. Tubbs RS, Smyth MD, Wellons JC 3rd, Blount JP, Grabb PA, Oakes WJ (2003) Alternative uses for the subgaleal shunt in pediatric neurosurgery. Pediatr Neurosurg 39(1):22–24
7. Nee LS, Harun R, Sellamuthu P, Idris Z (2017) Comparison between ventriculosubgaleal shunt and extraventricular drainage to treat acute hydrocephalus in adults. Asian J Neurosurg 12(4):659–663
8. Lam HP, Heilman CB (2009) Ventricular access device versus ventriculosubgaleal shunt in post hemorrhagic hydrocephalus associated with prematurity. J Matern Fetal Neonatal Med 22(11):1097–1101

P-28

Hydrocephalus due to Foramen Monroe Obstruction by a Basilar Trunk Aneurysm: Spontaneous Thrombosis After Shunting

Erkin Özgiray[1], Nevhis Akıntürk[1], Bilal Bahadır Akbulut[1], Celal Çınar[2]

[1]Ege University, Department of Neurosurgery
[2]Ege University, Department of Radiology

Objectives: 1.Giant basilar trunk aneurysms are rare and present with obstructive hydrocephalus.2. These complex aneurysms may spontaneously and paradoxically thrombose after shunting due to decreased intracranial pressure and changes in the arterial flow dynamics.

Background: Giant basilar artery aneurysms are less than 1% of all intracranial aneurysms, and the growth of these aneurysms into the third ventricle causing hydrocephalus is extremely rare. Hence, the diagnosis is usually made after the onset of the symptoms. However, the first-line treatment is still controversial. Whether to intervene in the hydrocephalus or aneurysm first is still debatable, and there is no consensus. We present a case of a giant basilar trunk aneurysm that spontaneously thrombosed after inserting a ventriculoperitoneal shunt.

Method: A 66-year-old female patient with a known giant basilar trunk aneurysm was referred from the emergency department due to gait abnormalities, headache, and confusion. The patient was awake but confused and apathetic, with 4/5 quadriparesis and right-sided facial asymmetry. CT scan revealed hydrocephalus without SAH, a basilar artery aneurysm extending to the third ventricle. After discussing with interventional radiology, ventriculoperitoneal shunting was decided as the first-line treatment.

Results: A right-sided placement of ventriculoperitoneal shunting was performed using ultrasound guidance with no catastrophic complication. The patient was discharged after three days once her quadriparesis and cognition improved. After a month of follow-up, the patient was readmitted for embolization, but the CT angiogram revealed that the giant basilar trunkaneurysm was spontaneously thrombosed; the patient was discharged without intervention.

Conclusions: Giant basilar trunk aneurysms may cause obstructive hydrocephalus. Its treatment remains challenging; io-USG and other intraoperative guidance techniques are necessary to ensure a safe treatment. In addition, these aneurysms may spontaneously and paradoxically thrombose after shunting due to decreased intra-cranial pressure and change in the arterial flow dynamics. Large case series may facilitate to conclude a certain treatment algorithm.

Keywords: giant aneurysm, basilar trunk, hydrocephalus

References

1. Liu JK, Gottfried ON, Couldwell WT. Thrombosed basilar apex aneurysm presenting as a third ventricular mass and hydrocephalus. Acta Neurochir (Wien). 2005 Apr;147(4):413-6; discussion 417. doi: 10.1007/s00701-004-0452-8. PMID: 15662571.

P-29

Evaluation of CRASH-TBI Score for predicting outcomes of Decompressive Hemi-Craniectomy versus Standard Conservative Treatment in patients with traumatic brain injury.

Dr. Tahreem Fatima[1], Dr. Umar Nadeem[1], Dr, Umar Hassan[1], Dr. Ayesha Farooq[1], Prof. Dr. Shahzad Shams[1]

[1]Mayo hospital Lahore, Pakistan

Objectives: To evaluate CRASH-TBI Score for predicting outcomes of Decompressive Hemi-Craniectomy versus Standard Conservative Treatment in patients with traumatic brain injury.

Background: DECRA (Decompressive Craniectomy in Diffuse Traumatic Brain Injury) Trial, reported early Decompressive Craniectomy in management of severe diffuse TBI and refractory intracranial hypertension. Our study involves Decompressive Hemi-Craniectomy, no previous studies involving either the effect of Decompressive Hemi-Craniectomy on mortality and morbidity of the patients or the correlation between Decompressive Hemi-Craniectomy with CRASH-TBI score have been conducted.

Method: A Retrospective Case-Control Study. SPSS V28.

Table 1-Case group

	Frequency	Percent	Valid Percent	Cumulative Percent
Valid None	1	3.2	3.2	3.2
Both	12	38.7	38.7	41.9
Total	18	58.1	58.1	100.0
	31	100.0	100.0	

Pupil reactive to light-Case group

	Frequency	Percent	Valid Percent	Cumulative Percent
Valid None	20	64.5	64.5	64.5
Both	11	35.5	35.5	100.0
None	31	100.0	100.0	

Obliteration of third ventricle or basal cisterns-Case group

	Frequency	Percent	Valid Percent	Cumulative Percent
Valid None	18	58.1	58.1	58.1
Both	13	41.9	41.9	100.0
None	31	100.0	100.0	

Subarachnoid hemorrhage in case group

	Frequency	Percent	Valid Percent	Cumulative Percent
Valid None	29	93.5	93.5	93.5
Both	2	6.5	6.5	100.0
None	31	100.0	100.0	

Major extra cranial injury-case group

	Frequency	Percent	Valid Percent	Cumulative Percent
Valid Present	31.0	100.0	100.0	100.0

Midline shift and petechial hemorrhages-case group

	Frequency	Percent	Valid Percent	Cumulative Percent
Valid Absent	23	74.2	74.2	74.2
Present	8	25.8	25.8	100.0
Total	31	100.0	100.0	

Nonevacuated hematoma-case group

Table 1-Case group

Table 2-Control group clinical and radiological characteristics at presentation

	Frequency	Percent	Valid Percent	Cumulative Percent
Valid Absent	22	71.0	71.0	71.0
Both	9	29.0	29.0	100.0
Total	31	100.0	100.0	

obliteration of third ventricle or basal cistern-Control group

	Frequency	Percent	Valid Percent	Cumulative Percent
Valid Absent	5	16.1	16.1	16.1
Both	26	83.9	83.9	100.0
Total	31	100.0	100.0	

Pupil reactive to light-control group

	Frequency	Percent	Valid Percent	Cumulative Percent
Valid Absent	19	61.3	61.3	61.3
Both	12	38.7	38.7	100.0
Total	31	100.0	100.0	

Subarachnoid hemorrhage-control group

	Frequency	Percent	Valid Percent	Cumulative Percent
Valid Absent	27	87.1	87.1	87.1
Both	4	12.9	12.9	100.0
Total	31	100.0	100.0	

Major extracranial injury-control group

	Frequency	Percent	Valid Percent	Cumulative Percent
Valid Present	31	100.0	100.0	100.0

Midline shift and petechial hemorrhage

	Frequency	Percent	Valid Percent	Cumulative Percent
Valid Absent	21	67.7	67.7	67.7
Both	10	32.3	32.3	100.0
Total	31	100.0	100.0	

Non-evacuated hematoma-control group

Table-2 Control group

Results: Case group[Decompressive Hemi-Craniectomy]= 31 patients presented with mean GCS of 7.45 ± 2.38. Mean eGOS-14 days or discharge= 3.06 ± 2.25, at 6 months= 2.61 ± 2.27. Control group[standard protocol]= 31 patients presented with mean GCS of 10.74 ± 0.99. Mean eGOS- 14 days or discharge= 2.55 ± 1.91, at 6 months was 2.19 ± 1.98. Estimated risk of 14-day Mortality by CRASH-TBI score significantly predicted eGOS observed in our study at 14-days or discharge, $F(1, 29) = 68.235$, $p < 0.001$. R2 value of 0.702 estimated mortality at 14-days by CRASH-TBI score explained 70.2% variance of eGOS at 14-days or discharge. estimated risk of unfavorable outcome (eGOS 1 to 4) at 6 months by CRASH-TBI score was significant in predicting the eGOS observed in our study at 6 months on follow-up, $F(1, 29) = 94.383$, $p < 0.001$. R2 value of 0.765 depicted estimated unfavorable outcome at 6 months by CRASH-TBI score explained 76.5% variance of eGOS at 6 months on follow-up.

Figure 1

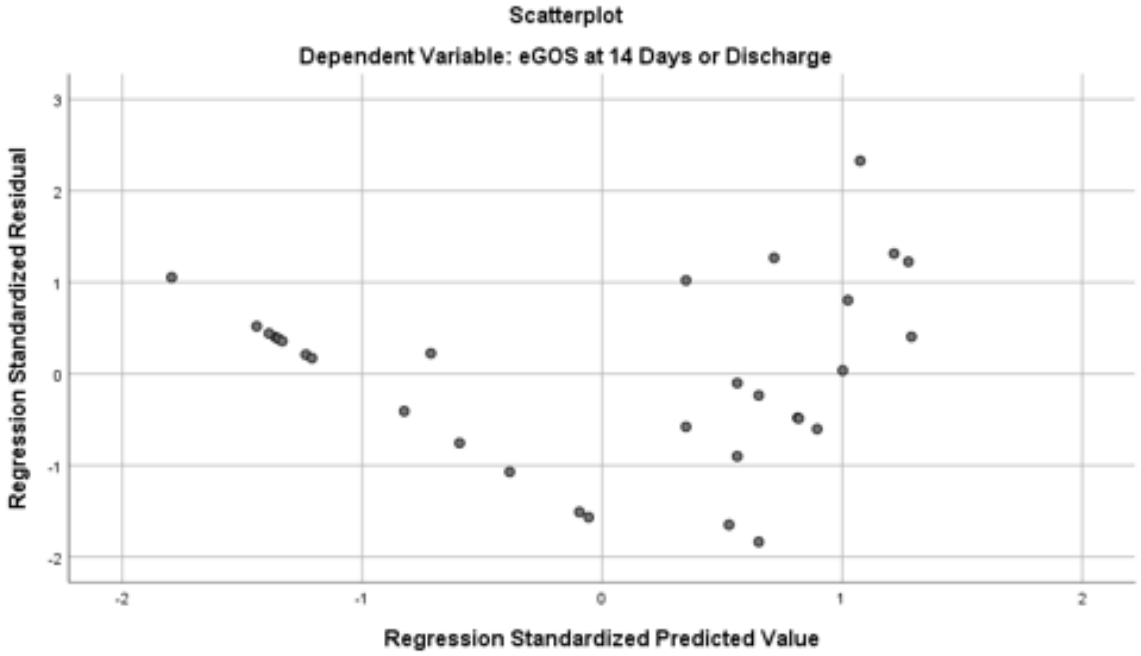
Scatterplot
Dependent Variable: eGOS at 14 Days or Discharge
Regression Standardized Residual
Regression Standardized Predicted Value
3
2
1
0
-1
-2
-2
-1
0
1
2

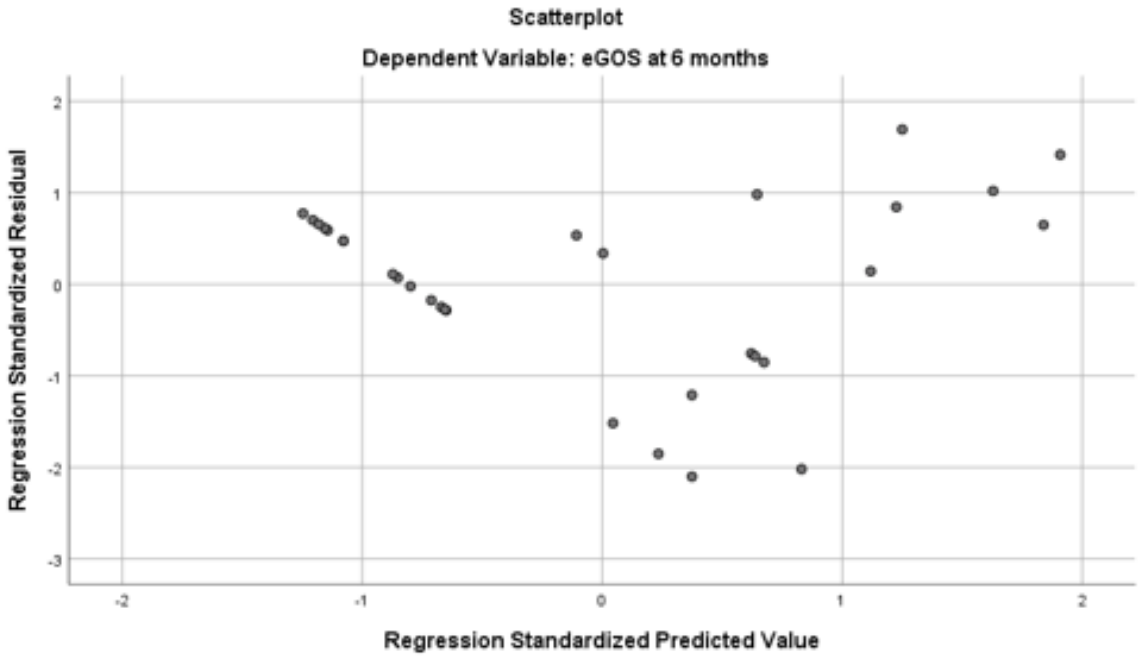
Scatterplot
Dependent Variable: eGOS at 6 months
Regression Standardized Residual
Regression Standardized Predicted Value
2
1
0
-1
-2
-3
-2
-1
0
1
2

Figure 2

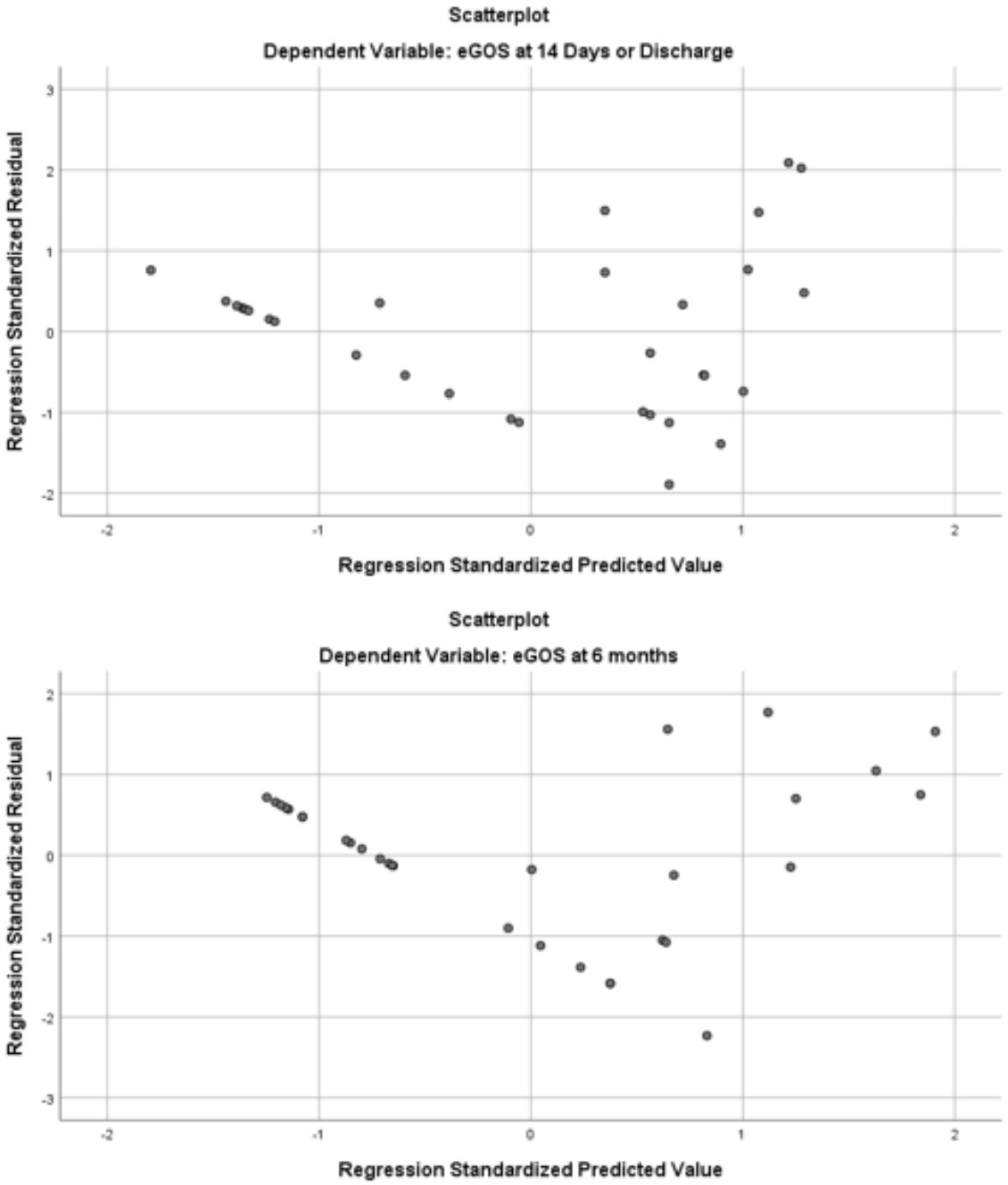

Conclusions: CRASH-TBI score can be used to predict outcomes better in patients with Decompressive Hemi-Craniectomy. DHC is associated with better short (low rate of 14-day mortality) and long-term outcomes (low rate of the unfavorable outcome at 6 months) as compared to conservative standard treatment.

Keywords: DECRA, Decompressive hemicraniectomy, CRASH-TBI score, predicit

References

1. Centers for Disease C, Prevention. CDC grand rounds: reducing severe traumatic brain injury in the United States. *MMWR Morbidity and mortality weekly report.* 2013;**62**(27):549–552.
2. Georges A, M Das J. Traumatic Brain Injury. [Updated 2022 Jan 5]. In: StatPearls [Internet]. Treasure Island (FL): StatPearls Publishing; 2022 Jan-. Available from: https://www.ncbi.nlm.nih.gov/books/NBK459300/
3. Correspondent; The Express Tribune (May 22,2022) ‘‘800,000 suffer head injuries every year in Pakistan’, *The Express Tribune;* URL: https://tribune.com.pk/story/2357713/800000-suffer-head-injuries-every-year-in-pakistan
4. Perel, P., Edwards, P., Wentz, R., & Roberts, I. (2006). Systematic review of prognostic models in traumatic brain injury. *BMC medical informatics and decision making*, *6*, 38. https://doi.org/10.1186/1472-6947-6-38
5. MRC CRASH Trial Collaborators, Perel, P., Arango, M., Clayton, T., Edwards, P., Komolafe, E., Poccock, S., Roberts, I., Shakur, H., Steyerberg, E., & Yutthakasemsunt, S. (2008). Predicting outcome after traumatic brain injury: practical prognostic models based on a large cohort of international patients. *BMJ (Clinical research ed.)*, *336*(7641), 425–429. https://doi.org/10.1136/bmj.39461.643438.25
6. Miller, J. D., Piper, I. R., & Dearden, N. M. (1993). Management of intracranial hypertension in head injury: matching treatment with cause. *Acta neurochirurgica. Supplementum*, *57*, 152–159. https://doi.org/10.1007/978-3-7091-9266-5_22
7. Cooper, D. J., Rosenfeld, J. V., Murray, L., Arabi, Y. M., Davies, A. R., D'Urso, P., Kossmann, T., Ponsford, J., Seppelt, I., Reilly, P., Wolfe, R., DECRA Trial Investigators, & Australian and New Zealand Intensive Care Society Clinical Trials Group (2011). Decompressive craniectomy in diffuse traumatic brain injury. *The New England journal of medicine*, *364*(16), 1493–1502. https://doi.org/10.1056/NEJMoa1102077
8. Fatima, N., Al Rumaihi, G., Shuaib, A., & Saqqur, M. (2019). The Role of Decompressive Craniectomy in Traumatic Brain Injury: A Systematic Review and Meta-analysis. *Asian journal of neurosurgery*, *14*(2), 371–381. https://doi.org/10.4103/ajns.AJNS_289_18
9. Tapper, J., Skrifvars, M. B., Kivisaari, R., Siironen, J., & Raj, R. (2017). Primary decompressive craniectomy is associated with worse neurological outcome in patients with traumatic brain injury requiring acute surgery. *Surgical neurology international*, *8*, 141. https://doi.org/10.4103/sni.sni_453_16
10. Hashmi, S. M. M., Nazir, S., Colombo, F., Jamil, A., & Ahmed, S. (2022). Decompressive Craniectomy for the Treatment of Severe Diffuse Traumatic Brain Injury: A Randomized Controlled Trial. *Asian journal of neurosurgery*, *17*(3), 455–462. https://doi.org/10.1055/s-0042-1756636

P-30

Enhancing Cerebrovascular Bypass Training: Innovating an Affordable, Home-Made 3D Model

Manuel De Jesus Encarnacion Ramirez[1], Renat Nurmukhametov[1], Gennady Chmutin[1]

[1]RUDN university

Objectives: To introduce an easily replicable anatomically accurate brain model with major blood vessels and pulsatile blood flow.

Background: Vascular anastomosis in neurosurgery is a crucial lifesaving skill requiring intensive continuous training. This makes laboratory training an invaluable aspect of the training. However, many residents have little exposure to this training due to lack of good training models.

Method: The brain model is made using a 3D printed resin mold. The mold is filled with silicone and mixed with pigment additives to replicate the color and consistency of brain tissue. Dura is made from quick drying silicone paste with grey dye. The blood vessels are made with tool decorator 25. The vessels were made of two layers and sizes 1.0 x 70mm 1.5 x 70mm, these vessels tolerate suturing well without tearing. Liquid with Paprika oleoresin (e160c) dye is used to simulate blood and is pumped through the vessels to simulate pulsatile motion. The realization of a 3D skull allows the most realistic interaction since it adds to the surgical skills the realization of the approach and the interaction between the model of the brain, the meninges, the skull and the vessels

3d model bypass





Brain model in the mold awaiting cure time, Brain covered by dura matter. Also seen is the marking of the MMA shown by the arrow

price of material for the 3d models

Silicon Ecoflex™ 00-10 44.00 2
Kelant S400S DLP 3D printers 8.9” LCD 2K laser 3D printer
UV Resin SLA light-cure
469.00 1
Silicon DragonSkin™ 44.00 1
Anycubic photopolymer - universal WHITE resin for 3D printing,
1 LITER
26.00 1
Silicone (Tooldecor 25 23.86 1
SILICONE TOOL DECORATOR 40 23.86 1
Silicon paste coating silicone 22.00 1
Silc pink polymer paste pigment 8.00 1
Silc red polymer paste pigment 8.00 1
Silc blue polymer paste pigment 8.00 1
Silc yellow polymer paste pigment 8.00 1
Silc white polymer paste pigment 8.00 1
Automatic Dosing Pump JEBAO Automatic Water Dosing
Pump Aquarium Fish Tank Marine Reef Filtration Peristaltic
Pump
30.00 1
Plaster Bandage Cast Orthopedic Tape Cloth Gauze 2.00

price of material for the 3d models

Silicon Ecoflex™ 00-10 44.00 2
Kelant S400S DLP 3D printers 8.9” LCD 2K laser 3D printer
UV Resin SLA light-cure
469.00 1
Silicon DragonSkin™ 44.00 1
Anycubic photopolymer - universal WHITE resin for 3D printing,
1 LITER
26.00 1
Silicone (Tooldecor 25 23.86 1
SILICONE TOOL DECORATOR 40 23.86 1
Silicon paste coating silicone 22.00 1
Silc pink polymer paste pigment 8.00 1
Silc red polymer paste pigment 8.00 1
Silc blue polymer paste pigment 8.00 1
Silc yellow polymer paste pigment 8.00 1
Silc white polymer paste pigment 8.00 1
Automatic Dosing Pump JEBAO Automatic Water Dosing
Pump Aquarium Fish Tank Marine Reef Filtration Peristaltic
Pump

30.00 1
Plaster Bandage Cast Orthopedic Tape Cloth Gauze 2.00

price of material for the 3d models

Silicon Ecoflex™ 00-10 44.00 2
Kelant S400S DLP 3D printers 8.9” LCD 2K laser 3D printer
UV Resin SLA light-cure
469.00 1
Silicon DragonSkin™ 44.00 1
Anycubic photopolymer - universal WHITE resin for 3D printing,
1 LITER
26.00 1
Silicone (Tooldecor 25 23.86 1
SILICONE TOOL DECORATOR 40 23.86 1
Silicon paste coating silicone 22.00 1
Silc pink polymer paste pigment 8.00 1
Silc red polymer paste pigment 8.00 1
Silc blue polymer paste pigment 8.00 1
Silc yellow polymer paste pigment 8.00 1
Silc white polymer paste pigment 8.00 1
Automatic Dosing Pump JEBAO Automatic Water Dosing
Pump Aquarium Fish Tank Marine Reef Filtration Peristaltic
Pump
30.00 1
Plaster Bandage Cast Orthopedic Tape Cloth Gauze 2.00

price of material for the 3d models

Silicon Ecoflex™ 00-10 44.00 2
Kelant S400S DLP 3D printers 8.9” LCD 2K laser 3D printer
UV Resin SLA light-cure
469.00 1
Silicon DragonSkin™ 44.00 1
Anycubic photopolymer - universal WHITE resin for 3D printing,
1 LITER
26.00 1
Silicone (Tooldecor 25 23.86 1
SILICONE TOOL DECORATOR 40 23.86 1
Silicon paste coating silicone 22.00 1
Silc pink polymer paste pigment 8.00 1
Silc red polymer paste pigment 8.00 1
Silc blue polymer paste pigment 8.00 1
Silc yellow polymer paste pigment 8.00 1
Silc white polymer paste pigment 8.00 1
Automatic Dosing Pump JEBAO Automatic Water Dosing

Pump Aquarium Fish Tank Marine Reef Filtration Peristaltic Pump 30.00 1 Plaster Bandage Cast Orthopedic Tape Cloth Gauze 2.00

Results: The models were used by eight neurosurgery residents with prior experience in anastomosis with silicone and chicken wing models and two vascular neurosurgeons. The feedback was unanimous: the models offered a more realistic 3D experience as it was anatomical with a skull, brain, and meninges. All the participants recommended the use of this model in future trainings

practice in byoas in model

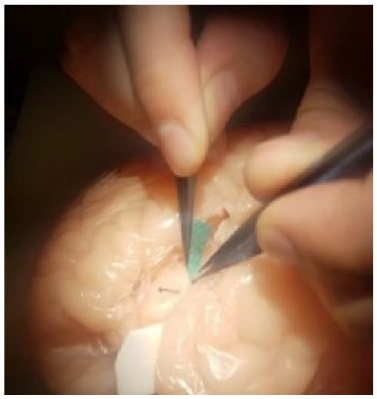
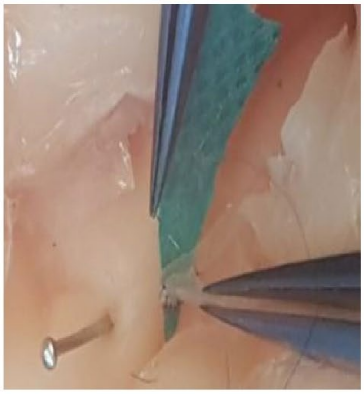
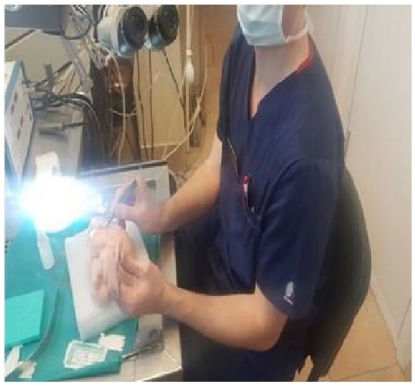

Performing dissection of the sylvian fissure, the synthetic vessel is fixed at one end to make it easier to suture it. When simulating pulsatile flow, the vessel has to be left free so as not to interrupt flow. View through a microscope: End to side bypass anastomosis using black monofilament non-absorbable polypropylene suture 10-0, A neurosurgeon demonstrating anastomosis on the brain model

Conclusions: Training of neurosurgeons in vascular anastomosis and bypass surgery remains a huge challenge. Our model offers the balance of an anatomically accurate model, affordability, replicability without the associated risks and costs associated with fresh cadavers. This model will help standardize training in this field in centers not equipped to manage fresh cadavers.

pterional approach for bypass practice



Pterional craniotomy showing the model intracranial

Keywords: 3D Model in Neurosurgery, Bypass, Neurosurgery Training, vascular neurosurgery

References

1. Aboud E, Al-Mefty O, Yaşargil MG. New laboratory model for neurosurgical training that simulates live surgery.

P-31

Comparison of Far Lateral -Extreme Lateral Approach to the Paracondylar Retrostyloid Region

Gamze Cesuroğlu , Zeynep Dağlar, Ali Karadağ , Necmettin Tanrıöver

[1]Sağlık Bilimleri Üniversitesi Tepecik Suam

Objectives: This study aims to compare the far-lateral and extreme-lateral surgical approaches to the jugular foramen (JF), an anatomically complex conduit located between the petrous part of the temporal bone and the occipital bone.

Background: Surgical access to the JF is challenging due to its close relationship with the brain stem, cerebellum, base of the skull, and neck. The far-lateral and extreme-lateral approaches provide potential pathways to the JF, but involve navigating different neurovascular structures and surgical corridors.

Method: Two cadavers (4 sides) were utilized to compare the far-lateral and extreme-lateral approaches to the JF, with each stage visualized in three dimensions

Results: Both approaches provided adequate visualization of the JF. The extreme-lateral approach, with transjugular modification, facilitated access from an anterolateral direction

Conclusions: The choice of approach to the JF should consider the surgical corridor, the size and origin of the lesion, and the anatomical compartments it involve.The JF's complexity necessitates careful selection between the far-lateral and extreme-lateral approaches. The former offers a direct route with minimized manipulation of neurovascular structures, while the latter grants extensive exposure with potentially greater risks. Each approach presents unique advantages and challenges, with the choice depending on specific anatomical and pathological considerations.

Keywords: skull base surgery, microsurgical anatomy, jugular foramen, far lateral approach

References

1. Katsuta vd. - 1997 - The Jugular Foramen Microsurgical Anatomy and Ope
2. Türe ve Pamir - 2002 - Extreme lateral—transatlas approach for resection
3. Komune vd. - 2016 - Surgical approaches to jugular foramen schwannomas

P-32

"Star Shape" Cranioplasty Via Polymethylmethacrylate

Tuychiboy Abdullaev[1], Sultan Seitnur[1], Darxan Zhetpisbayev[1]

[1]Almaty Sema Hospital

Objectives: Cranioplasty – a neurosurgical procedure to repair cranial defect after traumatic head injury, cerebrovascular disease, oncology resection and congenital anomalies. Nowadays, different bone substitutes are used either derived from biological products such as hydroxyapatite and demineralized bone matrix or synthetic ones such as sulfate or phosphate ceramics and polymer-based substitutes

Background: Considering that the choice of the best material for cranioplasty is controversial, linked to the best operation procedure, the intent of this report was to report the outcome of simplicity of intraoperation technical nuances of using polymethylmethacrylate (PMMA). The most interesting challenge is to preserve the mechanical properties while improving the bioactivity, biocompatibility, antibacterial properties, lowering thickness and most importantly lowering costs of operation. There are various materials are used as synthetic materials such as metals (titanium, tantrum etc.), ceramics (calcium phosphate, hydroxyapatite etc.) and polymers, bioactive fiber-reinforced composite, demineralized bone matrix and so on. Recently, custom-made prostheses for cranioplasty printed with three-dimensional printers are on market, but they are expensive. Among polymer materials, polymethylmethacrylate is the most motivating, due to its cost, biocompatibility, rigidity and toughness. It should be taken into consideration that each material must be selected for specific clinical use; the main limitation remains the defect size and the lack of vascularization

Method: Between 2012-2022 more than 10 patients were opereted. Intraoperatively, making some" star shape" impressions on edges of cranium defect, preparing PMMA cement a bit harder so it can be shaped in desired thickness, and closing skin flap quickly so cement takes 3D shape of defect and fits onto defect as original bone.

Results: Thereby, there is no need for fixing holes or plates. It dramatically decreases operation time, hospital expenses and increases patient wellbeing prognosis patient satisfactions.

Making an impression on skull



Cement onlayed



Conclusions: "Star shape" cranioplasty via polymethylmethacrylate is the best way of cranioplasty

Patient satisfaction



Keywords: synthetic cranioplasty, polymethylmethacrylate (PMMA), cranioplasty, cranial defect

References

1. PMID:36222944 Analysis of PMMA versus CaP titanium-enhanced implants for cranioplasty after decompressive craniectomy: a retrospective observational cohort study
2. PMID:28512612 Review of Cranioplasty after Decompressive Craniectomy
3. PMID: 33946170 State-of-Art of Standard and Innovative Materials Used in Cranioplasty

P-33

Management Of Aneurysm Associated With Moyamoya Disease: A Case Series Of 5 Patients With Literature Review

Noor ul Huda Maria[1]

[1]PINS

Objectives: To evaluate the management patients with aneurysms associated with Moyamoya Disease

Background: The treatment of aneurysms associated with moyamoya disease (MMD) is difficult for neurosurgeons, and little is known of strategy options. We are sharing our experience along with some literature

Method: We studied 5 patients with aneurysms associated with Moyamoya disease. 2 were anterior communicating artery aneurysms,1 at bifurcation of ICA and AchA,1 posterior communicating and the other one was paraclinoidal artery aneurysm.Hunt-Hess score was 3 in 4cases and was 4 in one case with anterior communicating artery aneurysm. Surgical clipping with STA-MCA anastomosis was performed in one patient with anterior communicating artery aneurysm while the other one had only clipping performed and he died on 2nd postoperative days, endovascular coiling was performed for the rest of the patients.Since the incidence of the disease is lower and aneurysms are associated in only 3-14% of patients with Moyamoya disease, thorough literature review was done and the cases were discussed with the endovascular neurointerventionists. The results were matched with case reports and case series available in literature and also with data available from other hospitals.

Results: Patients who underwent endovascular coiling had a better outcome as compared to the surgically treated group.Surgery is challenging in the case of Moyamoya disease.Many surgeons do not have enough experience to perform surgeried in cases with Moyamoya disease,many do not have experience of STA-MCA anastomsis as well. The risk of vasoconstriction is high after surgical manipulations and there can be disruption of the established collateral circulation during surgery.2 patients (both with anterior communicating artery aneurysm) were surgically treated,1 had a good recovery other died . Those patients who were treated with endovascular coiling made remarkable recovery

Conclusions: From our study we conclude that endovascular coiling is a safe and better option for patients having aneurysm associated with Moyamoya disease

Keywords: Moyamoya disease, aneurysms

References

1. Chalouhi N, Tjoumakaris S, Gonzalez L F. et al. Onyx embolization of a ruptured lenticulostriate artery aneurysm in a patient with moyamoya disease. World Neurosurg. 2013;80:436. e437-410.
2. Yang S, Yu J L, Wang H L. et al. Endovascular embolization of distal anterior choroidal artery aneurysms associated with moyamoya disease. A report of two cases and a literature review. Interv Neuroradiol. 2010;16:433–441.

P-35

Olfactory (Subfrontal) Schwannoma: Case Report and Literature Review

Agadadash Kasymov[1], Rzaev Jamil[1], Anton Kalinovsky[1], Evgeniya Voronina[1]

[1]FSBI "Federal Neurosurgical Center" Novosibirsk, Russia

Objectives: About 5.000 patients with various brain tumors underwent surgery at the Federal Center of Neurosurgery between 2012 and 2022. We report a 55-year-old patient with olfactory nerve schwannoma

Background: Cranial nerve schwannoma accounts for up to 8% of all primary brain tumors. In most cases, schwannomas are benign tumors, and relapses are extremely rare after total resection . Vestibular schwannoma is the most common in neurosurgical practice. This tumor grows from Schwann's sheath of vestibular segment of vestibulocochlear nerve. Schwannoma of trigeminal (V), facial (VII), glossopharyngeal (IX) and vagus (X) nerves is much less common. Olfactory nerve schwannomas are extremely rare. Their origin is still unclear, since olfactory nerve has no Schwann cells. About 70 patients with olfactory nerve schwannomas have been described in the world literature . There are currently no reports of samples of these patients.

Method: A 55-year-old man admitted to the Department of Neurooncology of the Federal Center of Neurosurgery. Recurrent headaches and progressive impairment of smelling persisted for previous 2 years. Contrast-enhanced MRI of the brain was performed due to progressive clinical symptoms. Extracerebral tumor of anterior cranial fossa base 34×35×35 mm with left-sided lateralization resembling meningioma of olfactory fossa was found .Considering localization, dimensions and nature of tumor, we performed lateral supraorbital craniotomy on the left and microsurgical resection of the neoplasm.

Fig.1.

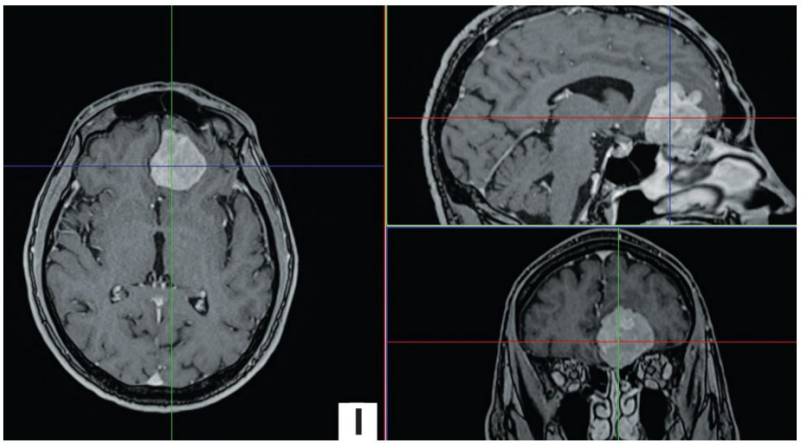

A round-shaped extracerebral neoplasm with homogeneous solid structure is visualized in olfactory fossa on the lef

Results: Immunohistochemical study revealed positive reactions on tumor cells with antibodies to S100 . Ki67 index was focally up to 1—2% .Schwannoma grade 1 (ICD-O code 9560/0) was verified considering combination of morphological and immunomorphological data

Fig.2.

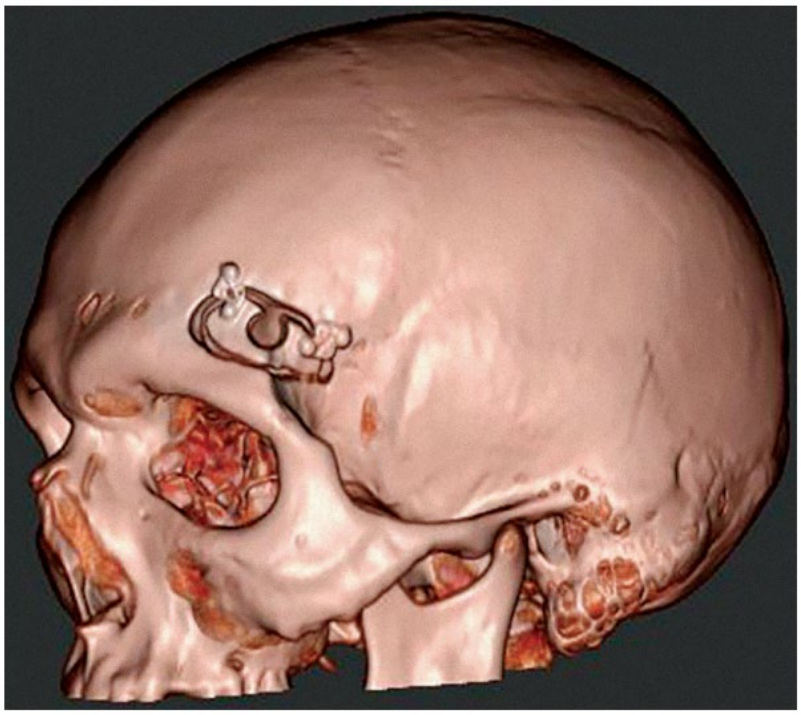

3D CT of the head. Left-sided lateral supraorbital craniotomy, bone flap is fixed with titanium plates and screws.

Fig.3.

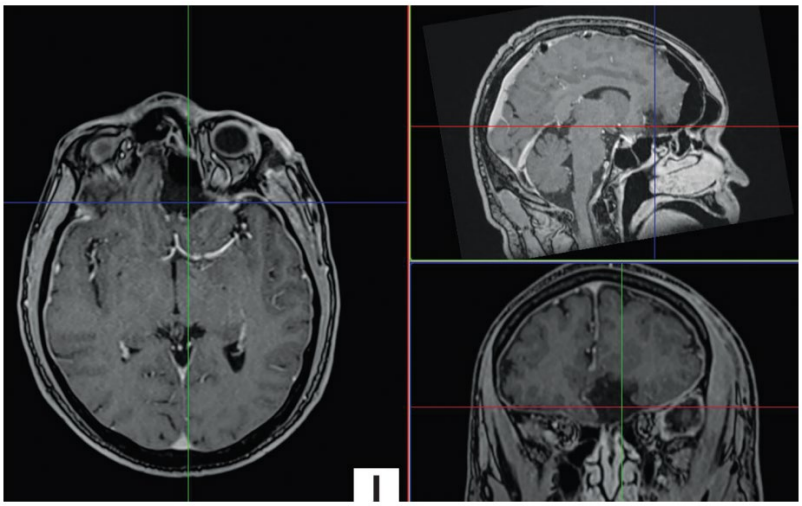

Postoperative contrast-enhanced T1WIs in axial, sagittal and coronal planes. Total resection of tumor.

Conclusions: Olfactory (subfrontal) schwannoma is a very rare benign tumor arising from olfactory nerve. At present, there are no literature data on relapses of these tumors. The risk of recurrence is unlikely after total resection. However, further analysis of this lesion and long-term postoperative follow-up data is needed

Keywords: schwannoma, olfactory nerve schwannoma, olfactory fossa, olfactory nerve

References

1. Manto A, Manzo G, De Gennaro A, Martino V, Buono V, Serino A. An enigmatic clinical entity: A new case of olfactory schwannoma. The Neuroradiology Journal. 2016;29(3):174-178. https://doi.org/10.1177/197140091559558
2. Taha MM, AlBakry A, ElSheikh M, AbdelBary TH. Olfactory Nerve Schwannoma: A Case Report and Review of the Literature. Surgery Journal. 2018;4(3):164-166. https://doi.org/10.1055/s-0038-1669991
3. Okamoto H, Mineta T, Wakamiya T, Tsukamoto H, Katsuta T, Nakagaki H, Matsushima T. Two Cases of Subfrontal Schwannoma, Including a Rare Case Located between the Endosteal and Meningeal Layers of the Dura. Neurologia Medico-Chirurgica. 2014;54(8):681-685. https://doi.org/10.2176/nmc.cr.2013-0153
4. Dabbs DG. Diagnostic immunohistochemistry: theranostic and genomic applications. 3rd ed. Philadelphia, PA: Saunders/Elsevier; 2010.
5. Louis DN, Perry A, Reifenberger G, von Deimling A, Figarella-Branger D, Cavenee WK, Ohgaki H, Wiestler OD, Kleihues P, Ellison DW. The 2016 World Health Organization Classification of Tumors of the Central Nervous System: A summary. Acta Neuropathologica. 2016;131(6):803-820. https://doi.org/10.1007/s00401-016-1545-1
6. Burger PC, Scheithauer BW. Tumors of the Central Nervous System. 2007. Accessed April 27, 2022. https://www.semanticscholar.org/paper/ Tumors-of-the-Central-Nervous System-Burger-Scheithauer/eca6d7f3cb2ca51ee397d0e0aaa450521ee35084
7. Burger PC, Scheithauer BW, eds. Neuropathology. Salt Lake City, UT: Amirsys; 2012.
8. Russell DS, Rubinstein LJ. Pathology of Tumours of the Nervous System. Williams and Wilkins, Baltimore; 1977.
9. Ogino-Nishimura E, Nakagawa T, Mikami Y, Ito J. Olfactory ensheathing cell tumor arising from the olfactory mucosa. Case Reports in Medicine. 2012;2012:426853. https://doi.org/10.1155/2012/426853
10. Mamoru M, Tetsuya T, Taketo H, Takuya N, Eiji O, Takako A. Olfactory Groove Schwannoma — case report. Neurologia Medico-Chirurgica. 2004;44(4):191-194. https://doi.org/10.2176/nmc.44.191
11. Auer RN, Budny J, Drake CG, Ball MJ. Frontal lobe perivascular schwannoma. Case report. Journal of Neurosurgery. 1982;56(1):154-157. https://doi.org/10.3171/jns.1982.56.1.0154
12. Nakayama K, Nakayama T, Matsuoka Y, Kono K. Supratentorial convexity leptomeningeal schwannoma:case report. Neurosurgery. 2002;51(5): 1295-1298. https://doi.org/10.1097/00006123-200211000-00031
13. Yamahata H, Hirahara K, Tomosugi T, Yamada M, Ishii T, Ishigami T, Uetsuhara K, Sueyoshi K, Matsukida S, Yatsushiro K, Arita K. Subfrontal schwannoma mimicking neuroblastoma: Case report. Skull Base Reports. 2011;1(1):59-64. https://doi.org/10.1055/s-0031-1275637
14. Li YP, Jiang S, Zhou PZ, Ni YB. Solitary olfactory schwannoma without olfactory dysfunction: A new case report and literature review. Neurological Sciences. 2012;33(1):137-142. https://doi.org/10.1007/s10072-011-0573-9
15. Bezircioglu H, Sucu HK, Rezanko T, Minoglu M. Nasal-subfrontal giant schwannoma. Turkish Neurosurgery. 2008;18(4):412-414. 16. Carron JD, Singh RV, Karakla DW, Silverberg M. Solitary schwannoma of the olfactory groove: Case report and review of the literature. Skull Base. 2002;12(3):163-166. https://doi.org/10.1055/s-2002-33463-1

P-36

Extraordinary Cranial Trauma

Rümeysa Karaçuha Sürücü[1], Ahmet Karkucak[2], Asuman Mehel[1]

[1]Samsun University, Samsun Training and Research Hospital, Department of Anesthesiology and Reanimation
[2]Samsun Büyük Anadolu Hospital, Neurosurgery

Objectives: Penetrating head trauma is trauma that penetrates directly into the brain tissue by crossing the bones of the scalp and cranium. They are usually serious and life-threatening traumas and require immediate medical treatment.

Background: With the knowledge that a 16-year-old male patient would be sent from the emergency department for surgery due to penetrating head trauma (figure 1), blood requests were made and crystalloid and colloid solutions and infusion pumps were prepared.

Figure 1

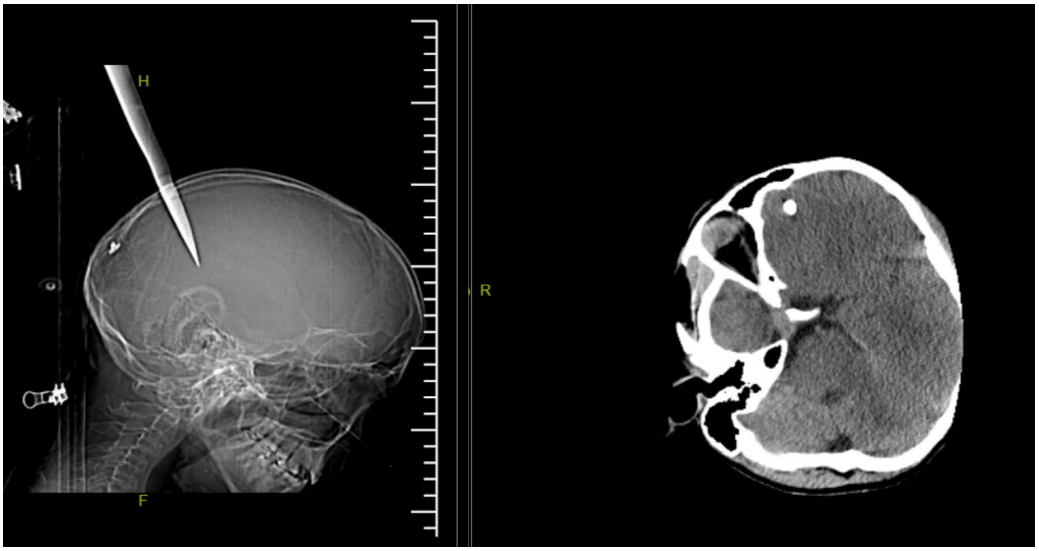

Preoperative Cerebral CT

Method: The patient, who had a knife stuck in the right parietal bone, was brought to the operating room with head-neck stabilization provided. Preoxygenation was applied during ECG, NIBP and sPO2 monitoring. Wide vascular access and invasive arterial monitoring were provided preoperatively. Thiopental sodium, rocuronium, lidocaine were administered for the induction of anesthesia. While the cutting tool and cranium were fixed by the neurosurgeon, endotracheal intubation was performed and mechanical ventilation was started. The patient was ventilated with end-tidal CO2 of 30-35 mmHg. Sevoflurane and Remifentanil were used for maintenance of anesthesia. The head fixation of the patient was continued and turned to the prone position (figure 2). The parietal bone was removed all around with the cutting tool (figure 3). After drainage of intracerebral hematoma, bone and subcutaneous-skin were closed. Hemodynamics remained stable in the operation, which lasted approximately 1.5 hours. He was awakened in the supine position and extubated.

Figure 2



The patient in prone position

Figure 3



Knife removed with parietal bone

Results: He was transferred to the ICU for postoperative follow-up. No neurological or hemodynamic complications occurred in the follow-ups here. After CT control on the 1st postoperative day, he was transferred to the service on the 2nd postoperative day.

Conclusions: Although the treatment may vary depending on the depth and damage of penetrating head trauma, it usually requires urgent surgical treatment. In addition to surgical treatment, a multidisciplinary approach is important in providing antibiotic therapy and supportive treatment.

Keywords: cranial trauma, penetrating head trauma

References

1. Koestler J, Keshavarz R. Penetrating head injury in children: a case report and review of the literature. The Journal of Emergency Medicine, 2001 August; 21 (2), 145-150.
2. Alao T, Waseem M. Penetrating head trauma. Stat Pearls (Internet), 2022-ncbi.nlm.nih.gov.
3. Tshering U, Kohli E. Penetrating head trauma. J Am Coll Emerg Physicians open. 2022 Feb; 3 (1):e12626.

P-37

Optic Foraminotomy Versus Anterior Clinoidectomy for Small Superior-Projecting Paraclinoid Aneurysms: Visual and Angiographic Outcome Evaluation

Sabino Luzzi[1], Alice Giotta Lucifero[1], Matias Baldoncini[3], Alvaro Campero[4], Renato Galzio[5], Micheal Lawton[6]

[1]Department of Clinical-Surgical, Diagnostic and Pediatric Sciences, University of Pavia, Pavia, Italy
[2]Neurosurgery Unit, Department of Surgical Sciences, Fondazione IRCCS Policlinico San Matteo, Pavia, Italy
[3]Department of Neurological Surgery, San Fernando Hospital, Buenos Aires, Argentina; Laboratory of Microsurgical Neuroanatomy, School of Medicine, University of Buenos Aires, Buenos Aires, Argentina.
[4]Department of Neurological Surgery, Padilla Hospital, Tucumán, Argentina.
[5]Neurosurgery Unit, Maria Cecilia Hospital, Cotignola, Italy.
[6]Department of Neurosurgery, Barrow Neurological Institute, Phoenix, Arizona, USA.

Objectives: In this study, OF and AC were compared for small superior-projecting paraclinoid aneurysms assuming visual and angiographic results as outcome measures. Indications for OF are also discussed.

Background: Optic foraminotomy (OF) has been recently proposed as an alternative to anterior clinoidectomy (AC) for selected types of paraclinoid aneurysms.

Method: Data of patients who underwent surgery for a paraclinoid aneurysm in the last 10 years were collected across 3 tertiary hospitals. Small to regular-size and superior projecting aneurysms were sorted. Multiple and complex aneurysms were excluded. Records of patients who went through OF were compared with those of patients who underwent AC. Neurologic outcome was reported as a modified Rankin Scale. Aneurysm complete occlusion rate and rate of approach-related worsened vision were selected as outcome measures of efficacy and safety, respectively, of the OF versus AC. Unpaired t test and $\chi 2$ test were used for numerical and categorical variables, respectively. A P value less than 0.05 was considered statistically significant.

Results: OF and AC groups involved 18 and 25 patients, respectively. Complication rate, overall neurologic outcome, rate of approach-related worsened vision, and complete occlusion rate did not differ between the groups. The average follow-up was 51 ± 34 and 60 ± 41 months in the OF and AC groups, respectively.

Conclusions: Compared to AC, OF did not show either a higher rate of approach-related worsened vision or a lower aneurysm complete occlusion rate. OF can be considered a valid alternative to the AC for small superior-projecting dorsal ICA wall paraclinoid aneurysms.

Keywords: anterior clinoidectomy, skull base, ophthalmic aneurysms, paraclinoid region

References

1. Luzzi S, Giotta Lucifero A, Baldoncini M, Campero A, Galzio R, Lawton MT. Optic Foraminotomy versus Anterior Clinoidectomy for Small Superior-Projecting Paraclinoid Aneurysms: Visual and Angiographic Outcome Evaluation. World Neurosurg. 2023 Feb;170:e612-e621. doi: 10.1016/j.wneu.2022.11.081.
2. Baldoncini M, Luzzi S, Giotta Lucifero A, Flores-Justa A, González-López P, Campero A, Villalonga JF, Lawton MT. Optic Foraminotomy for Clipping of Superior Carotid-Ophthalmic Aneurysms. Front Surg. 2021 Dec 9;8:681115. doi: 10.3389/fsurg.2021.681115.

P-38

Project AENEAS: Machine Vision for Real-Time Intraoperative Anatomic Guidance during Endoscopic and Microscopic Neurosurgery

Victor Staartjes[1], Gary Sarwin[2], Alessandro Carretta[1], Matteo Zoli[3], Diego Mazzatenta[3], Luca Regli[1], Carlo Serra[1], Ender Konukoglu[2]

[1]Department of Neurosurgery, University Hospital Zurich
[2]Computer Vision Lab, ETH Zurich, Switzerland
[3]Department of Biomedical and Neuromotor Sciences (DIBINEM), University of Bologna, Bologna, Italy

Objectives: - To understand the limitations of current technological adjuncts to guidance in neurosurgery, such as neuronavigation- To understand how machine vision-based anatomical guidance can assist neurosurgeons during endoscopic and microscopic procedures

Background: Current intraoperative orientation methods either rely on preoperative imaging, are resource-intensive to implement, or difficult to interpret. Real-time, reliable anatomic recognition would constitute another strong pillar on which neurosurgeons could rest for intraoperative orientation.

Method: First, we report the performance of a deep learning-based object detection method, YOLO, on detecting anatomical structures in neurosurgical images. Second, we present a method for generating neurosurgical roadmaps using unsupervised embedding without assuming exact anatomical matches between patients, presence of an extensive anatomical atlas, or the need for simultaneous localization and mapping. We trained and evaluated the proposed method with a data set of endoscopic transsphenoidal adenomectomy procedures, as well as a set of microsurgical retrosigmoid approaches.

Simplified representation of the suggested approach.

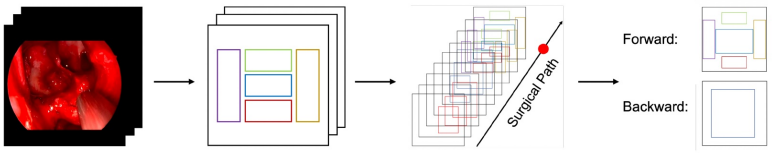

1. A sequence of input images is processed to detect bounding boxes of anatomical structures. 2. A neural network encodes the sequence of detections into a latent variable that correlates with the position along the surgical path. 3. Given the current position along the surgical path, an estimation of anatomical structures in the forward or backward directions can be obtained, by extrapolating the current value of the latent variable.

Results: A generated roadmap encodes the common anatomical paths taken in surgeries in the training set. At inference, the roadmap can be used to map a surgeon's current location using live image feedback on the path to provide guidance by being able to predict which structures should appear going forward or backward, much like a mapping application. Even though the embedding is not supervised by position information, we show that it is correlated to the location inside the brain and on the surgical path.

The normalized generated confidences of each class along the latent space.

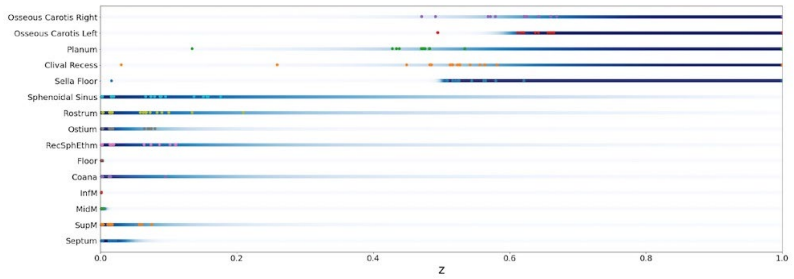

This visualizes the probability of finding a certain anatomical structure at a specific point in the latent space. Additionally, video frames of twenty test videos responsible for the first appearances of anatomical structures in every video have been encoded and overlaid onto the confidence intervals to demonstrate that their locations correlate with the beginning of these intervals.

Conclusions: Automated recognition of anatomic structures in endoscopic or microscopic videos by means of a machine vision model using only the endoscopic camera without prior explicit anatomo-topographic knowledge is feasible. This proof of concept encourages further development of fully automated software for real-time intraoperative anatomic guidance during surgery.

Keywords: MICRONEUROSURGERY, MACHINE LEARNING, Machine Vision, Neuroanatomy

References

1. Staartjes, V.E., Volokitin, A., Regli, L., Konukoglu, E., Serra, C.: Machine Vision for Real-Time Intraoperative Anatomic Guidance: A Proof-of-Concept Study in Endoscopic Pituitary Surgery. Operative neurosurgery (Hagerstown, Md.) 21(4), 242–247 (10 2021)
2. Ruzevick, J., Strickland, B., Zada, G: (2021). Commentary: Machine Vision for Real-Time Intraoperative Anatomic Guidance: A Proof-of-Concept Study in Endoscopic Pituitary Surgery. Operative Neurosurgery. 21. 10.1093/ons/opab203.

P-39

The Anatomical Laboratories in Neurosurgical Hospital: 10-Years' Siberian Experience

Jamil Rzaev[1]

[1]The Federal Neurosurgical Center

Objectives: To analyze organization of anatomical laboratories in the neurosurgical hospital.

Background: Annually in hospital has been performed 4500 procedures in Pediatric, Spinal, Neurovascular, Neurooncological and Functional Neurosurgery Division.The hospital staff, residents and medical students didn't have a regular possibility to practice microdissection in the Anatomic Department of the local University. That's why all the efforts were made to create and equip rooms where it could be possible to provide the anatomical dissection.

Method: In 2014 the first laboratory was launched. The nickname of this facility stands on MDV (microsuture, drilling and vets). In 2016 a CDS lab (Cadaver, Dissection & Skull base) was opened. In 2017 the Spinal lab providing possibility of safety usage of X-ray was opened. Laboratory equipment includes the following devices:•17 microscopes;•10 motor systems;•11 endoscopic settings;•10 suckers;•C-arm;•Navigation station;•X-ray transparent tables;•Head-holders;•Tool sets;•Disposable material.

Results: So-called "anatomical group" consisting of experienced neurosurgeons was organized for better control the laboratory functioning. 63 educational courses for specialists from other medical institutions lasting from 2 till 5 days were held during the period from January 2014 till May 2013.•Microsuture – 15•Drilling – 9•Drilling courses for scrub-nurses – 3•White matter dissection – 6•Endoscopic– 7•Spinal instrumentalization – 8•Skull-base approaches – 3•Botulin therapy (mimic muscles) – 2•Brain and Spine Tumors – 3•Temporal Bone Dissection - 2•Olympics (for medical students and junior residents) – 5

Conclusions: it should be noted that all the staff of the hospital could take part in the laboratory activities. Organization of practical laboratories for training manual skills is possible even in the absence of possibilities to work in university clinic.

Keywords: anatomical dissection, drilling, microsuture, cadaver heads

P-40

The Anatomy of Sylvian Fissure and Clipping of MCA Aneurisms For Young Neurosurgeons

Robert Shumkovski[1], Ivica Kocevski[1]

[1]Clinic for neurosurgery, University clinical center Mother Teresa, Skopje, N. Macedonia

Objectives: To elaborate and review the anatomy of the Sylvian fissure, and to discuss one of the most important and fundamental microsurgical skills, which is safe dissection and opening of the Sylvian fissure, relevant to MCA aneurisms.

Background: One of the fundamental microsurgical skills for neurosurgeons is the Sylvian fissure dissection. As a technique, it is of vital importance in order to avoid brain transgression when operating on vascular pathology, but is also relevant for skull bas access for different pathologies. The skills, dexterity and ease to properly dissect the Sylvian fissure have an evident learning curve.

Method: In this presentation we review the anatomy of the Sylvian fissure and present the different types, orientation and anatomical characteristics of microsurgical significance, important for MCA aneurisms. Also a review is presented on different styles and techniques for Sylvian fissure split.

Results: Although the major components defining the Sylvian fissure are somewhat constant, there is still a number of possible variations, including arteries, veins, arachnoid membranes, giral interdigitations, Sylvian fissure length and orientation, which make every Sylvian fissure unique. Here we review the different techniques for Sylvian fissure split, and offer some tips to young neurosurgeons in order to ease this sometimes difficult and demanding technique. However, this surgical technique requires meticulous dissection in all stages of the surgery.

sylvian fissure disection

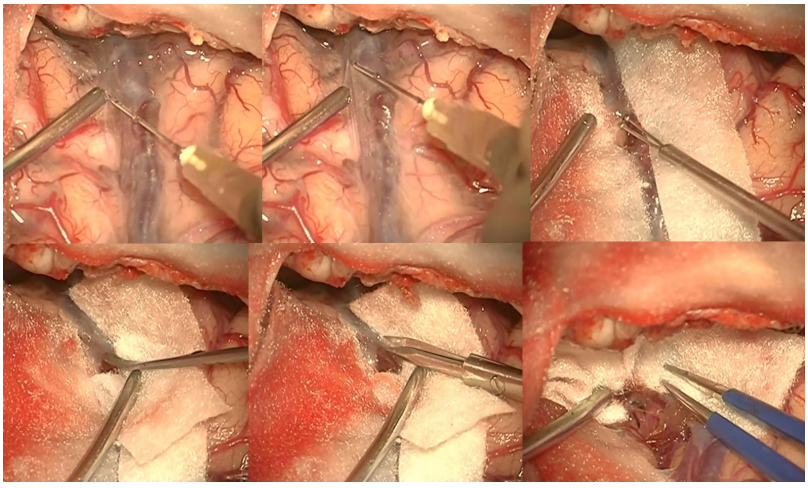

beginning of sylvian fissure disection

sylvian fissure disection 2

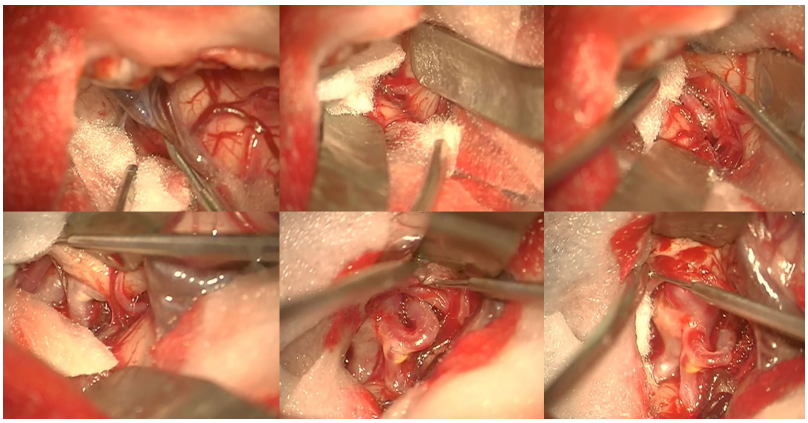

sylvian fissure opening and dissection, identification of MCA distal branches

sylvian fissure disection 3

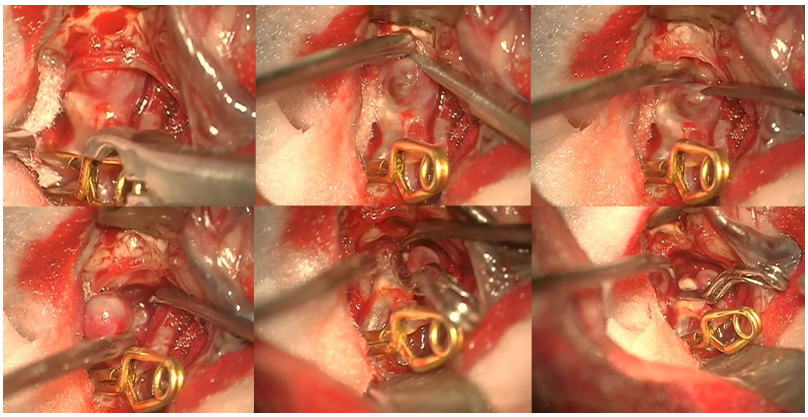

sylvian fissure dissection, aneurysm dissection and clipping

Conclusions: From a neurosurgical stand point, anatomical knowledge is of paramount importance and should enhance the success of the surgery. The Sylvian fissure and the Sylvian cistern have unique anatomical, vascular, and genotypical properties to the other areas of the cerebrum, making them complex, unique and special.

Keywords: cerebral aneurysm, Sylvian fissure, MCA aneurysms, Middle cerebral artery

References

1. Başkaya, Mustafa K; Coscarella, Ernesto; Tummala, Ramachandra P; Jea, Andrew; Heros, Roberto C. Surgical Management of Middle Cerebral Artery Aneurysms: Surgical Anatomy, Approaches, and Pitfalls. Neurosurgery Quarterly 15(4):p 201-210, December 2005. | DOI: 10.1097/01.wnq.0000190401.31517.33
2. Guner, Y.E., Salman, N., Gungor, Y. et al. The microanatomy of the Sylvian fissure. Childs Nerv Syst 39, 67–72 (2023). https://doi.org/10.1007/s00381-022-05682-6
3. Joo SP, Jung SH, Kim SH, Kim TS. Correct Plane of the Sylvian Vein Dissection for Middle Cerebral Artery Aneurysm Using Indocyanine Green Videoangiography. World Neurosurg. 2017 Jan;97:453-458. doi: 10.1016/j.wneu.2016.09.128. Epub 2016 Oct 11. PMID: 27742507.
4. Maekawa H, Hadeishi H. Venous-Preserving Sylvian Dissection. World Neurosurg. 2015 Dec;84(6):2043-52. doi: 10.1016/j.wneu.2015.07.050. Epub 2015 Jul 29. PMID: 26232211.
5. Martinez-Perez, R., Beer-Furlan, A., Albonette-Felicio, T. et al. The transsylvian corridor through minimally invasive transcranial approaches: a comparative anatomical study. Neurosurg Rev 44, 2619–2627 (2021). https://doi.org/10.1007/s10143-020-01439-4
6. Muhammad, S., Tanikawa, R., Lawton, M. et al. Microsurgical dissection of Sylvian fissure—short technical videos of third generation cerebrovascular neurosurgeons. Acta Neurochir 161, 1743–1746 (2019). https://doi.org/10.1007/s00701-019-03999-x
7. Park HW, Chung SY, Park MS, Kim SM, Yoon BH, Kim HK. Two indices affecting the directions of the sylvian fissure dissection in middle cerebral artery bifurcation aneurysms. J Cerebrovasc Endovasc Neurosurg. 2013 Sep;15(3):164-70. doi: 10.7461/jcen.2013.15.3.164. Epub 2013 Sep 30. PMID: 24167795; PMCID: PMC3804653.
8. Rhoton AL Jr: Anatomy of saccular aneurysms. Surg Neurol 14:59–66, 1980.
9. Rhoton AL Jr. Aneurysms. Neurosurgery. 2002 Oct;51(4 Suppl):S121-58. PMID: 12234448.
10. Rhoton AL Jr: The cerebellar arteries. Neurosurgery 47[Suppl 1]:S29–S68, 2000.
11. Rhoton, Albert L. Jr. M.D.. THE CEREBRUM. Neurosurgery 61(1):p SHC-37-SHC-119, July 2007. | DOI: 10.1227/01.NEU.0000255490.88321.CE
12. Rhoton AL Jr, Saeki N, Perlmutter D, Zeal A: Microsurgical anatomy of common aneurysm sites. Clin Neurosurg 26:248–306, 1979.
13. Tanriover N, Rhoton AL Jr, Kawashima M, Ulm AJ, Yasuda A. Microsurgical anatomy of the insula and the sylvian fissure. J Neurosurg. 2004 May;100(5):891-922. doi: 10.3171/jns.2004.100.5.0891. PMID: 15137609.
14. Tayebi Meybodi A, Borba Moreira L, Gandhi S, Preul MC, Lawton MT. Sylvian fissure splitting revisited: Applied arachnoidal anatomy and proposition of a live practice model. J Clin Neurosci. 2019 Mar;61:235-242. doi: 10.1016/j.jocn.2018.10.088. Epub 2018 Nov 13. PMID: 30446363.
15. Wen HT, Rhoton AL Jr, de Oliveira E, Castro LH, Figueiredo EG, Teixeira MJ. Microsurgical anatomy of the temporal lobe: part 2--sylvian fissure region and its clinical application. Neurosurgery. 2009 Dec;65(6 Suppl):1-35; discussion 36. doi: 10.1227/01.NEU.0000336314.20759.85. PMID: 19934983.
16. Yasargil MG (ed) Microneurosurgery, vol I., Georg Thieme Verlag, New York, pp 217–220, 1984.

P-41

A Simple Method for Reconstruction of Temporal Muscle After Interfascial Dissection

Busra AKTAS[1], Mehmet Ali KAHRAMAN[1], Muhammed Emin AKSU[1], Mehmet Sabri GURBUZ[1]

[1]Medeniyet University, Goztepe Prof. Dr. Suleyman Yalcin City Hospital

Objectives: Yasargil's technique temporal muscle (TM) requires piercing the superior temporal line (STL) using a craniotome and suturing the temporal muscle (TM) to these holes. Because it is difficult topierce the bone at the level of STL, we describe a simple technique that includes reattachment of the TM to the mini-plates with no necessity of piercing the bone flap.

Background: Interfascial dissection of the TM, an essential step of the pterional craniotomy, was described by Yasargil in 1984. The goal of this technique is to preserve the frontalis branch of the facial nerve. Although this technique has been used worldwide since then, there are some difficulties in reconstructing the TM. One technique is complete detachment of the muscle followed by suturing the muscle to the STL. Another is leaving a muscle cuff on the STL and suturing the muscle to this cuff at the end of the procedure.

Method: Thirteen patients were operated via pterional approach using inter fascial dissection. We applied all the steps introduced by Yasargil and detached the TM completely from the STL. Craniotomy flap was replaced using mini-plates and screws. Mini-plates were placed close to the STL. Utilizing the close proximity of STL to the upper border of craniotomy, we sutured the TM fascia to these mini-plates on the frontal site of the craniotomy. In this way, one can both preserve the integrity of TM and thus, prevent the muscle atrophy and avoid extra bone work.

Figure 1: Reconstruction of the Temporal Muscle

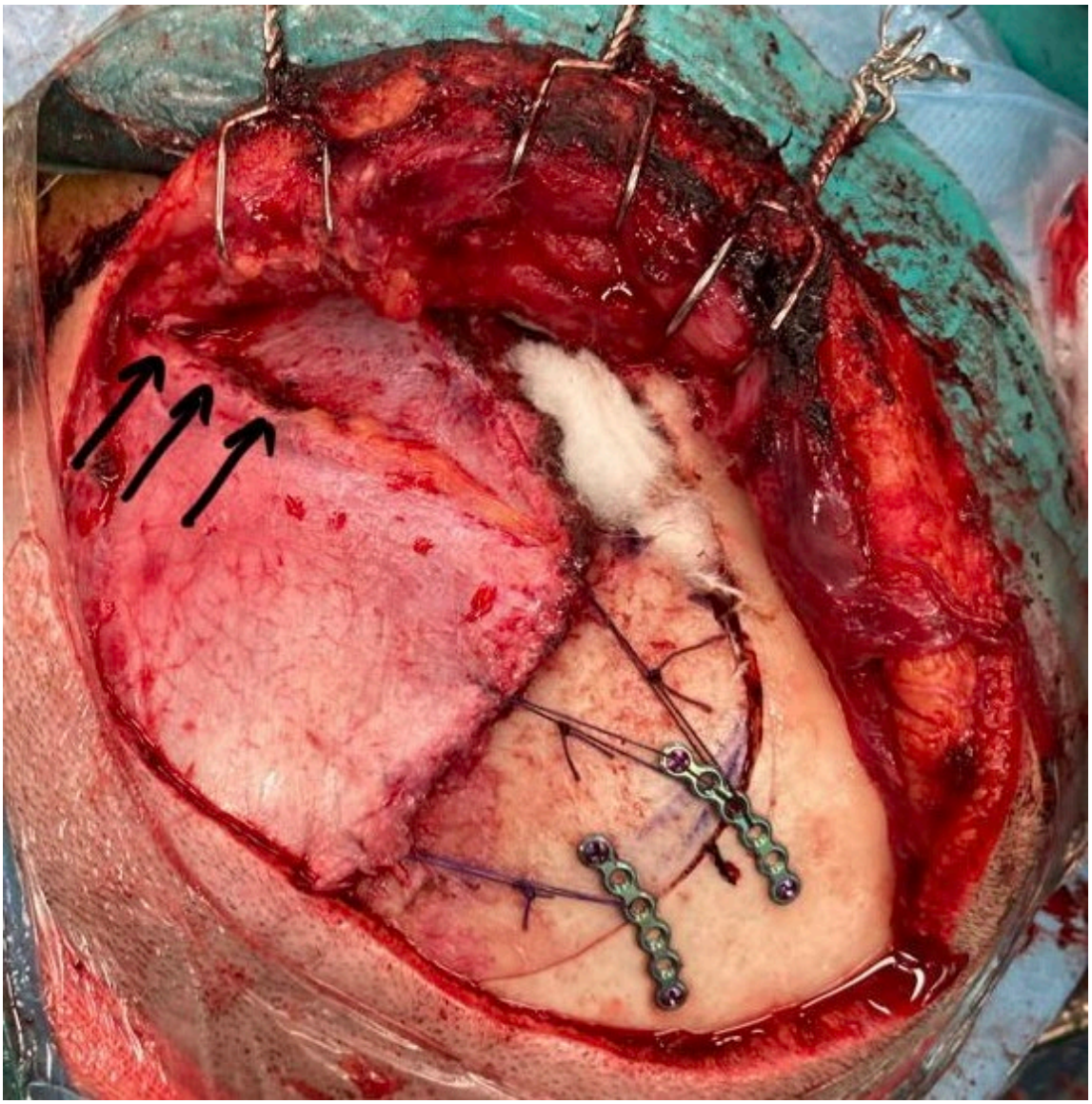

Peroperative picture reveals reconstruction of the temporal muscle by suturing the temporal muscle fascia to mini-plates. Black arrows show the site of the incision of superficial layer of superficial temporal fascia.

Results: We had temporary frontal branch palsy only in our first two patients. Both patients completely recovered their palsy at the end of the third month of the operation.

Figure 2: Temporary Paralysis of Frontal Branch of Facial Nerve in First Two Patients of our Series



In both patients, sequential recovery of the frontal branch of facial nerve is seen on; A) Early post-operative B) 6 Week post-operative C) 3 Month post-operative pictures.

Conclusions: Our technique is a safe and easy way to reattach the muscle to the STL with preserving the integrity of TM and acceptable cosmetic results.

Keywords: Interfascial dissection, Temporal muscle, Palsy, Frontal branch of facial nerve

References

1. 1.Yasargil MG, Reichman MV, Kubik S. Preservation of the frontotemporal branch of the facial nerve using the interfascial temporalis flap for pterional craniotomy. Technical article. J. Neurosurg. 1987; 67 (3):463-466
2. 2.Yasargil MG. General Operative techniques. In: Yasargil MG, ed. Microneuro-surgery. Vol. 1 Stuttgart: Georg Thieme Verlag; 1984:218.
3. 3.Poplete T, Jiang X, Komune N, Matsushima K, Rhoton AL Jr. Preservation of the nerves to the frontalis muscle during pterional craniotomy. J Neurosurg. 2015; 122(6): 1274-1282.
4. Ammirati M, Spallone A, Ma J, Cheatham M, Becker D. Preservation of the temporal branch of the facial nerve in pterional-transzygomatic craniotomy. Acta Neurochir (Wien). 1994; 128 (1-4): 163-165.

P-42

Feasibility of Awake Brain Tumor Surgery in Low and Middle Income Countries. Case report.

Dilshod Mamadaliev[1], Ulugbek Asadullaev[1], Jakhongir Yakubov[1], Gayrat Kariev[1], Kamoliddin Zokirov[1]

[1]Republican Scientific-Practical Medical Center of Neurosurgery

Objectives: to share our experiences of a simplified protocol of awake craniotomy in a limited financial setting.

Background: Awake brain tumor surgery is becoming desirable in low and middle-income countries, which may be explained by as its significant impact on diminishing of patient's postoperative neurological complications, reduced healthcare expenditures and shorter hospital stay in the postoperative period. Hereby we would like to share our initial experience of simplified awake surgery.

Method: These are the analysis of 25 patients with the diagnosis of tumor of left fronto-temporal region of the left cerebral hemisphere that were operated using awake surgery in our neurosurgical center in Tashkent, Uzbekistan in 2022-2023years. Preoperatively patients were carefully selected utilizing established criteria for awake surgery as well as neuropsychologically testing. Intraoperatively using minimum set of basic microsurgical instruments and neurophysiological monitoring technique for direct electrical stimulation.

Pre and postoperative MRI/CT

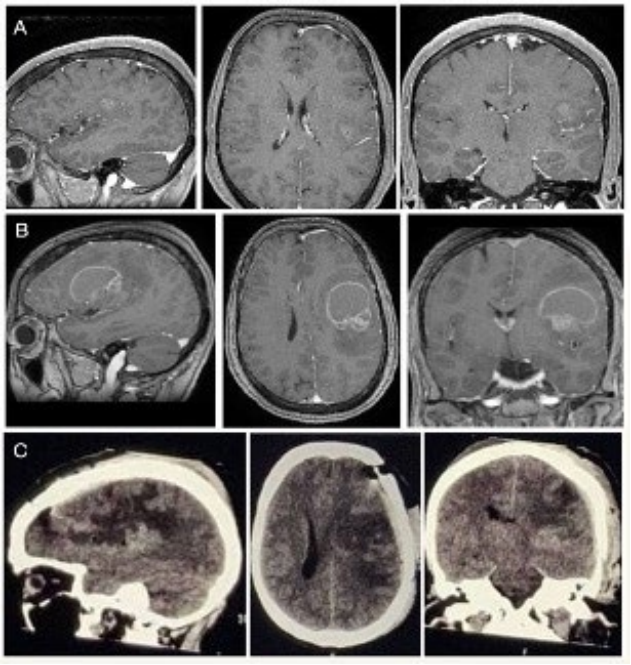

A. First MRI after having chemotherapy with temozolomide. Axial and sagittal MRI sequences on FSPGR (fast spoiled gradient echo) detected 17x14mm hyperintense lesion on

posterior parts of the inferior frontal gyrus of frontotemporal area of the left hemisphere. B. Preoperative MRI from May 29, 2021. showing progressive tumor growth and marked pertitumorous edema causing a brain shift to 9. 6mm. MRI showing active growth of the tumor with large cystic component, causing midline shift and mass effect. C. Early postoperative CT depicts remnants of the tumor in the periinsular area and slight brain edema of tumor bed.

Results: Anesthesia and awake procedure were carried out without complications in 23 cases. 2 case were unsuccessful because of the anxiety of the patients that occurred during awakening phase. There weren't used any auxiliary methods like intraoperative MRI, EEG or neuronavigation because of the limited resources of the OR settings in the country.

postoperative diagnostics

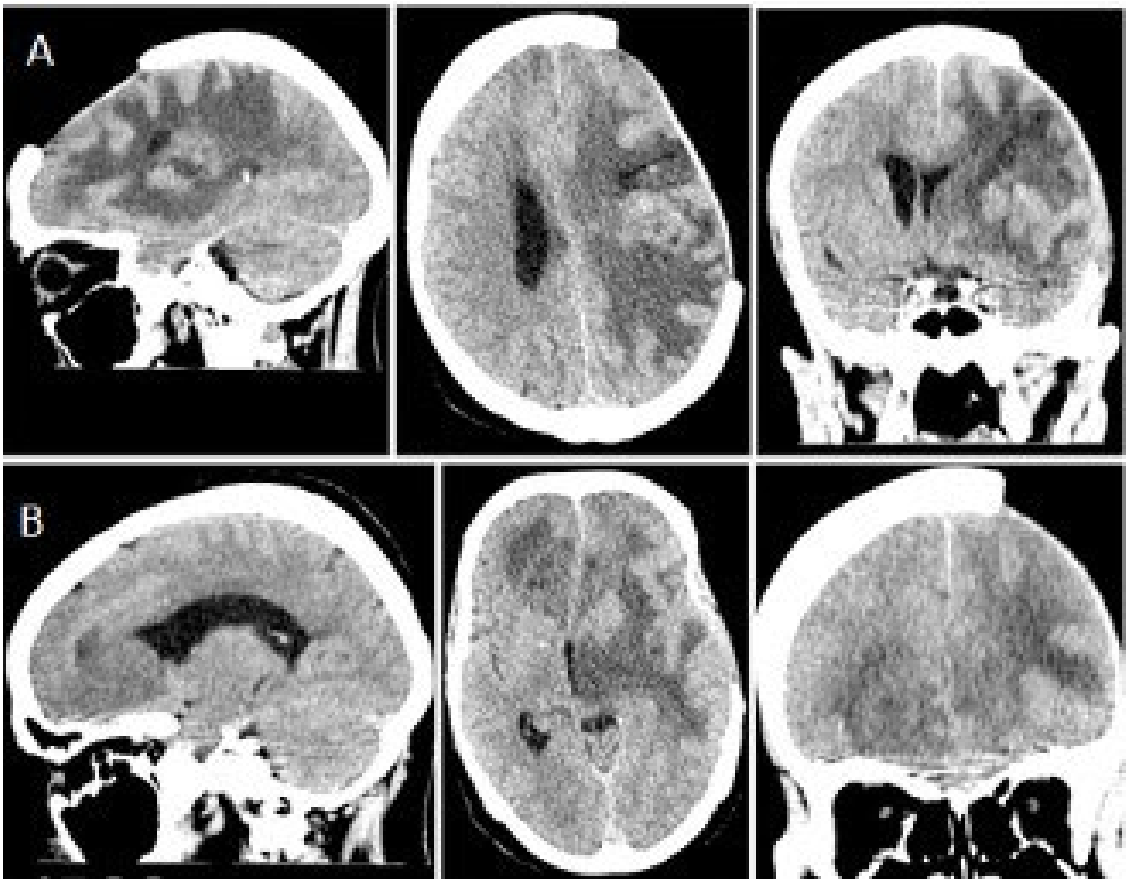

Figure 3. A.B. CT after performing decompressive craniectomy of the left frontotemporal region. Hyperdensity areas of left fronto-temporal lobes shows persisting ischemic changes.

follow up postoperative MRI

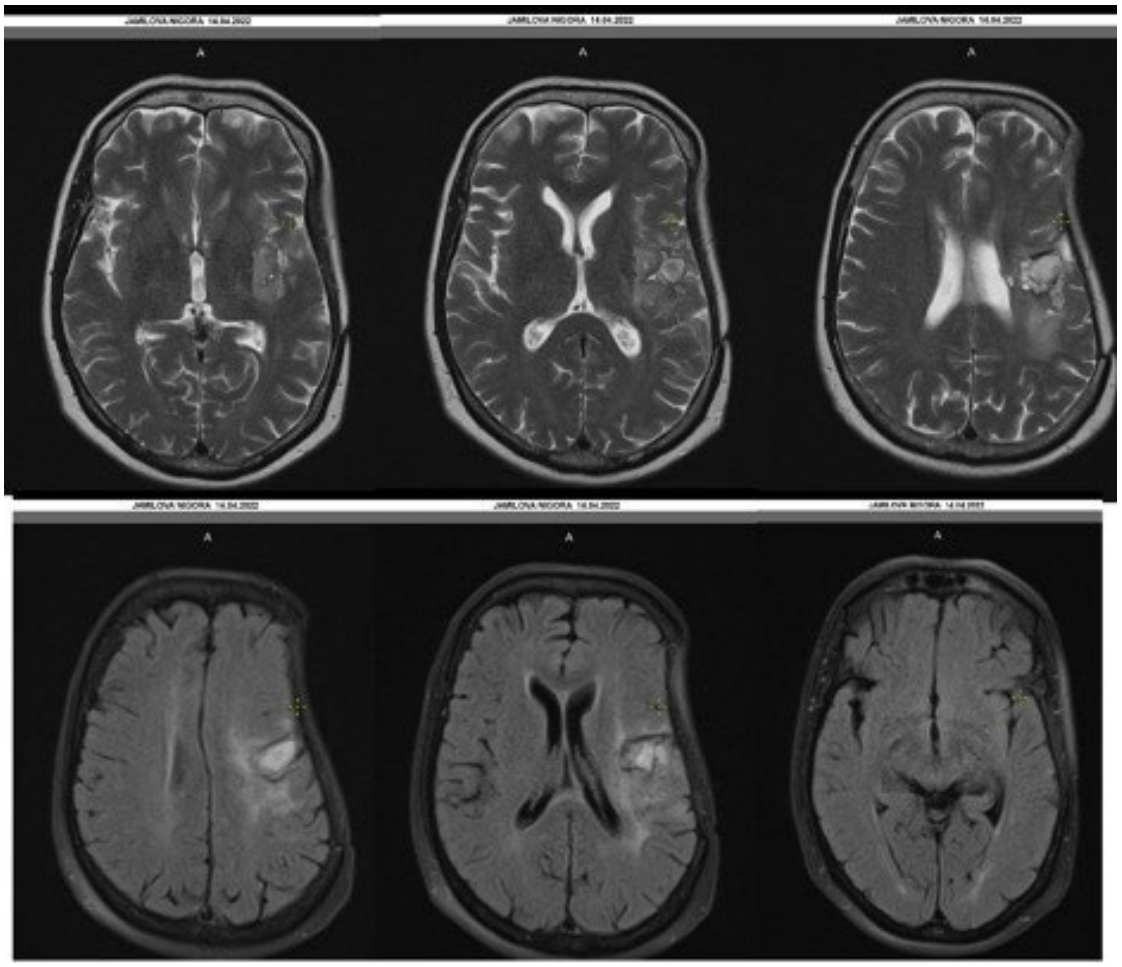

Follow-up MRI 11 months later (14.04.2022) after adjuvant chemotherapy. Axial T1 and T2WI shows a remnant of the tumor decreased significantly.

Conclusions: Awake craniotomy with intraoperative brain mapping is a perfect solution to avoid postoperative neurological deficit of the eloquent brain areas. Although Intraoperative anatomical data could be provided by the neuronavigation and iMRI, these settings are not mandatory to perform qualified awake surgery in limited resource settings of LMIC and in our view it has no significant affect to feasibility and safety of the intended method of treatment. Providing qualified functional data by intraoperative direct electrical cortical stimulation and awake cognitive testing can serve as the basic fundamental control method of awake surgery.

Keywords: awake craniotomy, brain mapping, brain tumors.

References

1. July J, Manninen P, Lai J, Yao, Bernstein M. The history of awake craniotomy for a brain tumor and its spread into Asia. *SurgNeurol.* 2009;71(51):621–624. doi: 10.1016/j.surneu.2007.12.022 . [PubMed] [GoogleScholar]
2. Duffau H, Gatignol P, Mandonnet E, Peruzzi P, Tzourio-Mazoyer N, Ca- pelle L. New insights into the anatomo-functional connectivity of the semantic system: a study using cortico-subcortical electrostimulations. Brain. 2005;128:797-810. doi: 10.1093/brain/awh423.
3. Wan Hassan WM. The history of awake craniotomy in hospital universitisainsmalaysia. Malays J MedSci. 2013 Oct;20(5):67-9. PMID: 24643321; PMCID: PMC3957358.
4. Kaewborisutsakul, A., Sae-heng, S., Kitsiripant, C., &Benjhawaleemas, P. (2019). The First Awake Craniotomy for Eloquent Glioblastoma in Southern Thailand. *JournalofHealthScienceand Medical Research*.
5. Bonhomme V, Franssen C, Hans P. Awake craniotomy. *Eur J Anaesthesiol.* 2009;26(11):906–912. doi: 10.1097/EJA.0b013e32833000c5 . [PubMed] [GoogleScholar] [Reflist]
6. Mamadaliev D.M, Kariev G.M, Asadullaev U.M., etal. Awake Brain Surgery. Neurosurgical and Anesthesiological Aspects. Problems of biology and medicine; 2021. Samarkand, Uzbekistan. №6 (132): 234-239.
7. Axelson HW, Latini F, Jemstedt M, Ryttlefors M, Zetterling M. Continuous subcortical language mapping in awake glioma surgery. FrontOncol. 2022 Aug 12;12:947119. doi: 10.3389/fonc.2022.947119. PMID: 36033478; PMCID: PMC9416475.
8. Motomura K, Fujii M, Maesawa S, Kuramitsu S, Natsume A, Wakabayashi T. Association of dorsal inferior frontooccipital fasciculus fibers in the deep parietal lobe with both reading and writing processes: a brain mapping study. J Neurosurg. 2014 Jul;121(1):142-8. doi: 10.3171/2014.2.JNS131234. Epub 2014 Mar 21. PMID: 24655122
9. Motomura K, Terasawa Y, Natsume A, Iijima K, Chalise L, Sugiura J, Yamamoto H, Koyama K, Wakabayashi T, Umeda S. Anterior insular cortex stimulation and its effects on emotion recognition. BrainStructFunct. 2019 Jul;224(6):2167-2181. doi: 10.1007/s00429-019-01895-9. Epub 2019 Jun 5. PMID: 31168738
10. Motomura K, Chalise L, Ohka F, Aoki K, Tanahashi K, Hirano M, Nishikawa T, Yamaguchi J, Shimizu H, Wakabayashi T, Saito R. Impact of the extent of resection on the survival of patients with grade II and III gliomas using awake brain mapping. J Neurooncol. 2021 Jun;153(2):361-372. doi: 10.1007/s11060-021-03776-w. Epub 2021 May 19. PMID: 34009509.

P-43

Ticking Circadian Clock and Gliomas

Noor ul huda Maria[1], Noor ul Huda Maria[1]

[1]PINS
[2]PINS

Objectives: To study how circadian clock affects glioma pathophysiology

Background: Dysregulated circadian clock gene expression can affect glioma progression by affecting tumour immune landscape and cell cycle and is a potential predictive biomarker in glioma as well as a potential treatment target

Method: Literature review

Results: Dysregulated circadian clock gene expression can affect glioma progression by affecting tumour immune landscape and cell cycle. Circadian rhythms modulate cellular functions via a transcriptional-translational feedback loop (TTFL) comprised of core clock genes transcriptional activators CLOCK, and ARNTL and transcriptional repressors PER1/2/3 and CRY1/2 .In the suprachiasmatic nucleus the PER gene expression is synchronized and stimulated by light. PER and CRY proteins, once transcribed, are translocated into the nucleus to interact with CLOCK and ARNTL, which then suppress the expression of PER and CRY. Analysis of 32 subjects revealed PERs and CRYs along with several other clock genes are downregulated in gliomas. KL001 is the first CRY modulator that activates both CRY1 and CRY2. Moreover, computational models based on cell cycle states or those based on the dynamics transcriptional/translational clock networks and of relevant drug-related metabolic pathways, and clinical studies showed that the timed drug administration impacts normal and tumour cells differently according to their internal circadian clock.Disparity is because clock and clock-regulated genes in tumour cells frequently have different circadian profiles or even different period lengths thus highlighting the importance of chronotherapy.Clinical and experimental studies showed that melatonin that helps regulate the circadian rhythm synchronize the sleep-wake cycle with night and day enhance the antineoplastic activity of chemotherapy.Clinically, biomarkers to quantify rhythmicity may facilitate the characterization of tissue-specific local oscillators to help understand pathological processes and application of chronotherapy

Normal and Disrupted Circadian Rhythms

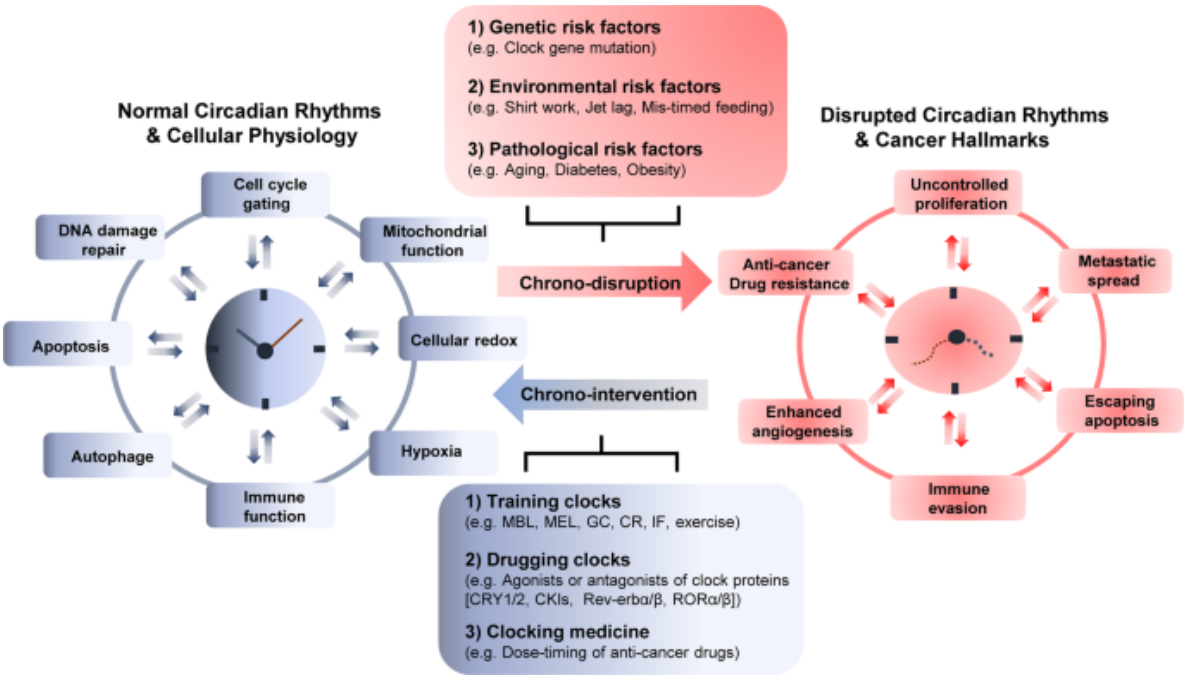

Normal and Disrupted Circadian Rhythms Circadian rhythm disruptions caused by genetic, environmental, and pathological risk factors promote cancer onset and progression characterized by cancer hallmarks courtesy Lee, Y. Roles of circadian clocks in cancer pathogenesis and treatment. Exp Mol Med 53, 1529–1538 (2021). https://doi.org/10.1038/s12276-021-00681-0

Implications of the circadian clock on cancer development and progression.

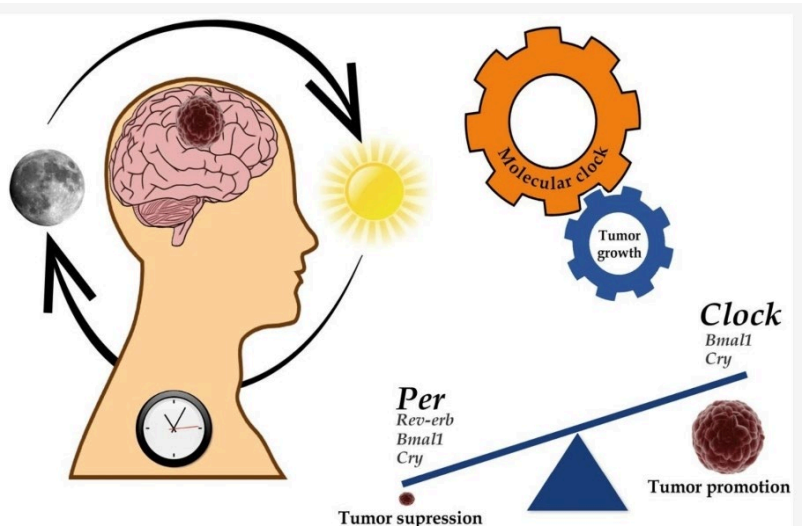

Several genes of the molecular clock have been associated with both the regulation of GBM genesis and progression as well as tumor suppression. Courtesy: Wagner, P.M.; Prucca, C.G.; Caputto, B.L.; Guido, M.E. Adjusting the Molecular Clock: The Importance of Circadian Rhythms in the Development of Glioblastomas and Its Intervention as a Therapeutic Strategy. Int. J. Mol. Sci. 2021, 22, 8289. https://doi.org/10.3390/ijms22158289

Conclusions: Importance of Circadian Rhythm in Gliomagenesis should be explored to assess risk of gliomagenesis, treatment targets as well as chronotherapyThere are

Keywords: circadian rhythm, chronotherapy, chronobiology

References

1. Panda S., Antoch M. P., Miller B. H., et al. Coordinated transcription of key pathways in the mouse by the circadian clock. *Cell* . 2002;109(3):307–320. doi: 10.1016/s0092-8674(02)00722-5. [PubMed] [CrossRef] [Google Scholar]
2. Zhang R., Lahens N. F., Ballance H. I., Hughes M. E., Hogenesch J. B. A circadian gene expression atlas in mammals: implications for biology and medicine. *Proceedings of the National Academy of Sciences of the United States of America* . 2014;111(45):16219–16224. doi: 10.1073/pnas.1408886111.

P-45

Elements of Neuroendoscopic Anatomy of The Fourth Ventricle-Cadaveric Studies

Nikolaos Syrmos[1]

[1]Aristotle University of Thessaloniki,Greece

Objectives: Introduction- Neuroendoscopic anatomy of the fourth ventricle has been reported infrequently in the literature, most of the times based on laboratory experiences. Neuroendosopy offers a quite different outlook of the anatomy of the fourth ventricle and compared with the microsurgical descriptions it seems to provide a superior and detailed visualization of the superior part.

Background: Aim-Regarding the upcoming neuroendoscopic techniques the fourth ventricle was examined.

Method: Material-Methods-In a series of 30 anatomically cadeveric specimens the fourth ventricle was investigated endoscopicaly. We are able to reach the fourth ventricle via the aqueductus cerebri and coming via the cerebromedullary cistern through the foramen of Magendie.

Results: Results- Using principally rigid and sometimes flexible endoscopes the basic anatomic details seen under the neuroendocope and the topographical landmarks of the approaches were investigated presented and discussed.

Conclusions: it seems that neuroendoscopy is a unique and very useful tool that it has a place in the armamentum of the modern neurosurgeon, its application will only broaden as we gain experience in using neuroendoscopic systems. Neurosurgery may have been slow to accept the use of modern neuroendocopic instruments in the management of neurological diseases but with advent of new scopes, illumination and instruments it is a fast growing arena for minimally invasive neurosurgery.

Keywords: Anatomy, Ventrıcles, Neuroendoscopy, Endoscopıc Anatomy

References

1. Nikolaos Syrmos-Endoscopic Anatomy of The IV Ventrıcle-Phd Thesıs Arıstotle Unıverıty Of Thessalonıkı-Greece

P-46

A Microsurgical Protocol for The Implantation of a Microprism Based High-Resolution Optical Access to the Mouse Anterior Cingulate Cortex

Daniel Kiss-Bodolay[1], Karl Schaller[1], Anthony Holtmaat[2]

[1]University Hospital of Geneva, Department of Neurosurgery
[2]University of Geneva, Department of Basic Neurosciences

Objectives: Objectives: Using laboratory microsurgical tools and animal models we aimed at:- studying the vascular and bony microanatomy surrounding the mouse anterior cingulate cortex (ACC)- developing a surgical protocol for the implantation of an in-vivo microprism based optical access to the ACC

Background: Background: The ACC has been implicated in a wide range of functions including executing and emotional control, learning, motivation, pain perception and fear conditioning [1]. In vivo high-resolution optical imaging techniques are powerful methods to study neuronal activity underlying these functions [2]. However, applying these techniques to explore ACC functions is extremely difficult mainly because of its deep interhemispheric localization, perpendicular orientation and because it is partly hidden under the superior sagittal sinus [3].

Method: Methods: Laboratory surgical loop (M80, Leica) and microsurgical instruments were used to study the mouse microanatomy and develop a protocol for the implantation of a 3 mm glass window combined with a 1.5 mm microprism inserted subdurally in the interhemispheric fissure facing the ACC. This optical access was then combined with in vivo 2-photon laser scanning microscopy and a combination of transgenic animals and virus-based transduction.

Results: Results: We developed and perfected a microprism based cranial window overcoming the above-mentioned technical barriers, allowing the high-resolution imaging of dendritic spines overs weeks and somatic calcium imaging of hundreds of neurons per field of view upon days in the mouse ACC.

Conclusions: Conclusions: We have developed a novel microsurgical protocol in a mouse model allowing high-resolution optical imaging of neuronal populations in the medial wall of the hemisphere. Using this approach we have succeeded in identifying bimodally modulated neuronal populations in the ACC during fear conditioning.

Keywords: microsurgery, anterior cingulate cortex, microprism, cranial window

References

(1) van Heukelum, S., Mars, R. B., Guthrie, M., Buitelaar, J. K., Beckmann, C. F., Tiesinga, P. H. E., Vogt, B. A., Glennon, J. C., & Havenith, M. N. (2020). Where is Cingulate Cortex? A Cross-Species View. *Trends in neurosciences*, *43*(5), 285–299. https://doi.org/10.1016/j.tins.2020.03.007

(2) Cramer, S. W., Carter, R. E., Aronson, J. D., Kodandaramaiah, S. B., Ebner, T. J., & Chen, C. C. (2021). Through the looking glass: A review of cranial window technology for optical access to the brain. *Journal of neuroscience methods*, *354*, 109100. https://doi.org/10.1016/j.jneumeth.2021.109100

(3) Low, R. J., Gu, Y., & Tank, D. W. (2014). Cellular resolution optical access to brain regions in fissures: imaging medial prefrontal cortex and grid cells in entorhinal cortex. *Proceedings of the National Academy of Sciences of the United States of America*, *111*(52), 18739–18744. https://doi.org/10.1073/pnas.1421753111

P-47

Temporary Artery Occlusion (TAO) During Intracranial Aneurysm Surgery is a Key Element in Facilitating Aneurysm Dissection And Clipping

Noor ul Huda Maria[1]

[1]PINS
[2]PINS

Objectives: In our study we want to compare results of anterior circulationaneurysm clipping with and without application of temporary clip for occlusionCONCLUSIONS:This study demonstrated only slight difference between application of temporary clipping versus no clipping in anterior circulationaneurysm surgery.It should be noted that no clipping method was performed by the experienced surgeon who had enough expertise in the applicationof clips and control of bleeding.Aneurysm were of anterior circulation only and posterior circulation aneurysm surgery was not compared.

Background: Temporary artery occlusion (TAO) during intracranial aneurysm surgery is a key element in facilitating aneurysm dissection andclipping. Despite its significance, knowledge of its effects on long-term clinical outcome in patients undergoing elective clipping is limited.

Method: Patients managed for an intracranial aneurysm were followed from january 2017-December 2017

Results: The study was conducted on a total 56 patients. half of whom underwent temporary arterial occlusion during their elective clipping procedureand the other half did not. Potential risk factors affecting outcome were considered. Effects of temporary occlusion on long-term clinical outcomewere evaluated using the Glasgow Outcome Scale (GOS) obtained retrospectively by analyzing medical records at the last follow-up visit ordischarge. Analyses included descriptive statistics, binary logistic regression, and ordinal logistic regression.Mean temporary artery clipping time was 13.1 minutes . 85% patients who had temporaryclipping had a good outcome and made a complete recovery at last follow-up (GOS 5); similarly in no occlusion group 88% had a good outcome anda complete recovery at last followup. 10% of patients were moderately disabled (GOS 4) in TAO group vs 8% in non occlusion group;5% of patientswere severely disabled (GOS 3), were in a vegetative state (GOS 2), or had died (GOS 1) in TAO vs 4% in non occlusion group.

Conclusions: There is no significant difference whether temporary occlusion is applied or not in anterior circulation aneuysm

Keywords: aneurysm clipping, temporary clipping

References

1. Abdulrauf SI, Vuong P, Patel R, Sampath R, Ashour AM, Germany LM, et al. "Awake" clipping of cerebral aneurysms: Report of initial series. J Neurosurg. 2017;127:311–8. [PubMed] [Google Scholar]
2. Suzuki K, Mikami T, Sugino T, Wanibuchi M, Miyamoto S, Hashimoto N, et al. Discrepancy between voluntary movement and motor-evoked potentials in evaluation of motor function during clipping of anterior circulation aneurysms. World Neurosurg. 2014;82:e739–45

P-48

Brain a Traumatic Situations in Young Patients During Amateur Sea Sports Activity

Nikolaos Syrmos[1]

[1]Aristotle Univesity of Thessaloniki,Greece

Objectives: Objective: Aim of this study is to present cases of brain and cervical spine traumatic situations during amateur sports sea activity

Background: Design: 10 cases are presented

Method: Setting: An acurrate analysis of such cases in sports sea sportsParticipants: 8 male and 2 female, range of age 12 -26,mean age 17,5 years

Results: Interventions : 10 hospitalization and treatment, 2 surgical interventions for brain trauma ,8 cases with conservative treatmentOutcome measures: Good outcome in all 10 cases

Conclusions: Main Results: Pain Killer pharmacological treatment,Ct ,Mri and x ray evaluation in all of themConclusions: Brain traumas are situations that needs accurate resolution and treatment

Keywords: SPORTS, TRAUMA, NEUROSURGERY, BRAIN

References

1. Syrmos N, Ampatzidis G. Depressive disorders after mild craniocerebral injuries in amateur athletes. Eur Psychiatry. 2021 Aug 13;64(Suppl 1):S695. doi: 10.1192/j.eurpsy.2021.1841. PMCID: PMC9480200.

P-50

Free, Accessible, and Sustainable Microsurgical Training for LMICs: The Madison Microneurosurgery Initiative Approach

Abdullah Keles[1], Alberto Acitores Cancela[2], Adefisayo Adekanmbi[3], Mohammad Shahnawaz Bari[4], Chloe Dumot[5], Guillermo Garcia Oriola[6], Turab Gasimov[7], Mehmet Sabri Gurbuz[8], Jared Paul U. Golidtum[9], Yannick Canton Kessely[10], Zviad Malazonia[11], Charbel K. Moussalem[12], Mohd Aidil Bin Mohd Nor[13], Ahmed Hussein Omar[14], Jayunkumar Shah[15], Burak Ozaydin[16], Mustafa K. Baskaya[1]

[1]Department of Neurological Surgery, University of Wisconsin, School of Medicine and Public Health
[2]Department of Neurological Surgery, Hospital Universitario Ramón y Cajal
[3]Department of Neurological Surgery, University College Hospital
[4]Department of Neurosurgery Bangabandhu Sheikh Mujib Medical University
[5]Department of Tumoral and Vascular Neurosurgery, Lyon Neurosurgical Hospital
[6]Department of Neurosurgery, Hospital Clinic University of Valencia
[7]Department of Neurosurgery, Respublika Diaqnostika Mərkəzi
[8]Department of Neurosurgery, Istanbul Medeniyet University
[9]Department of Surgery, Jose R. Reyes Memorial Medical Center
[10]Department of Surgery, Hôpital de la Renaissance
[11]Department of Neurological Surgery, Caucasus Medical Center
[12]Department of Surgery, American University of Beirut Medical Center
[13]Department of Neurological Surgery, Hospital Tengku Ampuan Afzan
[14]Department of Neurological Surgery, Faculty of Medicine
[15]Department of Neurological Surgery, M.K. Shah Medical College and Research Center
[16]Department of Neurological Surgery, University of Oklahoma College of Medicine

Objectives: LMICs are facing a substantial requirement for medical professionals skilled in microsurgical techniques. Madison Microneurosurgery Initiative (MMI) was founded to bridge this gap in microsurgical training by providing basic, accessible, and sustainable microsurgical training opportunities to medical professionals from LMICs in their respective countries.

Background: Even though modern microsurgical techniques were introduced in the late 1960s, they remain largely inaccessible in the majority of low- and middle-income countries (LMICs). The inadequate availability of microsurgical training facilities and medical professionals trained in microneurosurgical techniques is a key factor contributing to the disparity in LMICs when compared to high-income countries.

Method: To bridge this divide, in 2020, we began procuring stereo microscopes, microsurgery training instruments, and materials from various online auction websites and other sources. All the purchases and quality checks were made by the first author, AK, and MMI members. After the quality check, we donated different microscopes and instrument setups to neurosurgeons from LMICs based on individual needs. After delivering the setup to the intended locations, we provided previously recorded training videos and organized online lectures. Additionally, we have visited some of the centers and organized in-person microanastomosis training courses in those countries.

MMI Donation Setups



Some of MMI Donation Setups including stereo microscopes, macro and microsurgical instruments

Results: To date, we have reached out to 17 LMICs and 26 centers and donated 50 stereo microscopes and macro/micro instrument sets. We arranged virtual meetings with many of those centers to introduce the equipment we provided and offer guidance on utilizing our pre-recorded training videos to initiate microsurgery practice in their institutions. In addition, we organized microsurgical training "boot camps" in seven locations with over 100 trainees from four countries: Turkey, Georgia, Azerbaijan, and Paraguay.

Madison Microneurosurgery Initiative



Worldwide Impact of Madison Microneurosurgery Initiative

Hands-on Microvascular Anastomosis Courses



With trainees from Istanbul, Diyarbakir, Van, Erzurum, Tbilisi, Baku, and Asuncion.

Conclusions: Free, accessible, and sustainable microsurgical training for LMICs is feasible and MMI will further continue to contribute to microvascular laboratory training in LMICs.

Keywords: global neurosurgery, low and middle-income countries, Madison microneurosurgery initiative, microsurgical training

References

1. Dempsey RJ. Neurosurgery in the Developing World: Specialty Service and Global Health. Editorial Material. World Neurosurg. Apr 2018;112:325-327. doi:10.1016/j.wneu.2018.02.099

P-51

Microsurgical Management of Petroclival Meningiomas

Serick Duysenbi[1]

[1]National Scientific Medical Center

Objectives: To evaluate the outcome of patients with petroclival meningiomas who received microsurgical treatment at our center.

Background: Petroclival meningiomas is a challenging tumor and its treatment strategy is evolving.

Method: We have retrospectively reviewed the clinical and radiological data of all patients who underwent microsurgical removal of petroclival meningiomas at a single institution from June 2020 to May 2022.Clinical data were retrospectively analyzed and outcomes were evaluated by KPS scores.

Results: here were twelve consecutive patients. All patients are females, and the mean ages was 53.1 years. Five meningiomas were extended into the posterior fossa, while five meningiomas into middle fossa and three meningiomas into cavernous sinus. The large petroclival meningiomas that extended into the middle fossa and posterior fossa were removed via trasnzygomatic subtemporal and retrosigmoid approach as staged surgeries with 2 months interval, while pure inferior tentorial or clival meningiomas were removed through retrosigmoid approach or lateral superocerebellar inferior tentorial approach . Bilateral staged microsurgical removal of meningiomas were performed in one patient with bilateral petroclival meningioma at a two months interval. All patients were received angiographic examination preoperatively and main arterial feeders from meningohypophyseal trunk of internal carotid artery and extracranial carotid artery were embolized with Onyx. Follow-up time was 18 months (12-24 months). Gross total resection were achieved in 10 cases (83%), while subtotal resection in two cases (17%). There is no death among our patients.Neurologic conditons improved in all patients,but newly developed or worsening of cranial nerve deficit were observed in four patients(33%).KPS score at the last follow up was more than 80 in all patients. There is no recurrence during the follow up period.

Pre and post operative images of petroclival meningiomas

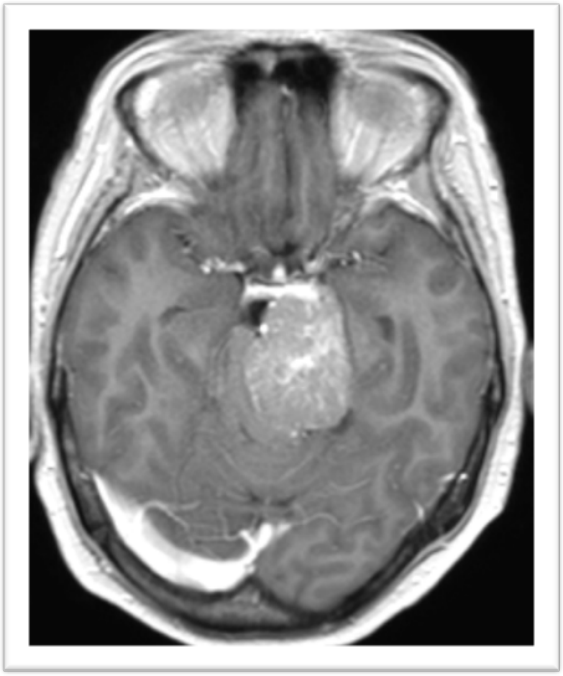

Pre operative MRI with contrast shows a large petroclival meningioma which significantly compressed the brainstem.

Post op CT



Immediate post operative CT showed grosss total tumor removal without any significant hematoma.

Post op 3D CT of the skull



3D CT of the Skull showed the extent of partial petrosectomy.

Complication

Location	Numbers	Approaches	Complication	Outcomes
Clival	2	Retrosigmoid	6th nerve palsy in one	Recovered partially
Petroclioval	10	Transzygomatic subtemporal,Retrosigmoid, Superocerebellar inferotentorial	Oculomotor Nerve palsy in one Trochlear Nerve Palsy in one 6th Nerve Palsy in One	Persist

cranial nerve palsy is the main neuronal complication in our series.

Conclusions: Although most of patients with the skull base tumors may benefit from microsurgery, but postoperative cranial nerve deficit in large complicated petroclival meningiomas is the major complication.

Keywords: petroclival meningiomas, microsurgery, approach, complication

References

1. Magill ST, McGahan BG, Carrau RL, Prevedello DM. Endoscopic endonasal transclival petroclival meningioma resection. Neurosurg Focus Video. 2022 Apr 1;6(2):V2.
2. Wijaya JH, Arjuna YYE, July J. The role of stereotactic radiosurgery in the management of petroclival meningioma: a systematic review. J Neurooncol. 2022 Aug;159(1):33-35.
3. Xie T, Wang Y, Zhang X, Shao N, Lu W, Yang Q, Qu C, Li C, Liu T, Liu S, Zhu W. Endoscopic Far-Lateral Supracerebellar Infratentorial Approach for Petroclival Region Meningioma: Surgical Technique and Clinical Experience. Oper Neurosurg (Hagerstown). 2022 May 1;22(5).
4. Jackson C, Tadokoro KS, Wang EW, Zenonos GA, Snyderman CH, Gardner PA. Approach selection for resection of petroclival meningioma. Neurosurg Focus Video. 2022 Apr 1;6(2):V9.
5. Ohata K, Hara M. [Petroclival meningioma]. No Shinkei Geka. 2002 Nov;30(11):1159-71. Japanese.
6. Kankane VK, Misra BK. Petroclival Meningioma: Management Strategy and Results in 21st Century. Asian J Neurosurg. 2021 Feb 23;16(1):89-95.
7. Vakharia KV, Naylor RM, Hasegawa H, Nassiri AM, Driscoll CLW, Link MJ. Right posterior petrosectomy for resection of petroclival meningioma. Neurosurg Focus Video. 2022 Apr 1;6(2):V14.
8. Hunter JB, Weaver KD, Thompson RC, Wanna GB. Petroclival meningiomas. Otolaryngol Clin North Am. 2015 Jun;48(3):477-90. doi: 10.1016/j.otc.2015.02.007. Epub 2015 Apr 9. PMID: 25863570.
9. Shinya Y, Shin M, Hasegawa H, Koizumi S, Kin T, Kondo K, Saito N. Endoscopic endonasal transpetroclival approach for recurrent bilateral petroclival meningioma. Neurosurg Focus Video. 2022 Apr 1;6(2):V7.

P-57

Clinical Assessment of Patient Reported Quality of Life Following Endoscopic Skull Base Surgeries

Suraj Gopal[1], Prakash Nair[1], HV Easwer[1]

[1]Sree Chitra Tirunal Institute For Medical Sciences and Technology

Objectives: 1)To assess the patient reported quality of life (PRQol) using the sinonasal outcome test (SNOT-22) , anterior skull base questionnaire (ASBQ) and the anterior skull base inventory (SBI) following endoscopic endonasal skull base surgery.2)To evaluate the changes in QOL preoperatively, 1 month and 6 months after surgery.

Background: Endoscopic endonasal surgery (EES) is a widely utilized approach for managing ventral skull base pathologies. Evaluating PRQoL following EES is crucial for assessing its effectiveness and improving patient outcomes.No single QoL assessment tool has been found to be superior in accurately estimating the PRQoL.

Method: Prospective study involving patients scheduled for endoscopic skull base surgeries. Baseline scores were obtained using all three questionnaires ie SNOT-22, ASBQ and SBI and re-administered at 1 month and 3 months post-surgery.

Results: 72 eligible patients were included in the analysis. SNOT-22 scores demonstrated significant improvement in all five domains and the total symptom score compared to pre-operative baseline values at both 1 month and 3 months post-surgery.Friedman test analysis revealed significant improvements in total scores and four out of five domains at 1 month and significant improvements in all domains and total scores at 3 months. The SBI scores showed significant improvement over time for all except for the nasal domain. Similarly, ASBQ scores demonstrated significant improvement over time for all except for the pain domain.For both SBI and ASBQ the Bonferroni Post-hoc test showed that the overall scores were significantly lower at 1month ($p = .001$) and 3month ($p = .001$) than at baseline.

Conclusions: The study highlights the positive impact of EES on PRQoL across multiple domains, as evidenced by improvements in SNOT-22, SBI and ASBQ-35 scores. Certain domains reflect these changes on PRQoL better than others. These findings emphasize the importance of incorporating patient perspectives during EES in treatment decision-making for optimal results.

Keywords: endoscopic endonasal surgery, patient reported quality of life, QOL assesment tools, improving patient outcomes

References

1. Gil Z, Fliss DM. Quality of life in patients with skull base tumors: current status and future challenges. Skull Base. 2010;20:11–18
2. Gill T.M. & Feinstein A.R. (1994) A critical appraisal of the quality of life of quality-of-life measurements. J. Am. Med. Assoc. 272, 619–626
3. Gil Z, Abergel A, Spektor S, Khafif A, Fliss DM. Patient, caregiver, and surgeon perceptions of quality of life following anterior skull base surgery. Arch Otolaryngol Neck Surg. 2004;130(11):1276-1281. doi:10.1001/archotol.130.11.1276

P-60

10-0 Pial Retraction Sutures for Excision of Intramedullary Tumors: A Video Demonstration

Mehmet Sabri Gurbuz[1], Huseyin Ikbal Akdemir[1], Mohammed O.H. Aladdam[1], Deniz Alyanak[1], Ilkenur Yıldırım[1]

[1]Istanbul Medeniyet University

Objectives: To demonstrate the use of pial 10-0 retraction sutures for removal of an intramedullary ependymoma. These retraction sutures prevent sagging of the medulla and thus enhance the exposure of the tumor.

Background: Intramedullary tumors are challenging tumors that removed via posterior-median sulcus, posterolateral sulcus and direct transpial approaches. Due to narrow surgical field and fact that retraction of spinal cord with blades is unacceptable, it is important to avoid sagging of the spinal cord and improve tumor exposure. Gentle retraction of the spinal cord with 10-0 pial retraction suture is reasonable solution to this problem.

Method: A 58-year-old woman presenting with numbness in the upper extremities was diagnosed with a cervical intramedullary tumor. She underwent surgery under neuromonitoring in the neutral-prone position. After total laminectomy, the dura was incised midline and retracted with 6-0 sutures. The arachnoid is incised separately and secured to dural edges. After identifying the posterior median sulcus and performing midline myelotomy, pia of the medulla is retracted to the dural margins using 10-0 sutures on both sides. This maneuver gently improved exposure of the intramedullary tumors. A gross-total resection of the tumor was achieved, and the patient was discharged from the hospital on the fourth postoperative day. The histopathologic diagnosis was WHO grade-II ependymoma. The important steps of the surgery, especially the placement of 10-0 retraction sutures, are demonstrated in a video presentation.

Perioperative Surgical Field

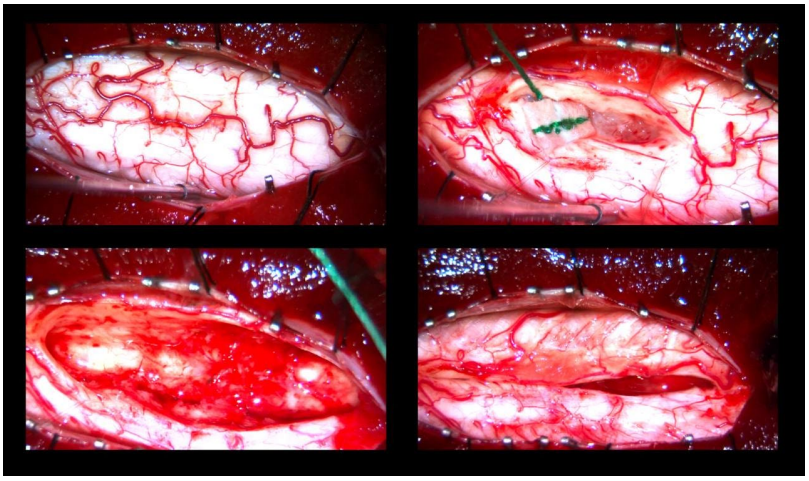

1. Dura was opened and retracted with 6-0 sutures 2. Arachnoid and pia was opened gently and seperated with 10-0 sutures are visible after the surgical field is exposed 3. The entire tumor area is clearly visible due to retraction. 4. the tumor is completely excised

Preoperative and Postoperative MRI

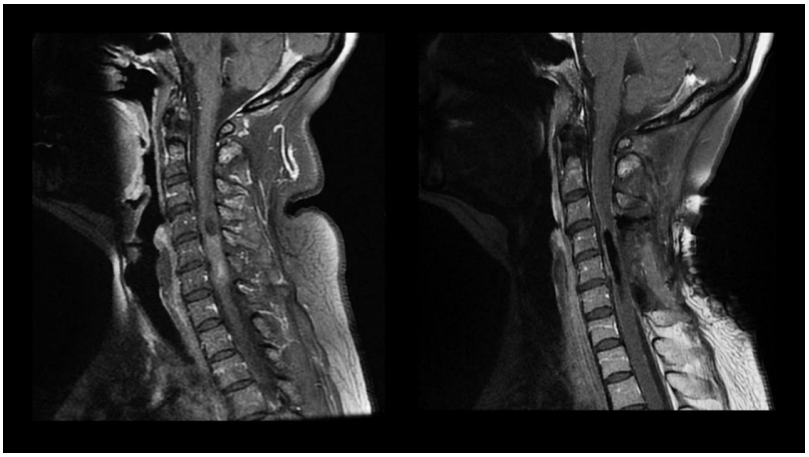

Preoperative cervical MRI (left) Postoperative 24-hour cervical MRI (right)

Results: After midline incision and retraction of both dura and arachnoid layers, the spinal cord was exposed under the microscope as usual. Superficial midline vessels were displaced and preserved after posterior midline myelotomy. Two 10-0 sutures were threaded to pia of the spinal cord on each side and gently retracted. Bladeless retraction technique safely exposed the intramedullary tumor.

Conclusions: The use of pial 10-0 retraction sutures provides safe, practical technique for exposure and gross-total removal of tumors.

Keywords: Intramedullary tumors, Ependymoma, Retraction suture

References

1. Uluc K, Cikla U, Morkan DB, Sirin A, Ahmed AS, Swanson K, Baskaya MK. Minimizing Retraction by Pia-Arachnoidal 10-0 Sutures in Intrasulcal Dissection. Oper Neurosurg (Hagerstown). 2018 Jul 1;15(1):10-14. doi: 10.1093/ons/opx193. PMID: 29029292.

P-62

Rupture Status Prediction Based on The Morphology of Cerebral Aneurysms: a Machine Learning Based Study

Dr Bhushan Sadashiv Akhade[1]

[1]SCTIMST Trivandrum,India

Objectives: To assess the significance of the morphological factors and its correlation to rupture status of IAs using statistical and machine learning tools.

Background: Intracranial aneurysms are common condition in neurosurgical practice. A key factor governing clinical management of cerebral aneurysms is the rupture status. Crucial clinical situations arise when it is difficult to identify the ruptured aneurysm in case of multiple aneurysms. In this realm, morphological features of aneurysms often provide valuable and reliable clues.

Method: Fifty consecutive cerebral aneurysms (32 unruptured, 18 ruptured) were studied. Geometric models were derived from using computational modelling computed tomographic angiography (CTA) or digital subtraction angiography (DSA). These models were created by performing image segmentation of angiographic images. The geometrical models were processed using software to extract key morphological indices and ratios. The morphological factors were tabulated, and statistically analysed. Further, machine learning algorithms were used to obtain the best prediction of aneurysm rupture status. This was performed by supervised learning and testing the dataset.

Results: The aforementioned workflow was used to gather morphological parameters for further statistical and machine learning-based inferences. Dome height, dome width, dome perpendicular height, neck diameter, aneurysm surface area, aneurysm volume, and surface area/volume ratio were identified as the best parameters based on the hypothesis test. The SVM algorithm delivered the best results in predicting rupture status based on morphological parameters. Different Machine learning models were compared. The highest accuracy was delivered by the Support Vector Machine (SVM) giving an accuracy about 87.5%.

Conclusions: Dome height, dome width, dome perpendicular height, neck diameter, aneurysm surface area, aneurysm volume, and surface area/volume ratio of aneurysms are the key predictors of aneurysm rupture status. Machine learning techniques offer reasonable accurate prediction of the aneurysm rupture status.

Keywords: Intracranial Aneurysm, Morphology, RiskAssessment; Machine Learning Classification Models.

References

1. Ingall T, Asplund K, Mähönen M, Bonita R. A multinational comparison of subarachnoid hemorrhage epidemiology in the WHO MONICA stroke study. Stroke. 2000;31(5):1054–61.
2. Thompson BG, Brown RD, Amin-Hanjani S, Broderick JP, Cockroft KM, Connolly ES, et al. Guidelines for the Management of Patients With Unruptured Intracranial Aneurysms: A Guideline for Healthcare Professionals From the American Heart Association/American Stroke Association. Vol. 46, Stroke; a journal of cerebral circulation. 2015. 2368–2400 p.
3. kassell1983.pdf.
4. Murayama Y, Takao H, Ishibashi T, Saguchi T, Ebara M, Yuki I, et al. Risk Analysis of Unruptured Intracranial Aneurysms: Prospective 10-Year Cohort Study. Stroke. 2016;47(2):365–71.
5. Malhotra A, Wu X, Forman HP, Nardini HKG, Matouk CC, Gandhi D, et al. Growth and rupture risk of small unruptured intracranial aneurysms a systematic review. Ann Intern Med. 2017;167(1):26–33.
6. Hadjiathanasiou A, Schuss P, Brandecker S, Welchowski T, Schmid M, Vatter H, et al. Multiple aneurysms in subarachnoid hemorrhage - Identification of the ruptured aneurysm, when the bleeding pattern is not self-explanatory - Development of a novel prediction score. BMC Neurol. 2020;20(1):1–12.
7. Kashiwazaki D, Kuroda S. Size ratio can highly predict rupture risk in intracranial small (<5 mm) aneurysms. Stroke. 2013;44(8):2169–73.
8. Xiang J, Natarajan SK, Tremmel M, Ma D, Mocco J, Hopkins LN, et al. Hemodynamic-morphologic discriminants for intracranial aneurysm rupture. Stroke. 2011;42(1):144–52.
9. Liu J, Chen Y, Lan L, Lin B, Chen W, Wang M, et al. Prediction of rupture risk in anterior communicating artery aneurysms with a feed-forward artificial neural network. Eur Radiol. 2018;28(8):3268–75.
10. Donahoe. 基因的改变 NIH Public Access. Mol Cell Biochem. 2012;23(1):1–7.
11. Raghavan ML, Ma B, Harbaugh RE. Quantified aneurysm shape and rupture risk. J Neurosurg. 2005;102(2):355–62.
12. Björkman J, Frösen J, Tähtinen O, Backes D, Huttunen T, Harju J, et al. Irregular Shape Identifies Ruptured Intracranial Aneurysm in Subarachnoid Hemorrhage Patients with Multiple Aneurysms. Stroke. 2017;48(7):1986–9.
13. Lindgren AE, Koivisto T, Björkman J, Von Und Zu Fraunberg M, Helin K, Jääskeläinen JE, et al. Irregular Shape of Intracranial Aneurysm Indicates Rupture Risk Irrespective of Size in a Population-Based Cohort. Stroke. 2016;47(5):1219–26.
14. Perera R, Isoda H, Ishiguro K, Mizuno T, Takehara Y, Terada M, et al. Assessing the risk of intracranial aneurysm rupture using morphological and hemodynamic biomarkers evaluated from magnetic resonance fluid dynamics and computational fluid dynamics. Magn Reson Med Sci. 2020;19(4):333–44.
15. Tanioka S, Ishida F, Yamamoto A, Shimizu S, Sakaida H, Toyoda M, et al. Machine Learning Classification of Cerebral Aneurysm Rupture Status with Morphologic Variables and Hemodynamic Parameters. Radiol Artif Intell. 2020;2(1):e190077.
16. Baharoglu MI, Schirmer CM, Hoit DA, Gao BL, Malek AM. Aneurysm inflow-angle as a discriminant for rupture in sidewall cerebral aneurysms: Morphometric and computational fluid dynamic analysis. Stroke. 2010;41(7):1423–30.

P-63

Superficial Temporal Artery to Middle Cerebral Artery Direct Bypass for Steno-Occlusive Disease in Patients with Previous Stroke. Tver Region Clinical Hospital Experience.

Salavat Mirkhaydarov[1]

[1]Tver region clinical hospital

Objectives: To examine the safety and efficacy of direct STA-MCA bypass in patients with symptomatic steno-occlusive disease with impaired distal perfusion, with previous had stroke. To examine CT perfusion for selection of patients for direct STA-MCA bypass.

Background: After COSS study interest for direct STA-MCA bypass decreased. Many papers suggest perfusion measurement for a patient selection. Using CT perfusion for population of patients with symptomatic steno-occlusive disease can facilitate detectability of patients for direct STA-MCA bypass.

Method: A retrospective review was performed to identify patients with cerebrovascular steno-occlusive disease who underwent bypass after despite optimal conservative treatment.

Results: A total of 17 patients (mean age 60 ± 6 yr) underwent direct STA-MCA bypass between 2021 and 2022. All anastomoses were patent. 2 patient developed hyperperfusion syndrome, 1 patient with hyperperfusion syndrome died, 1 patient developed subdural hematoma, 1 patient had recurrent stroke in 10 months after operation. A total of 13 out of 17 patients were stable or improved clinically at last follow-up (mean 14.8 ± 5.6 mo) without recurrent strokes. 5 patients were done CT perfusion, all of them had impaired brain perfusion.

Patient after direct bypass



Conclusions: Patients with symptomatic, hypoperfused steno-occlusive disease with previous stroke may benefit from cerebral revascularization. Direct STA-MCA bypass was safe and provided favorable outcomes in this small series. CT perfusion can help to reveal impaired brain perfusion.

Keywords: Bypass, Cerebral revascularization

References

1. Carlson AP, Yonas H, Chang YF, Nemoto EM: Failure of cerebral hemodynamic selection in general or of specific positron emission tomography methodology?: Carotid occlusion surgery study (COSS). Stroke 42; 3637-3639,2011

P-65

The Role of Extracranial-Intracranial Microvascular Anastomosis Surgery in Patients with The Acute Occlusive Intracranial Vascular Disease Following an Unsuccessful Endovascular Approach

Chingiz Nurimanov[1]

[1]National Centre for Neurosurgery

Objectives: This retrospective study aimed to evaluate the treatment outcomes of patients with acute occlusive intracranial vascular disease who underwent microvascular anastomosis surgery after unsuccessful attempts at endovascular revascularization interventions.

Background: Ischemic stroke is a significant societal burden, and although intra-arterial thrombolysis and mechanical thrombectomy are effective treatments, they are not always successful, with failure rates of 10-30% [1, 2]. The use of microsurgical interventions for cerebrovascular pathology has decreased, including revascularization operations for steno-occlusive diseases that have gained widespread use after the COSS1 and COSS2 studies [3]. However, emergency bypass vascular anastomoses between extra-intracranial vessels remain a viable option for patients when endovascular treatments are not possible. The first reported use of these operations was by G. Yasargil in 1968 [4].

Method: The study involved 9 patients (age range: 34-61 years, average age: 44.2 years) with acute occlusion of intracranial vessels. Microsurgical revascularization was performed within 6 hours from the start of symptoms, and within 2-6 hours in the occluded territory. Clinical signs included: hemiparesis, dysarthria, hemihypesthesia. The STA-MCA end-to-side bypass technique was used in all 9 patients for microsurgical revascularization. Intraoperatively, the patency of the anastomosis was confirmed by ultrasound duplex scanning.

Results: All 9 patients demonstrated functional anastomosis on control angiography. 7 patients (78%) exhibited complete regression of initial neurological symptoms and a mRS of 1 at discharge. The remaining 2 patients (22%) had minor neurological deficits, corresponding to a mRS of 2 at discharge. No complications related to the operation were observed during or after the procedure.

Illustrative case # 1

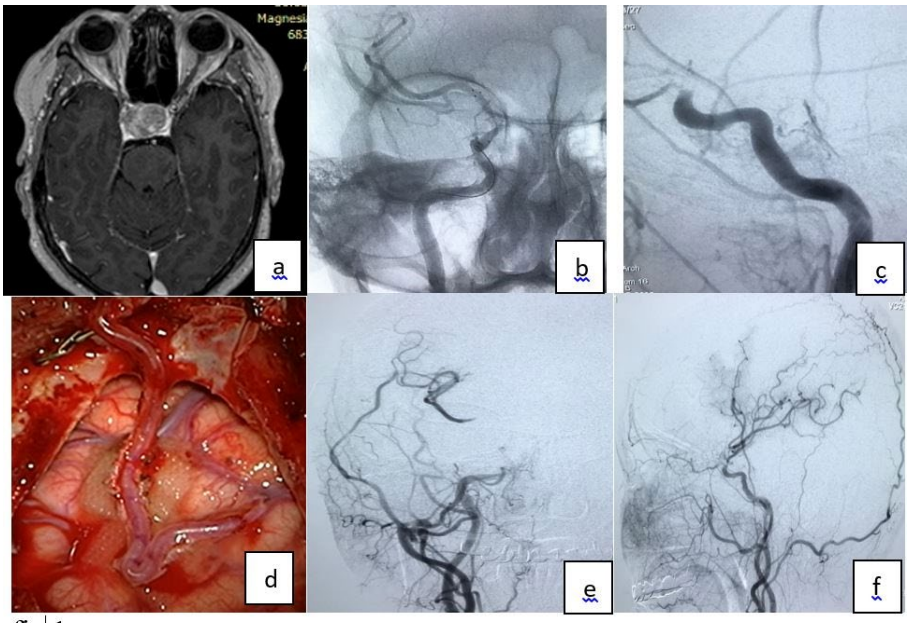

fig 1.

A 51-year-old woman with a diagnosis of pituitary adenoma (see Figure 1a) underwent a transnasal endoscopic removal of the adenoma. On the 5th day after the operation, the patient developed symptoms of left-sided hemiparesis. Angiography showed occlusion of the right ICA, and after unsuccessful attempts at endovascular revascularization methods (see Figures 1b, c), an STA-MCA bypass surgery was performed 4.5 hours after the index event (see Figure 1d). Follow-up angiography on the 2nd day (see Figures 1e, f) was performed. Complete regression of neurological symptoms. Discharged on the 8th day with a Rankin score of 1

Illustrative case # 2.

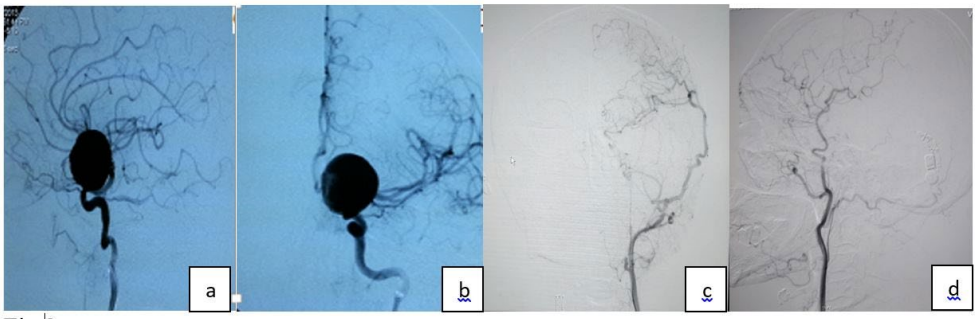

Fig 2.

Patient, 46 years old, female with a diagnosis of giant aneurysm of the left internal carotid artery. (see Fig. 2, a, b). A flow-diverting stent was installed. On the second day after the operation, the patient developed hemiparesis and aphasia. Control angiography revealed stent thrombosis, and after unsuccessful attempts at endovascular revascularization, a bypass STA-MCA was performed, followed by control angiography (see Fig. 2, c, d). Neurological symptoms regressed. Discharged on the 6th day with a Rankin score of 1.

Illustrative case # 3.

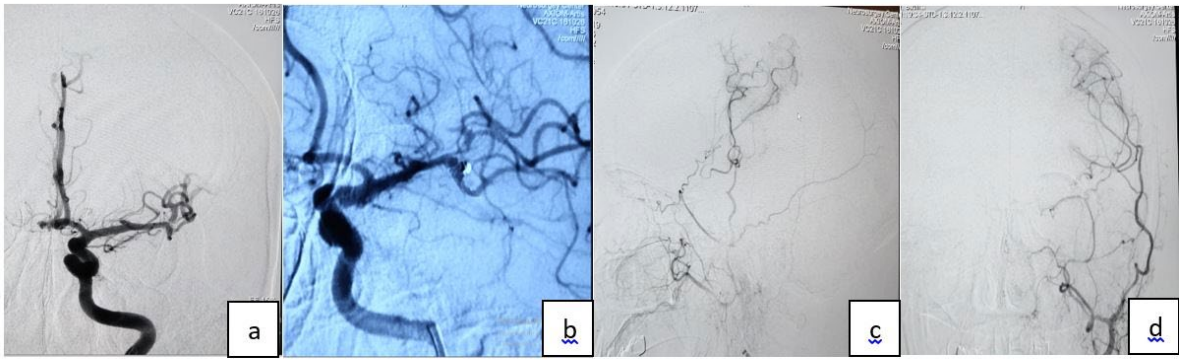

Fig 3.

Patient, 37 years old, a female with a diagnosis of an aneurysm of the left middle cerebral artery. (see Fig. 3, a, b), Embolization of the aneurysm with microcoils with stent assistance was performed. Three hours after the operation, the patient developed hemiparesis and aphasia. Control angiography revealed occlusion of the superior branch of the MCA, and after unsuccessful attempts at endovascular revascularization, a bypass STA-MCA was performed, followed by control angiography on the second day (see Fig. 3, c, d).

Conclusions: This study emphasizes the importance of microvascular anastomoses in the context of endovascular treatment for acute occlusion of cerebral vessels. It is essential for neurosurgeons to possess proficiency in the technique of microvascular anastomosis, which can prevent ischemic complications and improve outcomes in patients who experience thromboembolic complications during neurosurgical procedures.

Keywords: ischemic stroke, revascularization, STA-MCA anastomosis

References

1. Nogueira RG, Jadhav AP, Haussen DC, Bonafe A, Budzik RF, Bhuva P, et al. Thrombectomy 6 to 24 hours after stroke with a mismatch between deficit and infarct. N Engl J Med. 2018 Jan 4;378(1):11–21.
2. R. Bhatia, M.D. Hill, N. Shobha, B. Menon, S. Bal, P. Kochar, T. Watson, M. Goyal, A.M. Demchuk, Low rates of acute recanalization with intravenous recombinant tissue plasminogen activator in ischemic stroke: real-world experience and a call for action, Stroke 41 (10) (2010) 2254–2258.
3. Grubb RL Jr, Powers WJ, Clarke WR, Videen TO, Adams HP Jr, Derdeyn CP, Carotic Occlusion Study Investigators. Surgical results of the Carotic Occlusion Surgery Study. Journal of Neurosurgery. 2012 October 26; 118 (1) 25-3
4. Yaşargil MG. Anastomosis between the superficial temporal artery and a branch of the middle cerebral artery. In: Yaşargil MG, editor. *Microsurgery Applied to Neurosurgery.* George Thieme Verlag; Stuttgart: 1969. pp. 105–115

P-66

Management and Outcomes of Acinetobacter Baumannii Meningitis in Post-Neurosurgical Patients at Inkosi Albert Luthuli Central Hospital.

Authors: Diketso Mathebula[1,2], Basil Enicker[1,2]

Affiliations:
[1]Department of Neurosurgery, Nelson R. Mandela School of Medicine, College of Health Sciences, University of KwaZulu-Natal, South Africa.
[2] Inkosi Albert Luthuli Central Hospital

Abstract

Background: Acinetobacter baumannii meningitis/ventriculitis is a severe complication diagnosed in post neurosurgical patients. It is associated with high morbidity and mortality rates compared to other types of meningitis.

Objectives: To assess the susceptibility of Acinetobacter isolates to antimicrobials and identify factors that contribute to unfavourable outcomes.

Methods: A retrospective study was conducted on 59 patients who were treated for *Acinetobacter baumannii* meningitis following a neurosurgical procedure at Inkosi Albert Luthuli Hospital from August 2016 to May 2023. Data collected manually from electronic patient records included demographics, co-morbidities, clinical presentation, neurosurgical pathology, length of hospital stay, laboratory-based cerebrospinal fluid (CSF) analyses, antimicrobial susceptibility, and patient mortality.

Results:. The overall in-patient mortality rate was 52,54% and there were twenty eight (47,46%) survivors. The mean age at presentation was 26,7 years old. There were forty-four (74%) males and fifteen females (25%). Eight (13,56%) patients had immunosuppressive medical co-morbidities. The main primary neurosurgical pathology was traumatic brain injury (62,72%), followed by tumours (20,34%), hydrocephalus (8,47%), sepsis (3,39%), vascular pathologies (3,39%), and other (1,69%). Multidrug-resistant Acinetobacter baumanii was cultured in 74% of these patients, most of whom were treated with either intravenous or intrathecal Colistin. On further analysis, ICU admission, more than 4 external ventricular drain (EVD) procedures, MDR Acinetobacter baumanni csf isolate and concurrent nosocomial MDR pneumonia were all associated with unfavourable outcomes.

Conclusion: Acinetobacter baumannii meningitis/ventriculitis has a high mortality rate in post neurosurgical patients. Intravenous and/or intrathecal Colistin is used in the management of MDR A. baumanni meningitis. ICU admission, MDR A. baumanni, multiple EVD procedures, and concurrent MDR nosocomial pneumonia are associated with poor outcomes. Early diagnosis, meticulous infection control measures and prompt initiation of directed antimicrobial therapy is crucial for improving patient outcomes.

Key words: Acinetobacter baumannii, meningitis, postneurosurgical, antibiotic susceptibility

P-67

A Comparative Analysis of Outcomes and Complications Following Cranioplasty With Autologous Bone, Titanium Mesh, and Polymethyl Methacrylate: Results From a Single Centre in Durban, South Africa

Diketso Mathebula[1,2], Basil Enicker[1, 2]

[1]Department of Neurosurgery, Inkosi Albert Luthuli Central Hospital, KwaZulu-Natal, South Africa
[2]Nelson R Mandela School of Medicine, University of KwaZulu-Natal, South Africa

Abstract

Objective: To compare the outcomes of cranioplasty using autologous bone (AB), titanium mesh (TM), or polymethyl methacrylate (PMMA). The primary objectives were to assess the overall complication rate, revision rate, and postoperative length of stay (LOS) associated with these materials.

Background: Cranioplasty is a common reconstructive procedure performed to repair skull defects. There is currently no consensus regarding the optimal material for cranioplasty following craniectomy procedures.

Methods: A retrospective chart review was conducted on ninety six patients (n=96) who underwent a cranioplasty procedure between 2017 and 2023 at Inkosi Albert Luthuli Central Hospital (IALCH). Patients were categorised into three groups according to materials used, AB (n=41), TM (n=33), and PMMA (n=22). Demographics, clinical characteristics, postoperative complications and length of stay (LOS) were analysed.

Results: The indications for craniectomy were traumatic brain injury (81,25%), intracranial sepsis (10,42%), tumours (7,29%), and stroke (1,04%). Cranioplasty with AB had the highest complication rate (44%), followed by PMMA (32%) and TM (24%). AB had a 12,19% implant failure rate compared to TM and PMMA which had implant failure rates of 6,06% and 4,55% respectively. Post-operative implant-related collections were reported in 9,76% AB, 6,06% TM and 18,18% PMMA. The PMMA group had a 13,64% infective complication rate compared to AB and TM which had no infective complications. The overall revision rate was 9,76% in AB compared to 3,03% TM and 13,64% PMMA. The average LOS (days) was 10,82 in AB compared to 8,06 TM and 7,95 PMMA.

Conclusion: AB had the highest complication rate, followed by polymethyl methacrylate and titanium mesh. Complications post-cranioplasty resulted in a prolonged LOHS. Selection of material used for cranioplasty should be individualised, especially in resource constrained environments to improve outcomes and prevent complications.

Key words: autologous bone, cranioplasty, complications, titanium mesh, polymethyl methacrylate

P-68

Is There a Separation Between The Superior and Posterior Compartments of The Cavernous Sinus – Microsurgical and Endoscopic Study.

J.Kunicki (1), J. Hur (1), A.Dąbkowska (2)
1. Department of Neurosurgery, M.Sklodowska-Curie National Research Institute of Oncology, Warsaw , Poland
2. Department of Forensic Medicine , Warsaw Medical University

Recently, the new anatomy-based classification of the cavernous sinus compartments was presented, regarding the endoscopic endonasal surgery of the paresellar pathologies. According to this new division, the superior and posterior compartments were the two most commonly invaded (by the pituitary adenoma) compartments. The transition between the superior and posterior compartment was defined arbitrarily as the level of the posterior genu of ICA. As we observe clinical cases of invasive adenomas with selective invasion of the posterior or superior compartments, we hypothesized that there might be a possible partition separating both compartments.

The aim of the study was to verify the above hypothesis by anatomical dissection of the cavernous sinus using different anatomical methods.

Material The study was performed on 50 cavernous sinuses of fresh cadavers with injected arterial vessels. The posterior and superior compartments were dissected from the dorsal side by opening the petroclival venous confluence. Moreover, on 30 sides, the endoscopic examination of the cavernous sinus was performed through the opening within the oculomotor triangle and after the skull base block resection through inf. petrosal sinus preceded the microdissection.

Results: In 18/50 (36%) sides, the ectatic ICA's posterior genu obliterated the posterior compartment's space, making it just potential space. In the remaining specimens the area of the posterior compartment showed structures of different morphology forming the separation between the superior compartment: in 8/32 (25%) the membrane-like structure was observed commonly with fat tissue deposits separating the PC from the superior compartment; 19/32 (59%) the mesh of trabeculae around with meningohypophyseal branches formed an incomplete barrier, the single trabeculae or no structures were found in 5/32(18%). **Conclusions** Our observations show the significant separation of posterior and superior compartments was observed in only 16% of cavernous sinuses in remaining cases the separation was incomplete or absent.

Disclosure of conflict of interest: no conflict of interest

Keywords : cavernous sinus, anatomy, internal carotid artery, endoscopy

P-69

The Meningo Ligamentous Complex of the Dorsum Sellae and Upper Clivus

Jacek Kunicki (1) , Jiyun Hur(1), Agnieszka Dąbkowska (2)

1.Department of Neurosurgery, Maria Sklodowska-Curie *National* Research *Institute of Oncology, Warsaw , Poland*
2. Department of Forensic Medicine Warsaw Medical University, Poland

Background The development of skull base surgery with the use of transdorsum sellae approaches to the retro sellar space and the interpeduncular fossa, understanding the anatomy and architecture of meningeal and bony structures in this area is essential to perform surgery in this area safely.

The aim of the study was to investigate the structure of the dura mater and connective tissue clusters in the region of the dorsum sellae and upper clivus.
Material and methods: The study was done by dissecting the area of the 50 adults of both sexes subjected to autopsy. The dorsum sellae region and the upper clivus were dissected in layers using a microsurgical technique. The fibrous structures between the meningeal lamina and the periosteum of the upper clivus. Colored latex was injected into the carotid artery system. Further studies were performed on isolated and formaldehyde fixed specimens using microsurgical, endoscopic and histological techniques (additional 4 slides).
Results: In 41/50 (82%) cases, a marked osteomeningeal canal corresponding to the sinus of the dorsum sellae was found. The canal was bounded from above by a bone crest hanging over the sinus in a tile manner. The edge of the crest served as an attachment for the bands of connective tissue below the crest. These bands form various ligament-like structures. The following forms were distinguished: Fascial-membrane form in 36% of preparations, medial and lateral dorsoclival ligaments 74%, the petroclival ligaments 83%. The results and observations justify the description of the meningeal ligament complex with the distinction of the more common form of ligaments or fascia. These structures are most likely the result of the differential development of this part of the she skullbase (basipshenoid (basisphenoid cartilage) and ventral tentorium.
Conclusions The results of the study may help to better understand imaging studies and intraoperative anatomy for transdorsum approaches.

Disclosure of conflict of interest: no conflict of interest

Keywords : dorsum sellae, clivus, basilar plexus

FUTURE OF MICRONEUROSURGERY

August 25, 2023

SEMI-SITTING POSITION IN NEUROSURGERY

August 26, 2023

ORAL PRESENTATIONS

SSOP1-1

Semi-Sitting Bilateral Interhemispheric Approach for Resection of Deep Medial Brain Arteriovenous Malformations Without Pre-Operative Embolization: Surgical Techniques And Outcomes

Ari D. Kappel[1], Nirav J. Patel[1]

[1]Department of Neurosurgery, Brigham and Women's Hospital, Harvard Medical School, Boston, MA, USA

Objectives: Safe and successful resection of deep medial AVMs is facilitated by a bilateral interhemispheric semi-sitting position.

Background: Deep, medially located supratentorial cerebral arteriovenous malformations (AVMs) are difficult to treat due to their deep-seated location, deep arterial feeders, and difficult operating corridors. Previous reports describe either a contralateral or ipsilateral approach for surgical resection of these deep-seated brain AVMs. Here, we review our single-surgeon experience utilizing a semi-sitting bilateral interhemispheric approach without pre-operative embolization.

Method: We performed a retrospective single-surgeon case series review of all consecutive deep medial posterior cerebral AVMs treated with a supine, semi-sitting bilateral interhemispheric approach.

Results: Thirteen patients with deep medial brain AVMs underwent surgical resection with a bilateral interhemispheric approach in a supine, semi-sitting position. Five male and eight female patients with a median age at surgery of 37.5 years (range 21-59 years). There was an average Spetzler-Martin (SM) grade of 2.6. Seven cases were ruptured (53.8%) and the average nidus size was 2.8cm (SD 1.1cm, range 1.5-4.6cm). Post-operative cerebral angiogram demonstrated complete resection of all lesions and there was no evidence of residual or recurrent AVM at follow up. There were three cases of perioperative transient visual changes, three cases of transient contralateral weakness, and no cases of venous thrombosis or air emboli. Median follow-up was 22.8months (SD 22.7 months, range 3-72 months) and average mRS score at last follow-up was 0.38 (SD 0.51, range 0 to 1).

Figure 1

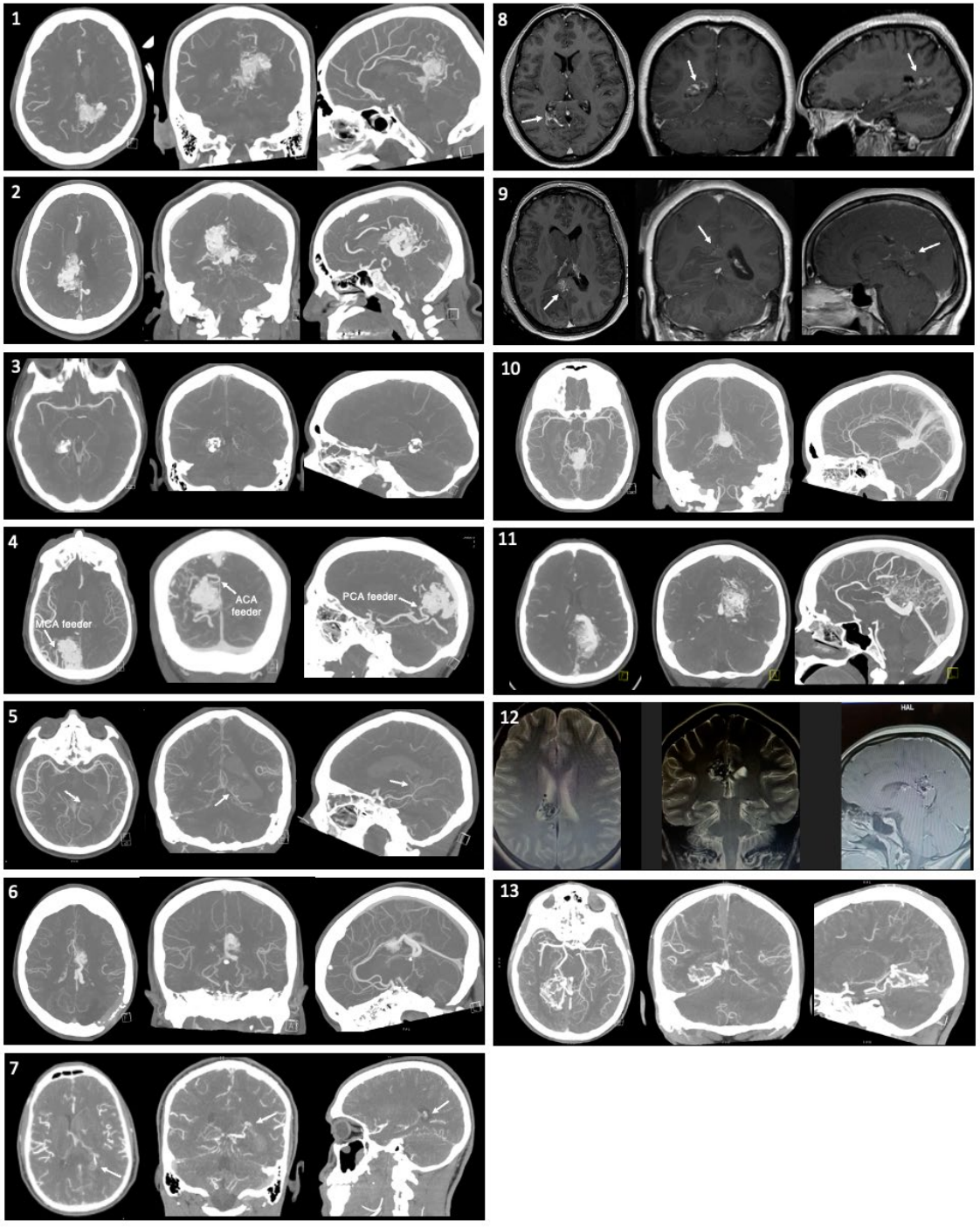

Figure 1: Imaging summary of thirteen cases of deep-seated medial AVMs treated surgically with a semi-sitting bilateral interhemispheric approach without preoperative embolization. Each set of three images per patient shows a representative section of the preoperative axial, coronal, and sagittal CTA or MRI.

Table 1

Case	Age	Sex	Ruptured	Pre-op mRS	Preoperative Neurologic Deficits	Spetzler-Martin Grade (S/E/D)	Nidus size (cm)	Post-operative Neurologic Deficits	Follow-up mRS	Follow-up (months)
1	21	m	y	2	Language deficit	2 (1/0/1)	1.5	None	1	72
2	27	f	y	1	No	1 (1/0/0)	2.2	None	0	61
3	49	f	y	1	No	2 (1/0/1)	2	None	1	6
4	52	m	y	1	No	3 (2/0/1)	4.5	Subtle distal LUE weakness	1	35
5	33	m	y	1	Obtundation	3 (2/0/1)	3.2	None	0	42
6	35	f	n	0	No	1 (1/0/0)	2.2	None	0	14
7	46	m	n	0	No	4 (2/1/1)	4.6	Left inferolateral VF cut	1	14
8	33	f	y	1	Right HH	3 (1/1/1)	1.6	None	0	2
9	59	f	n	1	No	2 (1/0/1)	2.2	None	1	20
10	40	f	n	0	No	3 (1/1/1)	2	Transient cortical blindness	0	3
11	37	f	n	0	No	4 (2/1/1)	4.5	Right sided weakness, resolved	0	7
12	25	f	n	0	No	3 (1/1/1)	2.5	Short term weakness	0	5
13	30	m	y	0	No	3 (2/0/1)	3.6	Left HH	0	6

Table 1: Patient characteristics of the thirteen cases of deep-seated medial AVMs treated surgically with a semi-sitting bilateral interhemispheric approach without preoperative embolization. HH = homonymous hemianopsia; LUE = left upper extremity; S/E/D = size/eloquence/deep venous drainage; VF = visual field

Conclusions: The bilateral interhemispheric semi-sitting approach decreases ipsilateral retraction and allows early access to superficial and deep arterial feeders on the medial side, obviating the need for pre-operative embolization, and reducing the overall risk of intervention. The advantages of the semi-sitting position include bilateral access, improved venous drainage, and neutral anatomy. In our series, this approach allowed for safe and successful resection of all deep medial AVMs.

Keywords: Bilateral interhemispheric approach, Semi-sitting, Arteriovenous malformation, Operative technique

SSOP1-2

Myths and Facts of Sitting Position in Neurosurgery: an Institutional Experience

Veysel Karani Ipek[1], Alican Tahta[1], Bahadir Ciftci[1], Nejat Akalan[1]

[1]Istanbul Medipol University

Objectives: Venous air embolism can be detected by end-tidal CO2 decrease and hypotension.Experienced anesthesiology staff with contemporary peri-operative monitoring enables a safe intervention under sitting position.

Background: Despite the obvious advantages both from anesthesiology and neurosurgery perspective, sitting position in neurosurgery has been declining due to its presumed tendency to cause life-threatening complications. This study aimed to retrospectively analyze the peri- and postoperative incidents where sitting position is invariably utilized both in pediatric and adult cases.

Method: Medical reports of 186 cases who were operated on sitting position between September 2014 and April 2023 were retrospectively analyzed based on perioperative anesthesiology charts. Patients' age ranged from 14 months to 77 years (mean 29.9± 22,014 years).

Results: 186 patients were operated on sitting position (159 had cranial and 27 had cervical pathology). All cases had central venous catheter and radial artery cannula. We performed invasive monitoring including central venous and arterial pressure throughout surgery. Mean operation time was 250 minutes (250±50,35 minutes) .Venous air embolism was detected in 12 patients (6.4%) (11 patients had cranial pathology and one patient had cervical pathology). Venous air embolism which was detected by end-tidal CO2 decrease and hypotension occurred in 6.9% of patients with cranial and 3.7% of patients with cervical pathology. An average of 15 ml air was drawn via the right subclavian vein catheter. Termination of procedure or position change were never needed except for temporary intermission of procedure and closing the surgical area with dampened dressing until normalization of altered values. There was no perioperative and postoperative morbidity/mortality.

Conclusions: Sitting position for cranial and cervical spine surgery have major advantages such as lower intracranial pressure due to enhanced cerebral venous outflow clear field due to gravity drainage of blood and CSF. Incidence and potential peri-and postoperative risks attributed to air embolism were not detected in our series.

Keywords: Air embolism, Neuro-anaesthesia, Sitting position, Complication

References

1. Hermann, Elvis J., et al. "Resection of posterior fossa tumors in the semi-sitting position in children younger than 4 years of age." *Child's Nervous System* 39.1 (2023): 159-167.
2. Gale, T., and K. Leslie. "Anaesthesia for neurosurgery in the sitting position." *Journal of Clinical Neuroscience* 11.7 (2004): 693-696.
3. Ganslandt, Oliver, et al. "The sitting position in neurosurgery: indications, complications and results. a single institution experience of 600 cases." *Acta neurochirurgica* 155 (2013): 1887-1893.

SSOP1-3

Transesophageal Echocardiography Related Side Effects And Complications In Semi-Sitting Position

Ezgi Aytaç[1], Hatice Türe[1], Uğur Türe[1]

[1]Yeditepe University Kosuyolu Hospital

Objectives: Transesophageal echocardiography (TEE) is used as the gold standard for detecting venous air embolism (VAE).It is important for clinicians to understand the side effects and complications associated with TEE. Clinicians should be aware of the risks of TEE and be able to diagnose them

Background: TEE is considered the gold standard for detecting VAE in the semi-sitting position (SSP) during neurosurgery. Our team has regularly used TEE for SSP in neurosurgery for the past 20 years in Turkey. In this study, we aim to report the incidence of complications related to TEE in the SSP for neurosurgery

Method: In our clinic, TEE is performed by experienced anesthesiologists, and all side effects and complications are routinely reported. These include trauma to the oral cavity, injury to the teeth, uvula, pharynx, glottis, stomach, or esophagus, perforation, aspiration, insufficient imaging, edema, dysphagia, dysphonia, bleeding, burns, and infections. We reviewed the medical records of 246 patients, and TEE-related side effects and complications were analyzed statistically

Results: Difficulty in TEE insertion was reported in 12 patients (4.8%), and in such cases. Bite guard-related minor lip injury was reported in 1 patient (0.4%). Dysphagia was reported in 1 patient (0.4%), color changes in the mouth due to the probe were reported in 1 patient (0.4%), and sore throat was reported in 6 patients (2.4%). There were no major complications during the placement of the TEE probe, such as arrhythmia, hypertension, hemodynamic changes, or displacement of the probe, nor ETT malpositioning in our series.

Conclusions: TEE is the gold standard for detecting venous air embolism in the SSP. However, the use of TEE probes can lead to various complications, ranging from dental injuries to esophageal perforation. Despite the majority of complications related to TEE being minor in our series, it is crucial that TEE is performed by experienced anesthesiologists.

Keywords: Transesophageal Echocardıography, Venous Aır Embolısm, Sıde Effect And Complication

References

1. Complications of Transesophageal Echocardiography:Areview of Injuries,Risk Factors,and Management. Kinjal M. Patel, Ronak G. Desai, Keyur Trivedi, Peter J: Neuburger, Sandeep Krishnan, Christopher P. Potestio; Journal of Cardiothoracic and Vascular Anesthesia 36(2022)3292-330
2. Purza R, Ghosh S, Walker C, et al. Transesophageal echocardiography complications in adult cardiac surgery: A retrospective cohort study. Ann Thorac Surg 2017;103:795–802
3. Mishra M, Chauhan R, Sharma KK, et al. Real-time intraoperative transe- sophageal echocardiographyhow useful? Experience of 5,016 cases. J Cardiothorac Vasc Anesth 1998;12:625–32.
4. Kallmeyer IJ, Collard CD, Fox JA, et al. The safety of intraoperative trans- esophageal echocardiography: A case series of 7200 cardiac surgical patients. Anesth Analg 2001;92:1126–30
5. Rousou JA, Tighe DA, Garb JL, et al. Risk of dysphagia after transesopha- geal echocardiography during cardiac operations. Ann Thorac Surg 2000;69:486–9;discussion 489-90.

SSOP1-5

Lateral Semi-Sitting Position: An Alternative

Roberto leal Da Silveira[1], Sebastiao Gusmao[1], Cassius Reis[1], Arthur Nicollato[1], Felipe Maluf[1]

[1]Institute of missionaries of Madre teresa Institute and Hospital - Belo Horizonte - Brazil - Centro de referencia de la Universidad Flanc

Objectives: The aims are to evaluate the lateral semi-sitting position to mimic the advantages and to avoid the hazards of the supine semi-sitting position.

Background: The supine semi-sitting position has been chosen for positioning the patients over many decades, because it improves fluids drainage and provides brain relaxation with the help of the gravity. Notwithstanding, the semi-sitting position still have significant risk of air embolism. Additionally, even medical legal problems have been arising relating to the semi-sitting position. Nowadays, the anesthesiologists are against to face the difficulties of the semi-sitting position.

Method: In the last six years and in more than 100 patients surgical cases we used prospectively the strategies of the lateral semi-sitting position to approach the posterior fossa and the quadrigeminal cistern.The patient is positioned in the lateral position and the proximal part of the table is to elevate the patient approximately to 40-60 degrees. We put a device bellow the buttock of the patient to be seated on. During the surgery we control the degree of sitting by trendelenburg and anti-trendelenburg maneuvers.

lateral semi-sitting position to the Quadrigeminal region

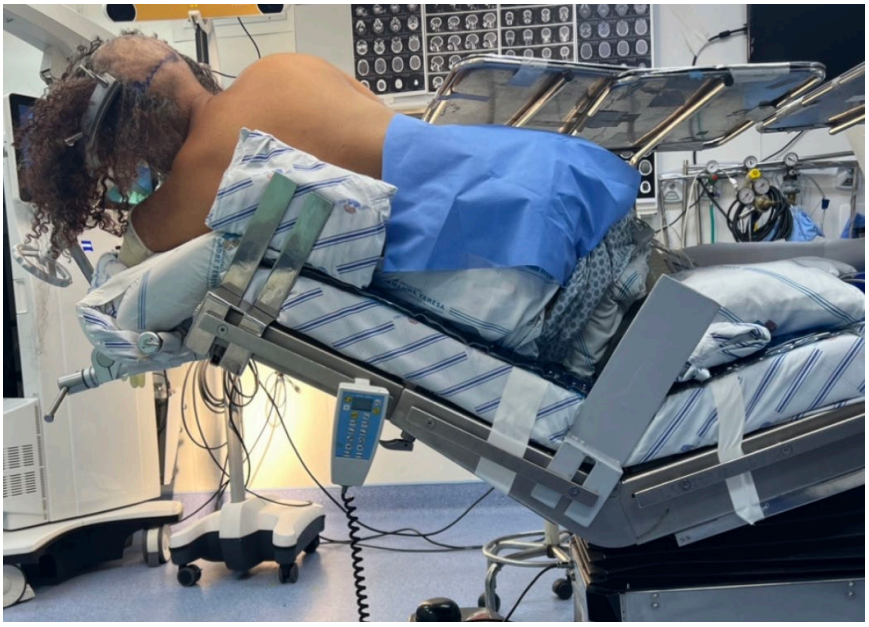

Notice the lateral support before protecting it by a foam and the cushion for the patient to be seated on it.

the lateral semi-sitting position

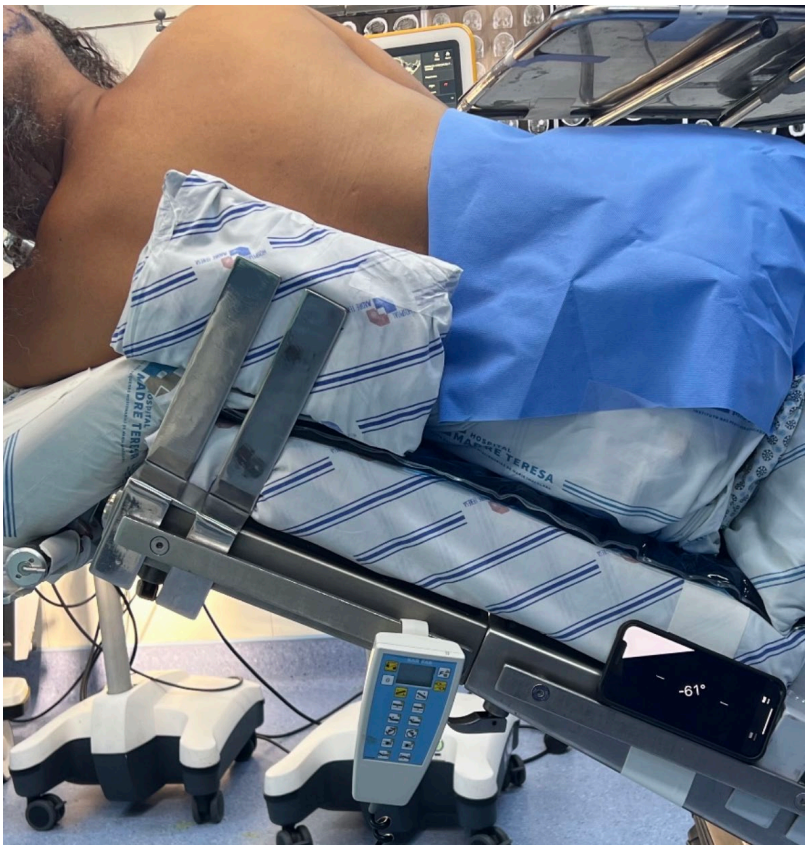

semi-sitting the patient to 61 degrees

lateral semi-sitting position to the lateral posterior fossa



Notice the patient is positioning to the lateral semi-sitting position and protected by supports and be seated on a cushion

Results: This lateral semi-sitting position has been proving to be more ergonomic for the surgeon, safer for the patient, and it was much less difficult to reverse this semi-sitting position in cases of the occurrence of air embolism. Of course, we observe that this position did not offer the same direct drainage of blood and CSF by gravity as it is provided by the supine semi-sitting position. To compensate that we put catheters to irrigate and to aspirate the fluids.

Conclusions: In conclusion, the lateral semi-sitting position has been proving to be very ergonomic for the surgeon, safer to the patient and easier to reverse this type of sitting position.There Is a need of more controlled studies to evaluate its applicability as a good alternative.

Keywords: semi-sitting position, posterior fossa lesions, quadrigeminal cistern, Incisura space

References

1) Air-embolism in the semi-sitting position for craniotomy: a narrative review with emphasis on single centers experience. Tufegdzic B et al. Clin Neurol Neurosurg. 2021. PMID: 34482115 Review.

2) Lateral semi-sitting position: A novel method of patient's head positioning in suboccipital retrosigmoid approaches. VelhoV, et al. Asian j Neurosurg. 2019. PMID: 30937014

SSOP1-6

Anaesthetic Management of Patients were Undergoing Neurosurgery in the Sitting Position- 20 years of Istanbul University-Cerrahpaşa Experience

Özlem KORKMAZ DİLMEN, Merve Tuba ÖZFİDAN, Eren FATMA AKÇIL, Yusuf TUNALI Istanbul University- Cerrahpaşa Department of Anaesthesiology and Reanimation

Background: Although the use of sitting position remains controversial and appears to be diminishing because of the risk of venous air embolism (VAE), it is still routinely using in our centre.

Methods: This is a retrospective analysis of 621 adult and 91 paediatric cases who underwent neurosurgery from January 1995 through December 2010 and between October 2016 and June 2019 in the sitting position. The incidence of VAE and other complications related to the sitting position has been determined. VAE was defined as a sudden and sustained decrease of end-tidal carbon dioxide ($ETCO_2$) ≥0.7kPa.

Results: The incidence of VAE in children and adults were found to be 26.3% (n=24) and 20.4% (n=143) consecutively but the difference was not significant. The incidence of positioning induced hypotension was more in adults (37.6%) compared to children (18.6%, p=0.00001). The presence of COPD (p=0.04) and ASA status (p=0.03) showed a correlation with 'hypotension with positioning'. There was no per-operative mortality (1, 2).

Conclusion: The study provides a significant body of data on neuroanesthesia for the sitting position and our results suggest that if the sitting position is a neurosurgical necessity, it can be used with vigilant follow up throughout the procedure.

References:

1. Dilmen OK, Akcil EF, Tureci E, Tunali Y, Bahar M, Tanriverdi T, Aydin S, Yentur E. Neurosurgery in the sitting position: retrospective analysis of 692 adult and pediatric cases. Turk Neurosurg. 2011;21(4):634-40. PMID: 22194128.
2. Dilmen OK, Akcil EF, Vehid H, Tunali Y. Cerebral oxygenation assessed by near-infrared spectroscopy in the sitting and prone positions during posterior fossa surgery: a prospective, randomized clinical study. Braz J Anesthesiol. 2021 Oct 7:S0104-0014(21)00375-4. doi: 10.1016/j.bjane.2021.09.016. Epub ahead of print. PMID: 34626757.

Table-1. Demographic Values

Factor	Adult (n = 621)	Children (n = 91)	*p* value
Age (years, mean ± SD)	43.8 ± 14.2	8.1 ± 4.4	N/A
Gender (n, M/F)	273/348	50/41	0.04
Body weight (kg, mean ± SD)	71.2 ± 13.9	30.2 ± 17.7	N/A
Height (cm, mean ± SD)	164.3 ± 14.0	146.1 ± 22.1	N/A
History of hypertension (n)	64 (10.4 %)	0	0.00001
History of asthma (n)	5.5 (0.9 %)	0	1.0
History of cardiac disease (n)	17 (2.8 %)	1 (1.0 %)	0.48
History of COPD (n)	15 (2.4 %)	0	0.14
ASA physical status (n)			0.00001
I	298 (48.0 %)	62 (68.1 %)	
II	168 (27.1 %)	9 (9.8 %)	
III	84 (13.6 %)	10 (10.9 %)	
IV	68 (11.1 %)	10 (10.9 %)	

N/A: Not applicable. n: number

COPD: Chronic Obstructive Pulmonary Disease

ASA: American Society of Anesthesiology

Table-2. Summary of intraoperative events related to incidence of venous air embolism (VAE) in children and adults.

Factor	Adult (n = 621)	Children (n= 91)	*p*
No. of patients with VAE, n (%)	126 (20.4)	24 (26.3)	0.21
VAE with hypotension, n (%)	52 (41.4)	11 (45.8)	0.76
VAE with hypoxia, n (%)	1 (0.8)	0	1.0
VAE with bradycardia, n (%)	19 (15.4)	6 (6.5)	0.23
VAE with tachycardia, n (%)	27 (21.9)	6 (6.5)	0.69
VAE with arrhythmia, n (%)	19 (15.4)	5 (20.8)	0.43
VAE with air aspiration, n (%)	101 (82.1)	19 (79.1)	0.67
Repeated episodes of VAE, n (%)	16 (13.0)	2 (8.3)	0.71
Position changes required, n (%)	2 (1.6)	0	1.0
Timing of VAE , n (%)			0.26
Head holder fixation	1 (0.1)	0	
Crani(otomy)ectomy	74 (11.9)	10 (10.9)	
During the procedure	49 (5.3)	12 (13.1)	
During closure	2 (0.3)	2 (2.1)	

SSOP1-7

Craniotomy in Semi-Sitting Position: A 3-year Single Institution Experience

Arunabha Karmakar, Muhammad Jaffar Khan, Ayten Saracoglu, Merve Ergenc, Kemal Tolga Saracoglu, Kishore Kumar Gangineni, Neeraj Kumar

Hamad Medical Corporation, Qatar University

Objectives: Our primary aim was to review our institutional experience of craniotomies conducted in sitting position and monitor for neurological outcome. Our secondary aim was to determine the relative incidence and severity of major known complications of sitting position in our patient population.

Background: Our neurosurgery team successfully performs more than 1000 surgeries annually while maintaining highest international quality levels. The neuroanesthesia fellowship program provides a multidisciplinary team approach to deliver the most compassionate care for patients., We reviewed the outcome of patients undergoing craniotomy in sitting position from 2019 to present. The study focused on perioperative outcomes and complications associated with craniotomy in sitting position.

Method: The electronic medical record database was used. Beginning from 2019, all adult patients undergoing craniotomy in sitting position were included. Individual patient charts were examined for significant events during the intraoperative and postoperative period. Any critical or adverse event were recorded.

Results: A total of 10 patients underwent craniotomy in sitting position from 2019 till date. Induction and maintenance of general anesthesia were accomplished using target controlled infusion total intravenous anesthesia with remifentanil and propofol. The patiens' demographics, diagnosis, duration of anesthesia, estimated blood loss and complications were summarized in Table. Moreover, the outcome related with intraoperative fluid management, mannitol use and urine output was displayed. Nine of 10 patients had pneumocephalus with one patient developing severe manifestations. One patient developed clinically significant venous air embolism with severe manifestations including massive pleural effusion. Except one patient, all were extubated at end of surgery.

Results

Serial No.	Age (yr)/ gender/ weight (kg)	Cranial pathology	Duration of anesthesia	Major hypotensive episode (Y/N)	Intra-op fluids	Intra-op vasopressor/vasodilator	Mannitol	Urine output	Estimated blood loss	Venous air embolism	Pneumocephalus	Delayed extubation (y/N)	Post-op nausea and vomiting	Other complications
1	33/M/70	Pineal gland pilocytic astrocytoma	7 h 55 min	Y	NS:2100 ml PPF: 500 ml	PE 100 mcg NE 693.3 mcg Eph 6 mg	35 gm	1500 ml	250 ml	N	Y- uneventful	N	N	Hyponatremia (SIADH vs Adrenal insufficiency); Unequal pupils, Upward gaze palsy. Gradually improved

2	39/M/92	Right CP angle acoustic schwannoma	8h 32min	Y	NS: 2300 ml PPF: 500 ml	NE: 292.6469 mcg	50 gm	3000 ml	300 ml	N	Y-uneventful	N	Y	Hypertension; Right Facial nerve LMN palsy
3	57/F/137	Left posterior fossa cerebellar metastatic breast invasive ductal carcinoma	6 h 35 min	Y	NS: 1000 ml PPF : 500 ml	PE: 900 mcg NE: 840 mcg	80 gm	1500 ml	250 ml	N	Y-uneventful	N	N	No immediate post-operative complications. Progression of cranial pathology with mortality
4	63/F/69	Metastatic cervical cancer left superior cerebellar peduncle	6 h 46 min	Y	NS 1500 ml	PE: 500 mcg NE: 0.3817 mg	-	-	250 ml	N	Y- significant. . Pneumocephalus at the subdural space of the left temporal and both frontal lobes with underlying Mass effect. High ICP. Hypertension and bradycardia.	N	Y. Multiple episodes	Intra-operative bradycardic episodes during surgical manipulation. Pre-operative cerebellar signs improved but still had ataxic gait.
5	35/M/83.8	Right acoustic schwannoma	6h 3min	y	NS 500 ml PPF 500 ml Plasmalyte 1000 ml	PE 466.6 mcg NE: 1291.66 mcg Eph 12 mg	40 gm	2500 ml	250 ml	N	N	N	Y	
6	33/M/80	Meningothelial meningioma of the pineal gland	6h 56 min	y	NS 2000 ml PPF 1000 ml	NE 513.3 mcg	40 gm	2800 ml	300 ml	N	Y-uneventful	N	N	Post-op Dilation of lateral and third ventricle and right temporal subgaleal hematoma. Patient had developed staring episodes. Otherwise maintaining patent airway. EVD inserted. Patient improved. However he also had diplopia, left foot numbness and later on headache.
7	33/F/109	Left CP angle vestibular schwannoma	7h 40 min	N	NS 2100 ml PPF 500 ml RL 500 ml	NE 2.48 mg	45 gm	3000 ml	100 ml	Y-complicated by desaturation episode, high oxygen requirements, ARDS, Massive pleural effusion, AKI , Sepsis, Sick euthyroid syndrome	Y-uneventful	Y	N	She had prolonged Surgical Intensive Care Unit stay and later improved. Follow up in Neurosurgery clinic showed left sided facial weakness

8	50/M/86	Right CP angle schwannoma	8H 31 min	Y	NS 3500 ml PPF 1250 ml	PE 416.6667 mcg NE 1.4367 mg	50 gm	1800 ml	400 ml	N	Y- uneventful	N	N	Patient developed nosocomial meningitis or focal encephalitis. He was treated and he improved. Long term follow up showed right sided facial numbness .
9	44/F/60	Large pineal parenchymal tumour of intermediate differentiation	7H 45 min	Y	NS 1200 ml PPF 1000 ml	PE 1000 mcg NE 240 mcg Labetalol 40 mg (To control one episode of sudden surge in blood pressure > 170 mm Hg)	30 gm	1600 ml	250 ml	N	Y- uneventful	N	N	Post operatively patient had occasional polyuria, Horizontal nystagmus, On and off diplopia and left eye burring of vision
10	49/F/65.75	Right vestibular schwannoma	7 h 10 min	Y	NS 500 ml PPF 750 ml RL 500 ml	PE 660 mcg NE 800 mcg	20 gm	1800 ml	200 ml	N	Y-Uneventful	N	N	Right sided bell's palsy was noted in neurosurgical follow up.
NS: Normal Saline; PPF: Plasma Protein Fraction; RL Ringer's lactate; Eph: Ephedrine; PE: Phenylephrine; NE: Nor-Epinephrine														

Conclusions: During last three years our neuroanesthesia team recorded 10 craniotomies in sitting position. There was no mortality. Ninety percent of patients were managed without any major long-term sequelae. We concluded that sitting position for craniotomy is not without its challenges. However, a dedicated experienced team can manage possible complications and improve patient outcomes.

Keywords: Sitting Position, Craniotomy, Pneumocephalus, Venous Air Embolism

References

1) Sloan T. The incidence, volume, absorption, and timing of supratentorial pneumocephalus during posterior fossa neurosurgery conducted in the sitting position. J Neurosurg Anesthesiol 2010; 22:59.

2) Ganslandt O, Merkel A, Schmitt H, et al. The sitting position in neurosurgery: indications, complications and results. a single institution experience of 600 cases. Acta Neurochir (Wien) 2013; 155:1887.

SSOP1-8

Semisitting Position for Posterior Fossa Tumors in Children

Oscar Garcia[1]

[1]Hospital Regional De Alta Especialidad Del Bajio

Objectives: We report about our experience with the semi-sitting position in 21 surgical procedures in children with posterior fossa tumors.

Background: The semi-sitting position is one of the preferred positions for resection of posterior fossa midline tumors. Nevertheless, it harbors some risks, with the most dreaded beeing airembolism. In small children another additional risk is rigid head fixation.

Method: Nineteen children younger than 17 years of age were operated (Aug 2019-Jun 2022) in the semi-sittingposition (mean age: 6.5 years; range between 1.8m and 16y). Persistent foramen ovale wasexcluded preoperatively in 15/19 patients. Intraoperative incidents were recorded and patientscourse followed postoperatively with a special focus on possible complications.

Results: The histopathological diagnoses included ependymoma (n=5), pilocytic astrocytoma(n=2), exofitic brainstem glioma (n=2), medulloblastoma (n=10). CSF shunt/ETV were done in 17of 19 children who presented with hydrocephalus preoperatively. No major intraoperativecomplications occurred. Air venous embolism was detected in 2 patients during surgery, the air embolismwas recorded in TEE without cardiovascular or respiratory signs or symptoms. In one patientarterial hypotension with reduction of pCO2 occurred and it was treated successfully withchatacholamin infusion and suction of air embolism via a central venous catheter withoutpostoperative complications due to the embolism. Postoperatively all children showedpneumocephalus and one of them developed a subdural hygroma and was treated by burr-holedrainage. No skull fractures were documented postoperatively using rigid fixation system. Revision surgery was necessary in two children, one child with subtotal resection and another patient with recurrence 8 months later.

Conclusions: The semi-sitting position for tumor resection of the posterior fossa in children under 16 years of age entails certain risks, however, it can be successfully performed taking special caution to detect and treat potential complications in an interdisciplinary teamwork with specializedneuroanaesthesiologists.

Keywords: Semisitting, Venous Air embolism, Posterior fossa tumors, Children

References

Teping F, Linsler S, Zemlin M, Oertel J. The semisitting position in pediatric neurosurgery: pearls

and pitfalls of a 10-year experience. J Neurosurg Pediatr 28:724–733, 2021.DOI: 10.3171/2021.6.PEDS21161.

SSOP2-9

Pregnant Patients underwent Neurosurgery in Semi-Sitting Position; Tree Cases

Bilgin H[1], Gacemer C[1], Aydin LG[1], Kocaeli H[2]
Bursa Uludag University Faculty of Medicine, Department of Anesthesiology and Reanimation[1] and Department of Neurosurgery[2]

Introduction

Semi-sitting position is related to major complication such as venous air embolism (VAE)(1). The incidence of VAE which was diagnosed by precordial doppler (PD) was 13.8%, 40% of these patients became hypotensive and 57% of these followed up by a decrease of end tidal CO_2 ($EtCO_2$)(5). Pregnancy can mask these symptoms. We analyzed the reports of 3 pregnant patients who underwent neurosurgery in semi-sitting position.

Methods

In that patients received an intravenous line, central venous catheter (CVC), five-lead ECG, invasive blood pressure, capnogram, pulse oxymetry and PD. When a loud *millwheel murmur* was audible or a five mmHg decrease of $EtCO_2$ and suddenly 10% changes of heart rate (HR) or blood pressure (BP) concidered as air embolism. The surgical area was covered to prevent new air inlets and air aspirated from right atrium through CVC when VEA diagnosed.

Results

The millwhell murmur was heard twice during follow-up with PD during surgery for first patient. Air was aspirated twice from the CVC during the operation. In the 30th minute and 90th minute of the case, decrease in BP and an increase in partial CO_2 pressure ($PaCO_2$) in the simultaneous blood gas were detected. All of the clinical variables of tree patients are shown in Table 1. All patients were taken to the intensive care unit as intubated.

Table 1. Ages, gestation weeks, diagnosis and some datas.

Age (year)	Gestation weeks	Surgery	VAE	PD	E_TCO_2	$PaCO_2$	BP	HR	Duration (min)
22	19	AVM	2 times	+	+	+	+	-	300
26	26	Hemangioblastoma	-	-	-	-	-	-	330
35	30	Cerebellar hemorrhage	-	-	-	-	-	-	400

Discussion and Conclusion

Pregnancy and VAE both cause similar cardiovascular and respiratory changes such as decrease of BP, increase of HR, decrease of $EtCO_2$. This situation may complicate the clinical diagnosis of VAE in pregnant women. VAE is detectable by PD in approximately 40% of patients and by TEE in up to 76% (4). Surgeries in semi-sitting position should be followed by sonography.

References

1. Tufegdzic B, et al. Clin Neurol Neurosurg. 2021;209:106904.
2. Bilgin H, et al. *Turk* J Anaesthesiol Reanim. 2003:31: 457-61.
3. Papadopoulos G. Et al. Acta Neurochir (Wien). 1994;126:140-43.

SSOP2-10

Endoscopic Ventriculoport Approaches to Third Ventricle And importance of Water Pressure in Semisitting Position

Bulent DUZ[1]

[1]Private office of Bulent DUZ

Objectives: The volume of third ventricle is very important during third ventricular approach and how it is possible to keep lateral ventricle volume using water pressure under semi sitting position will shown in this presentation.

Background: Third ventricle is very narrow space and all borders and walls are eloquent areas. During approaches to third ventricle, removing CSF from lateral ventricles and third ventricle is necessary in microscopic operations. In endoscopic operations removing CSF form ventricles is not necessary. In endoscopic operations we are working underwater. Ventriculoprt surgery is a combination of microscopic and endoscopic surgery. Ventriculoport is a channel from cortex to lateral ventricle which provides access to third ventricle via Foramen Monroe.

Method: In between 2006-2023 Author has done 200 third ventriculostomies and 35 lesions including colloid cyst, mesencephalic tumors metastasis and arachnoid cysts of third ventricle with ventriculoport technique.

Results: There is not any death or infection related to approach. Colloid cysts removed totally. In one colloid cyst case recurrence ccurred and reoperated. In the operation when CSF is removed from lateral and third ventricle the shrinkage of third ventricle volume is observed. When water is replaced and position is changed to semi sitting position the volume of third ventricle is enlarged again. Together with third ventricular shrinkage, in most cases the third ventriculostomy borders are also approached and orifice of Forman Monroe is also decreased or closed.

Conclusions: Enlargement the volume of third ventricle is very important in order to make maneuvers inside the third ventricle. In a narroved third ventricle, maneuverability of instruments is decreased and sometimes becomes impossible. Keeping third ventricle volume enlarged using water pressure under semi sitting position makes third ventricle approach feasible.

Keywords
colloid cyst , third ventricle , third ventriculostomy , ventriculoport

References

1. Harris AE, Hadjipanayis CG, Lunsford LD, Lunsford AK, Kassam AB. Microsurgical removal of intraventricular lesions using endoscopic visualization and stereotactic guidance. Neurosurgery. 2005 Jan;56(1 Suppl):125-32; discussion 125-32. doi: 10.1227/01.neu.0000146227.75138.08. PMID: 15799800.

SSOP2-12

Use of Semi-sitting Position for Posterior Circulation Aneurysm Surgery.

Yagmur Tuncbilekli[1], Hanside Setenay Unal[1], Pınar Eser[1], Hasan Kocaeli[1], Hülya Bilgin[2]

[1]Uludag University School of Medicine Department of Neurosurgery
[2]Uludag University School of Medicine Department of Anesthesiology and Reanimation

Objectives: We present 3 cases of posterior circulation aneurysms who were operated on in the semi-sitting position.

Background: Surgery in semi-sitting position has became rare for posterior circulation aneurysm surgery. This position has some advantages such as improved venous drainage, reduced intracranial pressure and blood loss. Disadvantages are air embolism, pneumocephalus and intracranial hypoperfusion. (1)

Method: We retrospectively analyzed clinical records of three patients with posterior circulation aneurysms who were operated on in the sitting position.

Results: Case 1: 28-year-old female patient who presented acute hydrocephalus due to a partially thrombosed, giant P3 segment PCA aneurysm. The patient was operated on in the semisitting position, and a right frontal ventricular drain was placed for brain relaxation. With posterior interhemispheric approach, the aneurysm thrombectomised and clipped. Postoperative computed tomography and magnetic resonance imaging revealed resolution of the hydrocephalus, and cerebral angiography confirmed total exclusion of the aneurysm from the circulation and occlusion of the P4 segment of the PCA, which was considered embolic. Case 2: 46-year-old female patient who presented acute hydrocephalus due to subarachnoidal hemorrhage. Cerebral angiography revealed a right sided ruptured PICA aneurysm. The patient was operated on in the semisitting position via a suboccipital craniotomy. Postoperative cerebral angiography confirmed total exclusion of the aneurysm. Case 3: 46-year-old female patient who came to hospital with complaints of severe headache, nausea and vomiting that started 10 days ago. Imagings showed subarachnoid hemorrhage and left superior cerebellar artery aneurysm. Attempted coil embolization was failed and the patient was operated on in the semi-sitting position with infratentorial-supracerebellar approach. No residual or recurrence aneurysm was detected in the control cerebral angiography.

Conclusions: The semi-sitting position provides a safe surgical access for posterior circulation aneurysm surgery.

Keywords: Semi-sitting Position, Posterior Circulation Aneurysm

References

1. De Cassai A, Geraldini F, Zarantonello F, et al. A practical guide to patient position and complication management in neurosurgery: a systematic qualitative review. Br J Neurosurg. 2022;36(5):583-593. doi:10.1080/02688697.2021.199559

SSOP2-13

Pineal Region in Semi-Sitting Positions: Anatomical Surgical Nuances for Safe Landing

Alhusain Nagm[1]

[1]Department of Neurosurgery University of Maryland School of Medicine, Baltimore, MD, United States
[2]Department of Neurosurgery, Al-Azhar University School of Medicine, Cairo, Egypt.

Objectives: The steep tentorial angle could misdirect novice neurosurgeons (nNS), leading them to be landed at a higher destination, struggle early with the galenic venous system, and mistakenly identify the splenium as the pineal gland. Perhaps a stepwise cadaveric simulation guide could help neurosurgeons to achieve safer accessibility with reasonable maneuverability. It is worthier for nNS to start cadaveric training early in their careers to shorten the learning curve.

Background: Pineal region surgery in semi-sitting positions is challenging for both neurosurgeons and neuro-anesthesiologists.

Method: Four colored-injected formalin-fixed heads were dissected to study the surgical steps to the pineal region in semi-sitting positions via a modified supracerebellar infratentorial (+/- trans-tentorial, +/- trans-falx cerebelli) approach. Anatomical targets (n= 6) in the pineal region were identified. The data were collected and analyzed.

Results: Three-dimensional planes (vertical, horizontal, depth) were utilized to apply three stepwise-surgical phases (lateral-to-medial “trochlear phase”, up-down “venous phase” and down-up “colliculi/balls phase”) were achieved to get a safe landing on the pineal region “approaching the pineal lesion from normal-to-abnormal”. The trans-tentorial and trans-falx cerebelli windows were selectively added to better identify the pulvinar/trochlear nerve and to enhance the central exposure “cross the midline to the contralateral side”, respectively. Reasonable visual validation and maneuverability were feasible for all targets (n=6) targets (Galenic venous system “including all territories”, splenium of the corpus callosum, pulvinar, trochlear nerve, brainstem colliculi, and pineal gland).

Figure 1

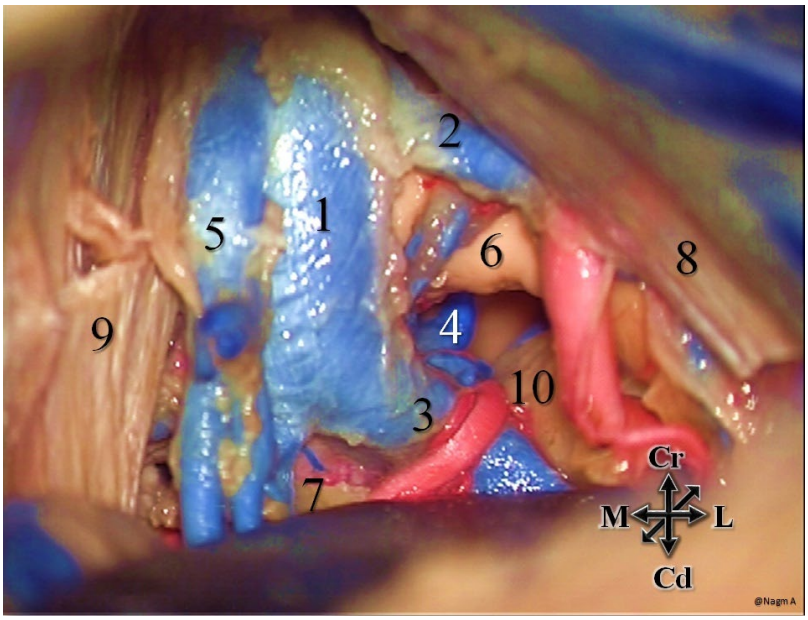

Galenic venous system

Figure 2

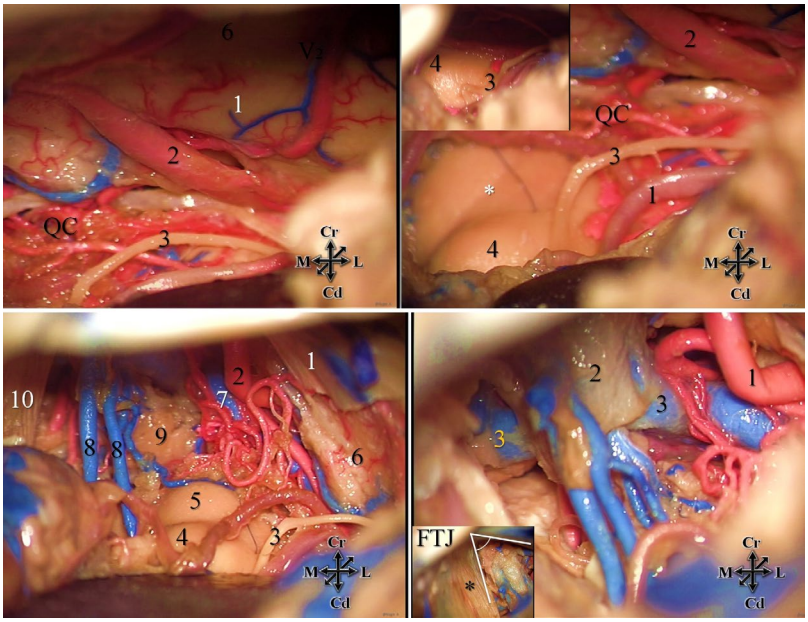

trochlear nerve from lateral to medial

Figure 3

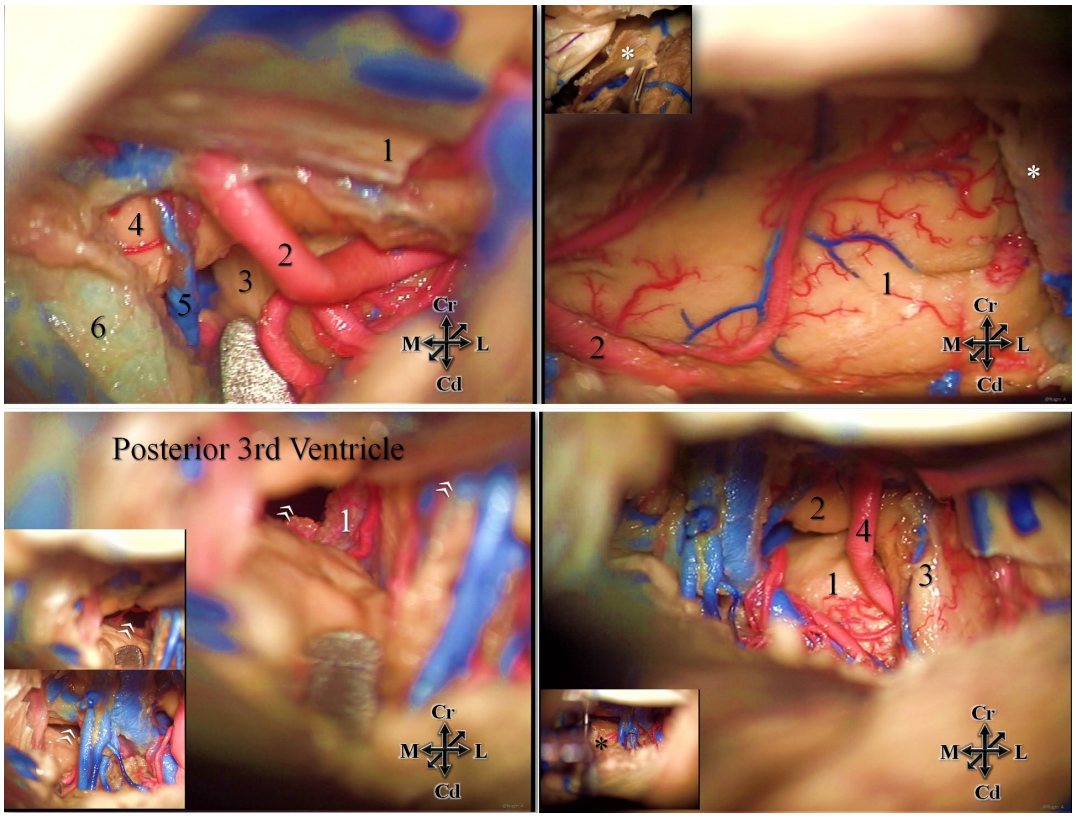

transtetorial and transfalx cerebelli windows for reasonable maneuverability

Conclusions: To ensure fruitful pineal region surgery with safer accessibility and reasonable maneuverability, our three stepwise-surgical phases (in 3D orientation) could be considered as a guide for surgeons to avoid false destinations in semi-setting position.

Keywords: Pineal Region, Semi-Sitting Position, cadaveric dissection, Vein of Galen

References

1. Matsuo S, Baydin S, Güngör A, Miki K, Komune N, Kurogi R, Iihara K, Rhoton AL Jr. Midline and off-midline infratentorial supracerebellar approaches to the pineal gland. J Neurosurg. 2017 Jun;126(6):1984-1994.

SSOP2-14

Semi-Sitting Position Experience for Brainstem and Cerebellar Lesions: Retrospective Evaluation of Five Cases

Batu Hergünsel[1], Serkan Çopur[1], Duygu Dereli[1], Saime Ayça Şahin[1], Aysel Salkaya[2], Sibel Oba[2], Adem Yılmaz[1]

[1]Şişli Hamidiye Etfal Training and Research Hospital, Department of Neurosurgery
[2]Şişli Hamidiye Etfal Training and Research Hospital Department of Anesthesiology

Objectives: We aimed to share our experience on cases operated in the semi-sitting position with discussing the potential risks and benefits of the technique.

Background: In the surgical treatment of lesions located in the posterior fossa or brainstem, semi-sitting position has advantages such as easy removal of blood from the surgical field, using gravity retraction and providing a relatively wider exposure. However, this approach also carries life-threatening risks such as venous air embolism.

Method: We present five patients with brainstem and posterior fossa lesions who underwent surgery between 2022 and 2023. Three of the cases were female and two were male. The age range was 2-69. Two cases were operated for brainstem cavernoma, one case for cerebellar astrocytoma, one case for recurrent cerebellar hemangioblastoma, and one case for medial temporal gangliocytoma.

Results: Besides standard procedures such as electrocardiography, pulse oximetry, urinary catheter, and temperature monitoring, all cases were applied invasive arterial blood pressure monitoring with radial artery catheterization, subclavian catheter placement and regional cerebral oximetry. The case with recurrent cerebellar hemangioblastoma developed a sudden decrease in end tidal carbon dioxide pressure while the dura was closed. The patient was placed in a horizontal position and air was aspirated from the subclavian catheter. The surgery was completed uneventfully. None of the cases had any additional neurological deficits save for one brainstem cavernoma case who developed bilateral medial gaze deficit postoperatively.

Conclusions: Besides its surgical advantages, the sitting position is an approach that should be carefully followed and managed due to the risk of venous air embolism. The risk-benefit analysis should be evaluated on a case-by-case basis and the approach should be limited to selected cases.

Keywords: posterior fossa, semi-sitting position, venous air embolism

References

1) Porter JM, Pidgeon C, Cunningham AJ. The sitting position in neurosurgery: a critical appraisal. Br J Anaesth. 1999
2) Tufegdzic B, Lamperti M, Siyam A, Roser F. Air-embolism in the semi-sitting position for craniotomy: A narrative review with emphasis on a single centers experience. Clin Neurol Neurosurg. 2021
3) Himes BT, Mallory GW, Abcejo AS, Pasternak J, Atkinson JLD, Meyer FB, Marsh WR, Link MJ, Clarke MJ, Perkins W, Van Gompel JJ. Contemporary analysis of the intraoperative and perioperative complications of neurosurgical procedures performed in the sitting position. J Neurosurg. 2017 Jul;127(1):182-188.
4) Ammirati M, Lamki TT, Shaw AB, Forde B, Nakano I, Mani M. A streamlined protocol for the use of the semi-sitting position in neurosurgery: a report on 48 consecutive procedures. J Clin Neurosci. 2013 Jan;20(1):32-4.
5) Al-Afif S, Elkayekh H, Omer M, Heissler HE, Scheinichen D, Palmaers T, Nakamura M, Hermann EJ, Samii M, Krauss JK. Analysis of risk factors for venous air embolism in the semisitting position and its impact on outcome in a consecutive series of 740 patients. J Neurosurg. 2021 Nov 5:1-8.

SSOP2-15

Our Clinical Experiences in Semi-Fowler Position in 2 Years

Kadriye Serap Karacalar[1], Gaye Şensöz Çelik[1], Ahmet Yasin Yavuz[1], Gökhan Perçinoğlu[1], Volkan Özen[1]

[1]Prof. Dr. Cemil Taşcıoğlu Şehir Hastanesi

Objectives: We aimed to focus on the intraoperative and postoperative complications and hemodynamic effects of neurosurgical operations performed in the semi-Fowler position and share our experiences.

Sitting position



Background: Various patient positions are used in neurosurgery, with the sitting positions being preferred, especially in posterior fossa surgeries. Studies have explored the impact of patient position on complications such as venous air embolism (VAE), haemorrhage, and operation duration. The sitting position in neurosurgery is associated with reduced blood transfusion, longer operation duration, and a higher risk of venous air embolism and hemodynamic instability (1-3).

Method: Ten patients who underwent surgery in the semi-Fowler position in the last 2 years, at the Department of Neurosurgery were retrospectively reviewed.

Results: Patients' demographic data are given in Table-1. Intraoperative and postoperative events are given in Table-2.

Table-1

Case number	Age	Gender	ASA Score
1	36	W	1
2	2	W	1
3	68	M	2
4	4	M	1
5	23	M	1
6	48	W	1
7	40	M	1
8	32	M	1
9	49	M	1
10	5	M	1

Patients' demographics

Table-2

Case number	Hemodynamics	Intraoperative transfusion	Complication	Operation duration(hr)
1	Unstable	+	VAE	8
2	Unstable	-	-	6
3	Stable	-	Hematoma	10
4	Stable	-	-	6
5	Unstable	-	-	5
6	Stable	-	VAE, Hematoma	6
7	Stable	-	-	5
8	Stable	-	-	3
9	Unstable	-	VAE	6
10	Stable	-	-	12

Intraoperative and postoperative events

Conclusions: The incidence of venous air embolism (VAE) in sitting neurosurgery varies from 7% to 76% (4,5). Our study detected VAE in 30% of cases, but these patients were discharged without complications after postoperative follow-up. Intracerebral haemorrhage can occur after posterior fossa surgeries (6,7). We observed intracerebral hematoma in two patients and subdural hematoma in one patient, requiring reoperation. One patient developed intracerebral infarction and was diagnosed with brain death. Hypotension is more common in the sitting position compared to the horizontal position (2). Among our patients, hypotension occurred in four cases, two of which were diagnosed with VAE. Pneumocephalus can occur in both semi-Fowler and supine positions but usually does not require intervention (9,10). Eight of our patients were diagnosed with pneumocephalus, which was asymptomatic and didn't require intervention. In conclusion, while the horizontal position is preferred in many centres, the sitting position remains necessary in certain cases. Both positions are used in our clinic, and the choice should be based on individual patient considerations, taking into account the advantages, disadvantages, and surgical indications

Keywords: Semi-Fowler, Venous Air Embolism, Neuroanaesthesia

References

1. Rath GP, Bithal PK, Chaturvedi A, Dash HH. Complications related to positioning in posterior fossa craniectomy. J Clin Neurosci. 2007 Jun;520–5.
2. Mavarez-Martinez A, Israelyan LA, Soghomonyan S, Fiorda-Diaz J, Sandhu G, Shimansky VN, et al. The Effects of Patient Positioning on the Outcome During Posterior Cranial Fossa and Pineal Region Surgery. Front Surg. 2020 Mar;
3. Türe H, Harput MV, Bekiroğlu N, Keskin Ö, Köner Ö, Türe U. Effect of the degree of head elevation on the incidence and severity of venous air embolism in cranial neurosurgical procedures with patients in the semisitting position. J Neurosurg. 2018 May;1560–9.
4. Palmon SC, Moore LE, Lundberg J, Toung T. Venous air embolism: a review. J Clin Anesth [Internet]. 1997 May [cited 2023 Jun 15];9(3):251–7. Available from: https://pubmed.ncbi.nlm.nih.gov/9172037/
5. Matjasko J, Petrozza P, Cohen M, Steinberg P. Anesthesia and surgery in the seated position: analysis of 554 cases. Neurosurgery. 1985 Nov;695–702.
6. Asheesh Tondon MS, A.K. Mahapatra MCh. Superatentorial intracerebral hemorrhage following infratentorial surgery. Journal of Clinical Neuroscience. 2004 Jul;11(7).
7. Lafta GA, Dolachee AA. CASE REPORT-OPEN ACCESS Supratentorial intracerebral hemorrhage as a complication of infratentorial tumor removal: A case report. Int J Surg Case Rep [Internet]. 2020 [cited 2023 Jun 15];75:1–3. Available from: https://doi.org/10.1016/j.ijscr.2020.08.031
8. İşçimen R, Bilgin H, Korfalı G, Atlas A, Korkmaz S. Oturur pozisyonda venöz hava embolisi görülme sıklığı: 185 olgunun analizi. Türk Anesteziyoloji ve Reanimasyon Dergisi. 2009;37(5):304–13.
9. Gader G, Rkhami M, Daghfous A, Zouaghi M, Zammel I, Badri M. Pneumocephalus after posterior fossa surgery in prone position: Is that any clinical effect? Int J Surg Case Rep. 2022 Jan 1;90.
10. Machetanz K, Leuze F, Mounts K, Trakolis L, Gugel I, Grimm F, et al. Occurrence and management of postoperative pneumocephalus using the semi-sitting position in vestibular schwannoma surgery. [cited 2023 Jun 15]; Available from: https://doi.org/10.1007/s00701-020-04504-5

SSOP2-16

Venous Air Embolism in Sitting Position: a Case Report

Ozge Sayin Ayan[1], Kadriye Serap Karacalar[1], Ahmet Yasin Yavuz[1]

[1]Prof.Dr.Cemil Tascioglu Sehir Hastanesi

Objectives: Emphasize the vital importance of placing the CVC in the correct location in the management of air embolism

Background: The sitting position is commonly used for patients undergoing cervical spine and posterior cranial fossa surgery.The advantages of this position include excellent surgical access, neck through enhanced ventilation and decrease in intracranial pressure. However, along with these advantages, the sitting position carries an increased risk of VAE.

Method: A case

Results: A 36-year-old female patient with ASA class 1 was scheduled for VP shunt and tumor excision from the pineal region.TIVA was initiated after induction.Due to technical issue with the USG guidance,the left subclavian vein was chosen for CVC placement since VP shunt catheter was already in the right side of the patient's neck.The correct position was confirmed by fluoroscopy, showing that was 1.5cm above the right atrium at the distal end of the superior vena cava.Fifteen minutes into the surgery, sudden drop in EtCO2 and hypotension occurred.The patient was repositioned supine while attempts were made to aspirate from the catheter,but no air was obtained.After 5 minutes,the patient's hemodynamics and EtCO2 values returned normal.In sitting position ,second episode of air embolism compromised the patient's hemodynamics,the surgical team decided to stop the operation.After two days,with the guidance of USG,the CVC was inserted through the right subclavian vein.The surgery's 20th minutes air embolism occurred,20ml of air was aspirated from the CVC.The patient's hemodynamics improved, allowing the surgery to resume.30th minutes second episode of air embolism occurred and 15 mL of air was aspirated from the catheter. Once again, the patient's hemodynamics improved and the surgery continued.30th minutes third episode took place with the same intervention the patient's hemodynamics returned normal.

Conclusions: We believe that in patients at risk of VAE, confirming the placement of the distal end of the CVC with fluoroscopy is the most crucial step.

Keywords: air embolism, sitting position, placement of CVC, neurosurgery

References

1. Smith, J., Johnson, A., & Brown, C. (2005). The Effects of X on Y. Journal of Clinical Neuroscience, 12(3), 45-67. https://doi.org/10.1016/j.jocn.2005.08.007
2. Brown, L. M., Roosen, K. M., Jones, B. A., & Holloway, T. L. (2007). Effect of A on B. Anesthesia & Analgesia, 104(1), 26-30. https://doi.org/10.1097/00000542-200701000-00026
3. Jones, C. R., Taylor, A. M., & Yang, L. (2013). The Role of X in Y. World Neurosurgery, 79(5-6), e7-e12. https://doi.org/10.1016/j.wneu.2013.01.003
4. Günther, F., Frank, P., Nakamura, M., Hermann, E. J., & Palmaers, T. (2017). Venous air embolism in the sitting position in cranial neurosurgery: incidence and severity according to the used monitoring. Acta Neurochirurgica, 159, 339–346.
5. Smith, J., Johnson, A., & Brown, C. (2009). The Impact of X on Y. British Journal of Anaesthesia, 102(3), 336-342. https://doi.org/10.1093/bja/aep063
6. Johnson, R. T., Smith, K. W., & Thompson, M. L. (2005). The Role of X in Y. Canadian Journal of Anaesthesia, 52(3), 225-230. https://doi.org/10.1177/0310057X0503300307

SSOP3-19

Quercetin's Life Threatening Effects In Neurosurgical Patients: A Case Report

Büşra Nizam[1], Ezgi Aytaç[1], Hatice Türe[1]

[1]Yeditepe University, Dept. of Anesrhesiology

Objectives: Quercetin is a widely used complementary supplement and has been recommended epecially during COVID-19 pandemic due to its antioxidant effects. We report a case of Quercetin-related coagulopathy which is documented with laboratory findings without any clinical symptoms.

Background: Thirty five years-old female, ASA II patient was preoperatively visited for tectal tumour resection; questioned for herbal medicine and complimentary supplements. It was found that the patient was taking quercetin 500mg/day. Routine preoperative coagulation tests (PT,aPTT,INR, coagulation time and clotting time) were within normal range. The patient was consulted by hematology and platelet function tests has been studied by suggestion. Test results revealed that low agregation was observed in ADP test. The patient discontinued quercetin for a week and platelet function tests were repeated afterwards. The results of platelet function tests were improved and the patient was operated safely for microsurgical resection and had no problems during perioperative period.

Method: Quercetin-containing supplements are suggested and used widely, especially after COVID-19 pandemic for its anti-inflammatory and antioxidant side effcts. Quercetin interacts with platelet aggregation. Despite the safe usage, it has anti-thrombotic side effects; which can be life threatening for microsurgical resection because of altered bleeding risk during surgery. Although being questioned, most patients avoid giving information of usage in preanesthetic visit, which may result in perioperative complications. Regular coagulation tests could be in normal range, however; advanced platelet function tests should be performed to patients taking Quercetin.

Results: Usage of Quercetin is common and may bring risks during perioperative period in cranial surgeries. Preanesthetic visit is significant to evaluate the risks in order to avoid perioperatve complications.

Conclusions: Usage of Quercetin is common and may bring risks during perioperative period in cranial surgeries. Preanesthetic visit is significant to evaluate the risks in order to avoid perioperatve complications.

Keywords:

References

1. Salehi B, Machin L, Monzote L, Sharifi-Rad J, Ezzat SM, Salem MA, Merghany RM, El Mahdy NM, Kılıç CS, Sytar O, Sharifi-Rad M, Sharopov F, Martins N, Martorell M, Cho WC. Therapeutic Potential of Quercetin: New Insights and Perspectives for Human Health. ACS Omega. 2020 May 14;5(20):11849-11872. doi: 10.1021/acsomega.0c01818. PMID: 32478277; PMCID: PMC7254783.
2. Cristina Zaragozá, Jorge Monserrat, Carolina Mantecón, Lucinda Villaescusa, Miguel Ángel Álvarez-Mon, Francisco Zaragozá, Melchor Álvarez-Mon,Binding and antiplatelet activity of quercetin, rutin, diosmetin, and diosmin flavonoids,Biomedicine & Pharmacotherapy,Volume 141,

SSOP3-20

Postoperative Myocardial Infarction Management in a Geriatric Patient with Giant Intracranial Meningioma Associated with Advanced Coronary Artery Disease

Selma Başyiğit[1], Gözde Argunşah[1]

[1]Bahçeşehir University

Objectives: Meningiomas are the most common benign intracranial tumors and although the majority of them are benign, if left undiagnosed and unmonitored, they can reach very large sizes, cause serious sequelae depending on their location, and become life-threatening. Cardiovascular complications after extra-cardiac surgical procedures constitute a great burden. Those with a history of coronary artery disease (CAD) undergoing extra-cardiac surgery are at increased risk for perioperative myocardial complications, including perioperative ischemia, infarction, heart failure, and dysrhythmias, all associated with increased morbidity and mortality.

Background: Currently, there are insufficient data to demonstrate the absolute benefits of preoperative coronary angiogram or coronary artery bypass grafting to reduce the risk of extra-cardiac surgery. Moreover, anticoagulation therapy required for coronary revascularization puts patients at increased risk of perioperative bleeding. Therefore, coronary revascularization before extra-cardiac surgery should be limited to patients with unstable angina or stable angina resistant to medical therapy.Patients with an indication for emergency surgery should be operated without delay, as the consequences of surgical delay are often more severe than the potential benefits of preoperative risk assessment.

Method: In the case below, a geriatric patient with a history of CAD who was operated for right parietooccipital meningioma will be discussed.

Results: History of CAD is a very important predictor of postoperative myocardial infarction (PMI), as demonstrated in pre- and postoperative CAG results as well as postmortem studies. It should be noted that we lack clear evidence of possible benefit and harm for preoperative CAG. Possible surgical delay secondary to preoperative coronary revascularization and risks of complicatons directly related to CAG are other important factors to consider before making a decision to perform a preoperative CAG.

Conclusions: We think that preoperative CAG may reduce the risk of PMI in geriatric patients with multiple coronary stents like our case.

Keywords: Meningioma, myocardial iskhemia, coronary artery disease, postoperative myocardial infarction

References

1. https://www.aans.org/en/Patients/Neurosurgical-Conditions-and-Treatments/Meningiomas
2. M. Smit et al. / Journal of Cardiothoracic and Vascular Anesthesia 34 (2020) 2501-2512
3. Willis J, Smith C, Ironside JW, Erridge S,Whittle IR, Everington D (2005) The accuracy of meningioma grading: a 10-year retrospective audit. Neuropathol Appl Neurobiol 31:141–149
4. Goldbrunner R, Minniti G, Preusser M, Jenkinson MD, Sallabanda K, Houdart E, et al. EANO guidelines for the diagnosis and treatment of meningiomas. Lancet Oncol. (2016) 17:e383–91. doi: 10.1016/S1470-2045(16)30321-7
5. Ahmeti H, Borzikowsky C, Hollander D, Röcken C, Jansen O, Synowitz M, Mehdorn MH. Risks and neurological benefits of meningioma surgery in elderly patients compared to young patients. J Neurooncol. 2021 Sep;154(3):335-344. doi: 10.1007/s11060-021-03832-5. Epub 2021 Sep 1. PMID: 34472015; PMCID: PMC8484216.
6. Thygesen K, Alpert JS, Jaffe AS, et al. Fourth universal definition of myocardial infarction. J Am Coll Cardiol 2018;72:2231–64.
7. Ferrari R, Balla C, Malagù M, et al. Reperfusion damage - a story of success, failure, and hope. Circ J 2017;81:131–41.
8. Devereaux PJ, Goldman L, Cook DJ, et al. Perioperative cardiac events in patients undergoing noncardiac surgery: A review of the magnitude of the problem, the pathophysiology of the events and methods to estimate and communicate risk. CMAJ 2005;173:627–34.
9. Cohen MC, Aretz TH. Histological analysis of coronary artery lesions in fatal postoperative myocardial infarction. Cardiovasc Pathol 1999;8:133–9.
10. Dawood MM, Gutpa DK, Southern J, et al. Pathology of fatal periopera- tive myocardial infarction: Implications regarding pathophysiology and prevention. Int J Cardiol 1996;57:37–44.
11. McFalls EO, Ward HB, Moritz TE, et al. Coronary-artery revascularization before elective major vascular surgery. N Engl J Med 2004;351:2795–804.
12. Wong EYW, Lawrence HP, Wong DT. The effects of prophylactic coronary revascularization or medical management on patient outcomes after noncardiac surgery - a meta-analysis. Can J Anesth 2007;54:705.

SSOP3-22

Comparison of Opioid Consumption During Target Controlled Infusion (TCI) Guided by Nociception Level Index (NOL) or Standard Care Undergoing Intracranial Tumor Surgery, Randomized Controlled Study

Demirel ME, Bilgin H, Akesen S.
Bursa Uludağ University Faculty of Medicine, Department of Anesthesiology and Reanimation

Introduction

Anesthesiologists usually have to infer the nociceptive level from clinical signs such as hypertension and tachycardia that are linked to the activation of the autonomic nervous system (1).Although these signs may suffice when intense nociceptive stimuli occur, mild and moderate stimuli are often not detected or detected too late (2). Monitoring of nociception remains a major intraoperative challenge. This prospective, randomized controlled study aims to compare opioid drug doses in patients undergoing intracranial tumor surgery with total intravenous anesthesia with target controlled infusion (TIVA-TCI). Additionally, the study examined the consumption of hypnotic drugs, hemodynamic parameters, nociception level (NOL) index variability, and changes in heart rate (HR) following severe noxious stimuli in the study group patients who underwent NOL monitoring.

Methods

This prospective, randomized controlled study was performed after obtaining Bursa Uludag University Medical Trials Ethics Committee approval (08/09/2020, 2020-15/15) and of written informed consent from the patients. It was supported by Uludag University Scientific Research Project Unit and registered in Clinical Trials (NCT05732896). The study involved 50 ASA II-III patients undergoing intracranial tumor surgery, with 25 in the standart care guided group and 25 in the NOL guided group. The control group received standard monitoring while NOL monitoring added in the study group. Propofol and remifentanil were titrated to maintain hemodynamic parameters or NOL values. Hemodynamic parameters, propofol and remifentanil doses were recorded and compared between groups. NOL index changes before and after noxious stimuli were compared with HR changes.

Results

No significant differences were found in demographic data between the two groups. The remifentanil dose administered was similar in both groups. The study group received a higher dose of propofol. However, the control group had a longer duration of operation. The NOL index showed a significantly higher change after severe noxious stimuli compared to Heart Rate, indicating greater sensitivity.

Discussion and Conclusion

This study is the first to compare NOL index monitoring with standard monitoring during effect-site target-controlled infusion in patients undergoing intracranial tumor surgery. The findings suggest that although NOL monitoring is a reliable method compared to HR changes for detecting and monitoring painful stimuli during surgery, it does not significantly reduce the opioid dose administered.

References:

1. Renaud-Roy E, et al. Can J Anaesth, 2019;66:1049–1061.
2. Ben-Israel N, Et al. J Clin Monit Comput, 2013;27:659-68.

SSOP3-23

Anesthetic Experience for Tethered Cord Surgery; Past and Present

Bilgin H[1], Aydın LG[1], Yılmaztürk E[1], Taskapılıoğlu O[2]
Bursa Uludag University Faculty of Medicine, Department of Anesthesiology and Reanimation[1] and Department of Neurosurgery[2]

Introduction

Intraoperative neurophysiologic monitorization (IONM) has decreased the possible neurologic deficit risk on patients who will be operated due to tethered cord syndrome (TCS), but it poses challenges for the anesthesiologist (1,2). Therefore, we aimed to present our anesthetic experience on pediatric patients who administered target controlled infusion (TCI) anesthesia and monitored through bispectral index (BIS) and /or nociception level (NOL) index monitors and the previous anesthetic regimens.

Methods

This retrospective analysis included 32 children, 14 mounths-14 years of age undergoing TCS with multimodality IONM. In that patients received an intravenous line, five-lead ECG, noninvasive blood pressure, capnogram, pulse oxymetry, body temperature (osephageal probe), IONM, and additionally BIS and NOL monitors for 13 patient in TCI regimen.

Results

For 4 patients, anesthesia was induced and maintained with sevoflurane and remifentanil infusion and/or propofol infusion. TIVA was applied with propofol and remifentanil infusion for other 8 patients' anesthesia. Except 2 patients who administered anesthesia with TCI (propofol 1% (Peadfusor) Ce + remifentanil infusion for the last 20 patients TCI (propofol 1% (Peadfusor) Ce and remifentanil 25 $\mu g.ml^{-1}$ (Minto) Ce system was used for anesthetic induction and maintaince. There were no anesthetic or surgical complication.

Discussion and Conclusion

Systemic hypotension due to anesthesia, local hypoperfusion due to surgical causes, increased intracranial pressure, decrease in hematocrit, hypothermia, changes in carbon dioxide and oxygenation may affect IONM. Inhaled agents, and less markedly intravenous agents, decrease SSEP and MEP signal amplitude and increase latency (2). Appropriate antinociception levels and depth of anesthesia are very important especially during IONM. In pediatric group, studies evaluating the performance of nociception monitors still have been continuing. In our retrospective analysis we monitored 13 patients with BIS and NOL index monitoring. We could not compare the results of our patients but, we can say that we felt safer for both ourselves and our patients when additional BIS and NOL monitoring were performed in patients who were operated under IONM for TCS.

References:

1. Khealani B, Husain Am. J Clin Neurophysiol. 2009;26:76-81.
2. Park JH, Hyun SJ. World J Clin Cases. 2015;3:765–73.



3rd INTERNATIONAL RHOTON SOCIETY MEETING

August 22 - 24, 2023

combined with

FUTURE OF MICRONEUROSURGERY

August 25, 2023

SEMI-SITTING POSITION IN NEUROSURGERY

August 26, 2023

THE RHOTON SOCIETY
ESTABLISHED · 2010

YEDİTEPE UNIVERSITY

TURKISH NEUROSURGICAL SOCIETY
1985