Check for updates

Microsurgery

WILEY

MICROSURGERY

CASE REPORT

Double-Paddle Use of the Superficial Circumflex Iliac Artery Perforator Flap for Fournier's Gangrene: A Case Report

Süleyman Çeçen | Menekşe Kastamoni Başkan | Selçuk Akin

Plastic Reconstructive and Aesthetic Surgery Department, Bursa Uludağ University Faculty of Medicine, Bursa, Turkey

Correspondence: Süleyman Çeçen (scecen@uludag.edu.tr)

Received: 22 May 2025 | **Revised:** 30 July 2025 | **Accepted:** 9 October 2025

Funding: The authors received no specific funding for this work.

ABSTRACT

Fournier's gangrene often leads to extensive perineogenital soft tissue loss, necessitating complex reconstruction. The superficial circumflex iliac artery perforator (SCIP) flap is known for its thin pliable skin and low donor site morbidity. We present a case of a 65-year-old male with Fournier's gangrene affecting both the mons pubis and scrotum. After multiple debridements, a double-paddle SCIP flap based solely on the superficial branch of the SCIA was designed with two independent skin paddles to reconstruct these adjacent but anatomically distinct areas. Preoperative CT angiography and intraoperative SPY imaging enabled flap design and ensured vascular reliability. A double-paddle SCIP flap was elevated with two skin paddles, each inset to separate regions. Through proximal-to-distal dissection, the superficial circumflex iliac artery and its superficial branch were identified and dissected. Upon confirming the origin of the arterial branching of the superficial branch, two flaps were designed—one superiorly and one inferiorly positioned—measuring 14 × 7 cm and 8 × 5 cm, respectively, with an approximate thickness of 10 mm and a pedicle length of 8 cm. The total operative time was approximately 55 min. Postoperative recovery was uneventful, with satisfactory healing and aesthetic outcome at 6 months. This case illustrates a novel use of a double-paddle SCIP flap based exclusively on the superficial branch of the SCIA to simultaneously reconstruct two separate anatomic regions affected by Fournier's gangrene. This approach provides a single-donor, dual-target solution that is both reliable and aesthetically favorable.

1 | Introduction

The advent and widespread use of perforator flaps have marked a significant advancement in reconstructive surgery, enabling refined approaches to complex tissue defects. By relying on perforators, these flaps offer substantial reductions in both donor and recipient site morbidity, while providing versatility and customizable solutions applicable across diverse clinical scenarios. Among these, the superficial circumflex iliac artery perforator (SCIP) flap has emerged as a particularly valuable donor site, owing to its reliable vascular anatomy and minimal donor site morbidity (Berner et al. 2020).

Advancements in imaging techniques and surgical methods have deepened the understanding of perforator vascular anatomy, paving the way for innovative applications such as chimeric designs. As anatomical studies have clarified the perforasome concept and preoperative imaging has improved, the ability to utilize SCIP flaps in chimeric configurations has become increasingly feasible and reliable (Yoshimatsu et al. 2019).

Fournier's gangrene is a form of necrotizing fasciitis affecting the perineal and genital regions. It is characteristically aggressive, often requiring multiple surgical debridements and resulting in large soft tissue defects due to polymicrobial infections. While

© 2025 Wiley Periodicals LLC.

skin grafts may serve as a straightforward reconstructive option, their utility is frequently limited by infection and extensive surface involvement. Optimal form and function restoration in such settings demand thoughtful surgical planning to minimize complications. Given its proximity, appropriate tissue thickness, and pedicled transfer capability, the SCIP flap presents a compelling option for reconstructing defects in the mons pubis, penis, and scrotum (Scaglioni, Meroni, and Fritsche 2022; Kim et al. 2023; Sisternas Hernández et al. 2024; Atik et al. 2006). However, in cases where multiple debridements have resulted in wide and multiregional defects, a combination of reconstruction techniques—including both flaps and grafts—may be required.

This case report presents the successful use of a double-paddle SCIP flap in reconstructing two adjacent yet distinct anatomical regions affected by Fournier's gangrene. The double-paddle flap, based solely on the superficial branch of the superficial circumflex iliac artery, was designed to address both mons pubis and scrotal defects using two separate skin paddles. Additionally, a literature review was conducted using the search terms (superficial circumflex iliac artery) AND (chimeric) and (superficial circumflex iliac artery) AND (paddle) on PUBMED. Following the screening of abstracts, a brief review was added.

2 | Case Report

A 65-year-old male presented to the emergency department with erythema and warmth in the scrotal and mons pubis regions. He was diagnosed with Fournier's gangrene and underwent emergency debridement by the general surgery team. The patient subsequently underwent 11 debridements before being referred for reconstruction once the wound beds became adequately granulated following surgical and medical management.

Preoperative CT angiography was performed to evaluate potential perforators around the defect. Imaging revealed that the left-sided superficial circumflex iliac artery system had been compromised due to previous surgical debridements. Therefore, a right-sided pedicled SCIP flap was planned.

As described by Yamamoto et al., an incision was made in the right groin to expose and dissect the flap pedicle from its origin (Yoshimatsu et al. 2016). Approximately 5 cm of the pedicle was isolated, including both its deep and superficial systems. The superficial branch was found to bifurcate at the level of the anterior superior iliac spine. Based on this anatomical finding, a flap was planned that utilized only the superficial system (Figure 1).

A double-paddle flap configuration was designed, comprising two skin paddles: one located above and the other below the inguinal crease. The superior skin paddle measured 14 × 7 cm and the inferior 8 × 5 cm, both including only the superficial fascia to preserve thinness. Both flaps had an approximate thickness of 10 mm and a pedicle length of 8 cm in total. The inferior paddle was planned for the mons pubis defect and the superior for the scrotal defect. Intraoperative perfusion of both skin paddles and the pedicle was confirmed using SPY fluorescence imaging prior to flap transfer (Figure 2).

Following sufficient pedicle dissection, the flaps were transferred to the defect sites without tension. Both donor sites were closed primarily. Capillary refill was adequate postinset, and SPY imaging confirmed satisfactory perfusion in both skin paddles and the

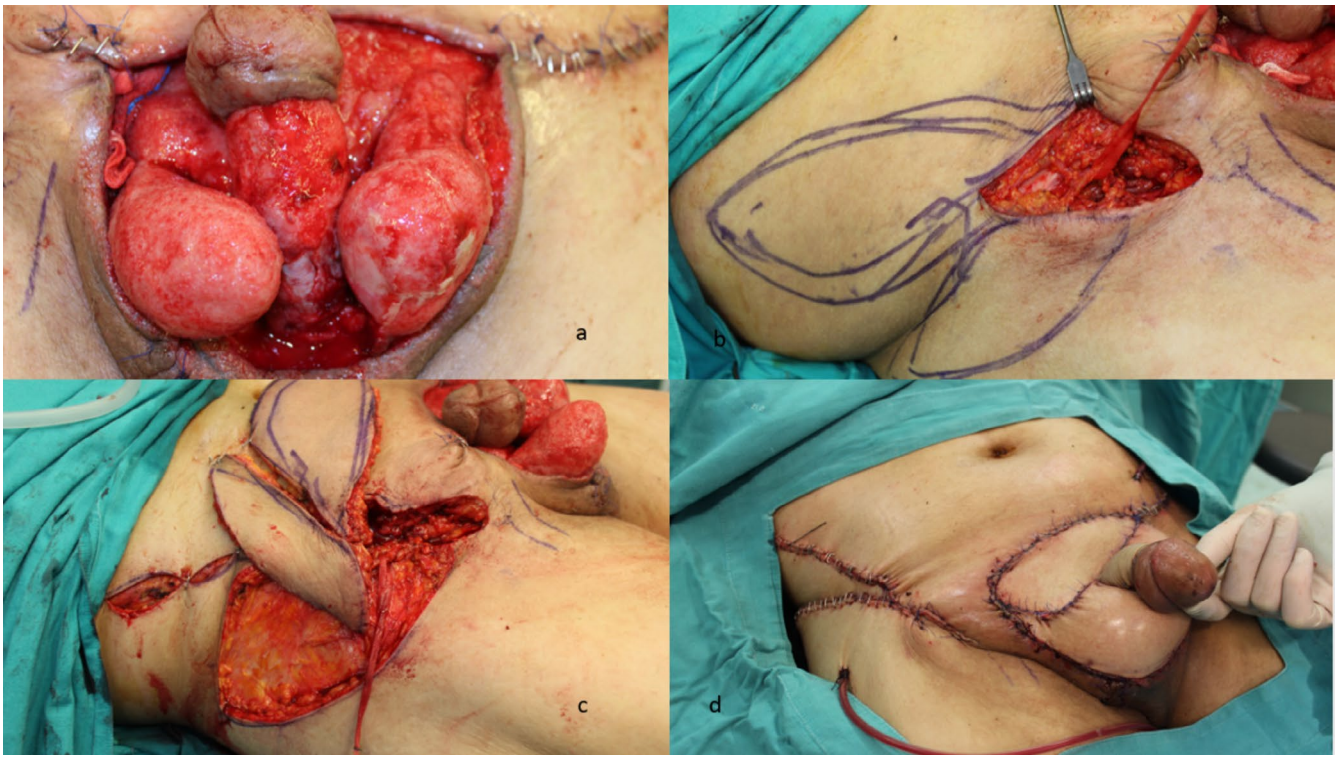

FIGURE 1 | (a) Perioperative view after debridement, (b) identification of pedicle and its branching pattern with exploratory incision, (c) flap after harvest, (d) perioperative view after inset.

10982752, 2025, 7, Downloaded from https://onlinelibrary.wiley.com/doi/10.1002/micr.70129 by Bursa Uludag University Kutuphane ve Dokumantasyon, Wiley Online Library on [19/10/2025]. See the Terms and Conditions (https://onlinelibrary.wiley.com/terms-and-conditions) on Wiley Online Library for rules of use; OA articles are governed by the applicable Creative Commons License

vascular pedicle. Following the inset of the flaps, the remaining exposed area on the penile shaft was grafted with a partial-thickness skin graft. The total operative time was approximately 55 min.

Postoperative recovery was uneventful with no complications at the recipient site. Minor marginal necrosis at the donor site was managed conservatively with dressings, requiring no additional surgical intervention. At the 6-month follow-up, both donor and recipient sites demonstrated excellent healing with aesthetically and functionally satisfactory outcomes (Figure 3).

3 | Discussion

Reconstruction following extensive debridement due to Fournier's gangrene or other causes affecting the pubic region remains a clinical challenge. Although skin grafts are often considered first-line due to ease of application, their reliability decreases in the presence of extensive infection, prior antibiotic use, and persistent positive cultures. Additionally, grafts are prone to contraction and late complications, particularly in mobile regions such as the perineum. As a result, local random-pattern or perforator-based flaps are generally preferred for more robust and durable coverage.

The introduction of perforator flaps has significantly expanded reconstructive options. Enhanced anatomical knowledge of perforator territories has improved flap harvest with minimal donor morbidity and increased flexibility in flap design. Moreover, detailed anatomical studies have enabled chimeric applications, wherein multiple tissue components based on a single vascular pedicle are used to reconstruct complex defects.

After branching from the femoral artery, the circumflex iliac artery divides into superficial and deep branches, supplying a wide array of anatomically diverse tissues, including the iliac crest, groin skin, sartorius muscle, lateral femoral cutaneous nerve, and abdominal wall fascia. Owing to this rich vascular anatomy, the SCIP flap based on this artery is highly amenable to chimeric design. Such chimeric configurations of the SCIP flap have been successfully employed both as regional and free flaps in the reconstruction of local and distant defects.

The SCIP flap, particularly in its perforator-based form described by Koshima et al. in 2004, has become increasingly popular due to its versatility and low donor-site morbidity (Koshima et al. 2004). However, the relatively short pedicle has been a limitation. Advances in anatomical understanding and surgical techniques have enabled longer pedicle dissection and more reliable inclusion of multiple tissue types into chimeric configurations. Yamamoto's technique, involving proximal-to-distal dissection, facilitates the identification of both superficial and deep branches of the pedicle, allowing for

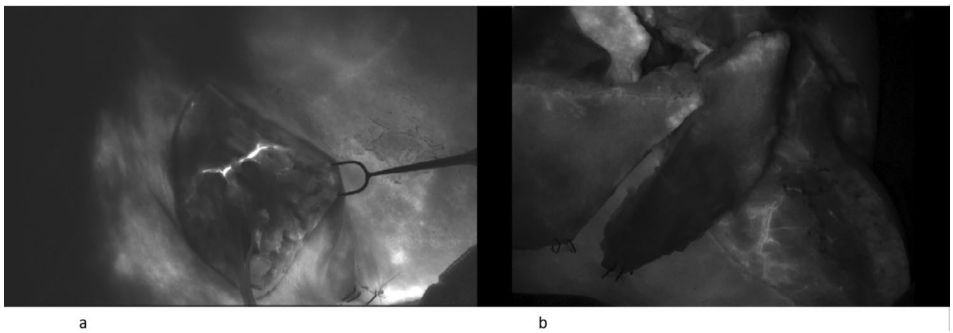

FIGURE 2 | (a) Intraoperative ICG imaging after identification of the pedicle and branching pattern. ICG, indocyanine green, (b) Intraoperative ICG imaging after flap harvest that shows both skin paddles.



FIGURE 3 | (a) Postoperative 6 months outcome of the recipient site, (b) postoperative 6 months outcome of the donor site, with minimal dehiscences that were managed conservatively.

10982752, 2025, 7, Downloaded from https://onlinelibrary.wiley.com/doi/10.1002/micr.70129 by Bursa Uludag University Kutuphane ve Dokumantasyon, Wiley Online Library on [19/10/2025]. See the Terms and Conditions (https://onlinelibrary.wiley.com/terms-and-conditions) on Wiley Online Library for rules of use; OA articles are governed by the applicable Creative Commons License

composite reconstruction using bone, muscle, skin, or nerve elements (Yoshimatsu et al. 2016).

Particularly in free flap applications for head and neck or extremity reconstruction (Werner et al. 2023; Scaglioni et al. 2024), various combinations of skin (Sidhoum et al. 2017), subcutaneous fat, bone (Iida et al. 2013; Torrano et al. 2023), fascia (Yamamoto et al. 2016; Chu et al. 2024), and nerve (Iida et al. 2012, 2014) components have been utilized, demonstrating the flap's adaptability to a wide range of defects. Furthermore, the use of a double paddle skin island based on the superficial branch for maxillary defect reconstruction has also been reported in a case presentation (Yamamoto, Yamamoto, and Ishiura 2022).

In addition to its use as a free flap, regional applications of the SCIP flap have been described for various indications, including defects of the genital region (Gentileschi et al. 2022), abdominal wall (Lichtenberg et al. 2024), and thigh (Scaglioni et al. 2023; Scaglioni, Meroni, Fritsche, and Fuchs 2022). Specifically, its use has been demonstrated in penoscrotal defects secondary to trauma (Sisternas Hernández et al. 2024), hidradenitis suppurativa (Sidhoum et al. 2017), and Fournier's gangrene (Han et al. 2016). In a series by Dong et al., involving 33 SCIP flaps in 24 patients, all flaps were based on the superficial branch, and bilateral SCIP flaps were employed in nine patients with extensive defects (Dong et al. 2025). Boissière et al. in their 2019 study, reported on 72 SCIP flaps used for regional reconstruction, including one case where bilateral SCIP flaps were utilized for scrotal reconstruction (Boissière et al. 2019). In addition to various case reports, the role of the SCIP flap in lymphatic reconstruction has also been explored. Ciudad et al. in their 2025 series of eight cases, used pedicled SCIP flaps for the treatment of genital lymphedema (Ciudad et al. 2025). Similarly, Yamamoto et al. in 2022, described the use of pedicled SCIP flaps incorporating both the superficial and deep branches to reconstruct the scrotal region following radical reduction surgery for scrotal elephantiasis in seven patients (Yamamoto, Daniel, et al. 2022). In 2023, Abdelfattah et al. utilized the SCIP flap for the treatment of genital lymphedema in 26 male patients. Scrotal involvement was reported in 15 cases, while penoscrotal structures were affected in 11 cases. Reconstruction was achieved using a pedicled SCIP flap (Abdelfattah et al. 2023).

The initial plan for the reconstruction of the mons pubis, scrotum and penile shaft involved bilateral SCIP flaps with skin grafting of the penile shaft. However, preoperative CT angiography revealed the absence of a suitable perforator in the left inguinal region, necessitating a revised approach utilizing a unilateral flap and grafts. Intraoperatively, the bifurcation of the superficial branch of the SCIA was identified, enabling the design of two independent skin paddles and permitting comprehensive reconstruction with grafting limited to the penile shaft. Proximal-to-distal dissection of the vascular pedicle facilitated flap preparation, while SPY imaging confirmed adequate perfusion both before and after inset.

Relying solely on the superficial branch of the SCIA offers several advantages, including simplified dissection, reduced donor site morbidity, and the ability to design multiple skin paddles from a single pedicle. However, this approach may be limited by a shorter pedicle length and reduced arc of rotation, potentially increasing the risk of tension or perfusion compromise in larger reconstructions. Careful preoperative imaging and intraoperative assessment are essential to ensure flap reliability and minimize these risks.

While the literature describes various configurations and combinations of SCIP flap applications, to our knowledge, there are no reports detailing a double paddle design based solely on the superficial branch, the deep branch, or a combination of both in the context of regional reconstruction. In conclusion, the principal novelty of this case lies in the utilization of the superficial branch of the SCIP flap for a multipaddle design, allowing simultaneous reconstruction of anatomically distinct subunits of the pubic region with minimal donor site morbidity and favorable postoperative outcomes. Despite the single-case nature of our experience and the absence of statistical validation, we suggest that this technique merits consideration, particularly for the simultaneous reconstruction of multiple adjacent regional defects, offering a versatile and efficient solution in appropriate clinical scenarios. Future series are needed to evaluate its broader application and long-term outcomes.

Acknowledgments

The authors have nothing to report.

Ethics Statement

The authors have nothing to report.

Conflicts of Interest

The authors declare no conflicts of interest.

Data Availability Statement

The data that support the findings of this study are available on request from the corresponding author. The data are not publicly available due to privacy or ethical restrictions.

References

Abdelfattah, U., T. Elbanoby, F. Hamza, et al. 2023. "Treatment of Advanced Male Genital Lymphedema With a Complete Functional Lymphatic System Pedicled Transfer." *Urology* 175: 190–195. https://doi.org/10.1016/j.urology.2023.02.006.

Atik, B., O. Tan, K. Ceylan, O. Etlik, and C. Demir. 2006. "Reconstruction of Wide Scrotal Defect Using Superthin Groin Flap." *Urology* 68, no. 2: 419–422. https://doi.org/10.1016/j.urology.2006.04.003.

Berner, J. E., D. Nikkhah, J. Zhao, E. Prousskaia, and T. C. Teo. 2020. "The Versatility of the Superficial Circumflex Iliac Artery Perforator Flap: A Single Surgeon's 16-Year Experience for Limb Reconstruction and a Systematic Review." *Journal of Reconstructive Microsurgery* 36, no. 2: 93–103. https://doi.org/10.1055/s-0039-1695051.

Boissière, F., V. Luca-Pozner, C. Vaysse, N. Kerfant, C. Herlin, and B. Chaput. 2019. "The SCIP Propeller Flap: Versatility for Reconstruction of Locoregional Defect☆." *Journal of Plastic, Reconstructive & Aesthetic Surgery* 72, no. 7: 1121–1128. https://doi.org/10.1016/j.bjps.2019.03.016.

Chu, T., J. Xiao, X. Zhou, K. Lin, and Z. Tao. 2024. "Free Chimeric Superficial Circumflex Iliac Artery Perforator Flap in Reconstructing the Distal Complex Extensor Tendon Injury." *Plastic and Reconstructive Surgery* 153, no. 2: 442e–447e. https://doi.org/10.1097/PRS.0000000000010599.

10982752, 2025, 7, Downloaded from https://onlinelibrary.wiley.com/doi/10.1002/micr.70129 by Bursa Uludag University Kutuphane ve Dokumantasyon, Wiley Online Library on [19/10/2025]. See the Terms and Conditions (https://onlinelibrary.wiley.com/terms-and-conditions) on Wiley Online Library for rules of use; OA articles are governed by the applicable Creative Commons License

Ciudad, P., J. M. Escandón, L. Escandón, H. F. Mayer, and O. J. Manrique. 2025. "Surgical Management of Genital Lymphedema Using the Combined Charles' Procedure and Lymphatic Superficial Circumflex Iliac Artery Perforator Flap Transfer (CHASCIP)." *Microsurgery* 45, no. 5: e70075. https://doi.org/10.1002/micr.70075.

Dong, W., X. Xiao, Z. Wang, X. Yang, and H. Bi. 2025. "Superficial Circumflex Iliac Artery Perforator Propeller Flap for Penoscrotal Extramammary Paget's Disease." *International Journal of Dermatology* 64, no. 1: 142–148. https://doi.org/10.1111/ijd.17325.

Gentileschi, S., A. A. Caretto, M. Servillo, et al. 2022. "Feasibility, Indications and Complications of SCIP Flap for Reconstruction After Extirpative Surgery for Vulvar Cancer." *Journal of Plastic, Reconstructive & Aesthetic Surgery* 75, no. 3: 1150–1157. https://doi.org/10.1016/j.bjps.2021.11.005.

Han, H. H., J. H. Lee, S. M. Kim, Y. J. Jun, and Y. J. Kim. 2016. "Scrotal Reconstruction Using a Superficial Circumflex Iliac Artery Perforator Flap Following Fournier's Gangrene." *International Wound Journal* 13, no. 5: 996–999. https://doi.org/10.1111/iwj.12353.

Iida, T., M. Mihara, M. Narushima, and I. Koshima. 2012. "A Sensate Superficial Circumflex Iliac Perforator Flap Based on Lateral Cutaneous Branches of the Intercostal Nerves." *Journal of Plastic, Reconstructive & Aesthetic Surgery* 65, no. 4: 538–540. https://doi.org/10.1016/j.bjps.2011.09.002.

Iida, T., M. Narushima, H. Yoshimatsu, T. Yamamoto, J. Araki, and I. Koshima. 2013. "A Free Vascularised Iliac Bone Flap Based on Superficial Circumflex Iliac Perforators for Head and Neck Reconstruction." *Journal of Plastic, Reconstructive & Aesthetic Surgery* 66, no. 11: 1596–1599. https://doi.org/10.1016/j.bjps.2013.03.031.

Iida, T., H. Yoshimatsu, H. Hara, M. Mihara, and I. Koshima. 2014. "Reconstruction of Large Facial Defects Using a Sensate Superficial Circumflex Iliac Perforator Flap Based on the Lateral Cutaneous Branches of the Intercostal Nerves." *Annals of Plastic Surgery* 72, no. 3: 328–331. https://doi.org/10.1097/SAP.0b013e318264fc7d.

Kim, W., S. Kim, H. Sung, K. Lee, and J. Pyon. 2023. "Penoscrotal Defect Reconstruction Using Loco-Regional Flaps in Treatment of Extramammary Paget's Disease: Experience and Suggestion of a Simplified Algorithm." *Microsurgery* 43, no. 4: 316–324. https://doi.org/10.1002/micr.30988.

Koshima, I., Y. Nanba, T. Tsutsui, et al. 2004. "Superficial Circumflex Iliac Artery Perforator Flap for Reconstruction of Limb Defects." *Plastic and Reconstructive Surgery* 113, no. 1: 233–240. https://doi.org/10.1097/01.PRS.0000095948.03605.20.

Lichtenberg, N. J., B. Sandeep, and D. M. Taylor. 2024. "Pedicled Chimeric Superficial Circumflex Iliac Artery Perforator (SCIP) Flap With External Oblique Fascia for Vesicocutaneous Bladder Fistula Repair: A Case Report and Literature Review on the Utility of Pedicled Chimeric SCIP." *Microsurgery* 44, no. 2: e31138. https://doi.org/10.1002/micr.31138.

Scaglioni, M. F., M. Meroni, and E. Fritsche. 2022. "Pedicled Superficial Circumflex Iliac Artery Perforator Flap for Male Genital Reconstruction: A Case Series." *Microsurgery* 42, no. 8: 775–782. https://doi.org/10.1002/micr.30933.

Scaglioni, M. F., M. Meroni, and E. Fritsche. 2023. "Pedicled Superficial Circumflex Iliac Artery Perforator Flap Combined With Lymphovenous Anastomosis Between the Recipient Site Lymphatic Vessels and Flap Superficial Veins for Reconstruction of Groin/Thigh Tissue Defect and Creation of Lymph Flow-Through to Reduce Lymphatic Complications: A Report of Preliminary Results." *Microsurgery* 43, no. 1: 44–50. https://doi.org/10.1002/micr.30840.

Scaglioni, M. F., M. Meroni, E. Fritsche, and B. Fuchs. 2022. "The Use of Pedicled Chimeric Superficial Circumflex Iliac Artery Perforator (SCIP) Flap as Lymphatic Interpositional Flap for Deep Thigh Defect Reconstruction: A Case Report." *Microsurgery* 42, no. 4: 360–365. https://doi.org/10.1002/micr.30823.

Scaglioni, M. F., M. Meroni, P. E. Tomasetti, and G. P. Rajan. 2024. "Head and Neck Reconstruction With the Superficial Circumflex Iliac Artery Perforator (SCIP) Free Flap: Lessons Learned After 73 Cases." *Head and Neck* 46, no. 6: 1428–1438. https://doi.org/10.1002/hed.27760.

Sidhoum, N., S. Dast, S. Perez, N. Assaf, C. Herlin, and R. Sinna. 2017. "Superficial Circumflex Iliac Artery Perforator Flap (SCIP Flap): Revival of the Inguinal Donor Site?" *Annales De Chirurgie Plastique et Esthetique* 62, no. 6: 646–651. https://doi.org/10.1016/j.anplas.2017.03.006.

Sisternas Hernández, L., S. López Fernández, P. D. Zamora Alarcón, C. Vega García, L. Torrano Romero, and M. Fernández Garrido. 2024. "Posttraumatic Scrotal Reconstruction With a Pedicled 'Extended' Superficial Circumflex Iliac Artery Perforator Flap: A Case Report." *Archives of Plastic Surgery* 51: 327–331. https://doi.org/10.1055/a-2166-8783.

Torrano, L., P. Zamora Alarcón, A. Ibarra, J. Masiá, L. Sisternas Hernández, and M. Fernández-Garrido. 2023. "Chimeric SCIP Flap With Iliac Bone for Reconstruction of Foot First Ray in a Radiated Surgical Bed: A Case Report." *Microsurgery* 43, no. 4: 403–407. https://doi.org/10.1002/micr.31019.

Werner, J., G. P. Rajan, and M. F. Scaglioni. 2023. "Functional Reconstruction of the Unilateral Supraglottis and Piriform Sinus With a Triple Chimeric Superficial Circumflex Iliac Artery Perforator Flap After Supraglottic Laryngectomy: A Case Report." *Microsurgery* 43, no. 3: 266–272. https://doi.org/10.1002/micr.30951.

Yamamoto, T., B. W. Daniel, J. R. Rodriguez, et al. 2022. "Radical Reduction and Reconstruction for Male Genital Elephantiasis: Superficial Circumflex Iliac Artery Perforator (SCIP) Lymphatic Flap Transfer After Elephantiasis Tissue Resection." *Journal of Plastic, Reconstructive & Aesthetic Surgery* 75, no. 2: 870–880. https://doi.org/10.1016/j.bjps.2021.08.011.

Yamamoto, T., T. Saito, R. Ishiura, and T. Iida. 2016. "Quadruple-Component Superficial Circumflex Iliac Artery Perforator (SCIP) Flap: A Chimeric SCIP Flap for Complex Ankle Reconstruction of an Exposed Artificial Joint After Total Ankle Arthroplasty." *Journal of Plastic, Reconstructive & Aesthetic Surgery* 69, no. 9: 1260–1265. https://doi.org/10.1016/j.bjps.2016.06.010.

Yamamoto, T., N. Yamamoto, and R. Ishiura. 2022. "Free Double-Paddle Superficial Circumflex Iliac Perforator Flap Transfer for Partial Maxillectomy Reconstruction: A Case Report." *Microsurgery* 42, no. 1: 84–88. https://doi.org/10.1002/micr.30824.

Yoshimatsu, H., J. Steinbacher, S. Meng, et al. 2019. "Superficial Circumflex Iliac Artery Perforator Flap: An Anatomical Study of the Correlation of the Superficial and the Deep Branches of the Artery and Evaluation of Perfusion From the Deep Branch to the Sartorius Muscle and the Iliac Bone." *Plastic and Reconstructive Surgery* 143, no. 2: 589–602. https://doi.org/10.1097/PRS.0000000000005282.

Yoshimatsu, H., T. Yamamoto, A. Hayashi, and T. Iida. 2016. "Proximal-To-Distally Elevated Superficial Circumflex Iliac Artery Perforator Flap Enabling Hybrid Reconstruction." *Plastic and Reconstructive Surgery* 138, no. 4: 910–922. https://doi.org/10.1097/PRS.0000000000002607.

10982752, 2025, 7, Downloaded from https://onlinelibrary.wiley.com/doi/10.1002/micr.70129 by Bursa Uludag University Kutuphane ve Dokumantasyon, Wiley Online Library on [19/10/2025]. See the Terms and Conditions (https://onlinelibrary.wiley.com/terms-and-conditions) on Wiley Online Library for rules of use; OA articles are governed by the applicable Creative Commons License