Received: 30 March 2025 | Revised: 28 August 2025 | Accepted: 12 January 2026

DOI: 10.1002/vrc2.70359

Vet Record CaseReports

CASE REPORT

Zoo animals

Pleomorphic oral squamous cell carcinoma in a captive Dumeril's ground boa (*Acrantophis dumerili*) with immunohistochemical analysis

Mehmet Emre Topcu | **Ozkan Yavas** | **Musa Ozgur Ozyigit**

Department of Pathology, Bursa Uludag University Faculty of Veterinary Medicine, Bursa, Turkey

Correspondence
Ozkan Yavas, Department of Pathology, Bursa Uludag University Faculty of Veterinary Medicine, Bursa, Turkey.
Email: oyavas@uludag.edu.tr

Abstract

Oral squamous cell carcinoma (oSCC) is an invasive tumour reported in humans and domestic animals, and poorly differentiated forms are rarely reported in snakes. We describe a case of pleomorphic oSCC in a 12-year-old female Dumeril's boa (*Acrantophis dumerili*) kept in the terrarium of a zoo. Histopathological examination revealed polygonal neoplastic cells with marked atypia, high mitotic activity, multinucleated cells and invasive growth in the bone tissue. Immunohistochemical analysis displayed cytokeratin-5 and p63 positivity, while markers for vimentin, Melan-A, MAC387, CD1a and p16 were negative. Approximately 75% of tumour cells expressed proliferating cell nuclear antigen, which indicates significant proliferative activity. This case highlights the important role of immunohistochemistry in the diagnosis of poorly differentiated types of tumours in a Dumeril's boa snake. Our observations aim to contribute to the limited literature on reptilian SCC and underline the need for continued research on tumour aetiology and diagnostic strategies in exotic species.

BACKGROUND

Squamous cell carcinoma (SCC) is one of the most common neoplasms observed in the oral cavity of humans and cats. It displays aggressive behaviour and is invasive to the adjacent tissues.[1,2] In humans, it has been extensively studied with well-known risk factors such as ultraviolet radiation and human papillomavirus (HPV) infections.[3] It has also been documented frequently in reptiles, most often affecting the oral cavity, head and mucocutaneous junctions.[4] Well-differentiated oral SCC (oSCC) invading surrounding tissues has been reported in various snake species; however, poorly differentiated oSCC has rarely been reported. A prolonged lifespan and chronic oral mucosal inflammation may be predisposing factors for oSCC in snakes.[4] Certain tumours can be challenging to diagnose because they are poorly differentiated.[5] In such cases, immunohistochemistry (IHC) is essential for diagnosing malignant tumours, such as poorly differentiated SCC.[6,7] In this case report, we present to diagnose pleomorphic oSCC in a Dumeril's ground boa (*Acrantophis dumerili*) using immunohistochemical methods.

CASE PRESENTATION

A 12-year-old female *A. dumerili*, weighing 4.2 kg and measuring 1.95 m in length, was brought from the Bursa Zoo to the Bursa Uludag University, Department of Veterinary Pathology, for necropsy. In the anamnesis, it was stated that the animal was kept in a closed environment with other snakes. In the snake's terrarium, a UVB lamp was placed approximately 50 cm above the ground, with a 100–125 W capacity. The zoo veterinarian stated that due to the tumour in the snake's oral mucosa, the animal had been unable to eat independently for the last few weeks and had been fed via an orogastric tube. Because of the poor prognosis and progressive debilitation, the snake was euthanased at the zoo.

On gross examination, a mass was observed in the right craniolateral maxillary mucosa in the oral cavity. The tumour measured approximately 3.5 × 3 × 3 cm, had a haemorrhagic appearance and was soft and friable (Figure 1a). Notably, the mass protruded through the dorsal skin of the maxilla (Figure 1b). No gross metastases were observed in other organs or tissues. During the necropsy, after the tumour was removed, the head, tumour and major organs were excised, fixed in a 10% neutral-buffered formalin solution, and the skull was decalcified. The tissues were then processed for histopathological examination following standard protocols and sectioned at 4-μm thickness and were stained with haematoxylin and eosin and immunohistochemically stained with vimentin, cytokeratin-5, Melan-A, MAC387, CD1a, p63, p16 and proliferating cell nuclear antigen (PCNA) antibodies.

Histopathological examination revealed that the mass extended from the surface epithelium to the maxillary bone tissue. The tumour comprised of polygonal cells with eosinophilic cytoplasm and oval vesicular nuclei containing prominent nucleoli. Marked anisocytosis and anisokaryosis were noticed. The presence of notable mitotic figures (defined

© 2026 British Veterinary Association.

LEARNING POINTS/TAKE HOME MESSAGES

- Oral squamous cell carcinoma (oSCC) should be considered in reptiles with oral masses, especially in ageing individuals.
- Poorly differentiated forms of oSCC may present diagnostic challenges and require immunohistochemical confirmation.
- Environmental factors such as artificial UV exposure may play a role in the tumourigenesis of exotic reptiles, warranting further investigation.

as 62 mitotic figures per 2.37 mm^2) and multinucleated neoplastic cells were observed (Figure 2a,b). These cells invaded the maxilla and caused osteolysis, proliferating in clusters within a thin fibrovascular stroma containing numerous heterophil leukocytes and haemorrhage. Examination of the liver demonstrated diffuse, moderately severe vacuolar degeneration, predominantly in the centrilobular regions. No pathological changes or tumour metastases were noted in other organs.

Immunohistochemical analysis showed that the tumour cells exhibited diffuse cytoplasmic immunoreactivity for cytokeratin-5 (Figure 2c,d) and nuclear immunoreactivity for p63 antigen (Figure 3a,b), whereas no expression was detected for vimentin, Melan-A, MAC387, CD1a and p16 antigens in the neoplastic cells. Approximately 75% of the tumour cells showed nuclear positivity for the proliferation marker PCNA (Figure 3c,d). Diffuse cytoplasmic positivity for vimentin was observed in the connective tissue cells within and surrounding the tumour (Figure 4). Negative controls were performed on all tumour sections, and no staining was observed. Details regarding the IHC antibodies and procedures are described in Table 1. Based on the histopathological features and immunohistochemical findings, the tumour was diagnosed as pleomorphic (grade 4) oSCC according to Anneroth's multi-factor grading system.[8]

INVESTIGATIONS

The diagnosis was established based on gross findings, histopathological evaluation, and immunohistochemical analysis of the necropsy material.

DIFFERENTIAL DIAGNOSIS

The differential diagnoses for an oral mass in a snake include:

- Melanoma: typically contains melanin pigment and may express Melan-A.
- Fibrosarcoma: composed of spindle-shaped cells, positive for vimentin and negative for cytokeratins.
- Histiocytic sarcoma: may show MAC387 or CD1a positivity.
- Ameloblastoma or odontogenic tumours: characterised by dental epithelium origin; less atypia.
- Papilloma: benign and usually associated with papillomavirus infection, typically lacks bone invasion and has p16 positivity if viral.

In this case, immunonegativity for vimentin, Melan-A, MAC387, CD1a and p16, combined with cytokeratin-5 and p63 positivity, confirmed the diagnosis of pleomorphic oSCC.

TREATMENT

No treatment was administered, as the case was evaluated post-mortem.

OUTCOME AND FOLLOW-UP

The animal was euthanased due to progressive deterioration and inability to feed. Postmortem histopathological and immunohistochemical evaluations confirmed the diagnosis. No metastases were detected. Since this case represents an end-stage presentation, no follow-up treatment or monitoring was possible. However, the findings may guide future



FIGURE 1 Pleomorphic oral squamous cell carcinoma, oral cavity, Dumeril's ground boa snake. (a) The appearance of the tumour from outside the oral cavity is remarkable for the proliferative lesions seen when the mouth is closed. (b) An ulcerated and proliferative neoplastic mass located in the upper palate of the oral cavity was closely examined, and the lysis of the cartilage and invasion of the lower layers were observed.

20526121, 2026, 1, Downloaded from https://bvajournals.onlinelibrary.wiley.com/doi/10.1002/vrc2.70359 by Bursa Uludag University Kutuphane ve Dokumantasyon, Wiley Online Library on [01/02/2026]. See the Terms and Conditions (https://onlinelibrary.wiley.com/terms-and-conditions) on Wiley Online Library for rules of use; OA articles are governed by the applicable Creative Commons License

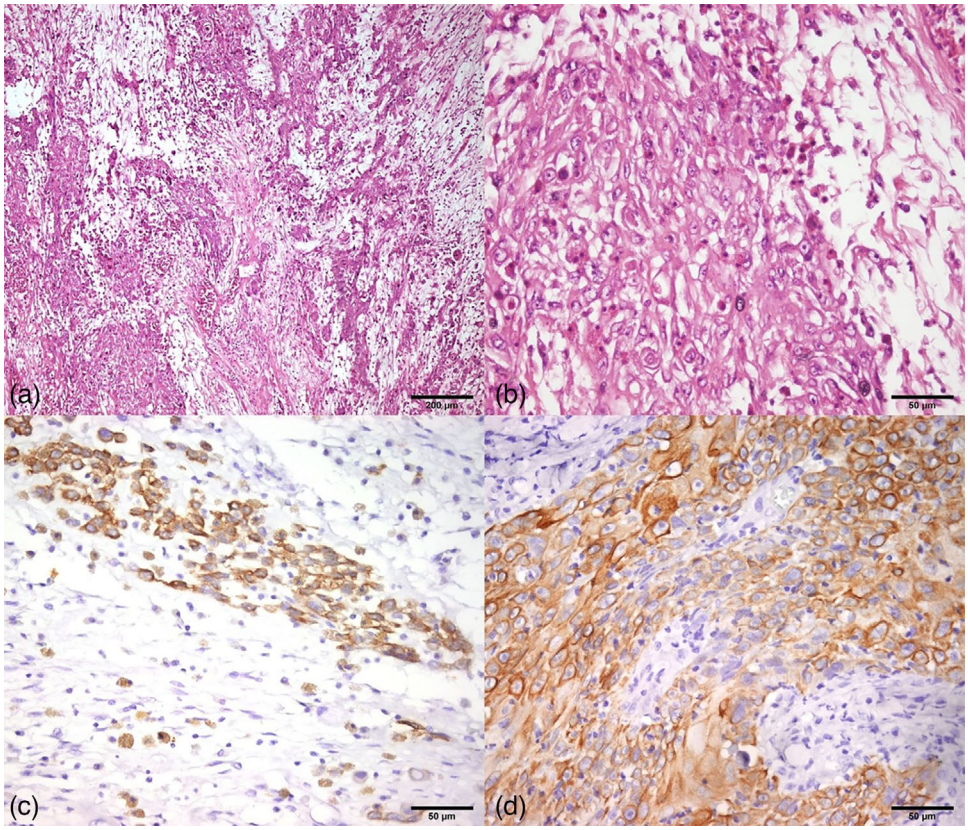

FIGURE 2 Pleomorphic oral squamous cell carcinoma, oral cavity, Dumeril's ground boa snake. (a) Round-oval-shaped neoplastic cells invaded between muscle tissue and connective tissue; cytoplasm and nucleus sizes of the cells are different (anisocytosis, anisokaryosis). Haematoxylin and eosin (HE). (b) Close appearance of the neoplastic cells. Cells with a vesicular nucleus and prominent nucleolus are visible. Multiple nucleolus are observed in some neoplastic cell nuclei. (c) Cytoplasmic cytokeratin-5 expression observed in neoplastic cells invading between stromal tissue, streptavidin peroxidase and (3,3'-diaminobenzidine (DAB). (d) Cytokeratin-5 expression was observed in neoplastic epithelial cell clusters, streptavidin peroxidase and DAB.

diagnostic and management approaches in similar reptile cases.

DISCUSSION

SCC, a common neoplasm in reptiles, particularly snakes, frequently affects various gastrointestinal tract regions, including the oral cavity.[9] Reports of oSCC cases in snakes have generally been limited to well-differentiated forms, while identifying the poorly differentiated variant presents diagnostic challenges, given the tumour's aggressive biological behaviour and invasive nature.[4] In this context, the marked atypia, high mitotic activity, osteolysis and invasive growth pattern observed in tumour cells reveal the malignant character of this tumour.[10] There are no previous specific literature studies on the expression of p63, p16, MAC387, CD1a and PCNA antigens in IHC analysis of snake tissues. This case report contains a detailed immunohistochemical demonstration of these antigens, and these data contributed to the diagnostic process.

Cytokeratins are intracellular filament proteins that provide structural integrity to epithelial cells and are expressed in distinct combinations depending on the epithelial subtype.[11] Cytokeratin-5 is a member of the cytokeratin family and is specifically expressed in the basal layer of stratified squamous epithelium. It is highly expressed in head and neck SCC, mesothelioma, lung SCC and various odontogenic tumours.[12–15] In the present case, the pleomorphic histopathological appearance of the tumour did not initially suggest an epithelial origin. For this reason, immunohistochemical staining with an antibody against cytokeratin-5 was performed. The strong cytokeratin-5 expression observed in tumour cells confirmed the epithelial nature of lesion. In differential diagnosis, odontogenic ameloblastoma was also considered, as this tumour may exhibit cytokeratin-5 positivity. However, this diagnosis was excluded on the basis of the relatively benign histomorphological features that characterise ameoblastomas.

The p63 gene is a member of the p53/p63/p73 family of transcription factors and plays an essential role in squamous epithelial development and homeostasis.[16] In human patients, p63 overexpression is observed in SCC originating from the oral cavity.[17] Due to its high prevalence in SCCs, p63 IHC helps identify these cancers.[18] The expression of cytokeratin-5 and p63 is critical in confirming squamous differentiation.[7,19] Although cytokeratin-5 expression in reptilian epithelial tissues has been previously described, there are no published data addressing p63 expression in snake epithelium or snake-derived tumours. Consequently, our interpretation was informed by available evidence from human studies. In the present case, the demonstration of strong p63 immunoreactivity in tumour cells further corroborated the epithelial nature of the neoplasm and supported the diagnosis of SCC. These findings suggest that, similar to observations in humans, p63 may serve as a valuable adjunct biomarker in reptilian epithelial tumours, particularly when histopathological features alone are insufficient to confirm squamous differentiation. Future studies with larger case series would be

20526121, 2026, 1, Downloaded from https://bvajournals.onlinelibrary.wiley.com/doi/10.1002/vrc2.70359 by Bursa Uludag University Kutuphane ve Dokumantasyon, Wiley Online Library on [01/02/2026]. See the Terms and Conditions (https://onlinelibrary.wiley.com/terms-and-conditions) on Wiley Online Library for rules of use; OA articles are governed by the applicable Creative Commons License

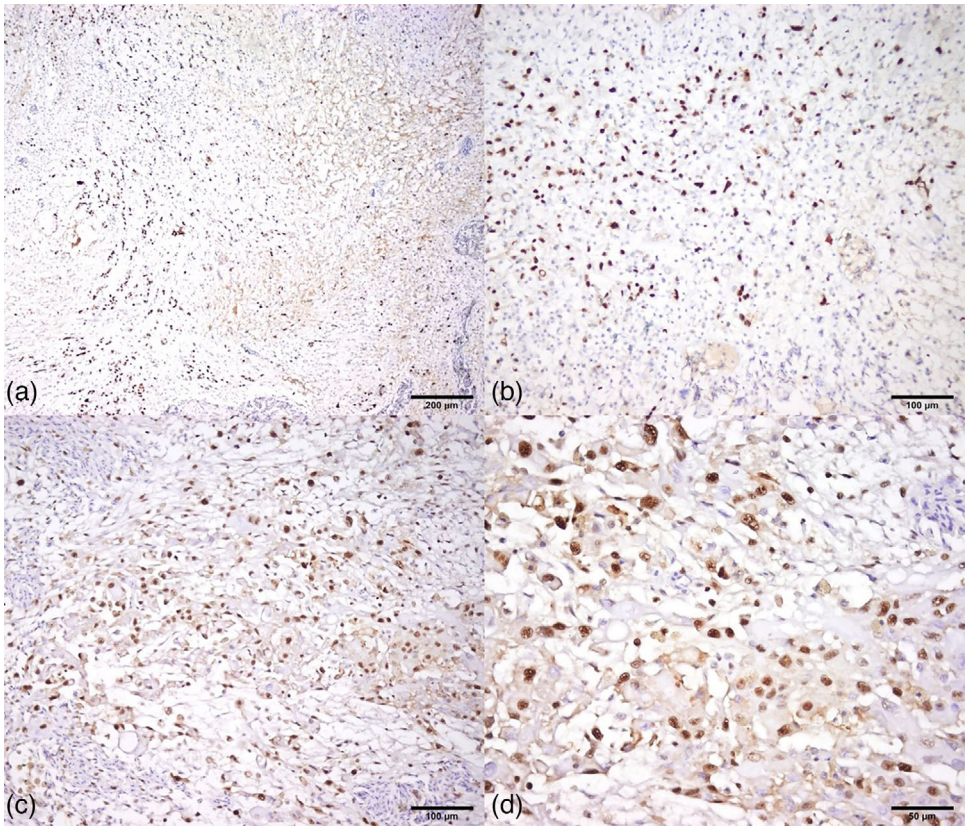

FIGURE 3 Pleomorphic oral squamous cell carcinoma, oral cavity, Dumeril's ground boa snake, streptavidin peroxidase and DAB. (a) Demonstration of p63 antibody nuclear staining in neoplastic squamous epithelial cells. (b) Demonstration of p63 immunopositivity at nuclear location in neoplastic squamous epithelial cells. (c) Immunopositivity of proliferating cell nuclear antigen (PCNA) with nuclear staining in neoplastic squamous epithelial cell clusters. (d) Close-up appearance of PCNA immunopositivity showing nuclear staining in neoplastic squamous epithelial cell clusters.

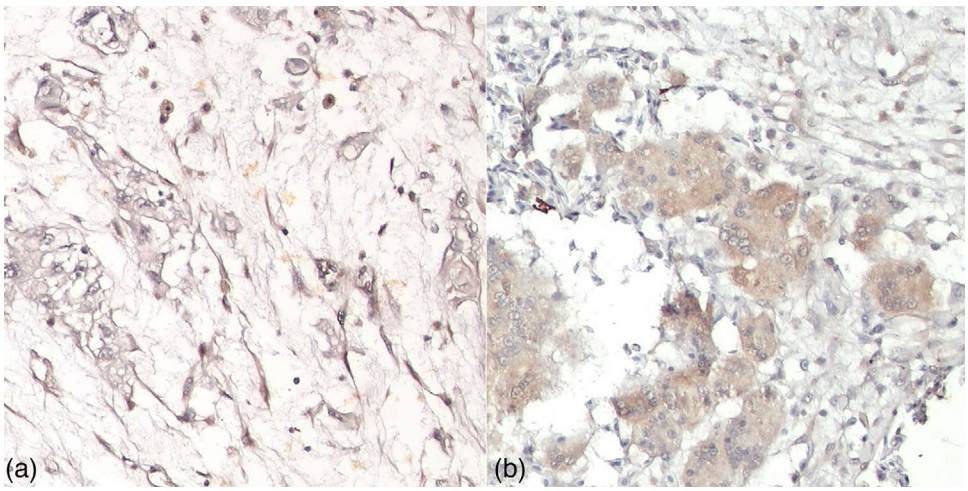

FIGURE 4 Immunohistochemical staining of snake tissue using the streptavidin peroxidase– 3,3'-diaminobenzidine (DAB) method with vimentin antibody as an internal positive control. (a) Positive immunoreactivity in stromal connective tissue cells within the tumour stroma. (b) Positive staining in osteoblasts, while the tumour cells remain negative.

necessary to establish the diagnostic and potential prognostic value of p63 in veterinary and comparative oncology.

PCNA is a protein that regulates DNA replication and repair during cell division and is expressed in cells in the proliferation phase.[20] In humans, high PCNA expression in cancer cells has been associated with increased mitotic activity and poor prognosis.[21,22] In the present case, the strong PCNA immunoreactivity observed in tumour cells indicated a high proliferative capacity, which is in agreement with the pleomorphic and aggressive histomorphological appearance of the lesion. While the prognostic implications of PCNA expression in reptilian tumours have not yet been systematically studied, our results highlight its potential utility as a marker of biological behaviour and support the need for further comparative investigations.

p16 is a tumour suppressor protein that regulates cell cycle progression through inhibition of CDK4 and CDK6.[23] In human cancers, p16 overexpression is often linked to

20526121, 2026, 1, Downloaded from https://bvajournals.onlinelibrary.wiley.com/doi/10.1002/vrc2.70359 by Bursa Uludag University Kutuphane ve Dokumantasyon, Wiley Online Library on [01/02/2026]. See the Terms and Conditions (https://onlinelibrary.wiley.com/terms-and-conditions) on Wiley Online Library for rules of use; OA articles are governed by the applicable Creative Commons License

TABLE 1 Summary information of the antibodies used.

Antibody	Supplier	Product code	Clonality	Isotype	Epitope unmasking	Dilution	Incubation time	Positive control
CK/5	Santa-Cruz	sc-32721	Monoclonal	Mouse	Citrate buffered	1:300	Overnight 4°C	Canine SCC
p63	Santa-Cruz	sc-25268	Monoclonal	Mouse	Citrate buffered	1:400	Overnight 4°C	Rat nasopharynx
p16	Santa-Cruz	sc-1661	Monoclonal	Mouse	Citrate buffered	1:300	Overnight 4°C	Rat testis
Vimentin	Elabscience	E-AB-36172	Polyclonal	Rabbit	Citrate buffered	1:400	Overnight 4°C	Canine skin tissue
Melan-A	Santa-Cruz	sc-20032	Monoclonal	Mouse	Citrate buffered	1:400	Overnight 4°C	Canine melanoma
MAC387	Santa-Cruz	sc-66204	Monoclonal	Mouse	Citrate buffered	1:400	Overnight 4°C	Canine SCC
CD1a	Santa-Cruz	sc-5265	Monoclonal	Mouse	Citrate buffered	1:300	Overnight 4°C	Canine skin tissue
PCNA	Santa-Cruz	sc-56	Monoclonal	Mouse	Citrate buffered	1:500	Overnight 4°C	Canine lymphoid

Abbreviations: PCNA, proliferating cell nuclear antigen; SCC, squamous cell carcinoma.

retinoblastoma protein (pRb) inactivation, commonly mediated by HPV infection, and is considered a surrogate marker for HPV-associated SCCs.[24–27] Although papillomaviruses have not been conclusively proven to cause SCC in snakes, viral DNA has been detected in some cases.[28] The significance of p16 expression in papillomavirus-infected tumour cells in snakes is unknown. In the present case, tumour cells did not express p16, suggesting that papillomavirus infection was unlikely to play a role. Molecular confirmation was not possible, as PCR could not be performed. Since p16 upregulation can also occur independently of viral infection through pRb inactivation, its absence may indicate that this pathway was not involved in the present tumour. Considering the poorly differentiated and highly mitotic features of the neoplasm, p16 expression might have been expected; therefore, further studies are needed to clarify the role of p16 in reptilian SCC.

Vimentin is one of the most widely expressed and highly conserved proteins of the type 3 intermediate filament family, predominantly expressed in connective tissue mesenchymal cells in adults.[29] It has been established that epithelial cells typically do not express vimentin except during the epithelial–mesenchymal transition process.[30] In our case, although the tumour stromal connective tissue and peritumoural connective tissue cells expressed vimentin, the tumour cells did not express it, which confirmed the internal control of the antibody used and confirmed that the tumour cells were most likely not of mesenchymal origin.

MAC387 is an antibody against calprotectin and is widely used as a marker for monocytes and macrophages that have migrated into tissues in immunohistochemical studies. Furthermore, positive MAC387 expression has been observed in human histiocytic sarcoma cases.[31,32] In our study, the absence of MAC387 expression in tumour cells suggests that this tumour is not of histiocytic origin. However, staining could not be performed due to the lack of antibodies against CD163, one of the most reliable antigens for demonstrating histiocytic origin.

CD1a is a glycoprotein belonging to the CD1 family that plays an important role in the immune system, particularly in presenting antigens to T cells.[33] CD1a-positive cells are typically found in Langerhans cells (LCs), a unique type of dendritic cell population in the epidermis, as well as in transient thymocyte populations.[34,35] In the present case, CD1a expression was not detected in tumour cells, thereby excluding an LC origin.

Melan-A, also known as MART-1 (melanoma antigen recognised by T cells), is a melanocytic differentiation antigen associated with cells belonging to the melanocytic cell lineage. It plays an important role in immunological recognition because it is frequently expressed in malignant melanomas.[36,37] Melanophoromas are a type of tumour that originates from melanocytes. These tumours have been observed in snakes and are considered the third most prevalent. It has been documented that, immunohistochemically, Melan-A sensitivity is low in melanophoromas and that S100 sensitivity is higher.[38–40] In the present case, tumour cells were negative for Melan-A, suggesting that the neoplasm is unlikely to be of melanocytic origin. However, S100 staining could not be performed, which should be considered when interpreting these findings.

It is worth discussing whether artificial UV radiation could be a potential risk factor for SCC, as the snake is kept in a closed environment using UV lamps. Although UV radiation is known to be one of the main risk factors for skin cancers in humans,[41] there is no evidence that indoor UV lamps could produce similar genotoxic effects in snakes. However, since there are insufficient data on how keeping snakes indoors, as opposed to their natural habitat, changes their UV exposure levels and effects, this issue should be addressed in detail in further studies. Thus, clarifying the effects of artificial UV radiation on the pathogenesis of oSCC in snakes will guide the development of diagnostic and preventive measures.

It is important to acknowledge the limitations of this study. Although positive staining of stromal tissues in vimentin IHC confirmed the internal control, positive control staining against p16, MAC387, CD1a and Melan-A antigens could not be performed due to the unavailability of snake tissue. Therefore, the possibility that the negative expression

20526121, 2026, 1, Downloaded from https://bvajournals.onlinelibrary.wiley.com/doi/10.1002/vrc2.70359 by Bursa Uludag University Kutuphane ve Dokumantasyon, Wiley Online Library on [01/02/2026]. See the Terms and Conditions (https://onlinelibrary.wiley.com/terms-and-conditions) on Wiley Online Library for rules of use; OA articles are governed by the applicable Creative Commons License

results obtained for these antigens may be due to interspecies antigenic differences or technical limitations should be considered. In future studies, the use of positive control snake tissues will enhance the reliability of immunohistochemical evaluations.

In conclusion, this case highlights the value of IHC in diagnosis of poorly differentiated oSCCs in snakes. The expression patterns of CK5 and p63 strongly supported the epithelial origin of the tumour, while elevated PCNA levels indicated its aggressive biological behaviour. The negativity of p16, MAC387, CD1a and Melan-A, in addition to vimentin staining, contributed to excluding other tumour possibilities in the differential diagnosis. These findings provide a preliminary contribution to the limited literature on the immunophenotypic characteristics of SCC in snakes and lay the groundwork for future studies with larger sample size.

AUTHOR CONTRIBUTIONS

Mehmet Emre Topcu analysed and interpreted the postmortem, histopathological and immunohistochemical findings and contributed to the diagnostic decision. Ozkan Yavas and Musa Ozgur Ozyigit participated in the histopathological evaluation, immunohistochemical analysis and diagnostic interpretation. Ozkan Yavas also performed microscopic photography and editing. Mehmet Emre Topcu was the primary contributor to manuscript writing and preparation. All the authors reviewed and approved the final manuscript.

ACKNOWLEDGEMENTS

We would like to acknowledge the local zoo for their cooperation and PhD student Ezgi Yumusak for her support during necropsy.

CONFLICT OF INTEREST STATEMENT

The authors declare they have no conflicts of interest related to this article's research, authorship and/or publication.

FUNDING INFORMATION

No financial support was received for this case report's research, authorship or publication.

ETHICS STATEMENT

This case involved a necropsy conducted on a zoo-owned reptile euthanased for humane reasons. No live animal experimentation was conducted, and ethical committee approval was not required for postmortem diagnostic evaluations.

ORCID

Mehmet Emre Topcu https://orcid.org/0009-0007-1631-8805
Ozkan Yavas https://orcid.org/0000-0001-9811-9920
Musa Ozgur Ozyigit https://orcid.org/0000-0003-0682-8127

REFERENCES

1. Stebbins KE, Morse CC, Goldschmidt MH. Feline oral neoplasia: a ten-year survey. Vet Pathol. 1989;26:121–28. https://doi.org/10.1177/030098588902600204
2. Tandon P, Dadhich A, Saluja H, Bawane S, Sachdeva S. The prevalence of squamous cell carcinoma in different sites of oral cavity at our Rural Health Care Centre in Loni, Maharashtra—a retrospective 10-year study. Współcz Onkol. 2017;2:178–83. https://doi.org/10.5114/wo.2017.68628
3. Rust A, McGovern RM, Gostout BS, Persing DH, Pittelkow MR. Human papillomavirus in cutaneous squamous cell carcinoma and cervix of a patient with psoriasis and extensive ultraviolet radiation exposure. J Am Acad Dermatol. 2001;44:681–86. https://doi.org/10.1067/mjd.2001.112359
4. Garner MM, Hernandez-Divers SM, Raymond JT. Reptile neoplasia: a retrospective study of case submissions to a specialty diagnostic service. Vet Clin North Am Exot Anim Pract. 2004;7:653–71. https://doi.org/10.1016/j.cvex.2004.04.002
5. Quinonez GE. Differentiation, histogenesis and morphogenesis: their implications for tumor diagnosis. Med Hypoth. 1999;53:243–45. https://doi.org/10.1054/mehy.1998.0753
6. DeLellis RA, Dayal Y. The role of immunohistochemistry in the diagnosis of poorly differentiated malignant neoplasms. Semin Oncol. 1987;14(2):173–92.
7. Kaufmann O, Fietze E, Mengs J, Dietel M. Value of p63 and cytokeratin 5/6 as immunohistochemical markers for the differential diagnosis of poorly differentiated and undifferentiated carcinomas. Am J Clin Pathol. 2001;116:823–30. https://doi.org/10.1309/21TW-2NDG-JRK4-PFJX
8. Anneroth G, Batsakis J, Luna M. Review of the literature and a recommended system of malignancy grading in oral squamous cell carcinomas. Eur J Oral Sci. 1987;95:229–49. https://doi.org/10.1111/j.1600-0722.1987.tb01836.x
9. LaDouceur EEB. Reptile neoplasia. eBooks. CRC Press; 2020. p. 1–53. https://doi.org/10.1201/9780429154317-1
10. Sato K, Mimura H, Han DC, Kakiuchi T, Ueyama Y, Ohkawa H, et al. Production of bone-resorbing activity and colony-stimulating activity in vivo and in vitro by a human squamous cell carcinoma associated with hypercalcemia and leukocytosis. J Clin Invest. 1986;78:145–54. https://doi.org/10.1172/JCI112544
11. Sundström BE, Stigbrand TI. Cytokeratins and tissue polypeptide antigen. Int J Biol Markers. 1994;9:102–8. https://doi.org/10.1177/172460089400900207
12. Vasca V, Vasca E, Freiman P, Marian D, Luce A, Mesolella M, et al. Keratin 5 expression in squamocellular carcinoma of the head and neck. Oncol Lett. 2014;8:2501–4. https://doi.org/10.3892/ol.2014.2591
13. Moll R, Dhouailly D, Sun TT. Expression of keratin 5 as a distinctive feature of epithelial and biphasic mesotheliomas. An immunohistochemical study using monoclonal antibody AE14. Virchows Arch B Cell Pathol Incl Mol Pathol. 1989;58:129–45. https://doi.org/10.1007/bf02890064
14. Miettinen M, Sarlomo-Rikala M. Expression of calretinin, thrombomodulin, keratin 5, and mesothelin in lung carcinomas of different types. Am J Surg Pathol. 2003;27:150–58. https://doi.org/10.1097/00000478-200302000-00002
15. Tsuji K, Wato M, Matsuda S, Matsushima Y, Hayashi T, Yoshida H, et al. Expression of cytokeratin in keratocystic odontogenic tumors and orthokeratinized odontogenic cysts. Jpn J Oral Maxillofac Surg. 2011;57:330–34. https://doi.org/10.5794/jjoms.57.330
16. Nakopoulou L, Janinis J, Panagos G, Comin G, Davaris P. The immunohistochemical expression of proliferating cell nuclear antigen (PCNA/cyclin) in malignant and benign epithelial ovarian neoplasms and correlation with prognosis. Eur J Cancer. 1993;29:1599–601. https://doi.org/10.1016/0959-8049(93)90303-W
17. Foschini MP, Gaiba A, Cocchi R, Pennesi MG, Gatto MR, Frezza GP, et al. Pattern of p63 expression in squamous cell carcinoma of the oral cavity. Virchows Archiv. 2004;444:332–39. https://doi.org/10.1007/s00428-003-0969-x
18. Steurer S, Riemann C, Büscheck F, Luebke AM, Kluth M, Hube-Magg C, et al. p63 expression in human tumors and normal tissues: a tissue microarray study on 10,200 tumors. Biomarker Res. 2021;9(1):7. https://doi.org/10.1186/s40364-021-00260-5
19. Li H, Jing X, Yu J, Liu J, Zhang T, Chen S, et al. A combination of cytokeratin 5/6, p63, p40 and MUC5AC are useful for distinguishing squamous cell carcinoma from adenocarcinoma of the cervix. Diagn Pathol. 2020;15(1):104. https://doi.org/10.1186/s13000-020-01018-7
20. González-Magaña A, Blanco FJ. Human PCNA structure, function and interactions. Biomolecules. 2020;10:570. https://doi.org/10.3390/biom10040570
21. Kinugasa S, Tachibana M, Hishikawa Y, Abe S, Yoshimura H, Monden N, et al. Prognostic significance of proliferating cell nuclear antigen (PCNA) in squamous cell carcinoma of the esophagus. Jpn J Clin Oncol. 1996;26:405–10. https://doi.org/10.1093/oxfordjournals.jjco.a023256
22. Nakopoulou L, Janinis J, Panagos G, Comin G, Davaris P. The immunohistochemical expression of proliferating cell nuclear antigen (PCNA/cyclin) in malignant and benign epithelial ovarian neoplasms

20526121, 2026, 1, Downloaded from https://bvajournals.onlinelibrary.wiley.com/doi/10.1002/vrc2.70359 by Bursa Uludag University Kutuphane ve Dokumantasyon, Wiley Online Library on [01/02/2026]. See the Terms and Conditions (https://onlinelibrary.wiley.com/terms-and-conditions) on Wiley Online Library for rules of use; OA articles are governed by the applicable Creative Commons License

and correlation with prognosis. Eur J Cancer. 1993;29:1599–601. https://doi.org/10.1016/0959-8049(93)90303-W
23. Li J, Poi MJ, Tsai MD. Regulatory mechanisms of tumor suppressor P16INK4Aand their relevance to cancer. Biochemistry. 2011;50:5566–82. https://doi.org/10.1021/bi200642e
24. Sano T, Oyama T, Kashiwabara K, Fukuda T, Nakajima T. Expression status of p16 protein is associated with human papillomavirus oncogenic potential in cervical and genital lesions. Am J Pathol. 1998;153:1741–48. https://doi.org/10.1016/s0002-9440(10)65689-1
25. Smith EM, Wang D, Kim Y, Rubenstein LM, Lee JH, Haugen TH, et al. p16INK4a expression, human papillomavirus, and survival in head and neck cancer. Oral Oncol. 2007;44:133–42. https://doi.org/10.1016/j.oraloncology.2007.01.010
26. Geißler C, Tahtali A, Diensthuber M, Gassner D, Stöver T, Wagenblast J, et al. The role of p16 expression as a predictive marker in HPV-positive oral SCCHN—a retrospective single-center study. Anticancer Res. 2013;33:913–16.
27. Ralli M, Singh S, Yadav SPS, Sharma N, Verma R, Sen R. Assessment and clinicopathological correlation of p16 expression in head and neck squamous cell carcinoma. J Cancer Res Therap. 2016;12:232. https://doi.org/10.4103/0973-1482.151447
28. Eleni C, Corteggio A, Altamura G, Meoli R, Cocumelli C, Rossi G, et al. Detection of papillomavirus DNA in cutaneous squamous cell carcinoma and multiple papillomas in captive reptiles. J Comp Pathol. 2017;157:23–26. https://doi.org/10.1016/j.jcpa.2017.04.005
29. Franke WW, Grund C, Kuhn C, Jackson BW, Illmensee K. Formation of cytoskeletal elements during mouse embryogenesis. Differentiation. 1982;23:43–59. https://doi.org/10.1111/j.1432-0436.1982.tb01266.x
30. Vilela P, Heuer-Jungemann A, El-Sagheer A, Brown T, Muskens OL, Smyth NR, et al. Sensing of vimentin mRNA in 2D and 3D models of wounded skin using DNA-coated gold nanoparticles. Small. 2018;14(12):e1703489. https://doi.org/10.1002/smll.201703489
31. Stříž I, Trebichavský I. Calprotectin—a pleiotropic molecule in acute and chronic inflammation. Physiol Res. 2004;53:245–53. https://doi.org/10.33549/physiolres.930448
32. Soulas C, Conerly C, Kim WK, Burdo TH, Alvarez X, Lackner AA, et al. Recently infiltrating MAC387+ monocytes/macrophages. Am J Pathol. 2011;178:2121–35. https://doi.org/10.1016/j.ajpath.2011.01.023
33. Xu H, Zhang H, Sun S, Zhang J, Huo J, Zhou C. Integrated analysis of CD1A immune infiltration and competing endogenous RNA networks in COAD. Int J Gen Med. 2024;17:2037–53. https://doi.org/10.2147/ijgm.s455546
34. West JA, Olsen SL, Mitchell JM, Priddle RE, Luke JM, Åkefeldt SO, et al. Polyclonal T-cells express CD1A in Langerhans cell histiocytosis (LCH) lesions. PLoS One. 2014;9:e109586. https://doi.org/10.1371/journal.pone.0109586
35. Riillo C, Caracciolo D, Grillone K, Polerà N, Tuccillo FM, Bonelli P, et al. A novel bispecific T-cell engager (CD1a x CD3ε) BTCE is effective against cortical-derived T cell acute lymphoblastic leukemia (T-ALL) cells. Cancers. 2022;14:2886. https://doi.org/10.3390/cancers14122886
36. Dutoit V, Rubio-Godoy V, Pittet MJ, Zippelius A, Dietrich PY, Legal FA, et al. Degeneracy of antigen recognition as the molecular basis for the high frequency of naive A2/Melan-A peptide Multimer+ CD8+ T cells in humans. J Exp Med. 2002;196:207–16. https://doi.org/10.1084/jem.20020242
37. Romero P, Speiser DE, Rufer N. Deciphering the unusual HLA-A2/Melan-A/MART-1-specific TCR repertoire in humans. Eur J Immunol. 2014;44:2567–70. https://doi.org/10.1002/eji.201445004
38. Beanes A, Passos M, Cavalcanti E, Zani G, Bandinelli M, Bandarra P, et al. Melanophoroma in a lichtenstein's green racer snake. Vet Clin Pathol. 2023;52:527–30. https://doi.org/10.1111/vcp.13222
39. Sykes J, Trupkiewicz J. Reptile neoplasia at the Philadelphia zoological garden, 1901–2002. J Zoo Wildl Med. 2006;37:11–19. https://doi.org/10.1638/04-112.1
40. Freitas S, Pereira L, Silva M, Chinen K, Bandarra M. First report of melanophoroma in salvator merianae. Braz J Vet Pathol. 2024;17:104–7. https://doi.org/10.24070/bjvp.1983-0246.v17i2p104-107
41. Aziz MH, Manoharan HT, Verma AK. Protein kinase Cε, which sensitizes skin to sun's UV radiation-induced cutaneous damage and development of squamous cell carcinomas, associates with Stat3. Cancer Res. 2007;67:1385–94. https://doi.org/10.1158/0008-5472.CAN-06-3350

How to cite this article: Topcu ME, Yavas O, Ozyigit MO. Pleomorphic oral squamous cell carcinoma in a captive Dumeril's ground boa (*Acrantophis dumerili*) with immunohistochemical analysis. Vet Rec Case Rep. 2026;14:e70359. https://doi.org/10.1002/vrc2.70359

MULTIPLE CHOICE QUESTION

What is the most likely diagnosis for an oral mass in a Dumeril's ground boa that shows polygonal neoplastic cells with cytokeratin-5 and p63 positivity, high mitotic activity and maxillary bone invasion?

POSSIBLE ANSWERS TO MULTIPLE CHOICE QUESTION

A. Ameloblastoma
B. Melanoma
C. Fibrosarcoma
D. Pleomorphic oral squamous cell carcinoma
E. Histiocytic sarcoma
F. Oral papilloma

CORRECT ANSWER

(D) Pleomorphic oral squamous cell carcinoma

Explanation: Histopathological features, including polygonal cell morphology, high mitotic index and invasive behaviour, along with positive immunoreactivity for cytokeratin-5 and p63 and negative staining for vimentin, Melan-A, CD1a, MAC387 and p16, support a diagnosis of pleomorphic oral squamous cell carcinoma. The presence of proliferating cell nuclear antigen in 75% of tumour cells further indicates a highly proliferative malignancy.

20526121, 2026, 1, Downloaded from https://bvajournals.onlinelibrary.wiley.com/doi/10.1002/vrc2.70359 by Bursa Uludag University Kutuphane ve Dokumantasyon, Wiley Online Library on [01/02/2026]. See the Terms and Conditions (https://onlinelibrary.wiley.com/terms-and-conditions) on Wiley Online Library for rules of use; OA articles are governed by the applicable Creative Commons License